



Chapter

5

Arthroscopic Treatment of Superior Labral (SLAP) Tears

Brian Cole and John-Paul Rue

DEFINITION

Superior labral (SLAP) tears represent injury to the superior aspect of the glenoid labrum, extending from anterior to posterior, including the biceps anchor.¹⁴

ANATOMY

- The superior glenoid labrum is composed of fibrocartilaginous tissue between the hyaline cartilage of the glenoid surface and the joint capsule fibrous tissue.¹³
- The vascular supply of the glenoid labrum does not come from the underlying glenoid, but rather from penetrating branches of the suprascapular, circumflex scapular, and posterior humeral circumflex arteries in the surrounding capsule and periosteal tissue.
- There is histologic evidence that vascularity is decreased in the anterior, anterosuperior, and superior aspects of the glenoid labrum.²

PATHOGENESIS

- The long head of the biceps functions to depress the humeral head and serves as an adjunct anterior stabilizer of the shoulder.^{5,6}
- Disruption of the biceps anchor and the superior labrum, as seen in type II SLAP tears, can result in glenohumeral instability.
- Although SLAP tears are commonly associated with trauma such as traction or compression injuries, up to one third of patients with SLAP lesions have no history of trauma.¹⁰
- SLAP tears are commonly classified according to Snyder¹⁴ as type I (fraying of superior labrum with intact biceps anchor), type II (detached superior labrum and biceps anchor), type III (bucket-handle tear of the superior labrum with intact biceps anchor), and type IV (bucket-handle tear of the superior labrum with extension into the biceps tendon).
- Other variations have been described that reflect associated injury to the anterior labrum and other structures.⁸

NATURAL HISTORY

- Conservative nonoperative treatment of SLAP tears is usually unsuccessful.
- Simple débridement of unstable SLAP tears (type II and IV) is generally not recommended because the results are poor.³

PATIENT HISTORY AND PHYSICAL FINDINGS

- Traction and compression are the two primary mechanisms of injury for SLAP tears.
- A SLAP tear should be considered in a patient with a history of a traction or compression injury with persistent mechanical symptoms such as catching or locking.
- Several clinical tests have been described that focus on the examination of the biceps tendon anchor on the superior

glenoid. The Speed, Yergason, O'Brien, and load-compression tests are commonly used.

- Speed and Yergason tests: Pain with the maneuvers suggests a SLAP tear.
- O'Brien test: Pain with downward pressure applied to the internally rotated arm that is relieved with supination suggests a SLAP tear.
- Load-compression test: Painful clicking or popping suggests a SLAP tear.
- Type II SLAP tears found in younger patients are commonly associated with instability and a Bankart lesion, whereas type II SLAP tears found in patients older than 40 are often associated with rotator cuff pathology.⁷
- Although no single clinical test can predictably be used to diagnose a SLAP tear, the examiner should use all of these tests, along with the history and a high clinical index of suspicion, to make the diagnosis of a SLAP tear.

IMAGING AND OTHER DIAGNOSTIC STUDIES

- Although conventional radiographs (anteroposterior and supraspinatus outlet and axillary views) are the standard for initial evaluation of a patient with shoulder complaints, magnetic resonance imaging (MRI) is the most sensitive imaging tool for evaluating the superior glenoid labrum, with a sensitivity and specificity of about 90%.¹
- The use of contrast arthrography MRI may improve the overall accuracy of MR for diagnosing SLAP tears.⁹
- Despite advances in imaging techniques, the gold standard for the diagnosis of a SLAP tear is arthroscopy.

DIFFERENTIAL DIAGNOSIS

- Glenohumeral instability
- Rotator cuff pathology
- Acromioclavicular joint pathology

NONOPERATIVE MANAGEMENT

- Physical therapy is the mainstay of nonoperative treatment of most shoulder injuries.
- Selective intra-articular injections with local anesthetic and corticosteroids can be diagnostic and occasionally therapeutic.
- The rehabilitation program should focus on achieving and maintaining a full range of motion and strengthening the rotator cuff and scapula stabilizers.
- Although physical therapy may be useful for regaining range of motion and strength, most patients with SLAP tears will continue to have symptoms despite physical therapy.

SURGICAL MANAGEMENT

- Surgical treatment of SLAP tears should be considered for patients who have persistent symptoms despite appropriate conservative management.

- Contraindications for SLAP repair include patients who are high-risk surgical candidates (ie, the risk of anesthetic complications outweighs the possible benefits of successful repair).

Preoperative Planning

- Preoperative assessment of glenohumeral instability is paramount to understanding the pathophysiology of a patient's shoulder complaints.
- Associated instability and any other coexisting pathology must also be addressed at the time of SLAP repair.

Positioning

- Beach-chair position
- Lateral decubitus position
 - May be preferred for cases of suspected labral pathology, especially if associated with posterior instability, because

this position allows improved visualization and access with distraction.

- No more than 10 to 15 pounds of traction should be used owing to increased risk of brachial plexus injuries.

Approach

- The primary goal of any SLAP repair is to stabilize the biceps anchor and address any coexisting pathology.
- After a thorough diagnostic evaluation, SLAP lesions are treated according to Snyder¹⁴ (see the Techniques section).
 - Standard anterosuperior and anteroinferior portals are established.
 - Accessory portals may also be established depending on the location of the SLAP tear.

TYPE I SLAP TEARS

- Type I SLAP tears may be treated using a motorized shaver to simply débride the degenerative or frayed tissue.
- Care must be taken not to detach the biceps anchor from the superior glenoid.

TYPE II SLAP TEARS

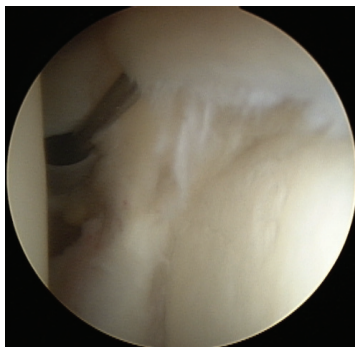
- Type II SLAP tears are the most commonly encountered SLAP tears (**TECH FIG 1**).
 - They represent detachment of the biceps anchor from the superior glenoid labrum.
 - As such, the primary goal of any repair should be to securely reattach the superior labral tissue to the superior glenoid.

Glenoid Preparation

- After identifying the detachment by direct probing, a 4.5-mm motorized shaver is used to gently débride any frayed or degenerative tissue.
- A motorized burr is used to débride the superior glenoid to exposed, bleeding bone (**TECH FIG 2**).

Accessory Portal Placement

- An accessory trans-rotator cuff portal is made using an outside-in technique. No cannula is inserted because this portal will be used only to insert the anchor.

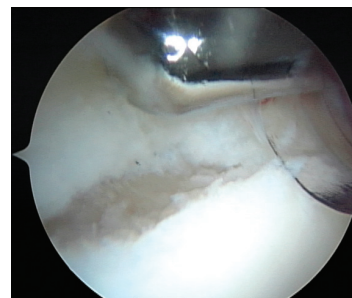


TECH FIG 1 • Arthroscopic view of type II superior labral anterior posterior (SLAP) lesion.

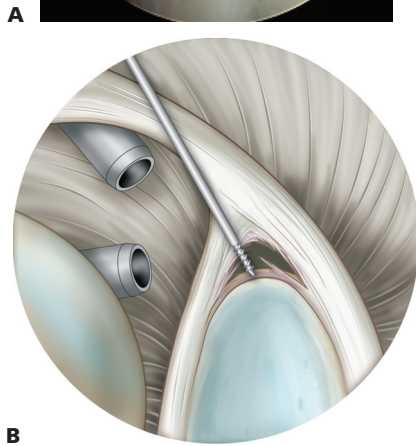
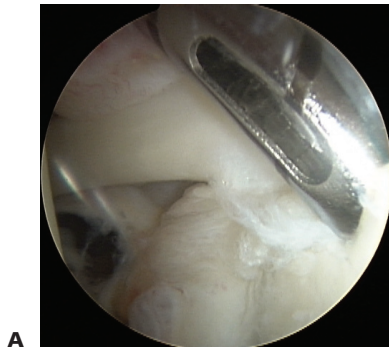
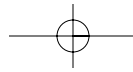
- This portal may be adjusted anteriorly or posteriorly depending on the location of the SLAP tear.
- A spinal needle is used to ensure that the correct trajectory is achieved to place the anchor at about a 45-degree angle to the glenoid face.
- A no. 11 blade knife is used to make the skin incision, but a cannula is not inserted because this portal will be used only to insert the suture anchor drill guide and anchor after drilling.

Suture Anchor Placement

- The suture anchor drill guide is placed on the glenoid face at about a 45-degree angle to the face, ensuring that the anchor will be solidly in bone (**TECH FIG 3**).
 - The suture anchor may be single- or double-loaded with nonabsorbable no. 2 braided suture, depending on preference.
 - If more than one suture anchor is to be used, the surgeon starts the repair posteriorly and works anteriorly to aid in visualization.
- The anchor is placed in the same trajectory as the drill, ensuring that the drill guide is maintained in its proper orientation and position.



TECH FIG 2 • Preparing superior glenoid with burr.



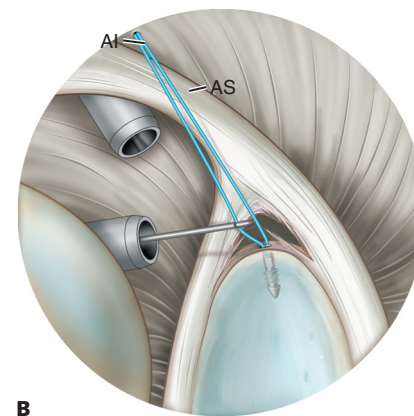
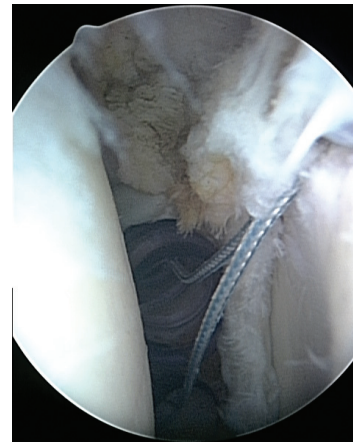
TECH FIG 3 • Drilling suture anchor through lateral portal.

Suture Management

- One limb (limb a) of the suture is retrieved out through the anterior superior cannula, using either a crochet hook or suture grasper.
- A crochet hook is used to capture the other limb (limb b) of the anchor suture and bring it out the anterior inferior cannula (**TECH FIG 4**).

Suture Passage

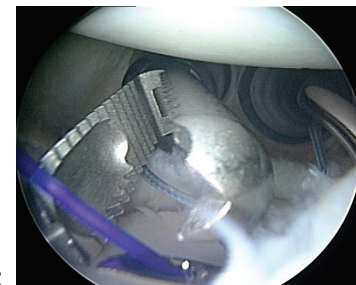
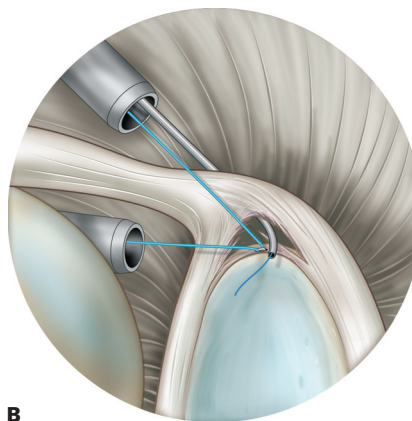
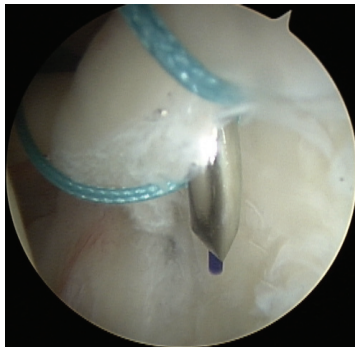- Through the anterosuperior cannula and starting at the posterior edge of the tear superiorly, the surgeon passes a tissue penetrator (Spectrum, ConMed Linvatec, Largo, FL) through the labrum (**TECH FIG 5A,B**).
 - A 45-degree left-curved tissue penetrator is used for a right shoulder SLAP tear (45-degree right-curved for



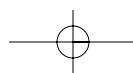
TECH FIG 4 • The surgeon retrieves one limb of the anchor suture out the anterosuperior cannula (AS) and one limb out the anteroinferior cannula (AI).

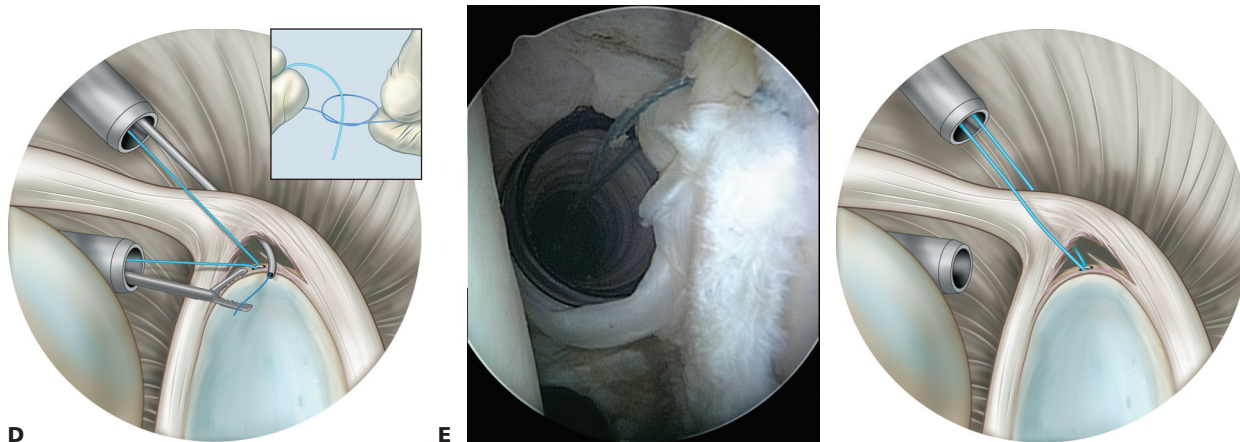
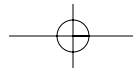
the left shoulder) loaded with a no. 1 monofilament or Shuttle Relay suture passer (ConMed Linvatec, Largo, FL) as a pull-through suture.

- An arthroscopic grasper inserted through the anteroinferior cannula is used to grasp the monofilament passing suture as it penetrates the superior labrum, and the free end is pulled out through the anteroinferior cannula (**TECH FIG 5C,D**).
- A simple knot is tied in the passing suture (see Tech Fig 5D, inset) and the free end of limb b from the suture an-



TECH FIG 5 • **A,B**. Spectrum tissue penetrator loaded with monofilament passing suture through superior labrum. **C,D**. Shuttle relay passing suture retrieved through the anteroinferior cannula. (*continued*)





TECH FIG 5 • (continued) **E,F**. The surgeon firmly pulls the shuttle relay suture through the anterosuperior cannula so that the two ends of the anchor suture are together in the anterosuperior cannula.

chor is inserted through the loop. The suture is pulled gently but firmly through the anterosuperior portal so that the two ends of the anchor suture are together out of the anterosuperior portal (**TECH FIG 5E,F**). (If a Shuttle Relay suture passer is being used, the free end of the anchor suture is placed through the wire loop and the same steps are followed.)

- The surgeon should ensure that the anchor is not unloaded of its suture during this process by maintaining continuous arthroscopic visualization of the anchor.
- There should be no movement of the suture at the anchor eyelet.

Knot Tying

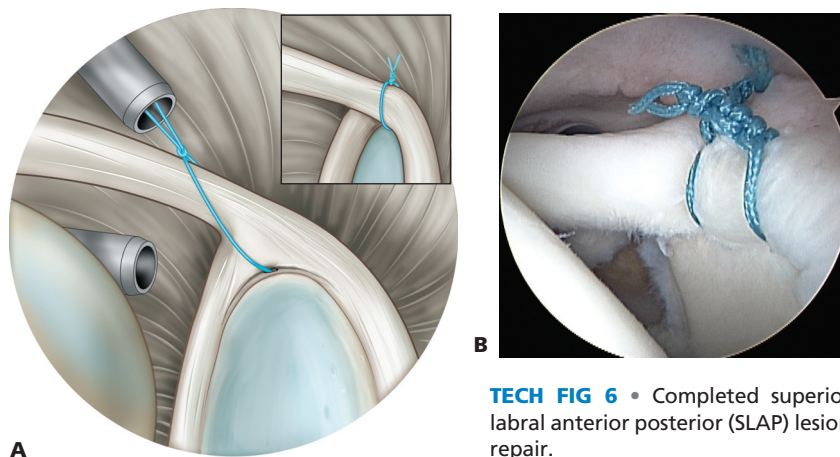
- Making sure that the post limb is off the glenoid surface, the surgeon ties the suture using either a sliding knot or

a series of half-hitches, taking care to switch posts and alternate directions of the loops.

- The excess suture is cut using an arthroscopic suture cutter.

Additional Suture Anchor Placement

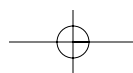
- This procedure is repeated until the biceps anchor has been securely reattached to the superior glenoid (**TECH FIG 6**).
- The surgeon should take care when securing the anterior aspect of the SLAP tears so that a normal labral foramen or an anterosuperior labral variant is not incorrectly identified as a SLAP tear, causing inadvertent tightness and resulting in decreased range of motion.



TECH FIG 6 • Completed superior labral anterior posterior (SLAP) lesion repair.

TYPE III SLAP TEARS

- Simple débridement of the labral bucket-handle tear is the preferred surgical technique for type III SLAP tears because the biceps anchor is intact.



TYPE IV SLAP TEARS

- Type IV SLAP tears involve a bucket-handle tear of the superior labrum with a tear of the biceps tendon.
 - The biceps anchor may be detached as well.
- Treatment is débridement of the labral tear and biceps tendon tear, with repair of the biceps anchor if needed, essentially converting the tear to a type II and then repairing the anchor detachment.
 - In an older patient with significant biceps tendon degeneration, biceps tenodesis should be considered.
 - Similarly, in a younger patient with a tear extending into the biceps tendon, repair of any tendon tears should be considered.

PEARLS AND PITFALLS

Indications	■ All associated pathology is identified and addressed (eg, instability, rotator cuff pathology, acromioclavicular joint disorders).
Planning	■ Lateral decubitus positioning is considered if posterior labral pathology is suspected.
Portal placement	■ Proper technique must be used in placing portals at the beginning of the case, with attention to positioning of the portals both in the superoinferior plane and the medial-lateral plane. Improperly placed portals can greatly increase the difficulty of this operation. A spinal needle is used to judge the angle of approach for each portal before making the portal to ensure that the correct trajectory is obtained.
Suture management	■ When retrieving and handling anchor sutures, the surgeon should not place tension on either limb and should maintain continuous visualization of the anchor–suture interface to ensure that the anchor is not unloaded. The surgeon should take care to avoid twists because these can place increased stress on a suture or knot and lead to breakage. The surgeon should place one anchor at a time and tie each suture or remove and replace the cannula and place the suture outside the cannula for suture storage to prevent tangles during tying.
Other	■ Articular cartilage damage is avoided by firmly seating the drill guide on the edge of the glenoid and avoiding skiving onto the glenoid face.

POSTOPERATIVE CARE

- 0 to 4 weeks: Sling at all times except for hygiene and exercises. (Active range of motion allowed in all planes except external rotation in abduction starting at 2 weeks.)
- 4 weeks: Discontinue sling. Start passive range of motion with emphasis on posterior capsule stretching.
- 6 weeks: External rotation in abduction allowed. Start strengthening.
- 3 months: Sports allowed except throwing (4 months)

OUTCOMES

- Table 1 summarizes outcomes from studies of SLAP tear repairs.

COMPLICATIONS

- Infection (rare)
- Brachial plexus neuropathy secondary to traction of the arm in the lateral decubitus position
 - Care must be taken to ensure that the smallest amount of traction and distraction necessary is used, with close monitoring of the tension applied to neurovascular structures.
- Persistent pain
 - Healed repair: Biceps tenodesis should be considered for pain relief.

Table 1 Results of Arthroscopic Superior Labral Anterior Posterior (SLAP) Lesion Repair

Study	Surgical Procedure	No. of Patients	Average Follow-up	Results
Cordasco et al, 1993 ³	Débridement only	27		89% good or excellent results at 1-year follow-up; 63% excellent results at 2-year follow-up; only 44% return to competition at 2-year follow-up
Field & Savoie, 1993 ⁴	Arthroscopic suture repair	20	21 mo	Rowe scale: 100% good or excellent results ASES scores: statistically significant increase in function score, decrease in pain score
Morgan et al, 1998 ¹¹	Arthroscopic suture repair	102	1 year	97% good or excellent results 4% return to competition among overhead throwers
O'Brien et al, 2002 ¹²	Arthroscopic suture repair (transrotator cuff portal)	31 (type II)	3.7 yr	71% good or excellent, 19% fair results Average postoperative ASES score: 87.2

ASES, American Shoulder and Elbow Society.

- Failed repair
 - Repeat arthroscopy should be considered with revision repair.
 - Biceps tenodesis should be considered for severely degenerative or intractable cases.

REFERENCES

1. Chandnani V, Yeager T, Deberardino T, et al. Glenoid labral tears: prospective evaluation with MR imaging, MR arthrography, and CT arthrography. *AJR Am J Roentgenol* 1993;161:1229-1235.
2. Cooper D, Arnoczky S, O'Brien S, et al. Anatomy, histology, and vascularity of the glenoid labrum: an anatomical study. *J Bone Joint Surg Am* 1992;74A:46-52.
3. Cordasco F, Steinman S, Flatow E, et al. Arthroscopic treatment of glenoid labral tears. *Am J Sports Med* 1993;21:425-431.
4. Field L, Savoie F. Arthroscopic suture repair of superior labral detachment lesions of the shoulder. *Am J Sports Med* 1993;21:783-790.
5. Healey J, Barton S, Noble P, et al. Biomechanical evaluation of the origin of the long head of the biceps tendon. *Arthroscopy* 2001;17:378-382.
6. Itoi E, Kuechle D, Newman S, et al. Stabilising function of the biceps in stable and unstable shoulders. *J Bone Joint Surg Br* 1993;75B:546-550.
7. Kim T, Quaele W, Cosgarea A, et al. Clinical features of the different types of SLAP lesions: an analysis of one hundred and thirty-nine cases. *J Bone Joint Surg Am* 2003;85A:66-71.
8. Maffet M, Gartsman G, Moseley B. Superior labrum-biceps tendon complex lesions of the shoulder. *Am J Sports Med* 1995;23:93-98.
9. Magee T, Williams D, Mani N. Shoulder MR arthrography; which patient group benefits most? *AJR Am J Roentgenol* 2004;183:969-974.
10. Mileski R, Snyder S. Superior labral lesions in the shoulder: pathoanatomy and surgical management. *J Am Acad Orthop Surg* 1998;6:121-131.
11. Morgan C, Burkhard S, Palmeri M, et al. Type II SLAP lesions: three subtypes and their relationships to superior instability and rotator cuff tears. *Arthroscopy* 1998;14:553-565.
12. O'Brien S, Allen A, Coleman S, et al. The trans-rotator cuff approach to SLAP lesions: technical aspects for repair and a clinical follow-up of 31 patients at a minimum of 2 years. *Arthroscopy* 2002;18:372-377.
13. Prodromos C, Ferry J, Schiller A, et al. Histological studies of the glenoid labrum from fetal life to old age. *J Bone Joint Surg Am* 1990;72A:1344-1348.
14. Snyder S, Karzel R, Del Pizzo W, et al. SLAP lesions of the shoulder. *Arthroscopy* 1990;6:274-279.
15. Verma NN, Cole BJ, Romeo AA. Arthroscopic repair of SLAP lesions. In: Miller MD, Cole BJ, eds. *Textbook of Arthroscopy*. Philadelphia: Saunders, 2004:159-168.