



# Ninety-day complications following the Latarjet procedure



Rachel M. Frank, MD<sup>a,\*</sup>, Bonnie Gregory, MD<sup>b</sup>, Michael O'Brien, MA<sup>b</sup>,  
Eamon Bernardoni, MD<sup>c</sup>, Nikhil N. Verma, MD<sup>b</sup>, Brian J. Cole, MD, MBA<sup>b</sup>,  
Gregory P. Nicholson, MD<sup>b</sup>, Anthony A. Romeo, MD<sup>d</sup>

<sup>a</sup>CU Sports Medicine, Department of Orthopedics, University of Colorado School of Medicine, Boulder, CO, USA

<sup>b</sup>Department of Orthopaedic Surgery, Rush University Medical Center, Chicago, IL, USA

<sup>c</sup>Department of Orthopaedic Surgery, University of Wisconsin, Madison, WI, USA

<sup>d</sup>Rothman Institute, New York, NY, USA

**Background:** The purpose of this study was to describe the rate and type of complications occurring within 90 days following the Latarjet procedure for anterior glenohumeral instability.

**Methods:** Consecutive patients undergoing the Latarjet procedure by fellowship-trained surgeons from a single institution between 2007 and 2016 were included for analysis. Indications for the Latarjet procedure included primary or recurrent anterior instability with clinically significant anterior glenoid bone loss and/or failed prior arthroscopic stabilization. Patients undergoing the Latarjet procedure after prior glenoid bone grafting were excluded. All complications that occurred within 90 days of surgery were analyzed and correlated with demographic factors.

**Results:** A total of 146 consecutive patients (146 shoulders) were included. Of these patients, 11 were lost to follow-up and 2 were excluded for having undergone prior open bone grafting. Among the remaining 133 patients (average age, 28.5 ± 11.8 years; 75% male patients), 10 total complications occurred within 90 days of surgery, for an overall short-term complication rate of 7.5%. Of these 10 complications, 6 required subsequent surgery, with recurrent instability in 2 cases (overall rate, 1.50%), infection in 2 (overall rate, 1.50%), musculocutaneous nerve palsy in 1 (overall rate, 0.75%), and postoperative pain in 1 (overall rate, 0.75%). The remaining 4 complications were transient, resolving with nonoperative treatment. No cases of hardware failure or graft osteolysis were reported.

**Conclusions:** The overall 90-day complication rate following the Latarjet procedure for anterior shoulder stabilization was 7.5%. In 6 of the 10 cases, complications led to subsequent surgery, including recurrent instability in 2, while in the remaining 4 cases, the complications were transient and resolved with nonoperative treatment.

**Level of evidence:** Level IV; Case Series; Treatment Study

© 2018 Published by Elsevier Inc. on behalf of Journal of Shoulder and Elbow Surgery Board of Trustees.

**Keywords:** Anterior shoulder instability; shoulder stabilization; Latarjet; 90-day complications; nerve injury; recurrent instability

Approval was received from the Institutional Review Board at Rush University Medical Center (IRB ORA No. 00000482).

\*Reprint requests: Rachel M. Frank, MD, CU Sports Medicine, Department of Orthopedics, University of Colorado School of Medicine, 2150 Stadium Dr, Boulder, CO 80309, USA.

E-mail address: [rachel.frank@ucdenver.edu](mailto:rachel.frank@ucdenver.edu) (R.M. Frank).

The use of the Latarjet procedure for the treatment of anterior shoulder instability has increased over the past 2 decades.<sup>7,9</sup> While the underlying reasons for the increase in Latarjet procedures are not entirely clear, increased recognition of the importance of glenoid bone loss, increased familiarity with the technical aspects of the procedure, improvements in arthroscopic techniques, and the increased interest—particularly in Europe—in performing the Latarjet procedure as a primary procedure for instability as opposed to the traditional gold standard of Bankart repair are all likely to contribute. In a recent study looking into national trends in shoulder stabilization surgery among 27,515 patients within a private insurance database between 2007 and 2011, the incidence of arthroscopic Bankart repair increased significantly (from 0.074% to 0.082%,  $P = .01$ ) while the rate of open Bankart repair decreased significantly (from 0.012% to 0.007%,  $P = .016$ ).<sup>9</sup> While accounting for only 3% of all stabilization procedures documented in the database, the incidence of the Latarjet procedure nearly doubled over the same period (from 0.001% to 0.002%,  $P = .014$ ). The increase in popularity of the Latarjet procedure is likely attributable to clinicians gaining a better understanding of risk factors associated with failed soft-tissue stabilization.

The Latarjet procedure has long been considered the gold standard for the management of recurrent instability associated with clinically significant anterior glenoid bone loss.<sup>4,5,7,13-16</sup> The combination of the coracoid bone graft re-creating the anterior arc of the glenoid and the sling effect provided by the conjoined tendon reproducibly results in stable joints at long-term follow-up, with relatively low recurrence rates. Despite historically good to excellent clinical outcomes, complications after the Latarjet procedure are not uncommon,<sup>1,6,8,10-12</sup> with some authors reporting complication rates as high as 25% following both arthroscopic and open techniques.<sup>3,18</sup> Similarly to any surgical procedure, some complications following the Latarjet procedure do not affect overall outcomes and are considered minor while other complications, such as neurovascular injury, may be permanent and are considered major.<sup>12</sup>

Relatively few data on short-term complication rates following the Latarjet procedure are available, particularly in patients who have undergone ipsilateral shoulder surgery prior to the Latarjet procedure. The purpose of this study was to describe the rate and type of complications occurring within 90 days following the Latarjet procedure for anterior glenohumeral instability. We hypothesized that the overall 90-day complication rate would approach 10% and that there would be a significantly higher rate of complications in patients who had undergone prior ipsilateral shoulder surgery compared with those undergoing primary Latarjet procedures.

## Methods

Consecutive patients undergoing the Latarjet procedure for anterior glenohumeral instability by fellowship-trained surgeons from a single institution between 2007 and 2016 identified using a Current

Procedural Terminology search were included for analysis. Indications for the Latarjet procedure included primary or recurrent anterior instability with clinically significant anterior glenoid bone loss (>15%) and/or failed prior arthroscopic stabilization. Patients undergoing the Latarjet procedure after a prior glenoid bone grafting procedure (ie, iliac crest bone graft or allograft reconstruction) were excluded. The electronic medical records of the patients were reviewed by 2 independent observers for all complications that occurred within 90 days of surgery, which were subsequently analyzed and correlated with demographic factors.

Complications were classified as major or minor, and all follow-up care associated with the complication, including any additional surgical procedures, was recorded. Demographic, preoperative, and intraoperative factors potentially associated with the development of a complication, including medical comorbidities and prior ipsilateral shoulder surgery, were analyzed.

## Statistical analysis

Descriptive analysis consisted of frequencies and percentages for discrete data and means and standard deviations for continuous data. All reported  $P$  values are 2 tailed, with an  $\alpha$  level of .05 detecting significant differences (SPSS Statistics, version 23.0; IBM, Armonk, NY, USA).

## Surgical technique

Our preferred surgical technique for Latarjet reconstruction has been previously described in detail.<sup>4</sup> Following a brief diagnostic arthroscopy with the patient in the beach-chair position, we lower the head of the bed to approximately 30°-40° with the arm placed in a commercially available arm holder or held free on a padded Mayo stand. An incision beginning just distal to the coracoid process and extending inferiorly for approximately 5 cm to the axillary fold is made. A modified deltopectoral exposure is performed to expose the conjoined tendon and coracoid process. The coracoid process is gently freed from soft tissues superiorly (coracoacromial ligament) and medially (pectoralis minor), as well as along its undersurface, with the assistance of a periosteal elevator. Once adequate exposure is achieved, with care taken to protect all neurovascular structures, a 90° oscillating saw blade is used to perform osteotomy of the coracoid in a medial to lateral direction just anterior to where the coracoclavicular ligaments insert at the coracoid base; at least 20-22 mm of bone should be harvested. The inferior edge of the coracoid surface is decorticated with the saw blade as well as a burr to prepare for eventual compression with the anterior rim of the glenoid: This will allow the lateral edge of the coracoid to become flush with the anterior glenoid articular surface. Notably, if the congruent arc technique is used, the graft is rotated 90° such that the inferior surface will become flush with the glenoid face. By use of a towel clamp or a custom graft holder, 2 pilot bicortical drill holes are created along the longitudinal axis of the coracoid graft approximately 1 cm apart, and the graft is then stored safely in the wound while the glenoid is exposed. The glenoid is exposed via a subscapularis split (superior two-thirds, inferior one-third) followed by a vertical or T-shaped capsulotomy (depending on the quality of capsular tissue available). The anterior rim of the glenoid is exposed with an elevator and decorticated with a high-speed burr to a bleeding surface to optimize graft compression and healing. The coracoid graft is retrieved from the wound and lined up with the anterior rim of the glenoid

under direct visualization; a custom-made offset guide can also be used to help with graft placement. Two small Kirschner wires are drilled to provisionally hold the coracoid in place. Next, 2 holes are drilled across the glenoid through the previously established drill holes in the coracoid graft, screw length is measured with a depth gauge, and the coracoid graft is subsequently fixed into place via a lag technique with 2 bicortical screws with or without washers or a mini-plate. For the majority of patients, the screws are typically 32–38 mm in length. Various screw types were used throughout the study period, including 3.4- to 3.5-mm diameter and both cannulated and noncannulated. In rare cases, a single screw was used because of a smaller coracoid harvest. The Kirschner wires are removed, and the remnant of the coracoacromial ligament is repaired to the capsule or primary capsular repair is carried out.

## Rehabilitation

A shoulder sling with an abduction pillow is used to support the arm for the first 4–6 weeks following surgery. At week 2, pendulum exercises and passive range of motion in the scapular plane are permitted. At week 4, active-assisted range of motion is initiated. At week 6, gentle strengthening is allowed under the supervision of a physical therapist. Full return to activity is expected at approximately 4–6 months postoperatively, with contact and collision sports restricted until at least 6 months following surgery.

## Results

A total of 146 consecutive patients (146 shoulders) underwent the Latarjet procedure for anterior glenohumeral instability by fellowship-trained surgeons from a single institution between 2007 and 2016. Of the 146 patients, 11 were lost to follow-up, for an overall follow-up rate of 92%. Two additional patients were excluded for having undergone a prior open bone grafting procedure.

Among the remaining 133 patients (average age,  $28.5 \pm 11.8$  years; 75% male patients), there were 10 total complications within 90 days of surgery, for an overall short-term complication rate of 7.5% (Table I). Of these 10 complications, 6 required subsequent surgery, with recurrent instability in 2 (overall rate, 1.50%), infection in 2 (overall rate, 1.50%), musculocutaneous nerve palsy in 1 (overall rate, 0.75%), and unresolved pain and stiffness in 1 (overall rate, 0.75%). Each of the 2 patients who experienced recurrent subluxation events ultimately required conversion to arthroplasty, including hemiarthroplasty in 1 case at 8 months (50-year-old woman with a seizure disorder and prior arthroscopic stabilization, Fig. 1) and total shoulder arthroplasty in the other case at 6 months (45-year-old woman with a large associated Hill-Sachs deformity and moderate joint arthrosis at the time of the Latarjet procedure, Fig. 2). The 2 patients with infections underwent subsequent irrigation and débridement, as well as antibiotic therapy, with resolution of infection following antibiotic treatment. The patient with the musculocutaneous nerve injury ultimately required further surgery in the form of a musculocutaneous nerve decompression and subsequent nerve transfer procedure.

The remaining 4 complications were transient and resolved with nonoperative treatment (Table I), including wound dehiscence ( $n = 1$ , 25-year-old man, resolved with oral antibiotics), hematoma ( $n = 1$ , 22-year-old man, resolved with contrast therapy with heat and ice), complex regional pain syndrome ( $n = 1$ , 26-year-old man, resolved with pain management consultation), and ulnar neuritis ( $n = 1$ , 22-year-old man, resolved itself within 2 months).

As a cohort, the 133 patients had an average age of  $28.5 \pm 11.8$  years (75% male patients), with 92 of the 133 patients undergoing an average of  $1.19 \pm 0.68$  prior ipsilateral shoulder surgical procedures (range, 1–3 prior surgical procedures). There were no significant differences in the number of prior ipsilateral shoulder surgical procedures in patients who experienced a complication compared with those who did not experience a complication ( $P = .63$ ). The 123 patients without complications had an average age of  $28.3 \pm 11.9$  years (75% male patients), with 85 (69%) having undergone at least 1 prior shoulder stabilization procedure. The 10 patients experiencing complications had an average age of  $30.9 \pm 10.9$  years (77% male patients), with 7 (70%) having undergone at least 1 prior shoulder stabilization procedure.

There were no cases of coracoid fracture intraoperatively or postoperatively. No cases of hardware failure or graft osteolysis were observed based on plain radiographic review.

## Discussion

The principal findings of this study suggest that the overall 90-day complication rate following the Latarjet procedure for anterior shoulder stabilization is 7.5%, substantially lower than the previously described rate of 25%. For 6 of the 10 complications, secondary surgery was required, including 2 conversions to arthroplasty for recurrent instability, while in the remaining 4 cases, the complications were transient and resolved with nonoperative treatment. Although only 1 major neurologic complication occurred in this cohort, this injury was considered major and required subsequent nerve transfer. This information can be used to counsel patients on the risks of early complications following the Latarjet procedure.

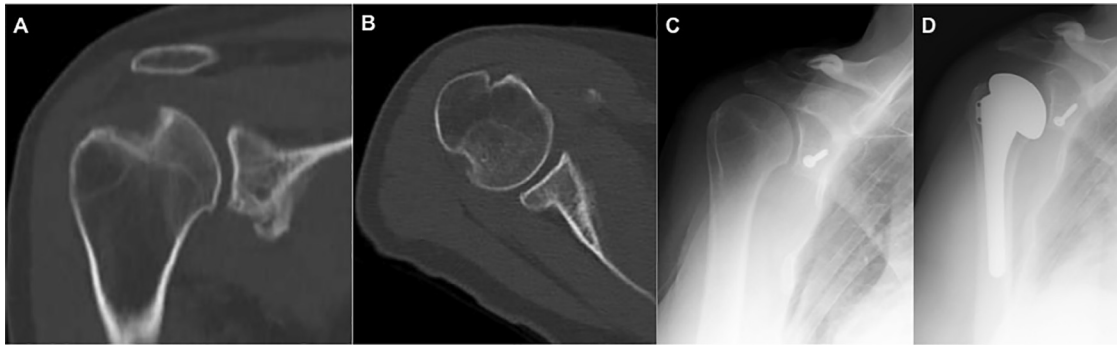
Throughout the studies available in the literature, complications following the Latarjet procedure have been inconsistently described. For example, in some articles, reoperations are considered complications, while in other studies, reoperations are considered separate from complications. The overall nomenclature can be somewhat confusing because, depending on which study is being interpreted, complications may be classified by degree of severity (major complication vs minor complication) or may be designated as “problems” as opposed to “complications.” Overall, significant heterogeneity continues to exist in the description of intraoperative, perioperative, and postoperative adverse events following the Latarjet procedure. In general, major complications include injury to neurovascular structures, deep infections, recurrent glenohumeral instability, and any

**Table I** Summary of major and minor complications occurring within 90 days of Latarjet reconstruction (10 complications in 133 patients, for overall complication rate of 7.5%)

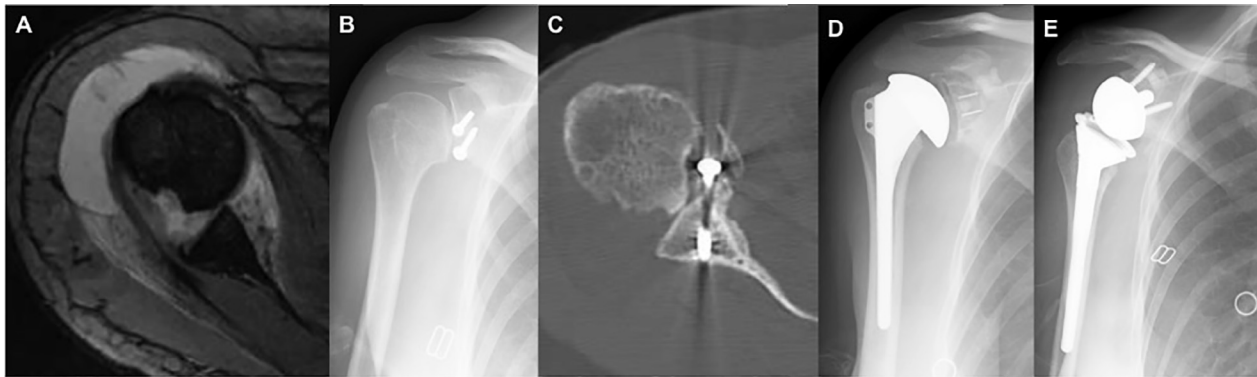
Age (DOS), yr	Sex	Prior Surgical Procedures	Complication	Intervention	Comorbidities
Major complications requiring reoperation					
50	F	2 prior arthroscopic stabilizations; most recent 2 yr prior to Latarjet procedure Large (>40%) Hill-Sachs lesion noted at time of Latarjet procedure (Fig. 1)	Recurrent instability (subluxations)	Immobilization and physical therapy, followed by revision to shoulder hemiarthroplasty (8 mo after Latarjet procedure, Fig. 1)	Anxiety, depression, and sleep disorder
45	F	NA	Recurrent instability; humeral head osteolysis with screw prominence and subsequent arthrosis in setting of minimal pain and poor proprioception	Immobilization and physical therapy, followed by revision to TSA (6 mo after Latarjet procedure) and reverse TSA (9 mo after Latarjet procedure, performed for persistent anterior instability including instability in internal rotation, poor proprioception, and subscapularis attenuation; Fig. 2)	None
22	M	NA	Infection with <i>Cutibacterium</i> (formerly <i>Propionibacterium acnes</i> ) noted 1 week after Latarjet procedure	Irrigation and débridement, as well as prolonged course of intravenous and oral antibiotics	Anxiety and depression
26	M	Arthroscopic stabilization 4 yr prior to Latarjet procedure	Musculocutaneous nerve injury—severe injury with axonotmesis	Musculocutaneous nerve decompression and subsequent nerve transfer procedure	None
44	M	2 prior arthroscopic stabilizations; most recent 1 yr prior to Latarjet procedure	Undetermined infection (no growth on cultures)	Irrigation and débridement, as well as prolonged course of antibiotics	None
27	F	2 prior arthroscopic stabilizations; most recent 3 yr prior to Latarjet procedure	Pain and “stiffness” after surgery, thought to be rotator cuff tendinitis	Subacromial corticosteroid injections ×2, oral anti-inflammatories, and physical therapy; subsequent arthroscopic SAD 1 yr after Latarjet procedure and subsequent mini-open BT 5 yr after Latarjet procedure	Abnormal involuntary movement disorder and asthma
Minor (transient) complications—all resolved without additional surgery					
26	M	2 prior stabilizations (1 arthroscopic and 1 open); most recent 9 mo prior to Latarjet procedure	Complex regional pain syndrome	Referral to pain specialist and additional physical therapy; symptoms resolved 5 mo after Latarjet procedure	None
25	M	NA	Superficial surgical-site infection	10 d of oral antibiotics; resolved uneventfully	None
22	M	Arthroscopic stabilization 4 yr prior to Latarjet procedure	Subjective numbness in ulnar nerve distribution	Observation; symptoms resolved at 6 weeks following Latarjet procedure	Depression
22	M	Arthroscopic instability repair and SLAP débridement 3 yr prior to Latarjet procedure	Hematoma formation	Contrast heat and ice therapy; symptoms resolved 1 mo following Latarjet procedure	None

DOS, date of surgery; F, female; NA, not applicable; TSA, total shoulder arthroplasty; M, male; BT, biceps tenodesis; SAD, subacromial decompression; SLAP, superior labrum anterior to posterior.





**Figure 1** Preoperative coronal (A) and axial (B) computed tomography images of a 50-year-old woman with a history of a seizure disorder and arthroscopic stabilization. Latarjet reconstruction of the right shoulder was performed (C), followed by persistent instability, with conversion to hemiarthroplasty (D).



**Figure 2** (A) Preoperative axial magnetic resonance image of 45-year-old woman with a large associated Hill-Sachs deformity and moderate joint arthrosis. Latarjet reconstruction of the right shoulder was performed (B), followed by persistent instability (C), with conversion to total shoulder arthroplasty at 6 months (D), ultimately followed by revision to reverse arthroplasty for persistent pain (E).

diagnosis related to the operative shoulder requiring a return to the operating room. Minor complications typically include hematoma (not requiring evacuation), superficial infection (not requiring surgical débridement), graft fracture, or hardware complications not adversely affecting outcome. For the purpose of this study, we classified complications as major if they required reoperation or if they resulted in an unsatisfactory outcome or as minor if they were transient and successfully managed without additional surgery. By use of this classification system, of the 10 total complications, 6 required reoperation and were considered major, while the remaining 4 resolved without any significant intervention and were considered minor. Therefore, the major complication rate (and reoperation rate) in this series of 133 patients undergoing the Latarjet procedure for recurrent anterior shoulder instability was 4.5%, and the minor complication rate was 3.0%.

Notably, the patient cohort in this study was complex, with 92 of the 133 patients (69%) having undergone at least 1 prior ipsilateral shoulder surgery. As a cohort, 92 of the 133 patients underwent an average of  $1.19 \pm 0.68$  ipsilateral shoulder surgical procedures prior to the Latarjet procedure, with no significant differences in the number of prior surgical procedures in patients who experienced a complication (70% of whom underwent  $\geq 1$  prior surgical procedures) compared with

those who did not experience a complication (69% of whom underwent  $\geq 1$  prior surgical procedures). Despite the complexity of the patient cohort, our overall complication rate of 7.5% in this series of 133 patients is relatively low compared with historical controls. In 2012, for example, Shah et al<sup>18</sup> reported complications in 12 of 48 shoulders (47 patients) undergoing the Latarjet procedure, for an overall complication rate of 25% at an average of 9.4 months' follow-up (minimum, 6 months). The complications in their series included infection (6%), transient neurologic injury (6%), persistent neurologic injury (4%), and recurrent instability (8%). While the average age of their patient population was older than ours (39 years vs 29 years), their cohort had a similar number of prior ipsilateral shoulder surgical procedures (73% vs 69%). The longer duration of follow-up in the study conducted by Shah et al may play a factor, as complications beyond 90 days were not accounted for in our study.

In 2016, Athwal et al<sup>3</sup> described their rate of intraoperative and early complications (within 90 days) in 83 patients undergoing the Latarjet procedure via an all-arthroscopic technique. They classified adverse events in their series as either problems—unanticipated perioperative events not likely to affect the patient's final outcome—or complications—events likely to negatively affect outcome. Similarly to the

findings reported by Shah et al<sup>18</sup> in their series of open Latarjet procedures, Athwal et al reported 20 adverse events in 83 patients (24%), including an 18% problem rate and a 10% complication rate. The most common adverse event in their series was coracoid graft fracture in 6 patients, of whom 4 had healing without difficulty (considered problems) and 2 required revision surgery (considered complications). The second most common adverse event was described as an inability to place 2 screws in the graft in 5 patients, all of whom healed uneventfully; these cases were considered problems (not complications). Neurovascular complications occurred in 2 patients (considered a complication in 1 and a problem in the other), and 7 total patients required reoperation (3 for hardware removal, 1 for deep infection, and 3 for recurrence) and were classified as having complications. While the average age of the patient population of Athwal et al was similar to ours (28 years vs 29 years), substantially fewer patients in their cohort underwent ipsilateral shoulder surgery prior to the Latarjet procedure compared with our cohort (49% vs 69%). The adverse event rate in their study was over 3 times higher than the complication rate in our study and is likely attributable to the number of intraoperative events included in their calculations. Moreover, the arthroscopic nature of the Latarjet procedure introduces additional complexity, and the learning curve was likely an additional factor.

In a series of 400 patients undergoing 416 open Latarjet procedures (16 patients with bilateral procedures), Gartsman et al<sup>10</sup> reported 21 complications in 19 patients, for an overall complication rate of 5%. These complications consisted of 13 neurologic injuries (3.1%), including 2 patients with multiple nerves affected; 6 infections (1.4%); and 2 hardware complications (0.05%). Of the 6 infections, 3 were deep and required surgery while 3 were superficial and resolved with oral antibiotics. Of the 13 nerve complications, 11 (85%) resolved. Of note, Gartsman et al did show a statistically significant increase in complications with greater age. Within their cohort, only 29.1% had undergone prior ipsilateral shoulder surgery, compared with 69% of patients in our series, and prior surgery was not shown to be a risk factor for complications.

In a 2012 study out of Switzerland, Schmid et al<sup>17</sup> described clinical outcomes and complications in a series of 49 patients undergoing open Latarjet procedures after undergoing at least 1 prior shoulder surgical procedure. At an average follow-up of 38 months, they reported complications in 6 patients, for an overall complication rate of 12%, including 4 cases of delayed wound healing, 1 frozen shoulder that improved with physical therapy, and 1 graft malunion that resulted in pain but not instability. Their complication rate was higher than the complication rate in our study (7.5%); however, 100% of patients in their cohort underwent prior ipsilateral shoulder surgery compared with 69% of patients in our series, possibly representing a more difficult overall patient population.

In a 2016 study, also out of Switzerland, Zimmerman et al<sup>19</sup> compared outcomes and complications of 93 patients

undergoing primary open Latarjet procedures with 271 patients undergoing primary arthroscopic Bankart stabilizations. In the Latarjet group, there were 8 complications, for an overall complication rate of 8.6%, including 3 patients with recurrence of instability (3.2%), 1 postoperative hematoma requiring evacuation (1.1%), 1 removal of hardware (1.1%), 1 screw exchange owing to infraspinatus irritation (1.1%), and 1 secondary arthroscopy for superior labrum anterior to posterior repair (1.1%). In this cohort, no patients had undergone ipsilateral shoulder surgery prior to the Latarjet procedure.

In a recent meta-analysis and systematic review comparing Bankart repair (open or arthroscopic) with the Latarjet procedure (open technique only), An et al<sup>2</sup> analyzed 795 shoulders (416 Bankart repairs and 379 Latarjet procedures) in 8 studies. They found significantly lower overall recurrent instability rates following the Latarjet procedure compared with Bankart repair, with no differences in complication rates between the 2 procedures. Complications following the Latarjet procedure included infections (0.5%), hardware complications (2.6%), fracture (1.6%), and hematoma (0.3%). Unfortunately, minor complications not requiring surgery were not described in this analysis, making it difficult to compare their findings with those in our study.

In a separate systematic review analyzing complication rates and reoperation rates after the Latarjet procedure, Griesser et al<sup>11</sup> reported on 45 studies comprising 1904 shoulders undergoing the original or modified Bristow or Latarjet procedure. Of the Latarjet procedures, 90.7% were open while 9.3% were arthroscopic. The authors reported an overall complication rate of 30%, an overall recurrent dislocation rate of 3%, and an overall recurrent subluxation rate of 6%. Complications included 23 neurovascular injuries (1.2%, including 6 axillary artery, 11 musculocutaneous nerve, and 6 axillary nerve injuries), 25 infections (1.3%, including 17 superficial and 8 deep), 10 hematomas requiring drainage (0.5%), 12 subscapularis muscle ruptures (0.6%), 28 coracoid fractures (1.5%), 60 cases of postoperative coracoid lysis (4.7%), and 174 coracoid nonunions or fibrous unions (9.1%). The authors did not specify the rates of complications in primary versus revision Latarjet procedures, however, making comparison with our study challenging.

Overall, while the ways in which complications following the Latarjet procedure are variably reported in the literature, there does seem to be a trend for an increased incidence of complications in cohorts including higher proportions of revision Latarjet procedures. Our cohort included 92 patients (69%) who underwent an average of  $1.19 \pm 0.69$  ipsilateral shoulder surgical procedures prior to undergoing the Latarjet procedure, with a relatively low short-term overall complication rate of 7.5%.

## Limitations

This study is limited by its short-term follow-up and retrospective nature. While our overall follow-up compliance rate

was relatively high, at 92%, 11 patients were lost to follow-up, and if any of them experienced a complication within the first 90 days after surgery, our complication rate may be artificially low. In addition, clinical outcomes were not assessed for this 90-day study; however, ongoing analysis of this cohort at a minimum follow-up period of 2 years is currently under way.

## Conclusions

The overall 90-day complication rate following the Latarjet procedure for anterior shoulder stabilization was 7.5%, substantially lower than the previously described rate of 25%. In 6 of the 10 cases, complications led to subsequent surgery, including 2 conversions to arthroplasty, while in the remaining 4 cases, the complications were transient and resolved with nonoperative treatment. This information can be used to counsel patients on the risks of early complications following the Latarjet procedure.

## Disclaimer

The authors, their immediate families, and any research foundations with which they are affiliated have not received any financial payments or other benefits from any commercial entity related to the subject of this article.

## References

- Allain J, Goutallier D, Glorion C. Long-term results of the Latarjet procedure for the treatment of anterior instability of the shoulder. *J Bone Joint Surg Am* 1998;80:841-52.
- An VVG, Sivakumar BS, Phan K, Trantalis J. A systematic review and meta-analysis of clinical and patient-reported outcomes following two procedures for recurrent traumatic anterior instability of the shoulder: Latarjet procedure vs. Bankart repair. *J Shoulder Elbow Surg* 2016;25:853-63. <http://dx.doi.org/10.1016/j.jse.2015.11.001>
- Athwal GS, Meislin R, Getz C, Weinstein D, Favorito P. Short-term complications of the arthroscopic Latarjet procedure: a North American experience. *Arthroscopy* 2016;32:1965-70. <http://dx.doi.org/10.1016/j.arthro.2016.02.022>
- Bhatia S, Frank RM, Ghodadra NS, Hsu AR, Romeo AA, Bach BR Jr, et al. The outcomes and surgical techniques of the Latarjet procedure. *Arthroscopy* 2014;30:227-35. <http://dx.doi.org/10.1016/j.arthro.2013.10.013>
- Burkhart SS, De Beer JF, Barth JR, Cresswell T, Roberts C, Richards DP. Results of modified Latarjet reconstruction in patients with anteroinferior instability and significant bone loss. *Arthroscopy* 2007;23:1033-41. <http://dx.doi.org/10.1016/j.arthro.2007.08.009>
- Butt U, Charalambous CP. Complications associated with open coracoid transfer procedures for shoulder instability. *J Shoulder Elbow Surg* 2012;21:1110-9. <http://dx.doi.org/10.1016/j.jse.2012.02.008>
- Degen RM, Camp CL, Werner BC, Dines DM, Dines JS. Trends in bone-block augmentation among recently trained orthopaedic surgeons treating anterior shoulder instability. *J Bone Joint Surg Am* 2016;98:e56. <http://dx.doi.org/10.2106/JBJS.15.01478>
- Delaney RA, Freehill MT, Janfaza DR, Vlassakov KV, Higgins LD, Warner JJ. 2014 Neer Award Paper: neuromonitoring the Latarjet procedure. *J Shoulder Elbow Surg* 2014;23:1473-80. <http://dx.doi.org/10.1016/j.jse.2014.04.003>
- Frank RM, Rosas S, Law TY, Weber A, Provencher MT, Verma NN, et al. Trends in the national utilization of Latarjet versus Bankart repair: analysis of 26,573 patients. Paper presented at: 2016 American Academy of Orthopaedic Surgeons Annual Meeting, March 1-5, 2016; Orlando, FL.
- Gartsman GM, Waggenspack WN Jr, O'Connor DP, Elkousy HA, Edwards TB. Immediate and early complications of the open Latarjet procedure: a retrospective review of a large consecutive case series. *J Shoulder Elbow Surg* 2017;26:68-72. <http://dx.doi.org/10.1016/j.jse.2016.05.029>
- Griesser MJ, Harris JD, McCoy BW, Hussain WM, Jones MH, Bishop JY, et al. Complications and re-operations after Bristow-Latarjet shoulder stabilization: a systematic review. *J Shoulder Elbow Surg* 2013;22:286-92. <http://dx.doi.org/10.1016/j.jse.2012.09.009>
- Gupta A, Delaney R, Petkin K, Lafosse L. Complications of the Latarjet procedure. *Curr Rev Musculoskelet Med* 2015;8:59-66. <http://dx.doi.org/10.1007/s12178-015-9258-y>
- Hovelius L, Sandström B, Saebö M. One hundred eighteen Bristow-Latarjet repairs for recurrent anterior dislocation of the shoulder prospectively followed for fifteen years: study II—the evolution of dislocation arthropathy. *J Shoulder Elbow Surg* 2006;15:279-89. <http://dx.doi.org/10.1016/j.jse.2005.09.014>
- Hovelius L, Sandström B, Sundgren K, Saebö M. One hundred eighteen Bristow-Latarjet repairs for recurrent anterior dislocation of the shoulder prospectively followed for fifteen years: study I—clinical results. *J Shoulder Elbow Surg* 2004;13:509-16. <http://dx.doi.org/10.1016/j.jse.2004.02.013>
- Hovelius L, Vikersfors O, Olofsson A, Svensson O, Rahme H. Bristow-Latarjet and Bankart: a comparative study of shoulder stabilization in 185 shoulders during a seventeen-year follow-up. *J Shoulder Elbow Surg* 2011;20:1095-101. <http://dx.doi.org/10.1016/j.jse.2011.02.005>
- Lafosse L, Boyle S. Arthroscopic Latarjet procedure. *J Shoulder Elbow Surg* 2010;19:2-12. <http://dx.doi.org/10.1016/j.jse.2009.12.010>
- Schmid SL, Farshad M, Catanzaro S, Gerber C. The Latarjet procedure for the treatment of recurrence of anterior instability of the shoulder after operative repair: a retrospective case series of forty-nine consecutive patients. *J Bone Joint Surg Am* 2012;94:e75. <http://dx.doi.org/10.2106/JBJS.K.00380>
- Shah AA, Butler RB, Romanowski J, Goel D, Karadagli D, Warner JJP. Short-term complications of the Latarjet procedure. *J Bone Joint Surg Am* 2012;94:495-501. <http://dx.doi.org/10.2106/JBJS.J.01830>
- Zimmermann SM, Scheyerer MJ, Farshad M, Catanzaro S, Rahm S, Gerber C. Long-term restoration of anterior shoulder stability: a retrospective analysis of arthroscopic Bankart repair versus open Latarjet procedure. *J Bone Joint Surg Am* 2016;98:1954-61. <http://dx.doi.org/10.2106/JBJS.15.01398>