

# Arthroscopic Management of Shoulder Stiffness

GARY M. GARTSMAN

## ARTHROSCOPIC MANAGEMENT OF SHOULDER STIFFNESS IN A NUTSHELL

### History:

Possibly prior trauma, diabetes, or thyroid dysfunction; painful limited range of motion

### Physical Examination:

Reduction in passive and active glenohumeral motion; scapulothoracic substitution of motion

### Imaging:

Standard radiographs; magnetic resonance imaging as needed

### Indications:

Pain and stiffness despite 6 months of nonoperative treatment

### Contraindications:

Postoperative and post-traumatic stiffness, which may require open release; malunited fractures associated with stiffness; patients in the inflammatory or contracting phase of idiopathic adhesive capsulitis

### Surgical Technique:

Interscalene block, examination under anesthesia, gentle manipulation; joint entry at superior margin of glenoid, rotator interval release, anterior capsule release, subscapularis delineation, subacromial bursectomy (if needed)

### Postoperative Management:

Intra-articular hydrocortisone, subacromial hydrocortisone, steroid dose pack, pillow (not sling) under axilla, continuous passive motion for 2 weeks, physical therapy

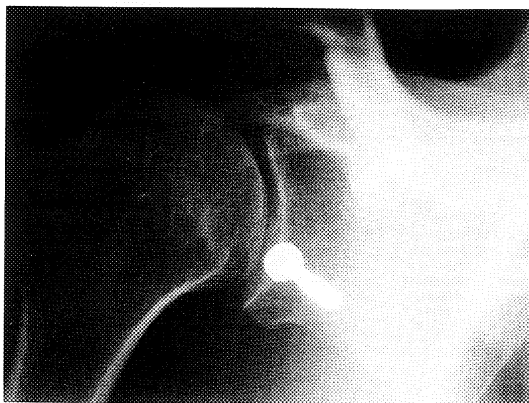
### Results:

Reduced pain and increased motion and strength in the majority of patients

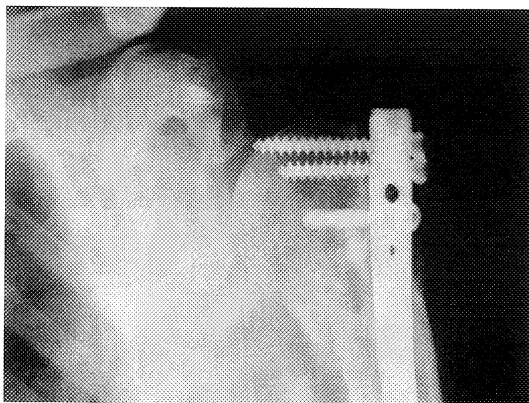
There are four basic conditions that produce shoulder stiffness and are amenable to arthroscopic treatment: idiopathic adhesive capsulitis, the diabetic stiff shoulder, post-traumatic stiffness, and postoperative stiffness.<sup>1,5,6,10</sup> Idiopathic adhesive capsulitis is widely believed to be a painful but self-limited condition that resolves after 1 to 2 years.<sup>1</sup> Reports suggest that although many patients improve, they have significant limitations of movement

and function. Additionally, many patients suffering from disabling pain are unwilling to wait for their condition to resolve and inquire about operative treatment.

Shoulder stiffness in patients with diabetes seems to cause greater pain and is more refractory to nonoperative treatment than is idiopathic stiffness.<sup>5,6</sup> The impairment from post-traumatic stiffness is related directly to the severity of the trauma. Postoperative stiffness can be



**Figure 26-1** Postsurgical stiffness after a Bristow procedure. (From Gartsman GM: *Shoulder Arthroscopy*. Philadelphia, WB Saunders, 2003, p 144.)



**Figure 26-2** Post-traumatic and postsurgical stiffness after open reduction and internal fixation. (From Gartsman GM: *Shoulder Arthroscopy*. Philadelphia, WB Saunders, 2003, p 144.)

the result of excessive scarring in the area of surgical treatment (subacromial adhesions after rotator cuff repair, anterior glenohumeral capsular contracture after a Bankart procedure),<sup>10</sup> but profound glenohumeral joint contractures can occur after surgical treatment that does not violate the capsule (Figs. 26-1 and 26-2).<sup>8</sup>

Arthroscopy is advantageous in that it enables the surgeon to release intra-articular, subacromial, and subdeltoid adhesions without dividing the subscapularis.<sup>2,4</sup> Postoperatively, active range of motion can be started immediately without concern for tendon dehiscence.

### History

A thorough history that ascertains prior trauma or shoulder difficulties is important. Patients should be queried about diabetes and thyroid dysfunction. Most patients either recall a trivial antecedent injury or cannot recall

an inciting event. Patients with all types of adhesive capsulitis present with painful, limited shoulder motion.<sup>9</sup> Pain at night interferes with sleep, and routine activities of daily living that require reaching overhead or behind the back are difficult and painful. Rapid movements in particular may cause severe pain. Patients demonstrate restricted passive and active motion, such that the motion is usually less than 50% that of the contralateral shoulder.

### Physical Examination

Passive range of motion in elevation, abduction, and external rotation (in adduction with the patient's arm at the side and in maximum allowable abduction) is recorded. Internal rotation is measured at the vertebral level to which the patient can reach with the extended thumb. Behind-the-back internal rotation is usually decreased; occasionally, however, it may be close to normal because internal rotation measured in this manner includes not only glenohumeral movement but also scapulothoracic motion. With prolonged shoulder stiffness, scapulothoracic motion may be increased to compensate for the loss of glenohumeral rotation. For this reason, stabilizing the scapula with one hand while the arm is maximally abducted to eliminate scapulothoracic motion during external and internal rotation provides a more accurate measure of glenohumeral rotation. Muscle strength in elevation and external rotation is also assessed.

### Imaging

Radiographs are typically normal, but mild osteopenia from disuse may be present. Standard anteroposterior, axillary, and supraspinatus (scapular) outlet radiographs are obtained. Magnetic resonance imaging is helpful when rotator cuff or labral pathology is suspected.

### Differential Diagnosis

Numerous other shoulder conditions produce painful limited motion, but these are eliminated by patient history, physical examination, and radiographic evaluation. Patients with rotator cuff tears present with passive motion greater than active motion, weakness evident on manual muscle testing, and abnormal magnetic resonance imaging scans or arthrograms. Patients with osteoarthritis have plain radiographs depicting loss of glenohumeral joint space (Fig. 26-3). Patients with post-traumatic stiffness may have malunited fractures, and those with postoperative stiffness may have internal fixation interfering with motion.

### Indications and Contraindications

Surgical intervention is considered if the patient has persistent pain and stiffness after 6 months of appropriate

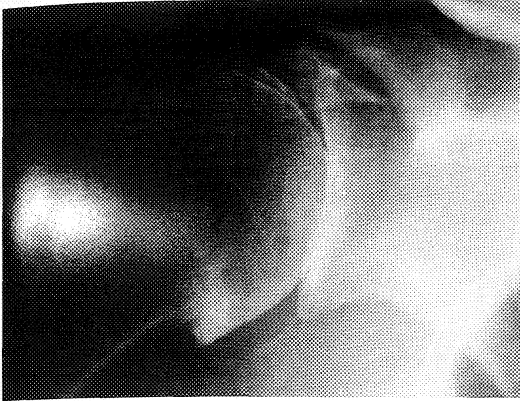

Figure 26-3 Osteoarthrosis. (From Gartsman GM: Shoulder Arthroscopy. Philadelphia, WB Saunders, 2003, p 144.)

nonoperative care. Severe stiffness is defined as 0 degrees of external rotation and less than 30 degrees of abduction. Moderate stiffness is defined as a decrease of 30 degrees in either plane compared with the contralateral shoulder. Although loss of internal rotation is clinically significant to the patient, by itself, it is not considered an indication for arthroscopic release. One exception is the throwing athlete. In these patients, posterior contracture and decreased internal rotation may be the only problems, and these patients may be candidates for arthroscopic release while addressing all intra-articular pathology. If stiffness persists at 6 months but pain has diminished, nonoperative care is continued for an additional 2 months, with the hope that the decrease in pain indicates that the stiffness is about to resolve, or “thaw,” spontaneously. If there is no improvement in the range of motion 2 months later, surgery is considered. If at 4 to 6 months after the start of nonoperative treatment external rotation remains at neutral or worse, operative intervention is recommended, because a response to further nonoperative care is unlikely.

Contraindications for arthroscopic treatment exist mainly in patients with postoperative and post-traumatic stiffness. Patients who have had surgical procedures for instability with subscapularis takedown or shortening may develop profound soft tissue contractures. The contracture in these patients is typically extra-articular between the subscapularis and the conjoined tendon. Open release is often necessary, in addition to arthroscopic glenohumeral joint release. Patients with mildly malunited greater tuberosity or proximal humerus fractures can be treated arthroscopically, but patients with badly malunited fractures or internal fixation require open release, removal of hardware, and fracture osteotomy, as indicated. Patients in the inflammatory or contracting phase of idiopathic adhesive capsulitis should not undergo surgery, because the procedure may accelerate the contracture.

## Surgical Technique

### Examination under Anesthesia

After induction of anesthesia, both shoulders are examined for range of motion in elevation, abduction, and external rotation in adduction. The affected shoulder is placed in maximal abduction, and internal and external rotation are measured.

### Manipulation

Before arthroscopic treatment, gentle closed manipulation is performed. It is difficult to quantify the term *gentle*, but only a small amount of force is applied to the shoulder in abduction and then in elevation. If the shoulder responds to closed manipulation, it will move with minimal force. If motion improves with abduction and elevation, the arm is placed in external rotation. This is performed with the shoulder in maximal abduction and then in adduction. If motion continues to improve, internal rotation stretching begins by internally rotating the shoulder in maximal abduction. If motion improves, the shoulder is stretched in cross-body adduction and finally in behind-the-back internal rotation. If the shoulder does not respond to abduction and elevation, no additional attempts at external or internal rotation are made, owing to torsional stresses associated with excessive external and internal rotation. In this scenario, proceeding directly to arthroscopy is indicated. If the shoulder responds to manipulation but full movement is not achieved, arthroscopy and release of the remaining adhesions are indicated. If full range of motion is obtained after manipulation, the arthroscope is inserted to confirm that the capsule is released completely. Some shoulders with full range of motion after manipulation have persistent capsular contracture because the manipulation may be releasing only extra-articular adhesions.

### Specific Surgical Steps

#### Joint Entry

Entry into the stiff shoulder is always difficult because, by definition, the joint volume is reduced. Forceful entry may damage the articular surfaces. The tight, thickened posterior capsule makes spinal needle entry difficult, and the generalized capsular stiffness limits the amount of fluid that can be injected. A standard metal cannula and a rounded trocar may be helpful, as they are larger and stiffer than the spinal needle, and palpation of the posterior glenohumeral joint is easier.

The entry position is critical. Joint entry through the traditional “soft spot” (located at the level of the glenoid equator) increases the risk of cartilage surface damage. At this level, the glenohumeral joint space is narrowest, making trocar entry difficult. Entering the joint superiorly relative to the glenoid, the rotator cuff, and the humeral head is safer and easier, because the joint is

widest in that location (Fig. 26-4). The skin is incised, and the cannula and trocar are inserted until bone is palpated. The shoulder is internally and externally rotated to determine whether the trocar tip rests on the humeral head (movement detected) or the glenoid (no movement). Lowering the hand holding the trocar elevates the trocar tip in an effort to palpate the superior glenoid rim. At this point, joint entry is attempted (Fig. 26-5).

Once the arthroscope is in the glenohumeral joint, it is directed at the rotator interval. Percutaneous placement of a spinal needle positioned lateral to the coracoid process is performed to target the entrance point for a 5-mm cannula and trocar.

#### Rotator Interval Release

The first step in the operation is to release the rotator interval (Figs. 26-6 and 26-7). This can be accomplished with a motorized soft tissue resector. The resector is inserted through the cannula into the joint; then the cannula is backed out of the joint, leaving the resector tip in the rotator interval. Soft tissue is excised from an area bounded by the biceps tendon medially, the superior border of the subscapularis tendon inferiorly, and the humeral head laterally. Before removing the resector, the cannula is reintroduced into the joint. The arthroscope is withdrawn from the posterior cannula, leaving an indwelling cannula. A closed manipulation is attempted, as described earlier. If full range of motion is obtained, the arthroscope is reintroduced posteriorly to verify that the capsule is divided and that the humeral head is properly located. If full range of motion is not achieved, or if motion has improved but the capsule is not completely divided, the anterior capsule is released.

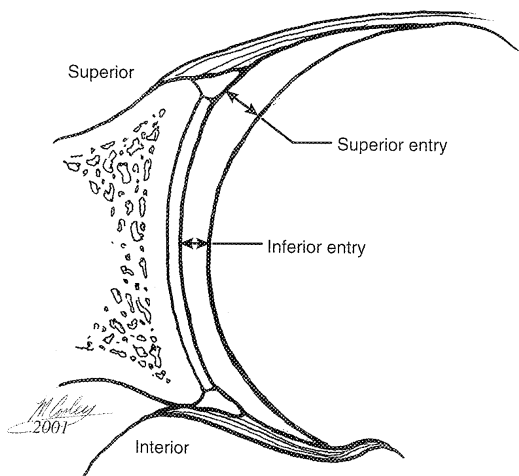


Figure 26-4 Location of joint entry. (From Gartsman GM: *Shoulder Arthroscopy*. Philadelphia, WB Saunders, 2003, p 146.)

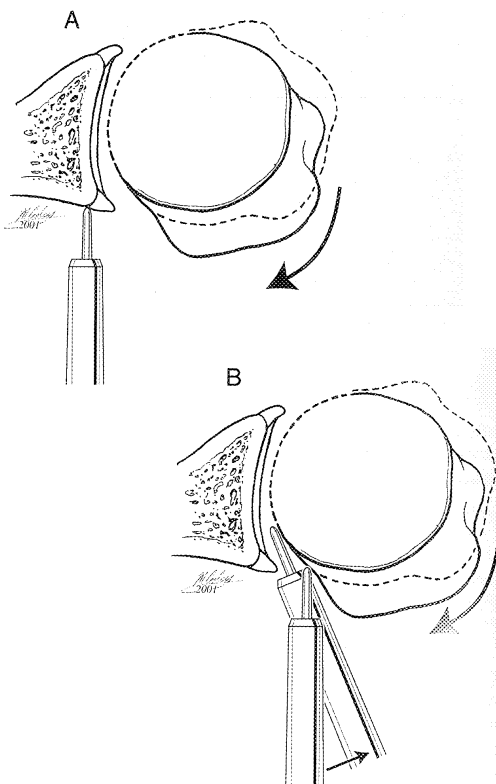


Figure 26-5 Palpate bone to determine the entry point. A, Palpate the glenoid. The trocar is too medial. B, Move the trocar laterally to enter the joint. (From Gartsman GM: *Shoulder Arthroscopy*. Philadelphia, WB Saunders, 2003, p 146.)

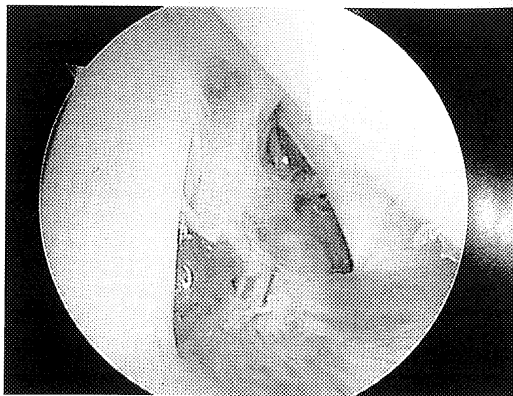
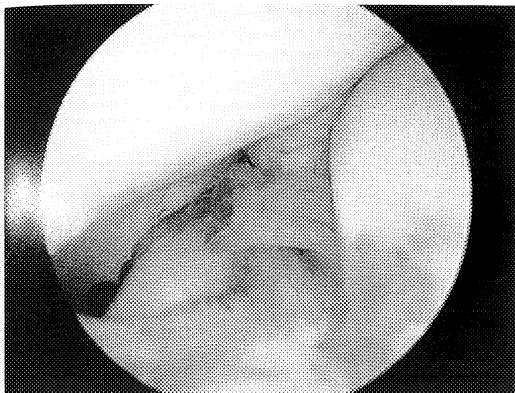
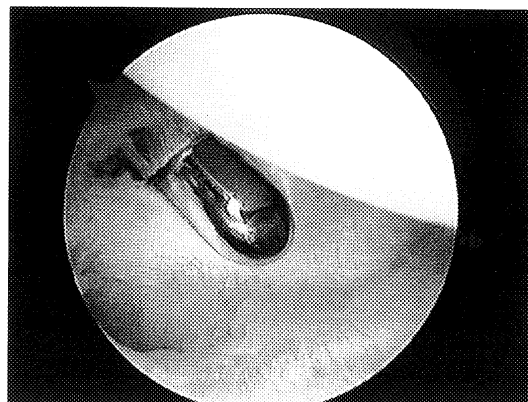


Figure 26-6 Contracted rotator interval. (From Gartsman GM: *Shoulder Arthroscopy*. Philadelphia, WB Saunders, 2003, p 146.)



**Figure 26-7** Synovitis in the rotator interval. (From Gartsman GM: *Shoulder Arthroscopy*. Philadelphia, WB Saunders, 2003, p 146.)

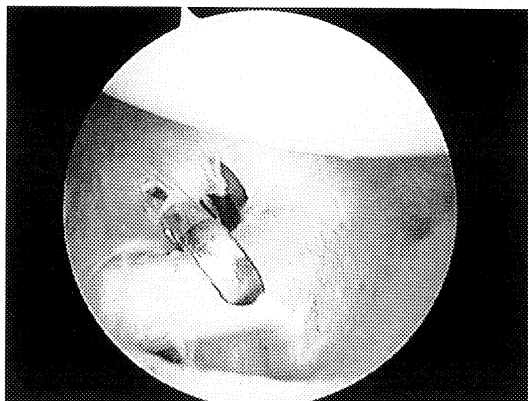


**Figure 26-9** Identify the superior portion of the middle glenohumeral ligament. (From Gartsman GM: *Shoulder Arthroscopy*. Philadelphia, WB Saunders, 2003, p 147.)

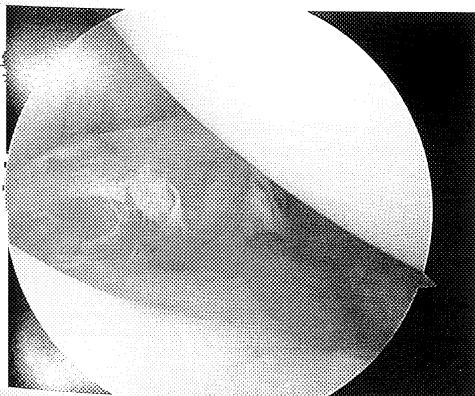### Anterior Capsule Release

The point where the middle glenohumeral ligament crosses the subscapularis tendon is identified (Fig. 26-8). It is important to separate the subscapularis tendon from the middle glenohumeral ligament, which is facilitated by an electrocautery device. It is helpful to divide fibers of the middle glenohumeral ligament gradually until the tendinous portion of the superior subscapularis is visualized. A blunt dissector is inserted anterior to the middle glenohumeral ligament to separate the two structures. A *Harveman* soft tissue punch (Smith and Nephew Endoscopy, Andover, MA) is helpful to remove a 5- to 10-mm strip of anterior capsule. This includes the middle glenohumeral ligament and the superior portion of the anteroinferior glenohumeral ligament. Alternatively, electrocautery may be used for this portion of the procedure (Figs. 26-9 to 26-16).

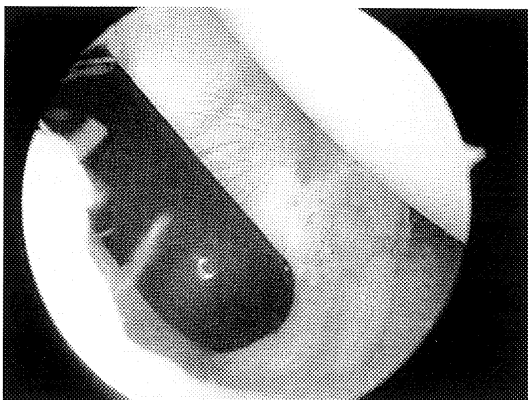
Usually, a small amount of increased lateral humeral head displacement results after these steps, allowing the



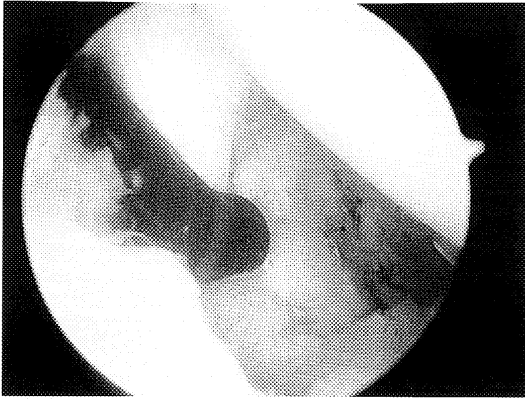
**Figure 26-10** Divide the superior portion of the middle glenohumeral ligament. (From Gartsman GM: *Shoulder Arthroscopy*. Philadelphia, WB Saunders, 2003, p 147.)



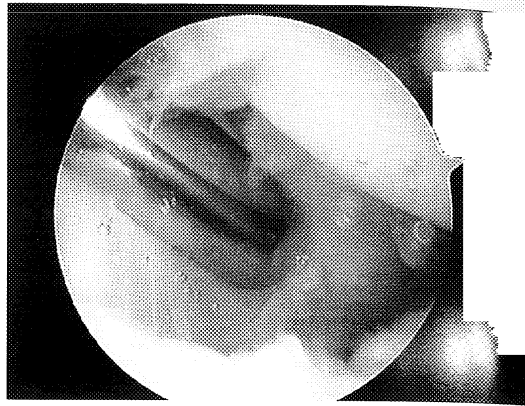
**Figure 26-8** Contracted anterior capsule. (From Gartsman GM: *Shoulder Arthroscopy*. Philadelphia, WB Saunders, 2003, p 147.)



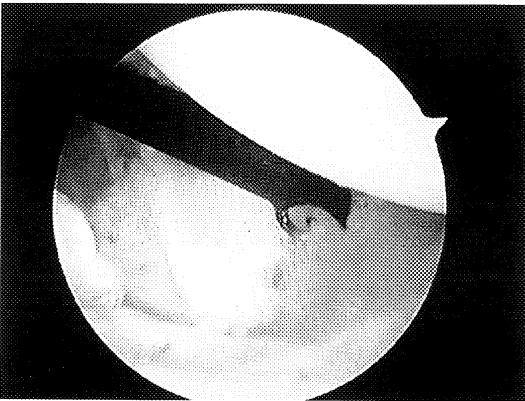
**Figure 26-11** Apply cautery to the middle glenohumeral ligament covering the subscapularis. (From Gartsman GM: *Shoulder Arthroscopy*. Philadelphia, WB Saunders, 2003, p 147.)



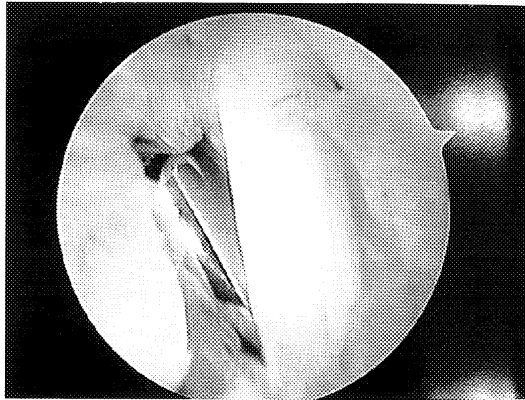
**Figure 26-12** Apply cautery to the middle glenohumeral ligament covering the subscapularis. (From Gartsman GM: Shoulder Arthroscopy. Philadelphia, WB Saunders, 2003, p 148.)



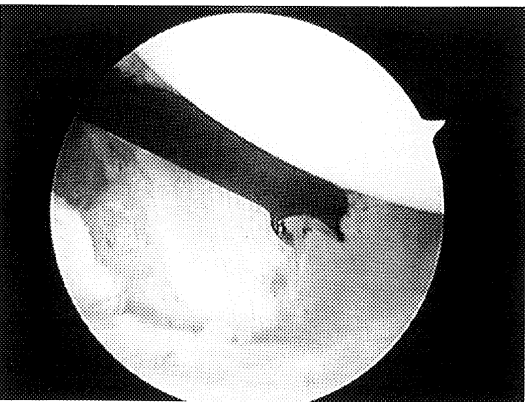
**Figure 26-15** Use a blunt dissector anterior to the subscapularis. (From Gartsman GM: Shoulder Arthroscopy. Philadelphia, WB Saunders, 2003, p 148.)



**Figure 26-13** Apply cautery to the middle glenohumeral ligament covering the subscapularis. (From Gartsman GM: Shoulder Arthroscopy. Philadelphia, WB Saunders, 2003, p 148.)



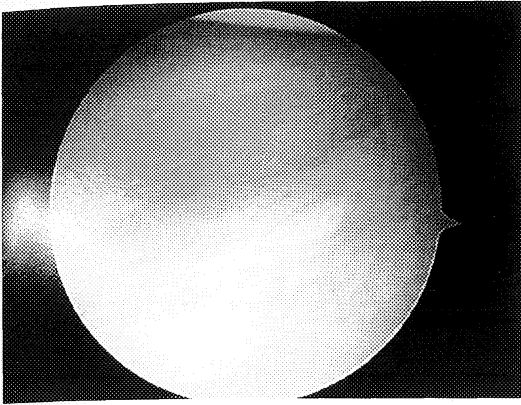
**Figure 26-16** Use a blunt dissector posterior to the subscapularis. (From Gartsman GM: Shoulder Arthroscopy. Philadelphia, WB Saunders, 2003, p 148.)



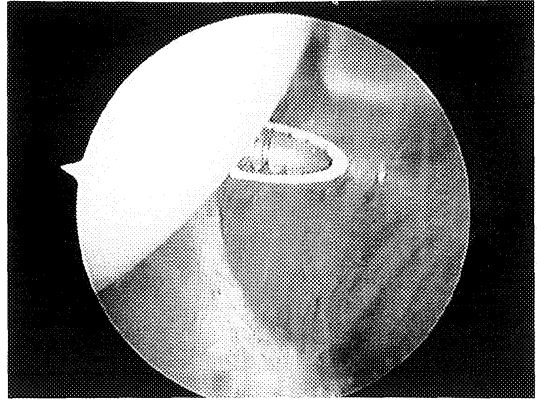
**Figure 26-14** Apply cautery to the middle glenohumeral ligament covering the subscapularis. (From Gartsman GM: Shoulder Arthroscopy. Philadelphia, WB Saunders, 2003, p 148.)

arthroscope to be advanced anteriorly and inferiorly to more clearly visualize the posterior portion of the anteroinferior glenohumeral ligament and the inferior capsule. The bottom, blunt jaw of the punch is placed exterior to the capsule to divide it from anterior to posterior as far from the glenoid labrum as possible (Figs. 26-17 and 26-18). The extent of this release depends on the amount of axillary pouch contraction, which may limit the degree of advancement of the punch without applying excessive distraction to the glenohumeral joint. This is usually about the 5-o'clock position for a right shoulder. To gain access to and release the axillary pouch safely, the posterior and inferoposterior areas of the capsule are treated next.

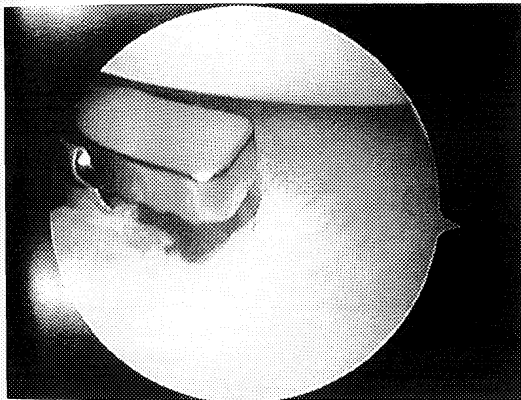
The soft tissue punch and cannula are removed from the anterior portal and exchanged for a metal cannula and trocar. The arthroscope is removed from the posterior portal and inserted anteriorly. Under direct vision,



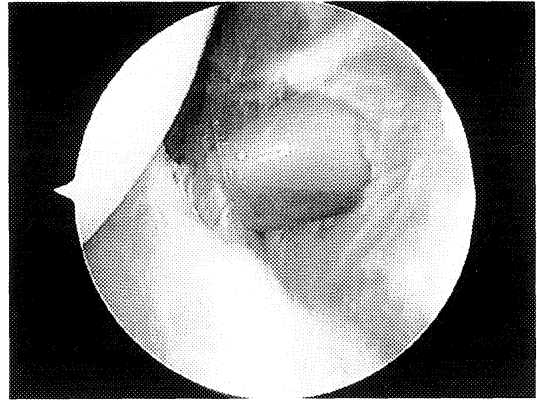
**Figure 26-17 Contracted inferior capsule.** (From Gartsman GM: Shoulder Arthroscopy. Philadelphia, WB Saunders, 2003, p 148.)



**Figure 26-18 A shaver is used to resect the posterior capsule.** (From Gartsman GM: Shoulder Arthroscopy. Philadelphia, WB Saunders, 2003, p 149.)



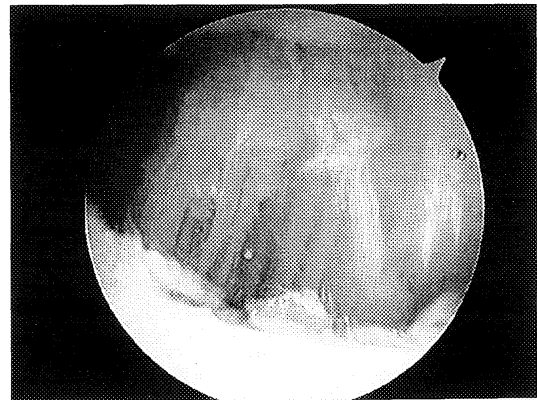
**Figure 26-19 Capsular punch in the anteroinferior capsule.** (From Gartsman GM: Shoulder Arthroscopy. Philadelphia, WB Saunders, 2003, p 149.)



**Figure 26-20 Insert a large cannula posteriorly.** (From Gartsman GM: Shoulder Arthroscopy. Philadelphia, WB Saunders, 2003, p 149.)

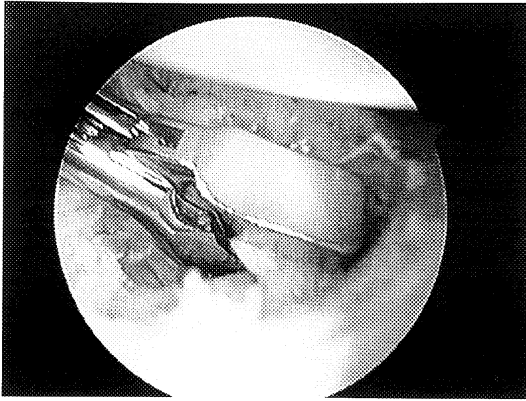
the small plastic cannula and trocar are placed posteriorly. The glenohumeral joint is usually too tightly contracted to allow insertion of a larger diameter cannula. A motorized shaver is used to resect 5 to 10 mm of posterior capsule, beginning superiorly and moving inferiorly (Fig. 26-19). Once the posterior capsule has been resected, a large-diameter cannula is inserted that will accommodate the capsular resection punch (Figs. 26-20 and 26-21).

The punch is used to resect a 10-mm strip of the posteroinferior capsule beginning 5 to 10 mm from the glenoid labrum to avoid any labral damage. The last step in the intra-articular portion of the procedure is complete release of the inferior capsule. Often, surgical division is not necessary because the last portion of the capsule can be released through manipulation, which avoids placing instruments near the axillary nerve.

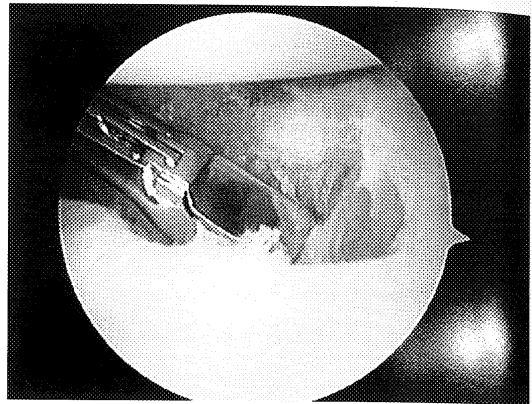


**Figure 26-21 Complete the posterior capsular resection with a punch.** (From Gartsman GM: Shoulder Arthroscopy. Philadelphia, WB Saunders, 2003, p 149.)

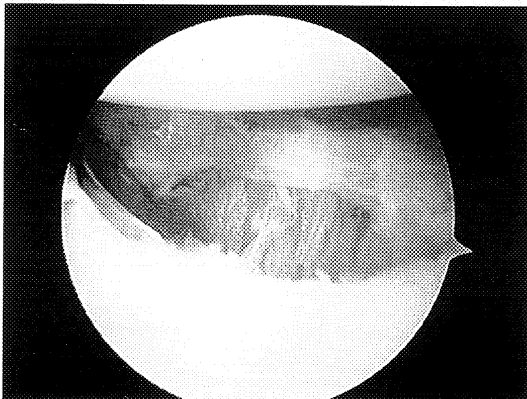




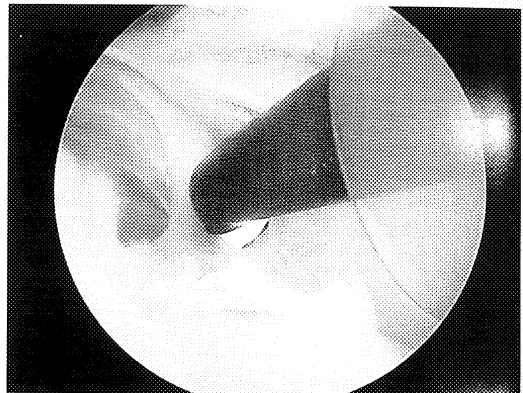
**Figure 26-22** Return the arthroscope to the posterior portal and complete the inferior capsular resection. (From Gartsman GM: *Shoulder Arthroscopy*. Philadelphia, WB Saunders, 2003, p 150.)



**Figure 26-24** Inferior capsular resection. (From Gartsman GM: *Shoulder Arthroscopy*. Philadelphia, WB Saunders, 2003, p 150.)



**Figure 26-23** Inferior capsular resection. (From Gartsman GM: *Shoulder Arthroscopy*. Philadelphia, WB Saunders, 2003, p 150.)



**Figure 26-25** Remove subacromial adhesions, if present. (From Gartsman GM: *Shoulder Arthroscopy*. Philadelphia, WB Saunders, 2003, p 150.)

Following manipulation, the arthroscope is inserted to inspect the gap between the resected edges of the capsule and to confirm that the humeral head is normally located. If full range of motion is not obtained with manipulation, the arthroscope is inserted posteriorly and the cannula and punch anteriorly, and the inferior capsule is resected (Figs. 26–22 to 26–24).

#### Subscapularis Delineation

A blunt dissector is used to release any adhesions anterior and posterior to the subscapularis. To achieve full passive range of motion, it is generally safe to resect the superior tendinous border of the subscapularis.

#### Subacromial Bursectomy

The arthroscope is introduced into the subacromial space. If the subacromial space is not clearly seen, a

motorized soft tissue resector is used to remove bursa and adhesions (Fig. 26–25).

An acromioplasty is not performed even if there is arthroscopic evidence of impingement, such as rotator cuff or coracoacromial ligament fraying. By definition, a patient with adhesive capsulitis cannot move the shoulder into the positions consistent with the clinical diagnosis of impingement. The raw acromial bone surface produced after acromioplasty creates the opportunity for postoperative adhesions and should be avoided.

#### Postoperative Management

To reduce postoperative inflammation and adhesion formation, the following protocol is used. Following arthroscopic confirmation of shoulder stiffness resulting from capsular contracture, but before soft tissue



resection, the anesthesiologist gives the patient 100 mg of hydrocortisone intravenously. Intra-articular cortisone is not given at the conclusion of the procedure, because resection of the capsule causes the steroid to extravasate and lose its effectiveness. In patients with post-traumatic or postsurgical stiffness and with subacromial adhesions requiring release, 1 mg of hydrocortisone (Solu-Cortef) is injected into the subacromial space at the conclusion of the operation. Postoperatively, the patient is placed on a methylprednisolone (Medrol) dose pack. Steroids are not used in patients with diabetes.

A sling or immobilizer is not used. Instead, a pillow is placed under the axilla to keep the arm away from the chest, and the patient is encouraged to avoid placing the arm in internal rotation. The patient is admitted to the hospital overnight. A continuous passive motion chair is used to maintain the full range of motion gained during the surgical procedure. Continuous passive motion begins the afternoon of the operation. It is extremely helpful to visit the patient on the afternoon of the surgical procedure and to demonstrate that the patient now has full range of motion. This is easily done, because the patient's shoulder is still anesthetized from the interscalene block. This visual demonstration of full movement impresses on the patient that the operation was successful. One should emphasize to the patient that complete recovery depends on adherence to the postoperative rehabilitation program. On discharge from the hospital, the patient uses the chair four times daily for 1 hour each session. This regimen continues for 2 weeks. At that time, the patient is seen in the clinic, and if movement is satisfactory, the continuous passive motion chair is discontinued.

Passive elevation while the patient is supine and external rotation with the aid of a dowel or pulley are continued. The patient is encouraged to use the arm for all activities and motions that are comfortable. The patient is seen again at 6 weeks, 3 months, and 6 months postoperatively.

If the patient has not achieved full range of motion by 3 months, a repeat contracture release is recommended. At this point, however, usually only gentle closed manipulation is necessary.

## Results

Ogilvie-Harris, Harryman, and Warner and their colleagues have published landmark articles describing their results.<sup>2,5,7-10</sup> Arthroscopic treatment is generally successful, with the degree of improvement depending on the patient's underlying condition. Warner et al.<sup>9</sup> reported on 23 patients with idiopathic adhesive capsulitis treated with arthroscopic release. In that study, the Constant score improved an average of 48 points. Flexion improved a mean of 49 degrees, external rotation 45 degrees, and internal rotation by eight spinous processes. Harryman<sup>2,4</sup> documented improved patient satisfaction, function, and pain relief in a population of patients with diabetes, although the range-of-motion improvement was not as great as that seen in patients with idiopathic adhesive capsulitis.

## References

1. Griggs SM, Ahn A, Green A: Idiopathic adhesive capsulitis: A prospective functional outcome study of nonoperative treatment. *J Bone Joint Surg* 82:1398-1407, 2000.
2. Harryman DT II: Shoulders: Frozen and stiff. *Instr Course Lect* 42:247-257, 1993.
3. Harryman DT II: Arthroscopic management of shoulder stiffness. *Oper Tech Sports Med* 5:264-274, 1997.
4. Harryman DT II, Matsen FA III, Sidles JA: Arthroscopic management of refractory shoulder stiffness. *Arthroscopy* 13:133-147, 1997.
5. Ogilvie-Harris DJ, Myerthall S: The diabetic frozen shoulder: Arthroscopic release. *Arthroscopy* 13:1-8, 1997.
6. Scarlat MM, Harryman DT II: Management of the diabetic stiff shoulder. *Instr Course Lect* 49:283-293, 2000.
7. Warner JJP: Frozen shoulder: Diagnosis and management. *J Am Acad Orthop Surg* 5:130-140, 1997.
8. Warner JJP, Allen AA, Marks PH, Wong P: Arthroscopic release of postoperative capsular contracture of the shoulder. *J Bone Joint Surg Am* 79:1151-1158, 1997.
9. Warner JJP, Answorth A, Marks PH, Wong P: Arthroscopic release for chronic refractory adhesive capsulitis of the shoulder. *J Bone Joint Surg Am* 78:1808-1816, 1996.
10. Warner JJP, Greis PE: The treatment of stiffness of the shoulder after repair of the rotator cuff. *J Bone Joint Surg Am* 79:1260-1269, 1997.