

is the most frequently disrupted ligament of the knee and is injured 9 times more frequently than the posterior cruciate ligament (PCL). In more than 70% of patients who present with an acute traumatic hemarthrosis of the knee, the ACL is at least partially torn. Annually in the United States, more than 250,000 patients are diagnosed as having torn their ACLs. The highest rate of injury appears to be in those age 10 to 19 years old who engage in high risk sports such as football, baseball, soccer, skiing and basketball. It is estimated that more than 25% to 30% of all ski-related knee injuries involve the ACL. In college football, 42 per 1000 players are at risk per year. There is a 16% chance of injuring the ACL over a typical 4-year college career, which is 100 times the risk of the general population. Associated injuries are common, with the classic triad described by O'Donoghue (1955, ACL-MCL-medial meniscus) being less common than a ACL-MCL-lateral meniscus triad.

Basic Science

Biomechanics

Kinematics

The ACL is the primary restraint (86%) to anteroposterior (AP) translation. It also provides restraint to internal rotation (IR), external rotation (ER), and hyperextension. Secondary stabilizers to AP translation include the MCL and medial meniscus. The ACL and PCL regulate the "screw-home" mechanism of the knee during the final 20 degrees of extension, with the tibia externally rotating on the femur 15 degrees at terminal extension. The ACL and PCL cross at the instant center of rotation, which moves posteriorly during flexion. A combination of rolling and gliding occurs at the articular surface during knee flexion. Ligament stress is greatest at 0 to 45 degrees, and translation is greatest at 20 to 30 degrees.

Strength and Load

The ACL normally encounters 400 to 500 N of force during walking. Cutting and changes in acceleration can increase this to 1700 N. The ultimate tensile strength (maximum stress before failure) ranges between 1730 N (Noyes, 1984) and 2500 N (Woo, 1990). The ACL is about half as stiff and strong as the MCL.

Anatomy

Embryology

The cruciate ligaments are first recognized at 7 to 8 weeks gestation as a condensation of vascular synovial mesenchyme.

Histology

The ACL is an intracapsular but extrasynovial structure. The ACL is primarily composed of type I (90%) and III (10%) collagen with variable amounts of elastin and reticulin. As in all ligaments, the ultrastructure is composed of fibrils which form fibers, which form subfascicular units, which are arranged into fascicles, and, finally, the ligament.

ANTERIOR CRUCIATE LIGAMENT INJURIES

Ligamentous injuries to the knee account for 25 to 40% of all knee injuries. The incidence of ACL tears varies widely depending on the population studied. While sprains of the medial collateral ligament (MCL) are more common, the ACL

Functional anatomy

Fascicles of the ACL are divided into three functional groups:

1. anteromedial band (AMB): tight in flexion
2. posterolateral band (PLB): tight in extension
3. central band: functional over entire range of motion. In reality, tension develops along a continuum of fibers during ROM.

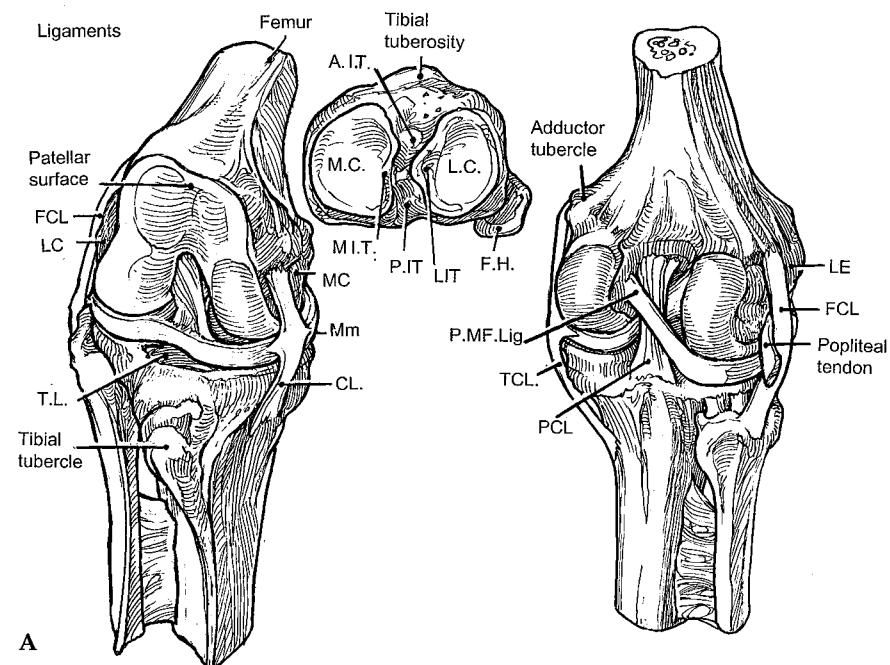
Surgical Anatomy

Origin

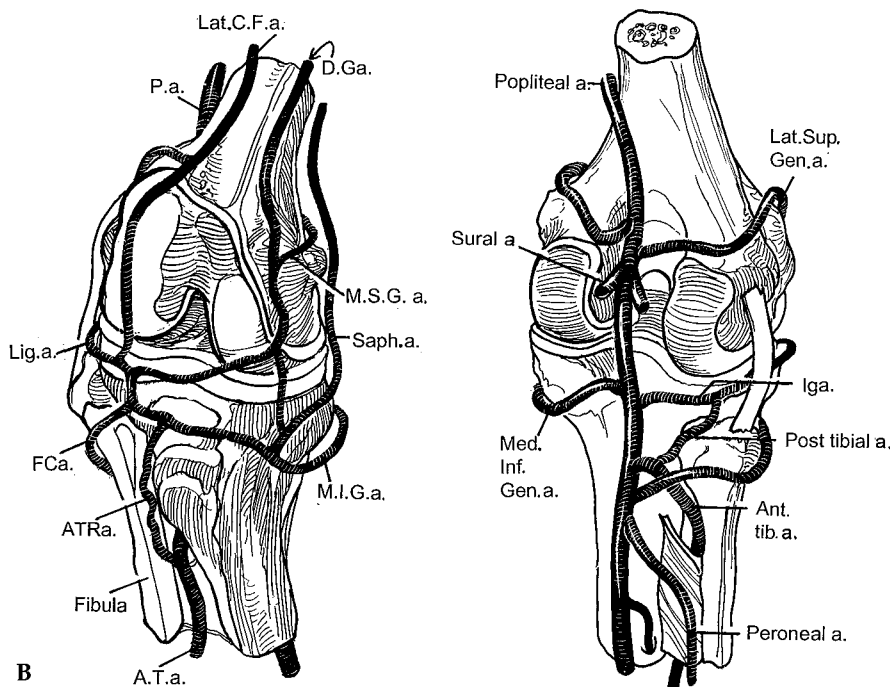
The ACL originates at the posteromedial lateral femoral condyle as a crescent averaging 23 mm in length (Fig. 35-11).

Insertion

The ACL inserts anterior to the medial tibial eminence 15 mm posterior to the anterior horn of medial meniscus as an oval



A



B

Figure 35-11 (A) Anterior view in flexion and posterior view in extension of the bones, ligaments, and menisci of the knee. (B) Vascular anatomy about the knee.

averaging 38 mm in length. The average ACL flexion length is 31 ± 3 mm, and average width is 11 mm.

Vascular supply

The ACL vascular supply is primarily from the middle geniculate via the periligamentous synovial sheath, and the medial and lateral inferior geniculate arteries via the fat pad.

Innervation

Primarily innervation is from the tibial nerve via the periligamentous vessels. Mechanoreceptors (proprioceptive) include the Ruffini end-organs, Pacinian corpuscles and free nerve endings. Reflex hamstring (HS) contraction pulling the tibia posteriorly may occur to protect the ACL during excessive load during anterior tibial translation.

Examination

History

Mechanism

This is most commonly a combination of forces at low velocity without contact during deceleration. Mechanisms include:

1. valgus/ER
2. hyperextension \pm IR
3. direct valgus load
4. hyperflexion (rare)

A pure valgus stress may only cause an isolated MCL tear. Combined ACL-MCL injuries are commonly produced by valgus/ER tearing the posterior oblique ligament (POL), ACL, and MCL, in that order.

Symptoms

Acutely, 30 to 90% of patients experience a "pop" or "snap." Other symptoms include hemarthrosis (up to 75%), inability to bear weight or return to play, instability as if the knee "comes apart," and locking due to the ACL stump or a torn meniscus (35–75% in acute and 75–98% in chronic). Not all meniscal tears, however, require treatment. Chronically, patients may complain of instability ("two fist sign"), giving

way with cutting or pivoting, and intermittent swelling or pain due to meniscal pathology and/or arthrosis.

PITFALL

Buckling or giving way is not pathognomonic for anterior cruciate ligament (ACL) deficiency. It occurs with patellofemoral (PF) instability, meniscal pathology, or painful inhibition of the quadriceps.

Physical Examination

The examination is optimally performed after the original injury, before pain and swelling develop. This is less important in the chronically ACL-deficient knee. Evaluation of the meniscus, collateral ligaments, cartilage surface, and posterolateral corner should also be undertaken, as these areas are commonly involved at the time of injury.

Inspection

Observe for effusion (may be delayed 12–24 hours), ecchymoses, antalgic gait, atrophy, and limited ROM. Combined ACL-MCL injuries may demonstrate a medial-based soft tissue swelling. Patients often demonstrate a "quadriceps avoidance" gait to reduce the risk of anterior tibial translation.

Palpation

Tenderness may exist with associated injuries (i.e., collaterals, meniscus, osteochondral injury).

Motion

Motion may be decreased due to HS spasm, meniscal pathology, effusion, ACL stump impingement, and pain.

Special Tests

Lachman Test

Acutely, this is the most sensitive test for ACL deficiency (Fig. 35–12). It is performed in 20 to 30 degrees of flexion with an anterior force applied to the proximal tibia. Assess the endpoint (i.e., soft or firm) and the amount of displacement with

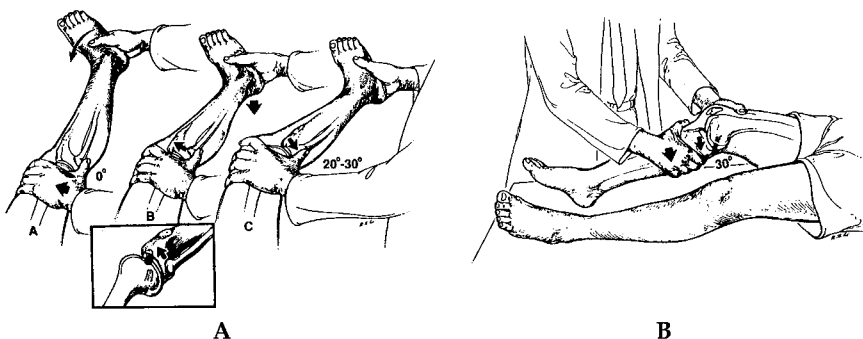


Figure 35–12 Common tests used for the diagnosis of an anterior cruciate ligament (ACL) tear. (A) The pivot shift test. Begin with the knee in full extension and internal tibial rotation with a valgus stress applied at the knee. The anteriorly subluxated tibia will reduce as the knee is flexed 20 to 30 degrees and the iliotibial band drops behind the knee's center of rotation. (B) The Lachman test. An anterior force is applied to the proximal tibia with the knee in 30 degrees of flexion. Reproduced with permission from Tria AJ, Klein KS. *An Illustrated Guide to the Knee*. New York, NY: Churchill Livingstone; 1992:50, 52.

side-to-side comparison (i.e., > 3 mm is considered pathologic). The test is graded: grade I (1–4 mm), grade II (5–10 mm), and grade III (> 10 mm). Letters further define the grade: A = solid endpoint, B = soft endpoint.

Anterior Drawer Test

A less reliable test compared to the Lachman test due to the effects of hamstring spasm, meniscal buttressing, effusion, and kinematic condylar restriction. The test is performed and graded as the Lachman test, with knee in 90 degrees of flexion.

Pivot Shift Test

This test is pathognomonic of ACL deficiency, especially when performed under anesthesia. It represents subluxation-reduction of the anterior tibia when the knee is brought from 0 to 20 to 30 degrees of flexion with the foot in slight IR, with slight valgus and axial load placed upon the knee. The posterior pull of the ITB is thought to assist in the reduction of the anteriorly subluxated tibia as it passes behind the knee's center of rotation with flexion. The test is graded: 0 (absent), 1+ (glide), 2+ (jump), and 3+ (transient locking). Sensitivity is improved with hip abduction and ER of the tibia. False negatives occur with displaced menisci or MCL deficiency.

Collateral Ligament Evaluation

Medial collateral ligament/lateral collateral ligament insertional tenderness may exist, accurately pointing to the site of injury. During collateral ligament evaluation (Fig. 35–13) the lateral collateral ligament (LCL) can be felt as a distinct band with the leg in a figure-four position. Additionally, stress testing can be performed and graded as in the Lachman test.

Abduction Stress Test

The abduction stress test is performed at full extension and 30 degrees of flexion. A gradual abduction stress is applied to the leg of the supine patient while the lateral knee is supported with one of the examiner's hands. The ankle is grasped with the other hand while applying a gentle valgus

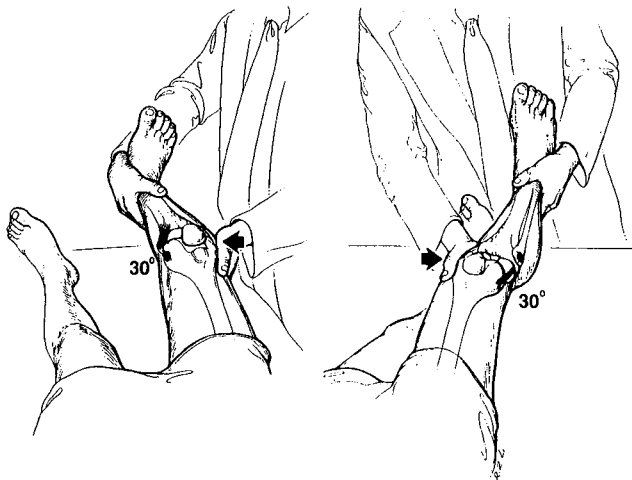


Figure 35–13 Valgus (B) and varus (B) stress testing in 30 degrees of flexion to test the medial collateral ligament and lateral collateral ligament, respectively. Reproduced with permission from Tria AJ, Klein KS. *An Illustrated Guide to the Knee*. New York, NY: Churchill Livingstone; 1992: 49, 50.

stress. The thigh can simply rest on the table surface, or the examiner can support the thigh to better palpate the joint line.

Adduction Stress Test

This test is similar to the abduction stress test, except the examiner places the hand on the medial knee to resist a varus stress applied at the ankle.

Interpretation

Isolated tears of the MCL or LCL are associated with valgus or varus laxity at 30 degrees. An opening at both 30 degrees and 0 degrees implies additional injury. Significant valgus laxity at 0 degrees implies injury to the posteromedial capsule (including the POL) and possibly injury to the PCL and or ACL. Mild (< 5 degrees) varus laxity at 0 degrees and 30 degrees can represent isolated LCL injury; but with grade 2+ to 3+ opening, posterolateral capsule and/or concomitant PCL injury may exist.

External Rotation Test

The anterior drawer test can be performed with the foot in 30 degrees IR to tighten lateral structures and 15 degrees ER to tighten medial structures. Anterior subluxation of the medial tibia in the ER position may indicate MCL and possibly ACL injury.

Instrumented Laxity Testing

Various devices such as the KT-1000/2000 (MED-metric; San Diego, CA) objectively measure pre- and postoperative side-to-side differences in knee laxity while simulating a Lachman test. Maximal manual translation greater than 10 mm, maximal manual side-to-side difference greater than 3 mm, or a compliance index greater than 2 mm is highly suggestive of ACL deficiency.

Aids to Diagnosis

Radiographic Evaluation

Complete radiographic evaluation is discussed above in Anterior Knee Pain and Patellofemoral Disorders. Specific findings related to the ACL are emphasized in this section. In general, an AP, lateral, axial and 45 degree PA flexion weight-bearing radiograph should be obtained.

Standard Anteroposterior View

Use an extension weight-bearing view. Evaluate for soft tissue abnormalities, joint space narrowing, and overall alignment. Second fracture (lateral tibial capsular avulsion in up to 7% of ACL injuries) may occur secondary to IR with AP translation (Fig. 35–14). Exclude tibial eminence fractures in adolescents. Chronic ACL deficient knees may demonstrate peaked tibial eminences, degenerative joint disease (DJD), narrowing of the intercondylar notch with osteophytes, and Fairbank's changes due to meniscal deficiency (squaring of the condyle, ridging, and joint space narrowing with DJD). Chronic MCL injury may appear as a calcification near the femoral origin of the MCL (Pellegrini-Stieda lesion). Lateral collateral ligament avulsion fractures may also be seen off of the fibula.

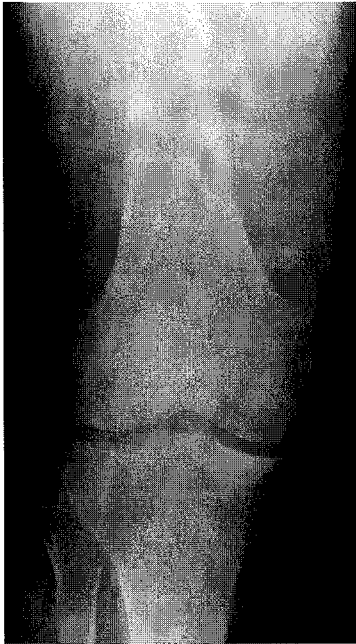

Figure 35-14 Anteroposterior radiograph demonstrating a Second fracture or lateral tibial capsular avulsion.

Valgus and Varus Stress Anteroposterior View

Suspicion of concomitant collateral ligament injury will demonstrate widening of the respective joint space on these views performed with the knee in 15 to 20 degrees flexion.

Lateral View

Deepening of the sulcus terminalis of the lateral femoral condyle may be seen.

Magnetic Resonance Imaging

Excellent accuracy (78–97%), sensitivity, and specificity (90–95%) can be obtained with MRI. Bone bruises seen on MRI of acute ACL injuries due to bony impaction occur most commonly in the posterolateral tibial plateau and anterior lateral femoral condyle. An MRI is useful to assess for associated pathology (e.g., collaterals, menisci, cartilage) (Figs. 35-15 and 35-16).

Bone Scan (Technetium Scintigraphy)

Bone scans are not routinely used in the acute setting. Chronically, increased osseous metabolic activity in the medial, lateral, and PF compartments (in that order) that may decrease after ACL reconstruction can be seen.

Specific Conditions, Treatment, and Outcome

The decision regarding treatment depends on a thorough understanding of the clinical and functional attributes of a torn ACL. Several studies report unacceptable functional performance in sports and activities that require deceleration and directional change on an ACL deficient knee. The absolute indications for ACL reconstruction are not clearly determined based on the literature. There is abundant evidence suggesting that ACL deficiency places the knee at high

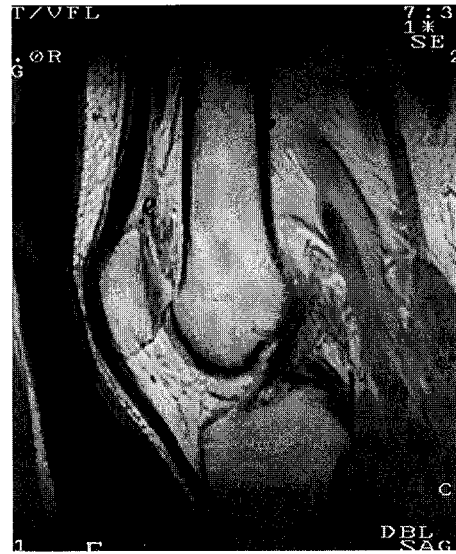


Figure 35-15 Magnetic resonance imaging scan demonstrating a normal ACL.

risk of damaging otherwise normal structures, such as the meniscus and articular cartilage, with recurrent episodes of instability over time. Ultimately, chronic ACL deficiency may lead to a higher incidence of irreparable meniscal tears and late degenerative changes in the knee. The patient's age, activity level, degree of instability, associated injuries, and ability to comply with a therapeutic program are important components of any algorithm predicating a treatment plan for the ACL deficient knee (Fig. 35-17).

Nonoperative Treatment

Reports on the true natural history of nonoperatively treated ACL injuries are flawed by several factors including, but not limited to, undocumented or missed ACL injuries, biased patient selection for nonsurgical treatment, mixing of acute

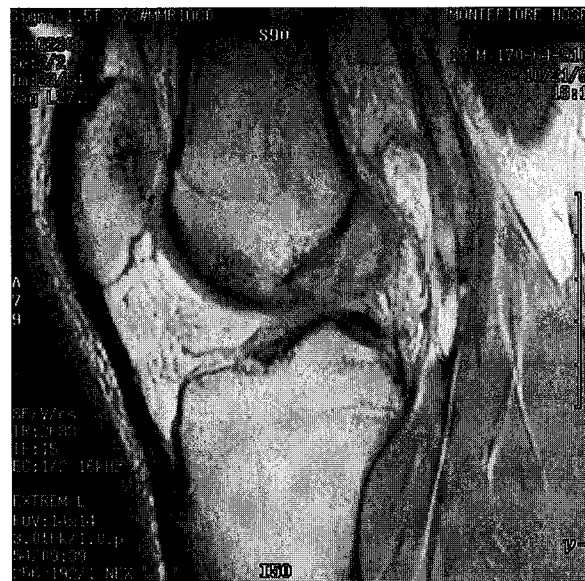

Figure 35-16 Magnetic resonance imaging scan demonstrating a complete tear of the ACL.

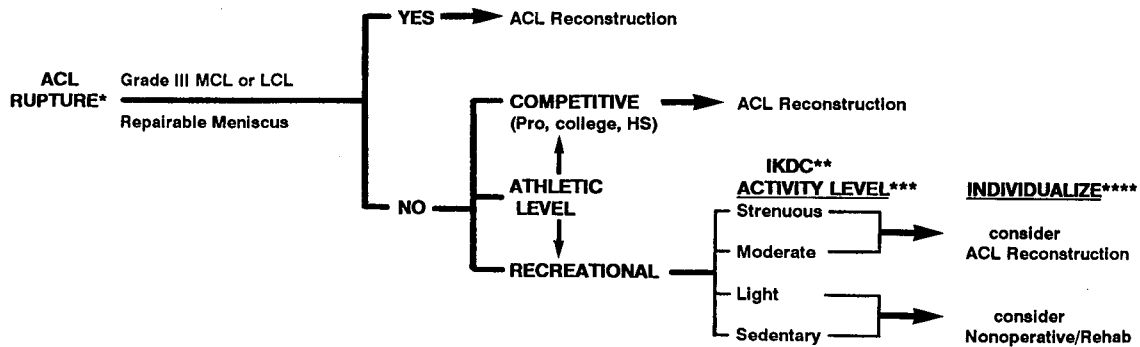


Figure 35-17 Algorithm for patient selection for ACL reconstruction based on associated collateral ligament and meniscal injury and anticipated future physical demands on the knee. *Mid-substance. **IKDC, International Knee Documentation Committee. ***Activity levels: strenuous (jumping or pivoting as in football and basketball), moderate (heavy manual work as in skiing), light (light manual work as in running), sedentary (activities of daily living). ****Individualize: Consider age, arthritis, occupation, activity modification and co-existing medial conditions. Reproduced with permission from Fu FH, Harner CD, Vince KG. *Knee Surgery*. Philadelphia, PA: Williams and Wilkins; 1994:652.

and chronic injuries, patients who are lost to followup, associated injuries, not accounting for age and activity level, and the variability in nonsurgical treatment and reporting of results. "Noyes' Rule of 3s" commonly quoted as "one third of the patients will compensate, one third will compensate with symptoms, and one third will do poorly" is often an inaccurate estimation of the results of nonoperative treatment (Noyes et al 1983). The majority of patients report worsening of their symptoms as subsequent giving-way episodes ensue. As indicated by the algorithm in Fig. 35-17, consideration of associated injury and activity level are perhaps the most important treatment determinants. In the presence of a pivot shift, despite only partial tearing of the ACL, the knee should be considered functionally as ACL deficient.

Acutely, emphasis on control of edema, analgesia, motion, quad control, and early weight-bearing as tolerated are critical. Patients can be initially managed with a hinged knee brace, crutches, cryotherapy, compression, elevation, and progressive ROM and isometric strengthening. Aseptic aspiration of a hemarthrosis may be diagnostic (e.g., blood and fat may indicate osteochondral injury) and therapeutic, allowing a more accurate physical examination.

Initially, nonoperative treatment is recommended for all patients including operative candidates prior to surgical reconstruction to reduce the incidence of knee stiffness. Nonoperative treatment only is indicated in those patients with an isolated injury and a willingness to modify their lifestyle. This should include a multimodality approach emphasizing resolution of inflammation, ROM, endurance, strengthening (especially HS and gastrocnemius), functional training, bracing, and patient education towards lifestyle modification. The goal is to obtain full ROM and return the muscle function to within 90% as compared with the normal side. Open-chain exercises provide isolated exercise for the HS and quadriceps. Closed-chain strengthening, isometrics, and cycling are frequently employed to minimize patellofemoral stresses. Dynamic stability is enhanced by gaining neuromuscular control through enhanced proprioception. Brace efficacy is controversial and is most useful in enhancing proprioception and in controlling anterior translation at low loads and rates of load application.

Operative Treatment

As previously indicated, several considerations are germane to the decision to surgically intervene.

Indications

Patient Age

No upper age limit for ACL reconstruction has been defined. Older patients may have equally as high or greater activity level expectations as their younger counterparts. Adolescents with open growth plates may be better candidates for HS reconstruction than bone-patellar tendon-bone (BPTB) reconstruction, although the latter is preferred by several authors and does not necessarily cause growth disturbances.

Partial Anterior Cruciate Ligament Tears

Operative treatment is recommended in high-demand patients with a partial ACL tear greater than 50% and the presence of a pivot shift.

Meniscal Tears

Combined ACL tears and "bucket-handle" meniscal tears causing a mechanical block must be addressed acutely. Simultaneous meniscal repair and ACL reconstruction have meniscal healing rates between 80 and 94% as opposed to meniscal repair in the ACL deficient knee where healing rates vary between 50 and 87%.

Anterior Cruciate-Medial Collateral Ligament Injuries

Combined ACL-MCL repair is commonly associated with postoperative loss of motion. The general consensus is that combined ACL-MCL injuries are managed by first nonoperatively treating the MCL injury with a hinged knee brace and early ACL reconstruction after ROM and muscular control are achieved. It is not unusual to wait an additional 2 to 3 weeks to attain normal ROM compared with an isolated ACL tear. Combined chronic ACL-MCL insufficiency may require an advancement procedure if laxity persists after ACL reconstruction.

Surgical Considerations

Timing

It is largely believed that allowing the edema to resolve and initiating preoperative rehabilitation to regain ROM are important factors in reducing the incidence of postoperative arthrofibrosis. Thus, the commonly quoted window of waiting 3 weeks before reconstruction is not a rigid criteria.

Primary Repair

Unlike the MCL, the ACL does not heal well. Most surgeons agree that there is no longer a place for primary repair. Repair of a bony avulsion, especially in adolescents with tibial eminence fractures, may be an exception to this rule if the ligament is viable without significant intrasubstance failure.

Extra-articular Reconstruction

Several procedures (i.e., Ellison, Losee) developed to tenodesis the ITB may reduce the pivot shift, but do not reliably limit anterior translation. These procedures do not have significant benefits over intra-articular reconstruction alone.

Intra-articular Reconstruction

This procedure is now considered the "gold standard" for active patients with ACL deficiency. After the decision to proceed with operative treatment has been discussed with the patient, the type of graft must be selected. Factors to be considered include availability, morbidity, structural properties, fixation, risk of disease transmission, surgeon familiarity, and cost.

Graft Selection

Possible grafts include autograft (BPTB, HS, ITB, quadriceps tendon), allograft (BPTB, Achilles tendon), synthetics (e.g., GoreTex, Dacron), and combined (biological with ligament augmentation device).

Bone-patellar tendon-bone grafts are typically used in the acute or chronic ACL-deficient knee in a high-level competitive or recreational athlete without PF problems. Hamstring grafts are typically used in cases with a significant history of PF problems, adolescents, and, possibly, lower-demand patients. Results comparing BPTB to HS grafts in the general

population appear to be similar. Allografts, although preferred by some in the acute setting, are most commonly used in revisions, older patients, combined ligament reconstruction, or where no other graft source is available. Freshfrozen allografts exposed to less than 2.5 Mrads of radiation (minimizing decline in strength) are commonly used. Of note, the risk of acquired immunodeficiency syndrome (AIDS) transmission using radiated fresh-frozen allografts has been reported to be 1:1,667,700. Iliotibial band, quadriceps tendon, and synthetic grafts are infrequently used. Advantages and disadvantages are listed in Table 35-1.

Structural Properties of Anterior Cruciate Ligament Graft

The ultimate tensile strength (UTS) of ACL grafts are: Normal ACL, 2160 N; 14 mm BPTB autograft, 164%; 10 mm BPTB, 107%; single semitendinosus (ST), 70%; single gracilis (G), 49%; and doubled ST-G, estimated as 250% of normal ACL UTS.

Stiffness: Stiffer grafts may be more vulnerable to early failure as they assume load before secondary restraints engage. The BPTB autograft is 3 times, and the ST-G autograft is approximately equal to, the normal ACL stiffness.

Graft Healing

Originally, the transplanted graft functions as a nonvascularized, free graft. Grafts undergo avascular necrosis, cellular repopulation, and revascularization during a process of "ligamentization" that is initiated between 1 and 3 months after surgery. Remodeling occurs in response to stress over the next 3 to 12 months. Graft tensile strength is weakest during the initial phase of avascular necrosis, retaining about 50% of its original tensile strength at 3 to 6 months and about 80% at 9 to 12 months. At 12 months, the graft may be only about 50% as strong as the native ACL. Complete maturation may take between 1 to 3 years and somewhat longer with BPTB allografts. Bone healing within tibial and femoral tunnels takes at least 6 to 8 weeks in normal bone, but may take up to 6 months. Stable ingrowth of ligament into bone in animal studies takes about 8 to 12 weeks after implantation.

TABLE 35-1 Graft Advantages and Disadvantages

		Advantages	Disadvantages
Autografts	BPTB	High UTS, early bone-to-bone healing, strong and flexible fixation, availability, accessible, technically forgiving	High stiffness, extensor morbidity, more anterior knee pain, difficult placement, patellar fracture, PT rupture
	HS	Less stiffness, less extensor morbidity, less anterior knee pain, high UTS with multiple strands, comparable results with BPTB	Lower UTS, less effective fixation, soft-tissue-to-bone healing, technically difficult, HS muscle weakness up to 1 year
Allografts		No donor site morbidity, technically forgiving, availability	Cost, sterility considerations, recipient biological response, bony tunnel reabsorption, disease transmission, delayed incorporation

Graft Fixation

Initially, the points of fixation are the weakest portion of the repair and must tolerate between 50 and 250 N during controlled rehabilitation. Numerous devices are available for fixation including metal and biodegradable interference screws, Endobutton (Acuflex Microsurgical; Mansfield, MA) with polyester tape, sutures around a post, screw/washer over a tendon, staple over a bone block, or tendon and sutures through a button. The most common construct, an interference screw against a bone block within a tunnel, has the following biomechanical characteristics: minimal contact length of 12.5 mm, minimal divergence of 15 degrees, 7 × 20-mm screw with a gap of 1 to 2 mm or 9 × 20-mm screw with a gap of 3 to 4 mm, and an insertion torque of 8 to 12 pounds. Other fixation devices with their respective estimated failure loads are listed in Table 35-2.

Graft Placement

Isometry is a condition in which there exists little to no change in the distance between the ligament graft-attachment sites through ROM. Graft diameter and attachment site size preclude "ideal isometry" as do changes in loads and flexion angles. The best one can achieve is anatomic placement of the graft to minimize graft length change during ROM (≤ 2 mm or $\leq 10\%$ change over 30 mm)(Table 35-3).

TABLE 35-2 Fixation device and estimated failure loads

Fixation Device	Estimated Failure Load
9-mm interference screw	400-500 N
No. 2 suture/No. 5 suture	64 N/150-450 N
Endobutton (Acuflex Microsurgical; Mansfield, MA)	250-500 N
Screw/washer on HS	160-200 N
Double-loop HS around screw/washer	821 N
Staples	100-240 N

TABLE 35-3 Errors in graft placement with resulting graft tension

		Too Posterior	Too Anterior
Femur Position	Extension	Tight	Loose
	Flexion	Loose	Tight
Tibial Position	Extension	Tight	Loose
	Flexion	Loose	Tight with impingement

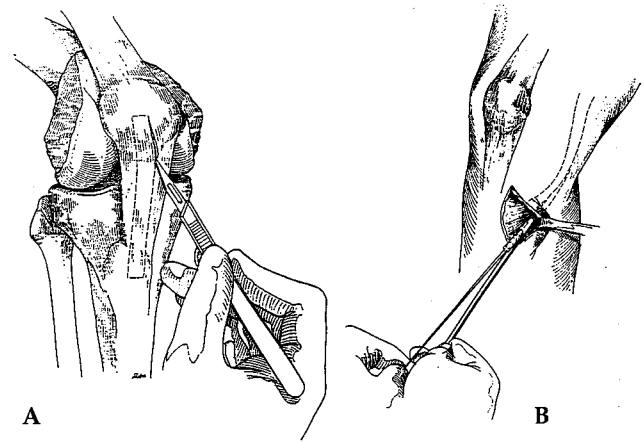


Figure 35-18 Graft harvesting. (A) Bone-patellar tendon-bone harvesting with the knee at 90 degrees of flexion. (B) Hamstring harvesting. The tendon stripper is advanced parallel to the semitendinosus using a back and forth or rotary type motion. Reproduced with permission from Fu FH, Harner CD, Vince KG. *Knee Surgery*. Philadelphia, PA: Williams and Wilkins; 1994:670, 671.

Surgical Technique

Graft Harvesting

Central third BPTB: A tourniquet may be used, but infiltration with 1:300,000 epinephrine solution may be satisfactory and limits ischemic morbidity including subclinical neuropraxia and muscle contractile dysfunction (Fig. 35-18). A 7 to 9-cm longitudinal skin incision is made 1 cm medial to the midline of the patellar tendon (PT). Alternatively, single or mini-double transverse incisions are preferred by some because of improved cosmesis. Subcutaneous flaps are developed, and the paratenon is reflected to expose the medial and lateral borders of the PT. Proximal extension is achieved with knee extended. While the knee is flexed, mark the distal pole of the patella and the center of the PT insertion onto the tibial tubercle with a sterile marking pen. A central 9 to 11-mm section of the PT is incised using a sawing-type motion with a No. 10 blade. Care is taken to stay parallel to the fibers of the PT as they deviate laterally toward the tibial tubercle.

The tibial tubercle and the patellar bone blocks are also outlined using a No. 10 blade. Although techniques may vary, a 5 to 6-mm in depth and 20 to 25-mm in length trapezoidal, bone plug (avoiding the joint surface) is harvested from the patella using an oscillating saw and 1/4 inch osteotome. Similarly, a bone plug in the shape of an equilateral triangle (maximizing bone beneath the remaining PT) is harvested from the tibial tubercle. Carefully dissect the fat pad from the patellar tendon with Metzenbaum scissors from distal to proximal. Contour the bone blocks into a cylinder and place 1 to 3 No. 5 nonresorbable sutures through each block after predrilling with a .062-inch K-wire. Oblique or parallel passage of the sutures minimizes the likelihood of suture laceration with an interference screw. Alternatively, an Endobutton may be used for fixation over the anterolateral femur.

Hamstrings: A figure-of-four position may be helpful to initially identify and harvest the HS tendons from the pes

anserinus (Fig. 35-18b). Through a 5-cm longitudinal incision located 4 cm medial and 3 cm distal to the tibial tubercle, layer 1 (the sartorius fascia) is identified. The G (more proximal) and ST tendons are palpated as two small bumps beneath layer 1, which is then incised parallel to these tendons. Care is taken not to violate layer 2, the superficial MCL. The G and ST tendons are found and retrieved from the undersurface of layer 1 using a right-angle clamp and Penrose drain. The infrapatellar branches of the saphenous nerve crossing the gracilis must be protected.

A tendon stripper can be used with tendon insertions left intact (slotted tendon stripper) or detached (closed tendon stripper). Mobilization requires release of fascial bands between the G and ST tendons. Connections between the ST and medial head of the gastrocnemius must be released 7 cm proximal to the insertion of the ST tendon. Additionally, a sling of tissue from the semimembranosus to the ST tendon may need to be released. At the time of distal release of the tendons, a running, baseball whip stitch with No. 2 or No. 5 nonabsorbable suture is placed in the free end of each tendon. The tendon stripper is advanced parallel to the tendon using a slow and steady, back and forth motion up into the thigh until the tendon is freed from its muscle-tendon junction. Each tendon is prepared by first stripping residual muscle from the tendon substance and doubling them to create a quadruple stand graft of 26 to 32 cm in length and 8 to 9 cm in diameter. The free ends are prepared as before using nonabsorbable suture. Depending on the femoral fixation system used a large polyester tape or No. 3 to No. 5 nonabsorbable sutures are used within the looped ends of the G and ST tendons.

Graft Placement

Anterior cruciate ligament reconstruction can be performed with a one-incision (endoscopic) or two-incision (arthroscopically assisted or mini-arthrotomy) technique. The femoral tunnel is prepared either inside-out (one-incision) or outside-in (two-incision). Examination under anesthesia with side-to-side comparison and diagnostic arthroscopy through anteromedial and anterolateral portals is performed in either technique to address associated pathology.

One-incision endoscopic technique: The contralateral limb is placed in a well-leg holder and the operative limb in a leg holder placed over a thigh-high tourniquet. The foot of the bed is lowered for circumferential access to the operative leg. After the graft is harvested, the intercondylar notch and ACL stump are debrided using a full-radius resector and basket rongeur. The goal is to expose the intercondylar wall of the lateral femoral condyle and the insertion site on the tibial eminence. Care must be taken not to injure the PCL or the intermeniscal ligament. A notchplasty (widening of the intercondylar notch) is performed from anterior to posterior. Only enough bone to aid in visualization and protect the graft from abrasion is removed. The "over-the-top" position must be identified and not confused with "resident's ridge," a prominence along the medial wall of the lateral femoral condyle located only two thirds of the way back posteriorly often mistaken as the most posterior aspect of the lateral femoral condyle.

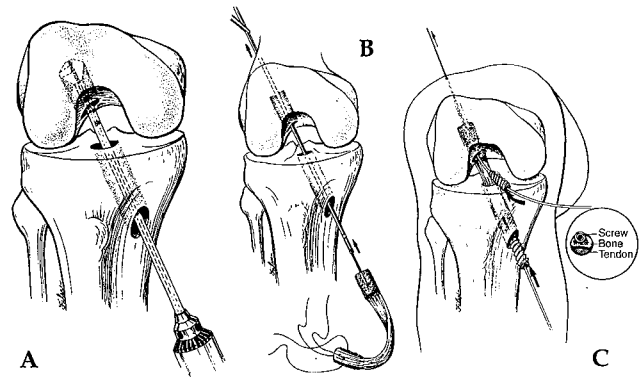


Figure 35-19 (A) Femoral tunnel preparation through the tibial tunnel. (B) Graft passage. (C) Graft fixation with interference screw. Reproduced with permission from Miller MD, Fu FH. Arthroscopic allograft anterior cruciate ligament reconstruction. *Op Tech Sports Med.* 1995;1:116.

With the arthroscope in the inferolateral portal, the tibial tunnel is started at a point midway between the tibial tubercle and the posteromedial edge of the tibia (Fig. 35-19). An ACL drill guide is set at 50 to 55 degrees for the BPTB graft and 45 to 50 degrees for the HS graft. The guide is placed through the inferomedial portal to place a guide pin into the center of the ACL tibial attachment site, erring slightly posteriorly (staying just anterior to Humphry's ligament). An appropriately sized cannulated reamer is used to overdrill the guide pin.

The femoral tunnel site is chosen such that the center of the hole will be located approximately at the 11-o'clock position in a right knee and at the 1-o'clock position in a left knee. Using a guide pin and appropriately sized cannulated reamer, the femoral tunnel is drilled through the tibial tunnel with the knee flexed 90 degrees, leaving a 1- to 2-mm posterior cortical rim. The intra-articular edges of both tunnels are debrided of remaining soft tissue and bone to minimize the potential to develop a soft tissue "cyclops" lesion and to prevent graft abrasion. Using the sutures attached to the graft end, the graft is passed retrograde through the tibial tunnel into the femoral tunnel and fixed within the femoral tunnel. The knee is flexed and extended several times while placing tension on the graft before the graft is fixed to the tibia with the knee in nearly full extension.

Two-incision arthroscopically assisted technique: The tibia tunnel is prepared as in the one-incision technique. The femoral tunnel is prepared using a 4-cm incision made in the midline of the lateral supracondylar area of the femur at the level of the proximal pole of the patella. The ITSB is split in line with its fibers, and the vastus lateralis elevated and retracted anteriorly. The lateral superior geniculate vessels are identified and electrocauterized. The femoral tunnel is prepared from outside-in using a drill guide placed intraarticularly and through the incision at the supracondylar region, meeting a point at a similar notch location as in the one-incision technique. The BPTB graft is passed and fixed in the lateral cortex from outside-in using an interference screw. The HS is fixed with a staple or screw and washer

technique. The graft is fixed at the tibia as in the one-incision technique.

PEARL

In the event that the graft is too short to secure to the tibia, the sutures can be transfixated around a screw and washer. If a bone-patellar tendon-bone (BPTB) graft is too long, a bone staple can be used, impacting the graft into a trough prepared to seat the bone plug.

Rehabilitation

Following ACL reconstruction, rehabilitation must respect initial graft strength, fixation, and biological healing. Postoperative rehabilitation emphasizes control of inflammation, progressive weight-bearing, restoration of motion including full extension, quadriceps exercises, and restoration of normal gait. Cold and compression are used in the first week to control inflammation and pain. Full weight-bearing is achieved as tolerated and assistive devices are eliminated when the patient demonstrates a normal gait. Full extension symmetric to the noninvolved side is achieved within 2 to 3 weeks, and full flexion within 8 weeks after surgery. Bracing in extension for the first week, unlocking it only for exercises, is preferred by some to minimize notch scarring. Patellar mobilization is generally performed.

Some surgeons advocate avoiding quadriceps loading from 45 degree flexion to full extension for 2 to 3 months because of concerns of placing excessive stress on the graft. Closed-chain minisquats (muscle co-contraction) exercises are utilized to minimize anterior tibial translation in this functional range. Open-chain quad sets can be performed in full extension minimizing ACL stress.

Proprioceptive activities are initiated to regain neuromuscular control. Accelerated rehabilitation can return an athlete to full sports participation in 4 to 6 months, in some instances. More commonly, it takes 6 to 9 months to return to sports. A functional brace may be recommended for the first 1 to 2 years after surgery.

Results

The goals of surgical reconstruction of the ACL-deficient knee are to first restore ligamentous stability and delay or prevent articular and meniscal damage. Ideally, a painless knee with full motion and normal strength and coordination is desirable. The lack of a uniform grading system for reporting the results of ACL reconstruction makes comparisons between studies difficult.

Reports of BPTB and HS autografts or allografts show good and excellent results in greater than 90% of patients at intermediate-term followup. Synthetic ligaments have had unacceptable rates of failure in most medium or long-term reports. Prospective, randomized long-term followup is still lacking, and controversy remains regarding the effects of ACL reconstruction on the future degeneration of articular surfaces.

Complications

The most common complication following ACL reconstruction is loss of motion, especially extension, due to quadriceps weakness and PF problems. A flexion contracture greater than 10 degrees or flexion less than 130 degrees may lead to a functional deficit. Stiffness may occur as a result of operating while the patient is still recovering from the inflammation of the initial injury. Patients with loss of motion should be evaluated for notch scarring or capsulitis. Treatment may include arthroscopic debridement and prolonged rehabilitation. Other causes of poor motion include prolonged immobilization, a "cyclops" lesion (residual tissue anterior to an ACL graft) blocking full extension, aberrant tunnel placement, inadequate notchplasty, improper graft tensioning, infrapatellar contracture syndrome, and generalized arthrofibrosis.

Anterior knee pain, often attributed to harvesting of the BPBT autograft, is not necessarily less frequent following HS reconstruction, especially when accelerated rehabilitation programs are used. The reported incidence ranges from 5 to 50%. Preoperative PF crepitus may be a risk factor for postoperative anterior knee pain.

Other less common complications include patella fracture, patellar tendonitis, graft rupture from impingement, failure of fixation, accelerated degenerative arthritis, ankylosis, fat pad fibrosis, recurrent effusion, deep vein thrombosis, heterotopic ossification, septic knee, and skin problems.

Future Directions

In the near future, improvements in current techniques, including graft fixation, the development of a three-dimensional arthroscopic visualization system, and robotic surgical procedures may enhance the outcome of ACL reconstruction. In the distant future, resorbable stents and growth factors may induce ACL healing. Full restoration of an ACL-deficient knee may be achieved through genetic manipulation, including tissue regeneration.

POSTERIOR CRUCIATE LIGAMENT INJURIES

Although more common than once believed, injuries to the PCL account for between 3 and 20% of all knee ligament injuries. It is estimated that 40% of all PCL injuries are isolated tears. The true incidence is probably much greater than this because many isolated tears remain undetected. Most injuries occur in young males involved in motor vehicle-related accidents ("dashboard injury") and contact sports.

Basic Science

Biomechanics

Kinematics

The PCL is the primary restraint (95%) to posterior tibial translation at 90 degrees of flexion. The PCL and ACL regulate the screw-home mechanism of external tibial rotation in terminal extension. The PCL also acts as a secondary restraint to ER of the tibia in combined posterolateral complex (PLC)