

## XII. Acromioclavicular and Sternoclavicular Injuries

A. Acromioclavicular Degenerative Disease. The AC joint is a diarthrodial joint vulnerable to the same degenerative processes affecting other joints. The AC joint transmits large loads across a very small surface area. Degeneration of the intra-articular disk may begin as early as the second decade. Its superficial location also predisposes it to traumatic injury.

Diagnosis and treatment depend upon a triad of pain over the AC joint, pain with cross-body adduction, and transient relief with a local anesthetic injection directly into the AC joint. A positive bone scan provides additional confirmation, but is rarely required. Initial nonoperative treatment includes activity modification, NSAIDs, corticosteroid injections, and physical therapy. Surgery, consisting of open or arthroscopic distal clavicle resection, should be considered if symptoms persist. Arthroscopic resection through standard portals (posterior, anterior, and lateral) with occasional use of a direct portal located over the AC joint has the advantage of accurate resection with preservation of the superior AC ligament and joint capsule and avoids detachment of the deltoid and trapezius, leading to quicker mobilization and recovery. Typically, no more than 8 to 10 mm of space is required for adequate decompression and symptom relief (Fig. 4-107). Visualizing the AC joint through the anterior portal ensures adequate posterior angle excision, a common source of persistent symptoms following AC joint resection. Good to excellent results have been reported in 85% to 100% of patients in large series. Associated AC joint instability is a poor prognostic factor for patients who undergo AC joint resection.

1. Primary Osteoarthritis. In spite of the high (approximately 50%) prevalence of radiographic evidence of degeneration in elderly people, symptomatic primary AC joint osteoarthritis is relatively uncommon. It must, however, be considered when evaluating any shoulder problem, particularly impingement syndrome and rotator cuff tears. AC joint excision is warranted if patients have tenderness over the AC joint, a positive cross-body adduction test, and pain relief with selective AC joint injection.
2. Post-Traumatic Arthritis. This may occur in up to 40% of individuals following grades I and II AC joint sprains or secondary to direct trauma. Operative procedures for AC joint dislocations in which the joint is trans-

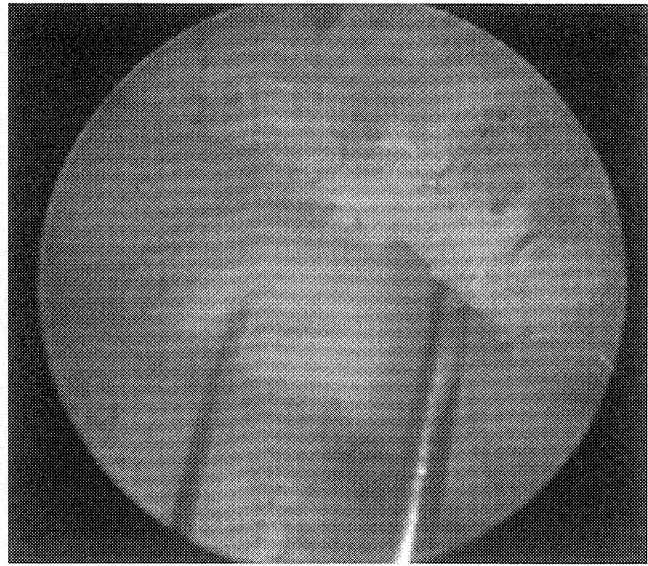


Figure 4-107. Arthroscopic view of acromioclavicular joint following distal clavicle excision. Two spinal needles placed percutaneously help to define the amount of resection.

fixed or preserved result in a higher incidence of post-traumatic degenerative change than those in which the joint is excised with subsequent stabilization (see below).

3. Distal Clavicle Osteolysis. This is increasingly recognized in weightlifters and in those with a history of traumatic injury. Localized aching and pain is exacerbated by weightlifting in otherwise young and active patients. Radiographs of the distal clavicle reveal osteopenia, osteolysis, tapering, and cystic changes (Fig. 4-108). Failing selective corticosteroid injection, NSAIDs, and activity modification, this condition responds favorably to AC joint excision.

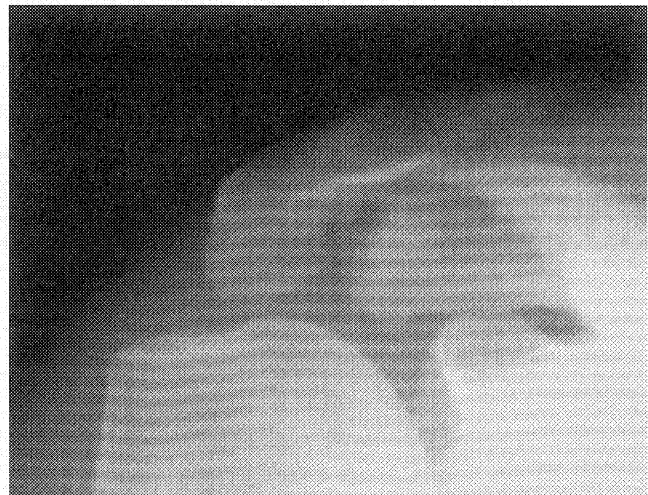
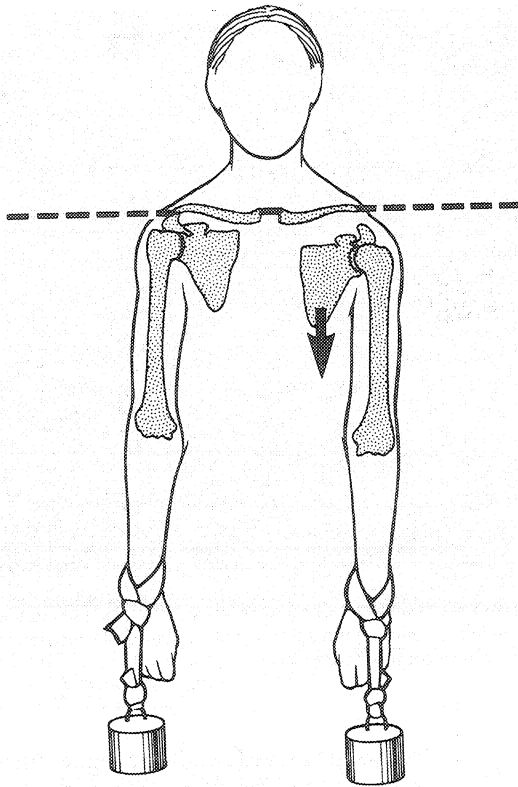


Figure 4-108. Zanca view demonstrating distal clavicular osteolysis with cystic changes in a 28-year-old male weightlifter.



**Figure 4-109.** Type III acromioclavicular injuries may be best demonstrated by measuring the distance between the coracoid and clavicle on bilateral AP radiographs of the shoulder with 10 to 15 lb of weights hanging from both arms. (From Rockwood CA Jr, Young DC: Disorders of the acromioclavicular joint. In Rockwood CA Jr, Matsen FA III [eds]: *The Shoulder*. Philadelphia: WB Saunders, 1990, p 421.)

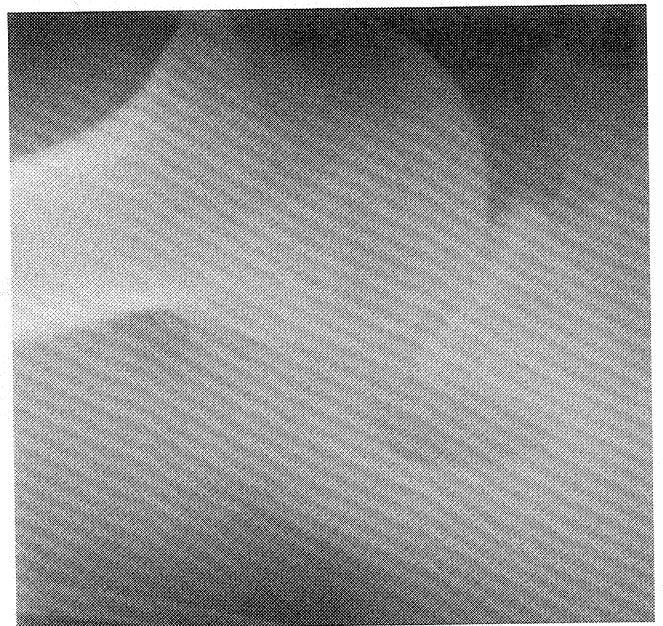
**B. Acromioclavicular Separation.** AC separations constitute about 12% of dislocations of the shoulder girdle and typically result from a fall directly onto the shoulder or through indirect forces to the upper extremity. The AC ligaments and capsule provide the major restraint to AP translation of the clavicle with small displacements. The CC ligaments provide the major restraint to superior translation with larger displacements. This explains the degree of displacement that occurs with progressive disruption of these ligaments. Radiographic evaluation includes the Zanca view (see Fig. 4-52) described previously and stress views of both AC joints (Fig. 4-109). It is critical to also obtain an axillary view to determine the AP position of the clavicle relative to the acromion (Fig. 4-110).

The classification scheme developed by Rockwood is well accepted (Fig. 4-111; Table 4-12). A type I injury (AC joint sprain) is stable with intact ligaments and minimal to moderate AC joint tenderness without palpable deformity. A type II injury (AC joint disruption and CC joint sprain) is associated with slight downward displacement of the scapula relative to the distal clavicle with moderate to severe AC joint pain, with the distal clavicle appear-

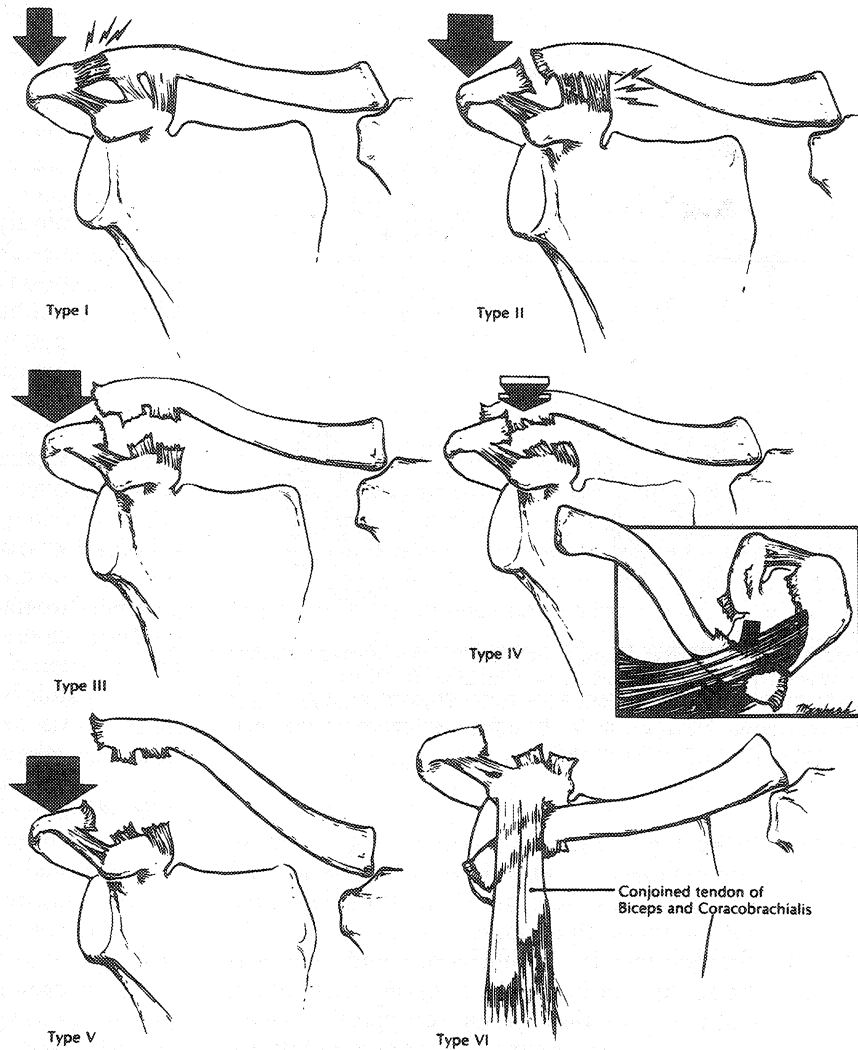
ing slightly superior to the acromion. Treatment is nonoperative with rest and short-term use of a sling for comfort. Return to activity is allowed when the patient demonstrates full painless range of motion.

A type III injury (AC joint and CC ligament disruption) presents with moderate pain and a depressed upper extremity compared with the opposite shoulder, with the distal end of the clavicle prominent enough to tent the skin. The distal clavicle can be manually reduced, but remains unstable when pressure is removed. Treatment of these injuries remains controversial. Most commonly, nonoperative treatment similar to that provided for types I and II AC separations is recommended. Operative management is generally reserved for high-level overhead athletes or laborers, for patients with brachial plexopathy, and for open or skin-compromising injuries.

A type IV injury (AC joint and CC ligament disruption with posterior displacement of the distal clavicle) presents with more pain than a type III injury, with a posteriorly displaced and irreducible clavicle that may be locked within the trapezius muscle fibers. A type V injury (AC joint and CC ligament disruption) is a very severe type III injury with detachment of the deltoid and trapezius muscles from the distal clavicle associated with profound and often irreducible drooping of the upper extremity. A type VI injury is very rare and associated with a traumatic abduction force to the upper extremity leading to dislocation of the distal clavicle beneath the coracoid process and posterior to the conjoined tendon. Open treatment is ap-



**Figure 4-110.** Axillary view demonstrating posterior displacement of the distal clavicle relative to the acromion.



**Figure 4-111.** Classification of acromioclavicular injuries. (From Rockwood CA Jr, Young DC: Disorders of the acromioclavicular joint. In Rockwood CA Jr, Matsen FA III [eds]: The Shoulder. Philadelphia: WB Saunders, 1990, p 423.)

appropriate for type IV, V, and VI injuries. Fixation across the AC joint with K-wires with their ends bent outside the lateral acromion or a hook plate lends stability, but hardware generally requires later removal and risks breakage and migration. Screw or cerclage fixation of the distal clavicle to the coracoid has also been described, yet holds many of the same disadvantages. Treatment of both acute and

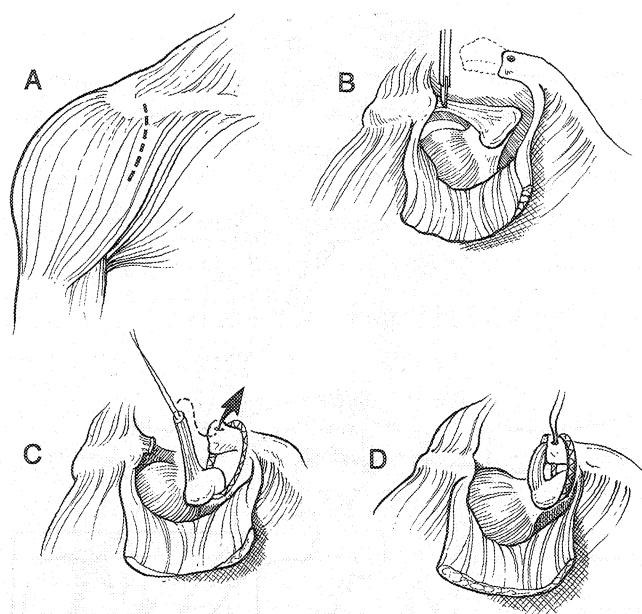
chronic AC separations may be accomplished with a modified Weaver-Dunn procedure (Fig. 4-112). This basically involves resection of the distal clavicle and transfer of the CAL to the resected end through drill holes. A braided PDS suture or prolonged absorbable suture is then passed under the coracoid and secured through a drill hole in the distal clavicle, lending stability until the reconstructed ligament

Table 4-12.

#### Classification of Acromioclavicular (AC) Injury

| Injury Classification | AC Ligament | Coracoclavicular Ligament | Deltotrapezial Fascia |
|-----------------------|-------------|---------------------------|-----------------------|
| I                     | Sprain      | Intact                    | Intact                |
| II                    | Disruption  | Sprain                    | Intact                |
| III                   | Disruption  | Disruption                | Partial disruption    |
| IV                    | Disruption  | Disruption                | Detached              |
| V                     | Disruption  | Disruption                | Detached              |
| VI                    | Disruption  | Disruption                | Detached              |

From Lemos MJ: The evaluation and treatment on the injured acromioclavicular joint in athletes. *Am J Sports Med* 26:137-144, 1998.



**Figure 4-112.** Weaver-Dunn procedure for symptomatic chronic acromioclavicular separations. *A*, Skin incision. *B*, Distal clavicle resection. *C*, Mobilization of the coracoacromial ligament and fixation of the clavicle to the coracoid. *D*, Transfer and fixation of the coracoacromial ligament to the clavicle.

heals (Fig. 4-113). Postoperatively, patients are immobilized in a sling for 4 to 6 weeks to limit downward displacement of the shoulder girdle during the healing phase.

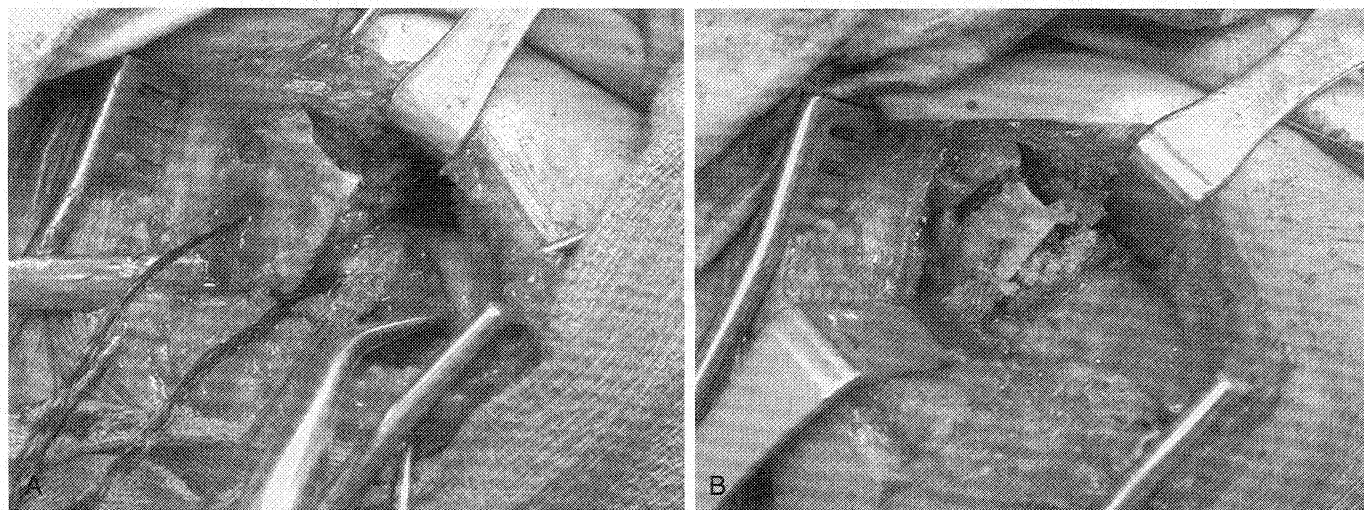
- C. Sternoclavicular Subluxation and Dislocation.** Injuries to the SC joint are uncommon, but may be serious. They are typically caused by high-energy trauma such as automobile accidents, but may also result from athletic injury associated with direct trauma. Localized

prominence, tenderness, and associated injuries should be noted. Hoarseness, shortness of breath, or dysphagia is particularly worrisome. Radiographs should include Hobbs and serendipity views, but a CT scan should be obtained if there is any question of dislocation. It is important to remember that the medial epiphysis of the clavicle is the last to ossify (18–20 years) and close (23–25 years) and can easily be mistaken for traumatic injury in this age group.

Anterior dislocation is more common than posterior dislocation (20:1). Treatment, if any, typically involves closed reduction, which is usually successful. If this fails, skillful nonoperative neglect is generally acceptable. Open treatment for posterior dislocation is often recommended and a vascular surgery consultation is important because of the risk of vascular injury or entrapment. Placement of hardware in or around the SC joint should be avoided as migration may lead to catastrophic complications. Patients with spontaneous SC joint subluxation should be treated nonoperatively as this is a self-limited condition. SC joint arthritis is rare, but usually manageable with rest, local modalities, and NSAIDs. Occasionally, medial resection is curative.

### XIII. Calcific Tendonitis

- A. Introduction.** Calcific tendonitis is a self-limited condition of unknown etiology predominantly affecting middle-aged women. Most commonly, the supraspinatus tendon is involved. It is a multifocal cell-mediated calcification of tissue followed by phagocytic resorption (painful phase) and tendon reconstitution. The condition must be distinguished from degenerative or dystrophic calcification, which tends to occur at tendon insertion sites.



**Figure 4-113.** Patient with chronic grade IV acromioclavicular injury. *A*, Intraoperative photograph demonstrating PDS braid passed around the coracoid and through a hole placed 2 cm medial to the lateral edge of the clavicle. No. 2 Ethibond placed in the coracoacromial ligament (CAL) in preparation for passage through drill holes placed in the end of the clavicle. *B*, PDS braid and CAL secured with clavicle reduced.

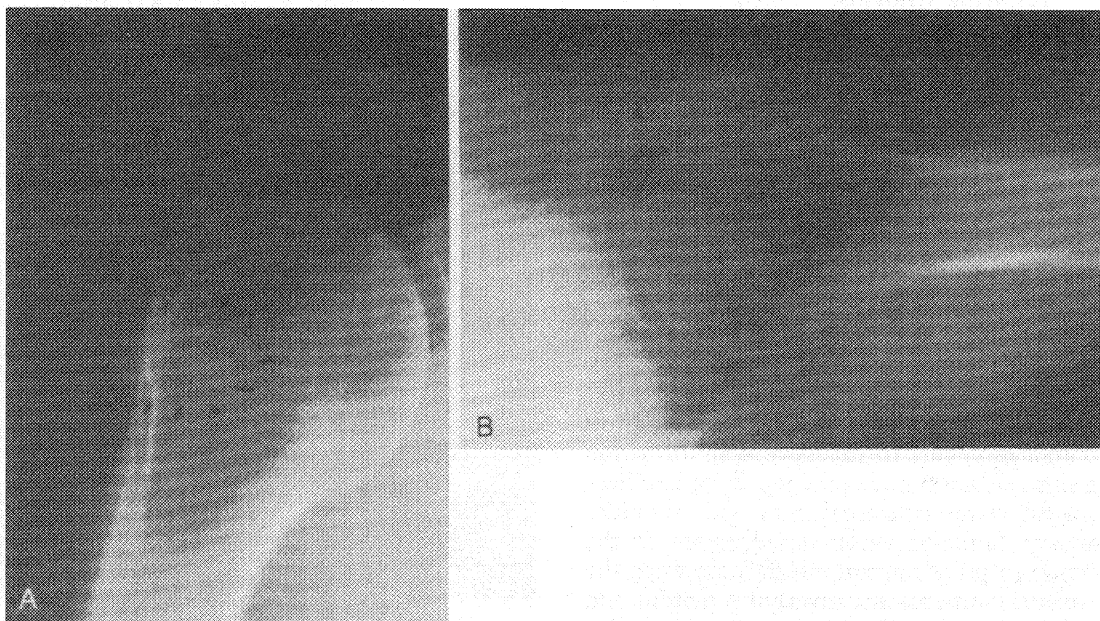
## B. Stages

1. Precalcific Stage. Fibrocartilaginous tendon metaplasia.
2. Calcific Stage
  - a. Formative phase with calcium deposition.
  - b. Resting phase where calcified area is surrounded by fibrocartilage.
  - c. Resorptive phase characterized by acute pain and the spontaneous appearance of vascular channels at the borders of the calcified deposit.
3. Postcalcific Stage. Granulation tissue and tendon remodeling.

C. Evaluation. Radiographic evaluation reveals calcifications, often localized to the supraspinatus tendon, 1.5 to 2.0 cm from its bony insertion (Fig. 4-114). Two radiographic subtypes have been identified: type I, with a fluffy, ill-defined appearance, correlating with the resorptive phase, and type II, with well-defined, homogeneous depositions that may overlie a crescentic shadow indicating rupture of the deposition into the underlying bursa.

D. Treatment. Patients in the resorptive phase, although acutely painful, will undergo relatively rapid and spontaneous symptom resolution. Nonoperative treatment is the rule, consisting of physical therapy and modalities. Needling of deposits and local anesthetic injection is advocated by some authors. The efficacy of local steroid injection is controversial. Extracorporeal shock wave therapy may achieve symptomatic improvement in up to 50% of patients but its use is largely investigational. Operative removal of calcific deposits

during the formative phase has been reported to have a high success rate.



**Figure 4-114.** AP (A), and axillary (B), lateral radiographs demonstrating calcific tendonitis near the subscapularis insertion on the lesser tuberosity. (From Re P, Karzel RP: Management of rotator cuff calcifications. *Orthop Clin North Am* 24:128, 1993.)