

Allograft Meniscus Transplantation: Bridge in Slot Technique

Andreas Gomoll, MD
Jack Farr, MD
Brian J. Cole, MD, MBA

It is generally believed that any significant meniscectomy alters the biomechanical and biologic environment of the normal knee, eventually resulting in pain, recurrent swelling, and effusions. Overt secondary osteoarthritis is often the endpoint.^{1,2} Recognition of these consequences has led to a strong commitment within the orthopedic community to meniscus-sparing interventions. However, there are cases in which meniscal preservation is not possible. In carefully selected patients, meniscal allografts can restore nearly normal knee anatomy and biomechanics, providing excellent pain relief and improved function.⁵

Several techniques exist for allograft meniscus transplantation, including bone plugs, a keyhole technique, and a dovetail technique. The senior authors prefer the bridge in slot technique, as described previously,⁶ because of its simplicity and secure bone fixation, the ability to more easily perform concomitant procedures such as osteotomy and ligament reconstruction, and the advantages of maintaining the relationship of the native anterior and posterior horns of the meniscus.

Preoperative Considerations

History

It is essential to elicit a thorough history, including the causative mechanism, associated injuries, and prior treatments. Operative reports are helpful to evaluate arthritic

changes that could constitute a contraindication to meniscal transplantation.

Typical History

- Knee injury, often an acute traumatic event initiating meniscal treatment
- One or more meniscectomies, open or arthroscopically performed with initial improvement
- Subsequent development of ipsilateral joint line pain and activity-related swelling
- Giving way (occasionally reported)

Physical Examination

Factors Affecting Surgical Indication

- Range of motion: usually preserved
- Effusion
- Joint line or femoral condyle tenderness
- Objective evidence of joint space narrowing (magnetic resonance imaging, flexion weight-bearing radiographs), development of localized or diffuse chondral disease in the ipsilateral compartment

Factors Affecting Surgical Planning

- Preexisting incisions
- Limb malalignment (may require concomitant realignment procedure)

- Ligamentous instability (may require prior or concomitant reconstructive procedure)
- Chondral injury, typically involving the femoral condyle (may require concomitant cartilage repair procedure)

Imaging

Radiography

- Weight-bearing anteroposterior radiograph in full extension
- Weight-bearing posteroanterior 45-degree flexion radiograph
- Non-weight-bearing 45-degree flexion lateral view
- Axial view of the patellofemoral joint
- Long-cassette mechanical axis view to evaluate malalignment

Other Modalities

- Magnetic resonance imaging with or without the intra-articular administration of contrast material is performed to assess extent of meniscectomy, degree of articular cartilage damage, and presence of subchondral edema in the involved compartment.
- Technetium bone scan may indicate stress overload in the involved compartment or overt osteoarthritis.

Indications and Contraindications

The ideal candidate has a history of prior total or subtotal meniscectomy with persistent pain localized to the involved compartment, intact articular surfaces (ideally, grade I or II), normal alignment, and a stable joint. Associated pathologic findings, such as malalignment, discrete chondral

defects, and ligamentous instability, are not contraindications in an otherwise appropriate candidate because they can be addressed in either staged or concomitant procedures.

In addition to uncorrected comorbidities (malalignment, ligament deficiency, uncorrected localized chondral damage in the involved compartment), contraindications are overt arthroscopic or radiographic arthritic changes (especially associated with femoral condyle or tibial flattening), history of inflammatory arthritis, marked obesity, and previous infection.

Surgical Planning

Concomitant Procedures

Significant limb malalignment, ligamentous instability, or discrete chondral defects can be addressed either before or concomitant with meniscus transplantation.

Allograft Sizing

Meniscal allografts are size and compartment specific. Pre-operative measurements are obtained from anteroposterior and lateral radiographs with magnification markers placed on the skin at the level of the joint line. After radiographic magnification is accounted for, meniscal width is measured on the anteroposterior radiograph from the edge of the ipsilateral tibial spine to the edge of the tibial plateau. Meniscal length is calculated by multiplying the depth of the tibial plateau (as measured on lateral radiographs) by 0.8 for the medial meniscus and 0.7 for the lateral meniscus (Fig. 47-1).

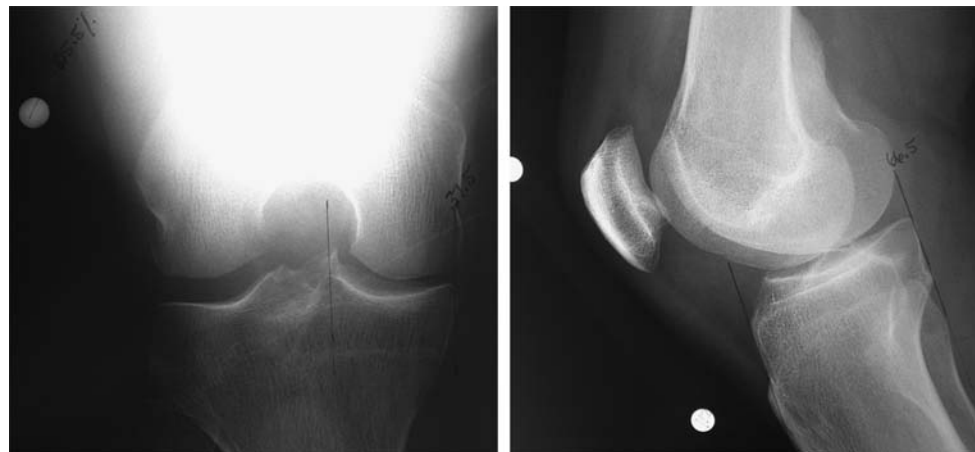

Figure 47-1 Graft sizing on anteroposterior and lateral radiographs.

Meniscal Graft Processing and Preservation

Meniscal allografts are harvested by sterile surgical technique, most commonly within 24 hours of donor asystole. Unlike with fresh osteochondral allografts, cell viability in meniscal allografts does not seem to improve the morphologic or biochemical characteristics of the grafts; thus, the most commonly implanted grafts are either fresh-frozen or cryopreserved. The risk of disease transmission is minimized through rigid donor screening, graft culturing, and polymerase chain reaction testing for human immunodeficiency virus. Several tissue banks are evaluating secondary sterilization techniques to further improve the safety of meniscal allograft tissue.

Surgical Technique

Anesthesia and Positioning

On the basis of the surgeon's, anesthesiologist's, and patient's preferences, the procedure can be performed under general, spinal, or regional anesthesia or a combination thereof. The patient is positioned supine on a standard operating room table, with a thigh tourniquet, and the extremity is placed in a standard leg holder allowing

full knee flexion or hyperflexion (Fig. 47-2). The posteromedial or posterolateral corner must be freely accessible for inside-out meniscus suturing to be performed.

Surgical Landmarks, Incisions, and Portals

Landmarks

- Patella
- Patellar tendon
- Tibial plateau
- Fibular head

Portals and Approaches (Fig. 47-3)

- Inferomedial portal
- Inferolateral portal
- Additional outflow portals as needed
- Posteromedial or posterolateral approach
- Mini-arthrotomy through ipsilateral side of patellar tendon

Structures at Risk

- Posterolateral approach: peroneal nerve, lateral collateral ligament

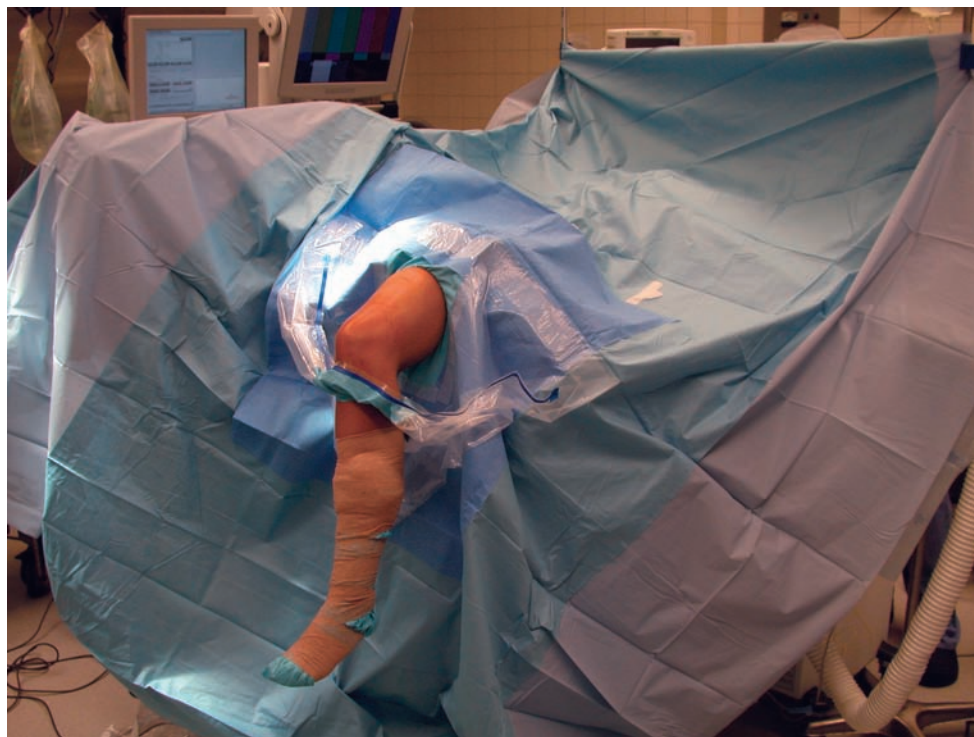


Figure 47-2 Patient positioning.

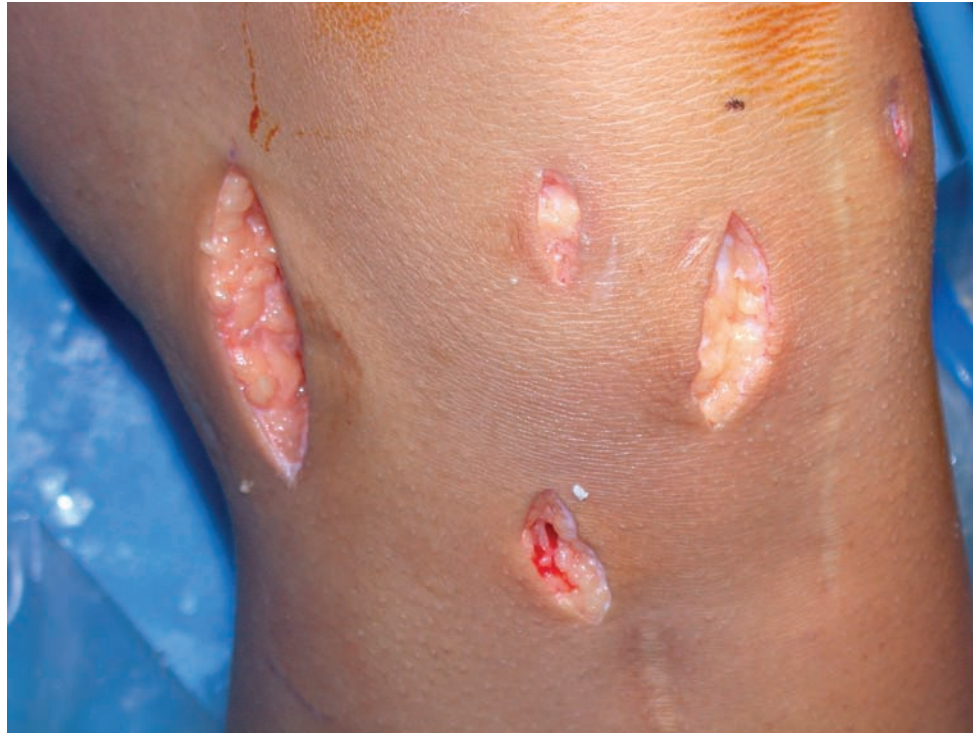

Figure 47-3 Incisions: accessory posteromedial incision (left); inferomedial and inferolateral arthroscopy portals, mini-arthrotomy for meniscal insertion (between portals); accessory incision for concomitant allograft anterior cruciate ligament reconstruction in this patient (inferior).

- Posteromedial approach: saphenous nerve, medial collateral ligament
- Mini-arthrotomy: patellar tendon

Examination Under Anesthesia and Diagnostic Arthroscopy

Examination under anesthesia should evaluate range of motion and ligamentous stability. Diagnostic arthroscopy is useful to evaluate for other intra-articular pathologic processes, such as loose bodies, ligamentous deficiency, and chondral defects.

Specific Steps (Box 47-1)

1. Arthroscopic Preparation

The initial steps for medial and lateral meniscus transplantation are similar. The remaining meniscus is débrided to a stable, 1- to 2-mm peripheral rim until punctate bleeding occurs (Fig. 47-4). The most anterior aspect of the meniscus can be excised under direct visualization by use of a No. 11 scalpel blade placed through the ipsilateral portal followed by the use of an aggressive arthroscopic shaver. The anterior and posterior horn insertion sites should be maintained because they are helpful markers during slot

Box 47-1 Surgical Steps

1. Arthroscopic preparation
2. Exposure
3. Slot preparation
4. Allograft preparation
5. Graft insertion and fixation
6. Closure

preparation. A limited notchplasty along the most inferior and posterior aspect of the ipsilateral femoral condyle allows improved visualization of the posterior horn and facilitates graft passage.

2. Exposure

A mini-arthrotomy is performed in line with the anterior and posterior horn insertion sites of the involved meniscus (see Fig. 47-3). This allows correct orientation of the slot and introduction of the graft. Depending on the surgeon's preference, the arthrotomy can be performed either directly adjacent to or through the patellar tendon in line with its fibers. An ipsilateral (either posteromedial or posterolateral) approach is required for meniscal repair (see Fig. 47-3). The incision should extend approximately one third

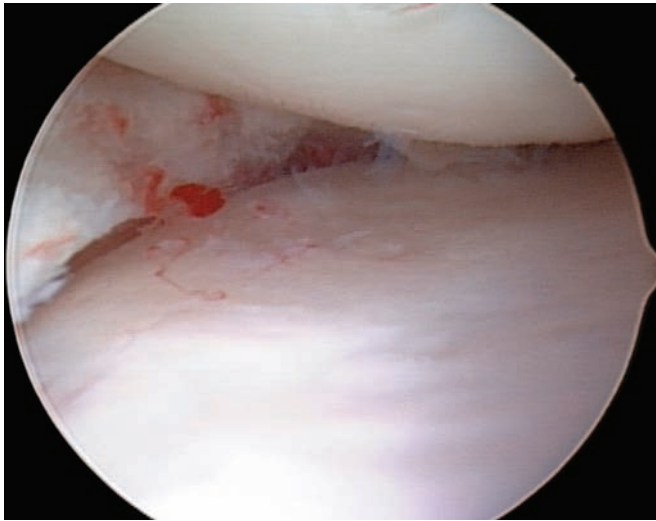


Figure 47-4 Meniscus débrided back to a stable and bleeding rim.

above and two thirds below the joint line and allow adequate exposure to protect the neurovascular structures during passage of the inside-out sutures. The ipsilateral gastrocnemius muscle–tendon junction is elevated off the posterior capsule, and a meniscal retractor is placed anterior to it. Elevation of either the iliotibial band–tensor fascia lata or sartorius fascia anteriorly allows suture tying beneath these structures to minimize the chances of capturing the knee due to soft tissue tethering.

3. Slot Preparation

Slot orientation follows the normal anatomy of the meniscus attachment sites. By use of electrocautery, the centers of the anterior and posterior horn attachment sites are connected with a line. With this line as a guide, a 4-mm bur is used to make a reference slot in the tibial plateau. Its height and width will equal the dimensions of the bur, and its alignment in the sagittal plane should parallel the slope of the tibial plateau (Fig. 47-5). Slot dimensions should be confirmed by placement of a depth gauge in the reference slot, which also measures the anteroposterior length of the tibial plateau (Fig. 47-6). With use of a drill guide, a guide pin is placed just distal and parallel to the reference slot (Fig. 47-7) and advanced to but not through the posterior cortex. The pin is subsequently overreamed with a 7- or 8-mm cannulated drill bit (Fig. 47-8), again with care taken to maintain the posterior cortex. A box cutter is then used to make a slot 7 to 8 mm wide by 10 mm deep (Fig. 47-9), which is smoothed and refined with a 7- to 8-mm rasp to ensure that the bone bridge will slide smoothly into the slot (Fig. 47-10).

4. Meniscal Allograft Preparation

This technique uses a bone bridge to secure the graft to the tibial plateau. The bone bridge is intentionally undersized by 1 mm to facilitate graft passage and to reduce the

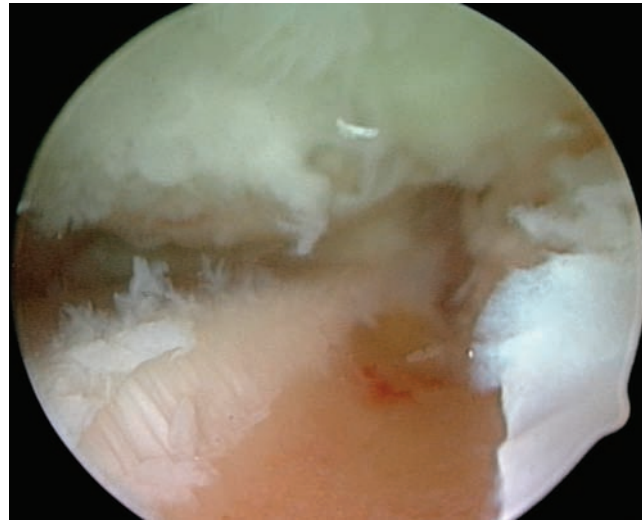


Figure 47-5 Reference slot prepared with a bur.

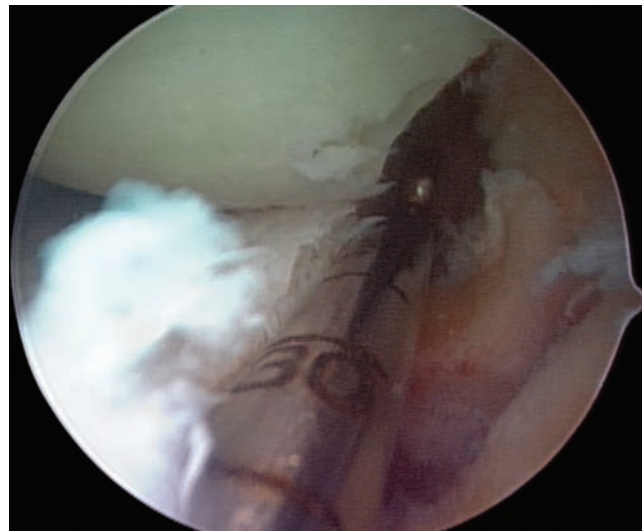


Figure 47-6 Guide probe in reference slot.

risk of inadvertent bridge fracture during insertion. The attachment sites of the meniscus are identified on the bone block, and the accessory attachments are débrided. Only the true attachment sites should remain, usually 5 to 6 mm wide. The bone bridge is then cut to a width of 7 mm and a height of 1 cm. Also, any bone extending beyond the posterior horn attachment site is removed; bone anterior to the attachment site of the anterior horn should be preserved to maintain graft integrity during insertion. A vertical mattress traction suture of No. 0 polydioxanone (PDS) is placed at the junction of the posterior and middle thirds of the meniscus (Fig. 47-11).

On occasion, the anterior horn attachment can be larger, up to 9 mm wide. If the anterior horn attachment site is wider than the intended width of the bone bridge,

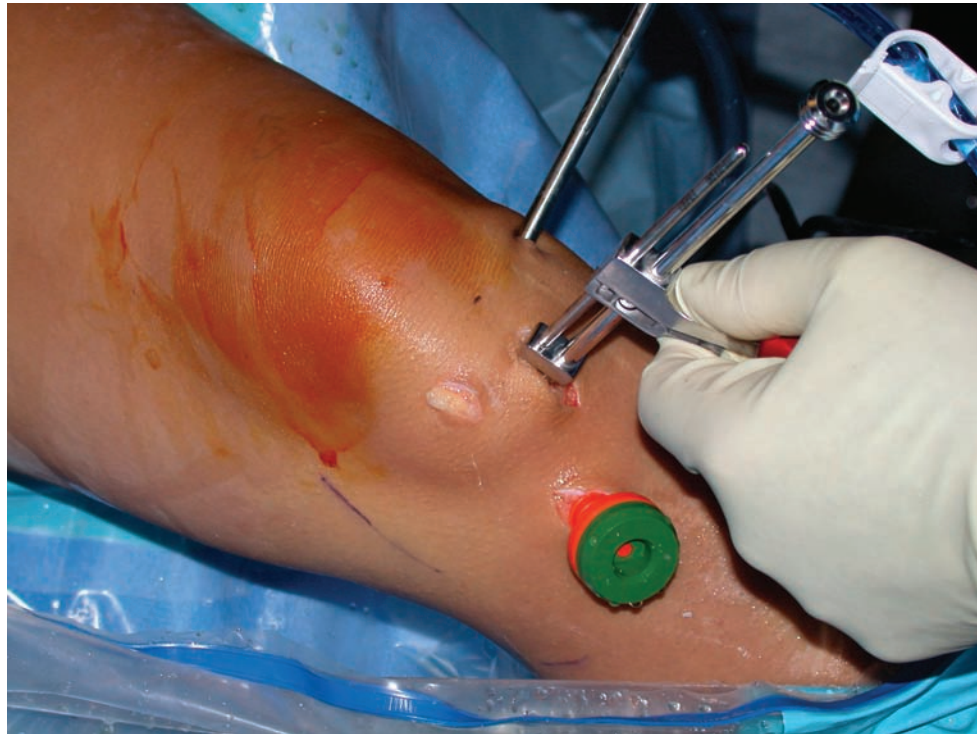


Figure 47-7 Guide pin placement.

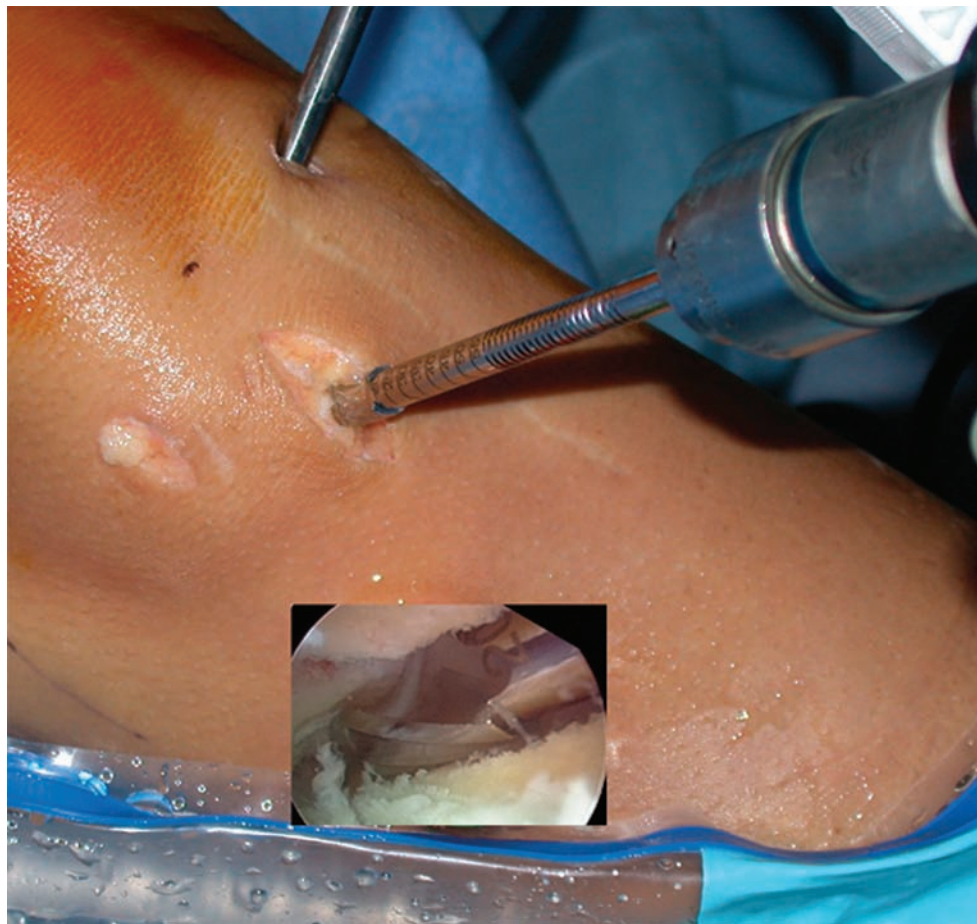


Figure 47-8 Overburring of guide pin to make the slot. *Inset:* arthroscopic view.

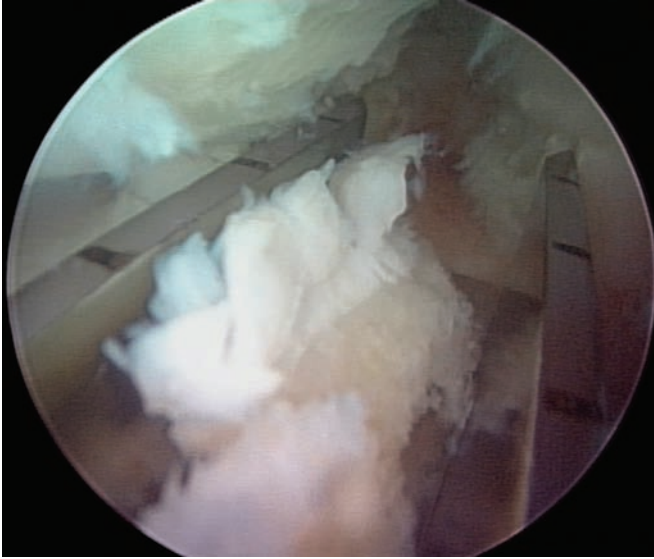


Figure 47-9 View of the box cutter connecting the superficial reference slot and deeper bur tunnel.

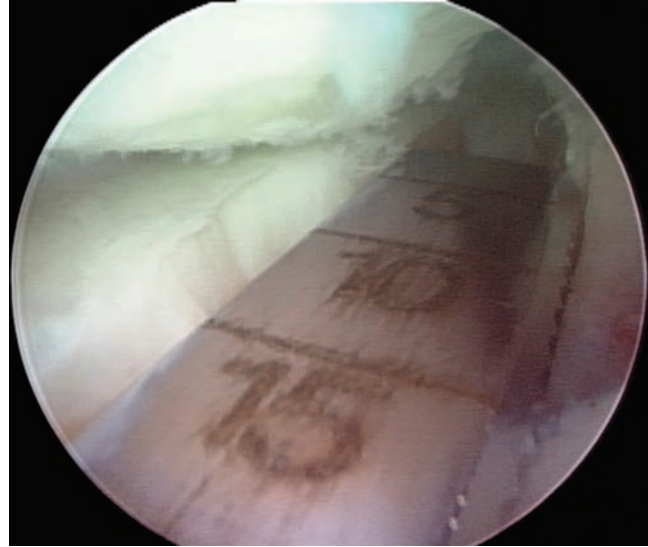


Figure 47-10 Rasping to smooth the slot.

47

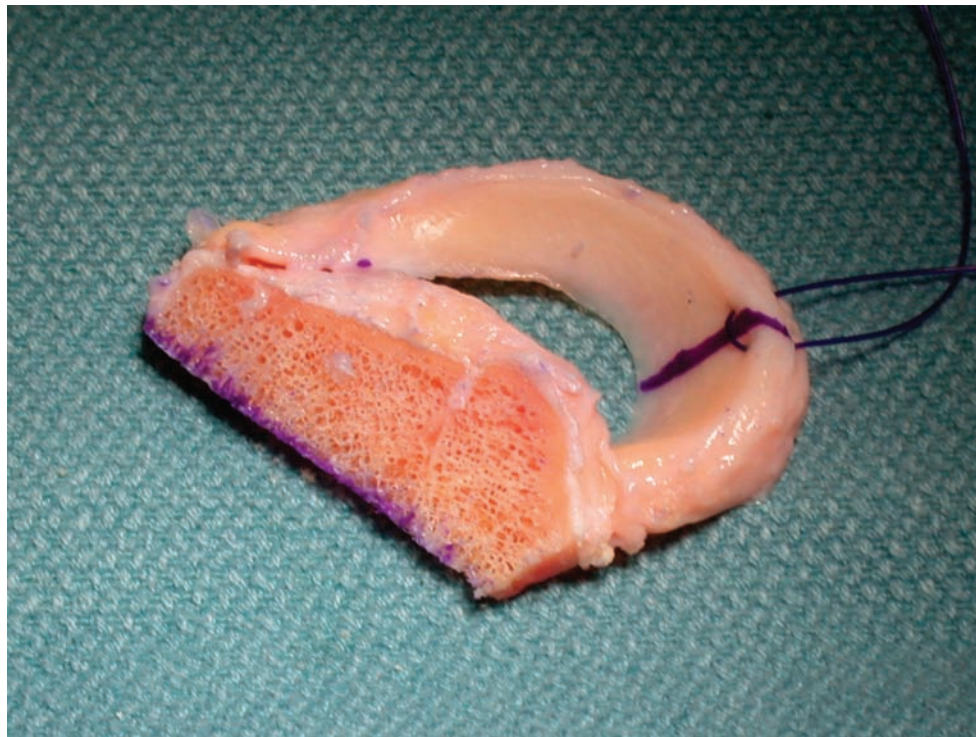


Figure 47-11 Prepared allograft with traction suture.

the attachment should be left intact, and the width of the bone bridge should be increased accordingly in the area of the anterior horn insertion only; the remainder of the bone bridge should be trimmed to 7 mm as intended. To accommodate the increased width, the corresponding area of the recipient slot should be widened accordingly.

5. Meniscus Insertion and Fixation

A single-barrel, zone-specific meniscal repair cannula placed through the contralateral portal on viewing through the ipsilateral portal is directed toward the capsular attachment site of the posterior and middle thirds of the meniscus. A long, flexible nitinol suture-passing pin is placed

through the capsule to exit the accessory posteromedial or posterolateral incision. The proximal end of the nitinol pin is then withdrawn from the anterior arthrotomy site (Fig. 47-12), the allograft traction sutures are passed through the loop of the nitinol pin, and the pin and sutures are withdrawn through the accessory incision (Fig. 47-13). With the aid of the traction sutures, the meniscal allograft is pulled into the joint through the anterior arthrotomy while the bone bridge is advanced into the tibial slot, and the meniscus is manually reduced under the condyle with a finger placed through the arthrotomy (Fig. 47-14). Appropriate valgus or varus stress to open the ipsilateral compartment aids in graft introduction and reduction. Once the meniscus is reduced, the knee is cycled to ensure proper placement and capturing by the tibiofemoral articulation, and the bone bridge is secured within the tibial slot with a bioabsorbable cortical interference screw. Finally, the graft is attached to the capsule with standard inside-out vertical mattress sutures placed equally on the dorsal and ventral meniscal surfaces (Fig. 47-15). This fixation can be supplemented with appropriate all-inside fixation devices placed most posteriorly and outside-in suture placed most anteriorly.

6. Closure

Standard closure of the arthrotomy and accessory incisions is performed.

Combined Procedures

Anterior Cruciate Ligament Reconstruction and Medial Meniscus Allograft Transplantation

- Prepare the soft tissue graft (hamstring autograft or Achilles tendon, tibialis anterior, or hamstring allograft).
- Drill tibial tunnel for anterior cruciate ligament (ACL) as oblique as possible, entering lateral aspect of tibial footprint.
- Drill femoral tunnel for ACL.
- Prepare meniscal slot as usual.
- Pass and fix femoral side of ACL graft.
- Pass meniscus and reduce soft tissue and bone components.
- Fix tibial side of ACL graft.
- Place interference screw against meniscus bridge (between ACL and most lateral aspect of bridge).
- Repair meniscus.
- Note: notching bone bridge may reduce intersection pressure of ACL graft against bone bridge.

Tibial Osteotomy and Medial Meniscus Allograft Transplantation

- Perform all aspects of meniscus transplantation first.

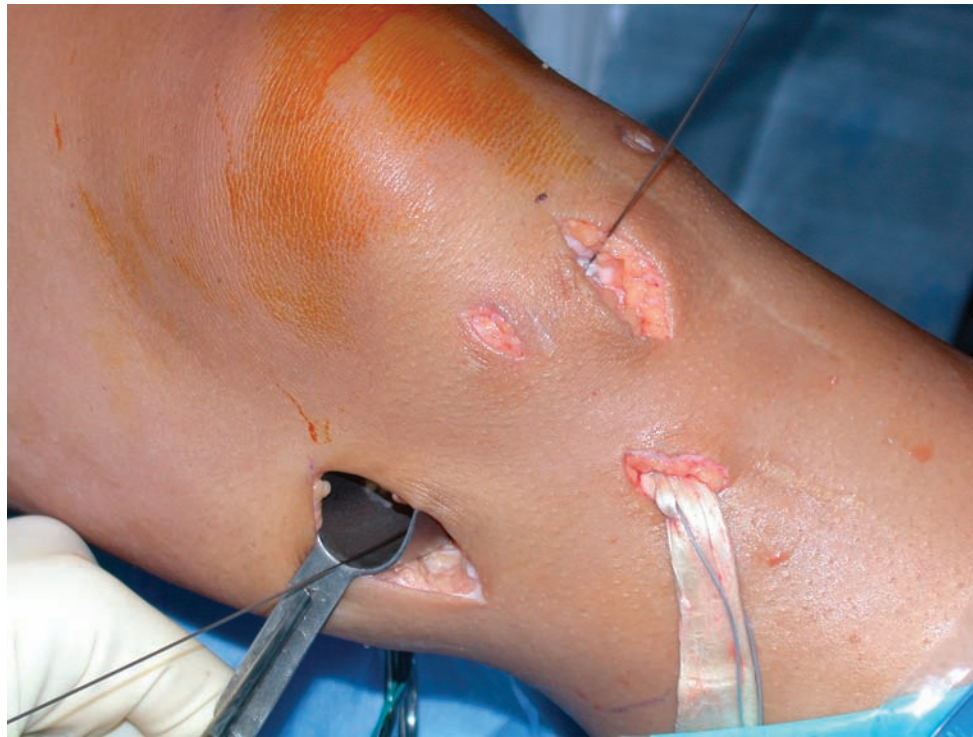

Figure 47-12 Nitinol wire in place. Also shown is an Achilles tendon allograft for anterior cruciate ligament reconstruction.

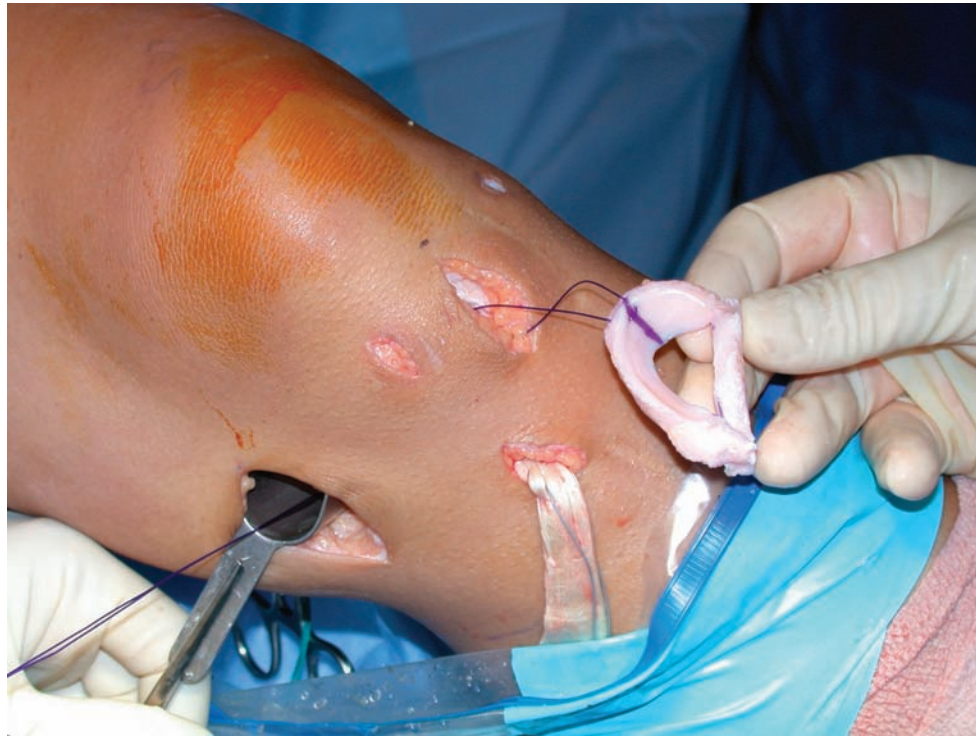

Figure 47-13 The traction sutures have been passed through the accessory incision with the nitinol pin.

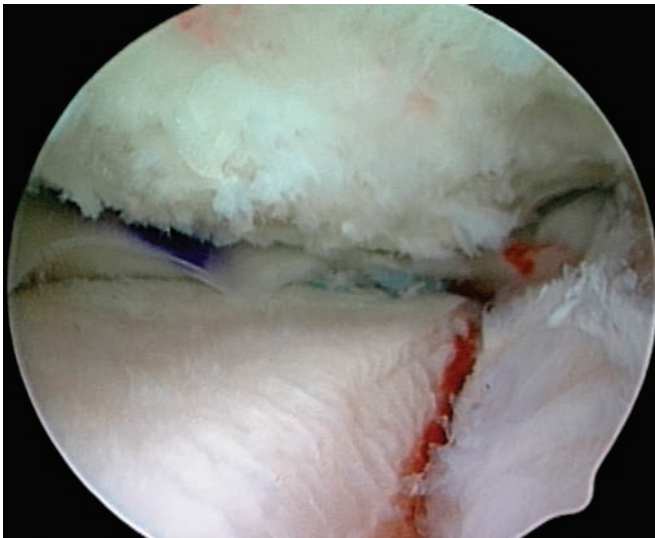


Figure 47-14 The reduced meniscus and bridge situated in the slot.

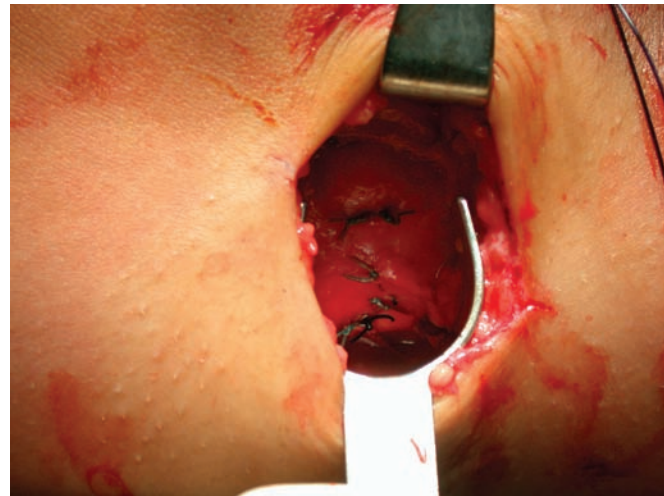


Figure 47-15 Capsular sutures for the meniscal repair as viewed through the posteromedial incision.

- Perform opening wedge osteotomy such that line of osteotomy passes at least 1.5 cm below bottom of tibial slot.

Postoperative Considerations

Follow-up

- At 7 to 10 days for suture removal and postoperative radiographs (Fig. 47-16)

Rehabilitation

- Immediate partial weight bearing is allowed in a hinged knee brace; range of motion is limited to 0 to 90 degrees of flexion.
- Non-weight-bearing flexion beyond 90 degrees is allowed immediately.
- Full weight-bearing and range-of-motion and gentle strengthening exercises are initiated at 4 weeks postoperatively.
- In-line running is permitted after 16 weeks.
- Return to full activities is permitted after 6 months, once strength has returned to more than 80% that of the contralateral leg.

Complications

Complications are those of meniscal repair:

- Incomplete healing of the meniscus repair
- Infection
- Arthrofibrosis

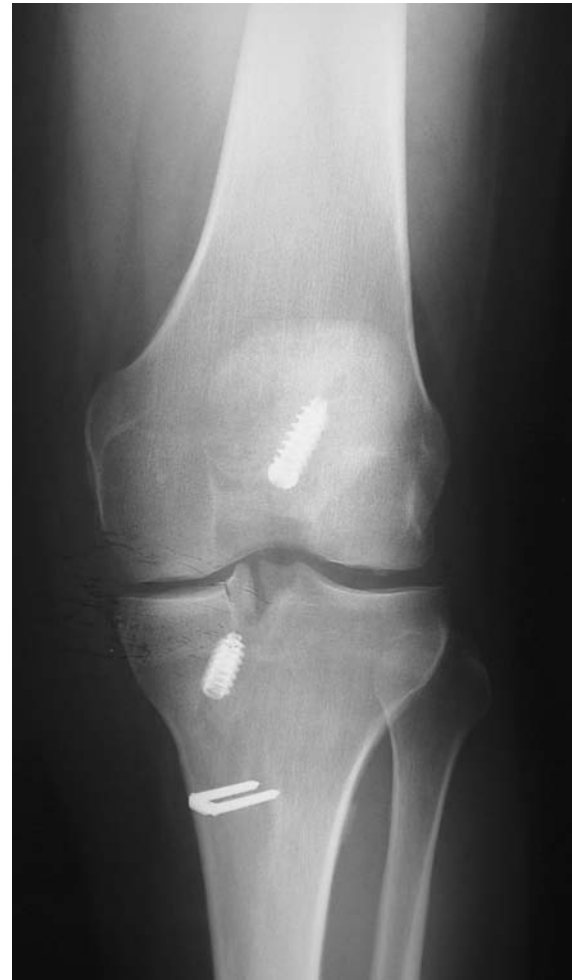

Figure 47-16 Postoperative radiograph (concomitant anterior cruciate ligament reconstruction).

- Neurovascular injury (saphenous nerve medially, peroneal nerve laterally)

Traumatic tears of the transplanted meniscus are treated with standard arthroscopic meniscal repair or partial meniscectomy as indicated.

PEARLS AND PITFALLS

- The posterior meniscal horn can be débrided more easily and more completely once the slot has been made.
- The anterior meniscal horn can be cut with a scalpel blade through the ipsilateral portal to improve débridement. Be careful not to break the blade (especially No. 11 blades).
- In making the superficial slot with the bur, sometimes the bur catches and pulls across the articular surface of the tibia. A secure hold on the bur, reversal of its direction, and strong downward pressure can minimize the risk of this occurrence.

With Concomitant ACL Reconstruction

- Achilles allograft has been helpful because it has no bone block in the tibia that would interfere with the slot for the meniscal allograft.

- Use a more vertical tibial tunnel that enters the joint more toward the contralateral side of the meniscal allograft.
- Pass the ACL graft and perform the femoral fixation, then pass the meniscus and seat the slot. Finally, fix the tibial ACL and place the interference screw adjacent to the meniscus bridge for final fixation.

With Concomitant Osteotomy

- Finish the meniscal transplantation before performing the osteotomy because introduction of the meniscus requires significant varus or valgus stress. This could jeopardize fixation if the osteotomy were to be performed first.
- In wedging open a high tibial osteotomy, a thin osteotome can be placed proximal to the wedges to support the tibial plateau; otherwise, the crack could propagate into the meniscal allograft slot, resulting in a tibial plateau fracture.

Table 47-1 Clinical Results of Meniscal Allograft Transplantation

Author	Follow-up	Outcome
Milachowski et al ¹⁰ (1989)	14-month mean	19 of 22 (86%) successful
Garrett ⁷ (1993)	2-7 years	35 of 43 (81%) successful
Noyes and Barber-Westin ¹¹ (1995)	30-month mean (range: 22-58 months)	56 of 96 (58%) failed
van Arkel and de Boer ¹⁶ (1995)	2-5 years	20 of 23 (87%) successful
Goble et al ⁸ (1996)	2-year minimum	17 of 18 (94%) successful
Cameron and Saha ² (1997)	31-month mean (range: 12-66 months)	58 of 63 (92%) successful
Carter ³ (1999)	48-month mean	45 of 51 (88%) successful
Rodeo ¹³ (2001)	2-year minimum	22 of 33 (67%) successful 14 of 16 (88%) with bone fixation 8 of 17 (47%) without bone fixation
Rath et al ¹² (2001)	5.4-year mean (range: 2-8 years)	14 of 22 (64%) successful
Verdonk et al ¹⁷ (2005)	7.2-year mean (range: 0.5-14.5 years)	10 of 61 (16%) lateral transplants failed 11 of 39 (28%) medial transplants failed
Cole et al ⁴ (2006)	33.5-month mean (range: 24 to 57 months)	41 of 45 (91%) successful 85% of successful transplants would have surgery again

Results

After meniscal allograft transplantation, good to excellent results are achieved in nearly 85% of cases, and patients demonstrate a measurable decrease in pain and increase

in activity level (Table 47-1). The risk of graft failure appears greatest with irradiated grafts, grade III to IV osteoarthritic changes, and residual malalignment or instability.

References

- Alford W, Cole BJ. The indications and technique for meniscal transplant. *Orthop Clin North Am* 2005;36:469-484.
- Cameron JC, Saha S. Meniscal allograft transplantation for unicompartmental arthritis of the knee. *Clin Orthop* 1997;337:164-171.
- Carter TR. Meniscal allograft transplantation. *Sports Med Arthrosc Rev* 1999;7:51-62.
- Cole BJ, Dennis MG, Lee SJ, et al. Prospective evaluation of allograft meniscus transplantation: a minimum 2-year follow-up. *Am J Sports Med* 2006;34:919-927.
- Cole BJ, Rodeo S, Carter T. Allograft meniscus transplantation: indications, techniques, results. *J Bone Joint Surg Am* 2002;84:1236-1250.
- Farr J, Meneghini RM, Cole BJ. Allograft interference screw fixation in meniscus transplantation. *Arthroscopy* 2004;20:322-327.
- Garrett JC. Meniscal transplantation: a review of 43 cases with two to seven year follow-up. *Sports Med Arthrosc Rev* 1993;1:164-167.
- Goble EM, Kane SM, Wilcox TR, Doucette SA. Meniscal allografts. In McGinty JB, Caspari RB, Jackson RW, Poehling GG, eds. *Operative Arthroscopy*. Philadelphia, Lippincott-Raven, 1996:317-331.
- Graf KW, Sekiya JK, Wojtys EM. Long-term results following meniscal allograft transplantation: minimum eight and one half-year follow-up. *Arthroscopy* 2004;20:129-140.
- Milachowski KA, Weismeyer K, Wirth CJ. Homologous meniscus transplantation: experimental and clinical results. *Int Orthop* 1989;13:1-11.
- Noyes FR, Barber-Westin SD. Irradiated meniscus allografts in the human knee: a two to five year follow-up. *Orthop Trans* 1995;19:417.
- Rath E, Richmond J, Yassir W, et al. Meniscal allograft transplantation: two to eight year results. *Am J Sports Med* 2001;29:410-414.
- Rodeo SA. Current concepts: meniscus allografts—where do we stand? *Am J Sports Med* 2001;29:246-261.
- Sekiya JK, Giffin RJ, Irrgang JJ, et al. Clinical outcomes following combined meniscal allograft transplantation and anterior cruciate ligament reconstruction. *Am J Sports Med* 2003;31:896-906.
- Sekiya JK, West RV, Groff YJ, et al. Clinical outcomes following isolated lateral meniscal allograft transplantation. *Arthroscopy* 2006;22:771-780.
- van Arkel ERA, de Boer HH. Human meniscal transplantation: preliminary results at 2- to 5-year follow-up. *J Bone Joint Surg Br* 1995;77:589-595.
- Verdonk PC, Demurie A, Almqvist KF, et al. Transplantation of viable meniscal allograft. Survivorship analysis and clinical outcome of one hundred cases. *J Bone Joint Surg Am* 2005;87:715-724.
- Yoldas EA, Sekiya JK, Irrgang JJ, et al. Arthroscopically assisted meniscal allograft transplantation with and without combined anterior cruciate ligament reconstruction. *Knee Surg Sports Traumatol Arthrosc* 2003;11:173-182.

