

Can Anatomic Femoral Tunnel Placement Be Achieved Using a Transtibial Technique for Hamstring Anterior Cruciate Ligament Reconstruction?

Eric J. Strauss,* MD, Joseph U. Barker,* MD, Kevin McGill,* MPH, Brian J. Cole,* MD, MBA, Bernard R. Bach Jr.,* MD, and Nikhil N. Verma,*[†] MD

Investigation performed at Rush University Medical Center, Chicago, Illinois

Background: Recent studies have emphasized the importance of anatomic tunnel placement during anterior cruciate ligament (ACL) reconstruction in an effort to restore normal knee kinematics and stability. Secondary to the constraints imposed by a coupled drilling technique, the ability to achieve an anatomic femoral tunnel during transtibial hamstring ACL reconstruction may be limited.

Hypothesis: The size limitations imposed by the small-diameter tibial tunnel used in hamstring ACL reconstruction would preclude the ability to place an anatomic femoral tunnel.

Study Design: Descriptive laboratory study.

Methods: In a descriptive laboratory study, fresh-frozen human cadaveric knees fixed at 90° of flexion were dissected to expose the centers of the native femoral and tibial ACL insertions. The geometry and location of each insertion were evaluated. Using a standardized starting point, tibial tunnels were drilled to the center of the tibial insertion using an 8-mm reamer. Next, a 6-mm over-the-top guide was used to position as close as possible to the anatomic femoral ACL insertion on the lateral wall, and femoral tunnels were drilled with the 8-mm reamer. For each tunnel, the location, geometry, and percentage overlap with the native insertion site were evaluated using a 3-dimensional laser scanner.

Results: The reamed tibial tunnel was central within the insertion site, occupying $40.4\% \pm 2.0\%$ of the native tibial insertion. Transtibial drilling resulted in femoral tunnels that were superior and posterior compared with the native femoral insertion. The femoral tunnel had a mean \pm SD overlap of $30.0\% \pm 12.6\%$ with the femoral insertion, with the center of the tunnel 7.6 ± 0.5 mm from the center of the native ACL femoral insertion.

Conclusion: Based on our data using our specific starting point, during hamstring ACL reconstructions, the constraints imposed by a coupled drilling technique result in nonanatomic femoral tunnels that are superior and posterior to the native femoral insertion.

Clinical Relevance: Anatomic femoral tunnel placement during hamstring ACL reconstructions may not be possible using a coupled, transtibial drilling approach.

Keywords: anterior cruciate ligament; transtibial technique; hamstring ACL reconstruction

Secondary to an improved understanding of normal intra-articular knee anatomy and kinematics coupled with advances in surgical instrumentation and technique, ACL reconstruction has evolved considerably over the

past 2 decades.^{5,14} Although double-bundle ACL reconstruction has garnered recent interest, the single-bundle endoscopic transtibial approach remains the gold standard and most commonly used operative technique among orthopaedic surgeons in the United States.^{7,17} In an effort to replicate the function of both the anteromedial and posterolateral bundles of the ACL with a single-bundle reconstruction, the surgical goal is to create a single tunnel positioned within the anatomic center of the native femoral footprint.

Proper positioning of the femoral tunnel during ACL reconstruction is paramount, with nonanatomic tunnel placement cited as the most common cause of clinical failure secondary to pain and persistent instability.^{3,10,23} Recent clinical and biomechanical studies have questioned

[†]Address correspondence to Nikhil N. Verma, MD, Division of Sports Medicine, Rush University Medical Center, 1611 West Harrison St, Chicago, IL 60612 (e-mail: nverma@rushortho.com).

*Division of Sports Medicine, Rush University Medical Center, Chicago, Illinois.

The authors declared that they had no conflicts of interest in their authorship and publication of this contribution.

the ability of the transtibial operative technique to adequately create an anatomic femoral tunnel secondary to the dependence and limitation of femoral tunnel positioning on the tibial tunnel. Studies by Pearle et al¹⁸ and Brophy et al⁸ demonstrate that single-bundle reconstructions performed with a transtibial technique have a tendency for vertical graft orientation secondary to the constraints imposed by the tibial tunnel. Although modifications to the conventional transtibial technique such as posterolateral beveling of the tibial tunnel and using a more colinear, proximal, and medial tibial starting point have been used to improve femoral tunnel positioning, these have been employed primarily with the 10- or 11-mm tunnels created for bone-patellar tendon-bone reconstructions.^{12,19} At the present time, few data are available on whether these operative technique modifications are applicable to the smaller tunnel sizes (7-8 mm) used for hamstring ACL reconstruction.

The purpose of the current cadaveric study was to define the location of the center of the anatomic ACL tibial and femoral insertions relative to standard intraoperative landmarks using 3-dimensional imaging and investigate whether an anatomic femoral tunnel could be created with a transtibial surgical technique using the smaller tunnel sizes typically used during hamstring ACL reconstruction. We hypothesized that the anatomic center of both the femoral and tibial ACL footprints could be precisely located and related to available intraoperative structures and that the size limitations imposed by the small-diameter tibial tunnel used in hamstring ACL reconstruction would preclude the ability to place an anatomic femoral tunnel.

METHODS

Seven fresh-frozen adult knee specimens (mid-femur to mid-tibia, 4 right, 3 left) without ligamentous injury or significant degenerative joint disease were obtained and thawed over a 24-hour period before testing. There were 4 male specimens and 3 female specimens with a mean age of 53.7 years. Each femur and tibia was mounted at 90° of flexion using a custom testing apparatus (Figure 1). Once mounted, each specimen had its extra-articular soft tissues removed along with the patella and patellar tendon. The medial femoral condyle was then carefully removed using an oscillating saw exposing the intercondylar notch. Next, the ACL was sharply removed with a #10 scalpel, leaving the femoral and tibial insertion sites intact for subsequent analysis.

Evaluation of the Anterior Cruciate Ligament Insertion Sites

The anterior-posterior and medial-lateral dimensions of both the femoral and tibial insertion sites of the ACL were measured using a digital caliper with a resolution of 0.1 mm and an accuracy of 0.05 mm (Avenger 6" Digital Caliper; Avenger Products, Boulder City, Nevada). The

periphery and center of each insertion site were then marked using an electrocautery device allowing for the digitization of each site with a NextEngine 3-dimensional desktop scanner (NextEngine, Inc, Santa Monica, California) (Figure 2). The insertion sites were also sprayed lightly with an aerosol powder to decrease glare and enhance the accuracy of the scan, as recommended by the manufacturer.

Scans were initially viewed using the Scanstudio HD (NextEngine, Inc) and later analyzed using Rapidform Explorer software (INUS Technology, Seoul, Korea) (Figures 3 and 4). According to the manufacturer, the NextEngine scanner has a resolution of 0.005 inches when used on the macro setting with the object of interest placed 6.5 inches from the face of the scanner. We internally assessed the accuracy of the scanner by creating a 3-dimensional scan of the digital caliper while measuring an object of known size and then verified that the dimensions of the object, as measured by the digital caliper, matched the dimensions as measured by the Rapidform Explorer software.

The femoral and tibial native insertions on the digitized images were outlined, and then the surface areas and centroids of the insertions along with the relative distances between them were measured. Additional anatomic measurements were then made using both the digital caliper and the digitized, scanned image for each insertion site. For the tibial insertion of the ACL, measurements included the distance to the anterior aspect of the posterior cruciate ligament and the distance to the posterior aspect of the anterior horn of the lateral meniscus. For the femoral insertion of the ACL, measurements included the distance to the posterior wall of the intercondylar notch, the distance to the roof of the intercondylar notch, the distance to the inferior aspect of the lateral femoral condyle, and the distance to the anterior aspect of the lateral femoral condyle.

Creation of the Tibial Tunnel

Using a standardized starting point found in a previous study to allow anatomic femoral tunnel position with transtibial drilling using an 11-mm tibial tunnel, a guide pin was inserted using a tip-aiming device.¹⁹ In this previous cadaveric laboratory study, a digitizer and computer navigation were used to determine a starting point that would result in zero mismatch when using a bone-patellar tendon-bone graft reconstruction. As many orthopaedic surgeons use their usual bone-patellar tendon-bone surgical approach for hamstring reconstructions, this zero-mismatch starting point was chosen to allow for consistency in the current laboratory experiment while reproducing a clinically relevant situation. This starting point was 33.0 mm below the edge of the medial plateau, 5.7 mm above the superior border of the pes anserinus tendons, 8.3 mm posterior to the medial margin of the tibial tubercle, and 23.1 mm from the anterior margin of the medial collateral ligament (Figure 5). The tip-aiming device allowed for guide pin placement in the center of the native ACL

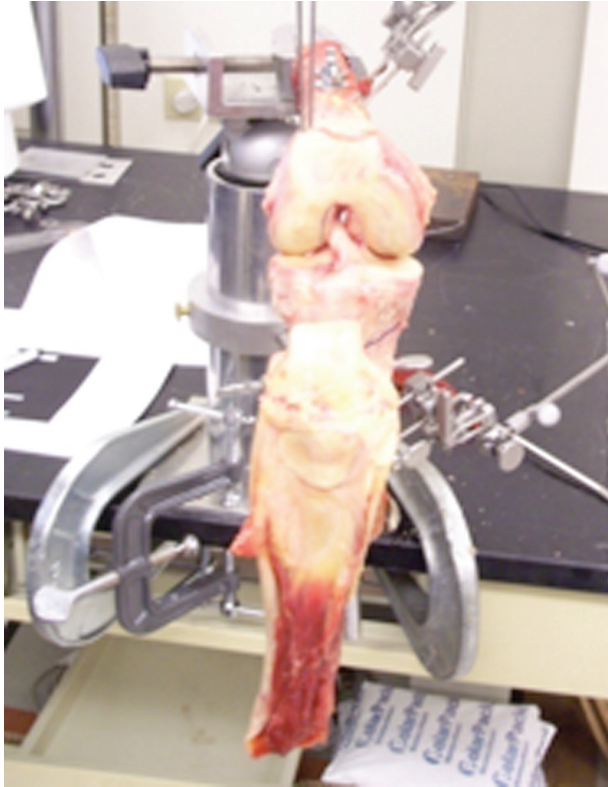

Figure 1. Adult knee specimen mounted at 90° of flexion using a custom testing apparatus.

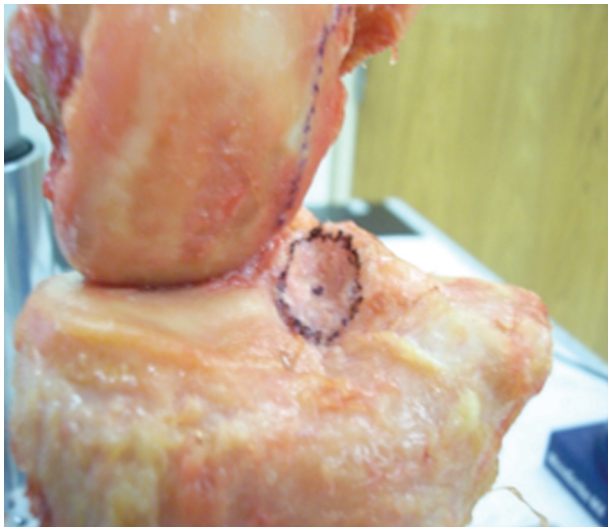

Figure 2. Digital image of a mounted specimen after periphery of the anterior cruciate ligament is marked, in addition to calculated center of the footprint, before guide pin placement.

insertion. The guide pin was then overreamed using an 8-mm cannulated reamer (Arthrex, Inc, Naples, Florida).

The dimensions of the reamed tibial tunnel were then measured using the digital caliper and the specimen was

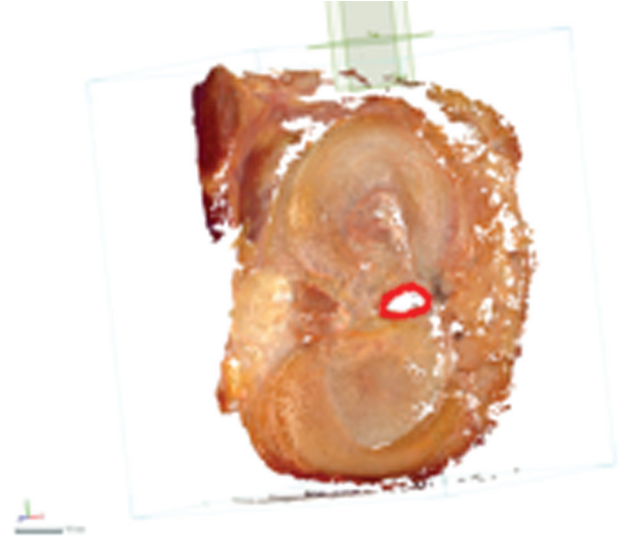


Figure 3. Image created by NextEngine 3-dimensional desktop scanner before calculation of the dimension of the ACL tibial footprint.



Figure 4. Image created by NextEngine 3-dimensional desktop scanner before calculation of the dimension of the ACL femoral footprint.

rescanned with the 3-dimensional optical scanner. The digitized, scanned image was then assessed for tunnel dimensions and surface area. The percentage of coverage of the native ACL tibial insertion site by the reamed tibial tunnel was then calculated.

Creation of the Femoral Tunnel

A 6-mm offset guide (over-the-top guide) was then inserted through the reamed tunnel to simulate a transtibial ACL reconstruction. Once the tip of the guide was hooked

around the posterior wall of the intercondylar notch, the guide was maximally rotated in an attempt to place the femoral tunnel guide pin as far inferior on the lateral wall of the intercondylar notch as possible. The guide pin was then inserted and the offset guide removed. The position of the guide pin was then assessed with respect to the native center point of the ACL femoral insertion. The digital caliper and 3-dimensional optical scanner were used to measure the distances between the guide pin and the posterior wall of the intercondylar notch, the roof of the intercondylar notch, the inferior aspect of the lateral femoral condyle, and the anterior aspect of the lateral femoral condyle.

The guide pin was then overreamed transtibially using an 8-mm reamer (Acorn reamer; Arthrex, Inc) followed by removal of the guide pin. The dimensions of the reamed femoral tunnel were then measured using the digital caliper in addition to measurement of the distances between the reamed tunnel and the posterior wall of the intercondylar notch, the roof of the intercondylar notch, the inferior aspect of the lateral femoral condyle, and the anterior aspect of the lateral femoral condyle. The specimen was then rescanned with the 3-dimensional optical scanner, allowing for these measures to be repeated using the digitized, scanned image in addition to an assessment of the reamed tunnel's surface area. The percentage overlap of the reamed femoral tunnel and the native ACL femoral insertion site was then calculated.

Data Analysis

For each measurement at each stage of the experimental model, the mean of the values obtained by each assessment method (caliper and 3-dimensional optical scanner) was recorded in millimeters. Mean values for the series of 7 specimens were calculated \pm standard deviations.

RESULTS

The overall surface area of the ACL tibial footprint was $137.8 \pm 2.6 \text{ mm}^2$ with the longest dimension in the anterior-medial to posterior-lateral plane ($15.6 \pm 0.4 \text{ mm}$). The width (anterior-lateral to posterior-medial) was $11.1 \pm 0.4 \text{ mm}$. The distance from the most posterior aspect of the ACL footprint to the anterior PCL was $5.4 \pm 0.4 \text{ mm}$ (range, 4.7-5.8 mm) and from the center aspect of the ACL footprint to the anterior PCL was $13.3 \pm 0.4 \text{ mm}$ (range, 12.7-13.7 mm). In regards to the anterior horn of the lateral meniscus, the periphery was $4.9 \pm 1.1 \text{ mm}$ (range, 4.1-5.7 mm), and the center of the footprint was $2.7 \pm 0.3 \text{ mm}$ (range, 2.2-3.1 mm) (Figure 6A).

After the tibial tunnel was reamed with an 8-mm reamer, the reamed tibial tunnel had a longest dimension in the anterior-medial to posterior-lateral dimension of $8.1 \pm 0.1 \text{ mm}$ and shortest dimension of $7.6 \pm 0.2 \text{ mm}$. The overall surface area of the reamed tunnel was $55.9 \pm 2.3 \text{ mm}^2$ with a percent overlap with the native ACL insertion of $40.4\% \pm 2.0\%$.

The longest dimension for the ACL femoral footprint was proximal-posterior to distal-anterior and measured $14.4 \pm 0.3 \text{ mm}$. The shortest dimension was $10.0 \pm 1.2 \text{ mm}$. The overall surface area was $100.6 \pm 2.3 \text{ mm}^2$. The distance from the periphery of the insertion to the back wall was $2.9 \pm 0.3 \text{ mm}$ (range, 2.6-3.4 mm), to the roof (defined as the 12 o'clock position) was $3.2 \pm 0.8 \text{ mm}$ (2.7-3.8 mm), to the inferior cartilage of the lateral femoral condyle was $2.6 \pm 0.8 \text{ mm}$ (2.2-2.9 mm), and to the anterior wall was $7.9 \pm 0.4 \text{ mm}$ (7.3-8.4 mm) (Figure 6B).

In comparing the calculated center of the native femoral ACL footprint to the position of the transtibial guide pin prior to reaming, there was overall a $7.6 \pm 0.5\text{-mm}$ distance with the transtibial guide pin being located superior and posterior to the native center. Specifically, the native center was $8.7 \pm 1.2 \text{ mm}$ from the back wall compared with $5.7 \pm 0.5 \text{ mm}$ for the guide pin. Distance to the roof (12 o'clock position) was $8.6 \pm 0.4 \text{ mm}$ for the native center compared with $4.5 \pm 0.7 \text{ mm}$ for the guide pin. Additional comparisons between the native ACL femoral center to the transtibial guide pin location were $6.9 \pm 1.3 \text{ mm}$ vs $8.0 \pm 0.5 \text{ mm}$ for the distance to the inferior cartilage and $15.2 \pm 0.7 \text{ mm}$ vs $21.8 \pm 1.5 \text{ mm}$ for the distance to the anterior wall, respectively (Table 1).

After being reamed with an 8-mm reamer, the overall surface area of the femoral tunnel was calculated to be $48.1 \pm 1.6 \text{ mm}^2$. The longest dimension was proximal-posterior to distal-anterior and measured $8.0 \pm 0.1 \text{ mm}$, whereas the shortest dimension was $7.5 \pm 0.2 \text{ mm}$. The percent overlap with the native ACL femoral insertion was $30.0\% \pm 12.6\%$, overlapping only the most posterior-superior portion (Figure 7). The respective distances from the periphery of the tunnel to intra-articular landmarks were $2.6 \pm 0.2 \text{ mm}$ to the back wall, $1.9 \pm 0.4 \text{ mm}$ to the roof (12 o'clock position), $5.9 \pm 0.8 \text{ mm}$ to the inferior cartilage, and $16.4 \pm 1.6 \text{ mm}$ to the anterior wall.

DISCUSSION

The principle finding of this study is that transtibial drilling with smaller (8-mm) tunnel sizes results in nonanatomic femoral tunnel placement in a posterior, superior position compared with the native insertion. In addition, the previous emphasis on minimizing back wall size when drilling a femoral tunnel may be misguided, as the native center of the femoral ACL insertion is located an average of 8.7 mm from the posterior back wall of the femur. Thus, if a guidewire is to be placed at the center of the femoral insertion, an 8-mm offset guide would be required.

The conventional transtibial single-bundle technique for ACL reconstruction has been the gold standard for the past 2 decades, resulting in good to excellent outcomes in 80% to 95% of cases.^{1,7} Despite this high level of success, a growing body of literature has questioned whether this technique sufficiently re-creates the anatomy and function of the native ACL.^{7,16,22} Although anteroposterior stability is typically restored with a single-bundle reconstruction, rotational instability and a persistent pivot shift may still

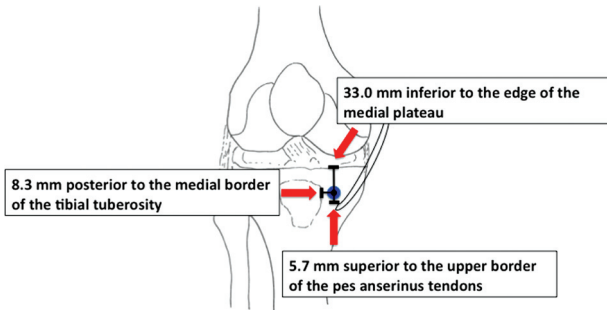


Figure 5. Standardized starting point for creation of the tibial tunnel, 33.0 mm below the edge of the medial plateau, 5.7 mm above the superior border of the pes anserinus tendons, 8.3 mm posterior to the medial margin of the tibial tubercle, and 23.1 mm from the anterior margin of the medial collateral ligament.

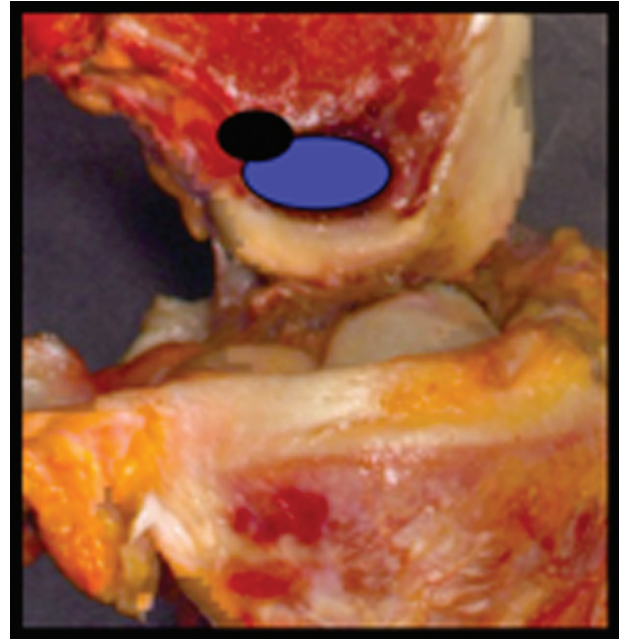


Figure 7. Reamed femoral tunnel positioned posterior and superior relative to the native femoral ACL footprint.

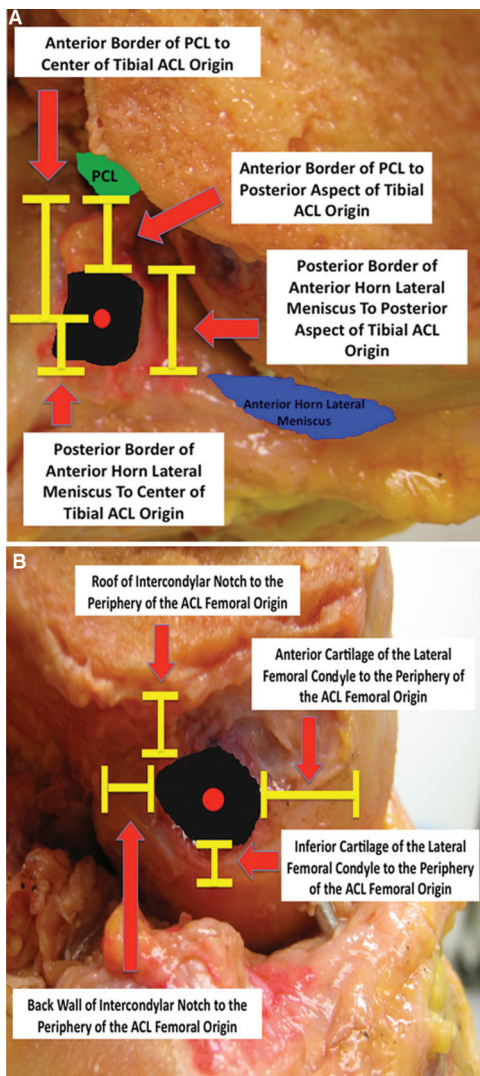


Figure 6. Measurement of distances to intra-articular landmarks relative to the tibial (A) and femoral (B) ACL origins.

be present postoperatively if the anatomic footprints of the native ligament are not accurately replicated.^{5-7,16,18} Recent biomechanical studies have suggested that grafts positioned centrally within the native tibial footprint and low on the lateral wall of the intercondylar notch in the center of the native femoral footprint will more closely re-create the normal ligament's stability and graft-tension relationship than traditionally oriented single-bundle grafts.^{16,20}

The primary criticism of the transtibial approach during ACL reconstruction has been the ability of the surgeon to obtain an anatomic femoral tunnel position through the tibia. The limitations of linear surgical instrumentation coupled with the constraints imposed by the tibial tunnel have often led to femoral tunnels that are vertical and non-anatomic.^{4,6,9,18} The implications of a vertical graft position have been reported in recent clinical and biomechanical studies, demonstrating less effective resistance to applied rotatory loads and lower International Knee Documentation Committee (IKDC) knee scores compared with lower, more horizontally oriented reconstructions.^{13,16} Although modifications to the conventional surgical technique such as posterolateral beveling of the tibial tunnel and using a more colinear, proximal, and medial starting point have been used to improve femoral tunnel positioning, these have been employed primarily with the 10- or 11-mm tunnels created for bone-patellar tendon-bone reconstructions.^{12,19} We have previously evaluated the ability to achieve anatomic femoral tunnel placement with a transtibial technique using an 11-mm tibial tunnel. We found that using a more proximal starting point on the tibia resulted in 88% coverage of the native femoral footprint by the femoral tunnel. It is likely that tibial size in comparison with the offset aimer allows for

TABLE 1
Center of ACL Femoral Footprint vs Transtibial Guide Pin Position (in millimeters, mean \pm standard deviation)

	Center of Femoral Footprint	Transtibial Guide Pin Position
Center of footprint to back wall	8.7 \pm 1.2	5.7 \pm 0.5
Center of footprint to roof (12 o'clock position)	8.6 \pm 0.4	4.5 \pm 0.7
Center of footprint to inferior articular margin of lateral femoral condyle	6.9 \pm 1.3	8.0 \pm 0.5
Center of footprint to anterior wall of lateral femoral condyle	15.2 \pm 0.7	21.8 \pm 1.5
Distance of transtibial guide pin to center of femoral footprint		7.6 \pm 0.5

rotation of the femoral aimer into a more distal femoral position. Our hypothesis for the present study was that when drilling smaller tunnel sizes typically used during hamstring reconstruction, the smaller tibial tunnel size would limit appropriate access to the anatomic femoral position. At the present time, few data are available on whether these operative technique modifications are applicable to the smaller tunnel sizes used for hamstring ACL reconstruction.

Data from the present cadaveric study demonstrate that when using the smaller tunnel size typically utilized with hamstring ACL reconstructions, the constraints of the tibial tunnel limit the surgeon's ability to create an anatomic femoral tunnel when drilling transtibially. Despite using a tibial starting point that provided a more colinear approach to the femoral footprint, transtibial drilling of the femoral tunnel using an over-the-top drill guide had a tendency to place the tunnel in a superior and posterior position relative to the center of the native footprint. Despite best efforts to bring the over-the-top guide as low and lateral as possible before guide pin placement, the resultant reamed femoral tunnel had a mean overlap of only 30% with the femoral footprint. This limited coverage is likely due to more vertical tunnel placement in combination with the smaller oblique tunnel aperture that is created with a smaller size reamer in comparison with larger sizes used during bone-patellar tendon-bone reconstructions. Because hamstring grafts provide a relatively smaller restoration of the ACL footprint compared to bone-patellar tendon-bone grafts, central tunnel placement is more critical¹⁵; this study suggests that to achieve an anatomic femoral tunnel, an alternative to the transtibial approach must be used.

In addition, previous recommendations for femoral tunnel placement when performing transtibial ACL reconstruction have emphasized posterior placement of the femoral tunnel by minimizing the size of offset aimer.²¹ The goal was to create a 1- to 2-mm back wall to allow for adequate graft fixation. On the basis of the measurements of the current study, this emphasis on posterior placement appears misguided. The native center insertion point of the femoral ACL footprint is nearly 9 mm anterior to the back wall of the femoral notch. Thus, if a 6-mm offset guide is selected and an 8-mm tunnel is created, the resulting guidewire would be in a posterior position compared with the native center insertion site. The results of this study would suggest that a more anterior guidewire position is desirable to achieve anatomic tunnel placement.

In an attempt to better re-create the anatomic femoral footprint, some authors have advocated using an anteromedial portal for femoral tunnel drilling. In a recent cadaveric study, Gavriilidis et al¹¹ demonstrated that tunnels drilled through the anteromedial portal more accurately re-created the native femoral footprint than those drilled through the standard transtibial technique. Improved positioning of the femoral tunnel using an anteromedial portal approach was confirmed radiographically by Dargel et al⁹ in their series of 70 patients. The authors demonstrated that in patients whose ACL reconstruction was performed with a transtibial technique, the femoral tunnel was in the ideal position in 57% of cases compared to 86% of cases when the anteromedial approach was used. Clinical benefits of improved femoral tunnel placement with an anteromedial portal drilling technique were reported by Alentorn-Geli et al² in their retrospective review of 47 patients whose ACL reconstructions were performed using either the standard transtibial technique (21 cases) or the anteromedial portal approach (26 cases). In that study, patients in the anteromedial portal group had significantly better anteroposterior and rotational knee stability compared with those in the conventional transtibial group, in addition to higher postoperative IKDC knee scores and a shorter time to return to athletic activity.

Limitations of the current study include its use of a relatively small number of specimens and its static evaluation of the ACL. Although we chose 90° of flexion as the most practical position to evaluate the ACL reconstruction, the potential biomechanical implications of a normally dynamic ligament cannot fully be elucidated from a study design that employs a single knee position. However, we believe that our findings are clinically applicable as many surgeons keep the knee in approximately 90° of flexion during drilling of their tunnels for ACL reconstruction. We are unable to comment on whether different knee flexion angles would have resulted in a more anatomic femoral tunnel placement as no other position was tested. In addition, the purpose of this study was to assess the anatomic position of tunnels in relation to normal ACL footprints, not the biomechanical performance of the reconstruction. In addition, in our experimental model, we used a standardized tibial starting point for creation of the tibial tunnel, which was based on previous work in our laboratory for optimization of tunnel positioning using bone-patellar tendon-bone graft reconstructions. Although a slightly more proximal and medial starting point may improve transtibial access to the native femoral insertion,

limitations imposed by the skin incision for hamstring harvest and concern for fracture into the medial tibial plateau limit the applicability of significant changes in the starting point position. In addition, we believe that our experimental model accurately replicated the common current practice of surgeons, where typical landmarks for bone-patellar tendon-bone reconstructions are applied to hamstring reconstructions.

CONCLUSION

Anatomic placement of the femoral tunnel during ACL reconstruction is paramount, enabling the surgeon to restore both anteroposterior and rotational stability to the injured knee. Findings from the current study using our specific starting point demonstrate that when using the smaller tunnels necessary for hamstring graft reconstruction, the transtibial drilling technique does not allow the surgeon to position the femoral tunnel within the native femoral footprint. The constraints imposed by the small tibial tunnels lead to femoral tunnels that are superior and posterior to the center of the femoral footprint with a transtibial drilling technique. Despite best efforts to rotate the over-the-top guide to improve guide pin positioning, resultant femoral tunnels had a mean 30% overlap with the native femoral insertion site. Future studies are needed to evaluate whether an alternative method such as an independent drilling technique through the anteromedial portal can improve the likelihood of anatomic femoral tunnel positioning when using the smaller tunnel sizes necessary for hamstring ACL reconstruction.

REFERENCES

1. Aglietti P, Buzzi R, Zaccherotti G, De Biase P. Patellar tendon versus doubled semitendinosus and gracilis tendons for anterior cruciate ligament reconstruction. *Am J Sports Med.* 1994;22(2):211-218.
2. Alentorn-Geli E, Samitier G, Alvarez P, Steinbacher G, Cugat R. Anteromedial portal versus transtibial drilling techniques in ACL reconstruction: a blinded cross-sectional study at two- to five-year follow-up. *Int Orthop.* 2010;34(5):747-754.
3. Anderson AF, Snyder RB, Lipscomb AB Jr. Anterior cruciate ligament reconstruction: a prospective randomized study of three surgical methods. *Am J Sports Med.* 2001;29(3):272-279.
4. Arnold MP, Kooloos J, van Kampen A. Single-incision technique misses the anatomical femoral anterior cruciate ligament insertion: a cadaver study. *Knee Surg Sports Traumatol Arthrosc.* 2001;9(4):194-199.
5. Bedi A, Altchek DW. The "footprint" anterior cruciate ligament technique: an anatomic approach to anterior cruciate ligament reconstruction. *Arthroscopy.* 2009;25(10):1128-1138.
6. Behrendt S, Richter J. Anterior cruciate ligament reconstruction: drilling a femoral posterolateral tunnel cannot be accomplished using an over-the-top step-off drill guide. *Knee Surg Sports Traumatol Arthrosc.* 2010;18(9):1252-1256.
7. Brophy RH, Pearle AD. Single-bundle anterior cruciate ligament reconstruction: a comparison of conventional, central, and horizontal single-bundle virtual graft positions. *Am J Sports Med.* 2009;37(7):1317-1323.
8. Brophy RH, Voos JE, Shannon FJ, et al. Changes in the length of virtual anterior cruciate ligament fibers during stability testing: a comparison of conventional single-bundle reconstruction and native anterior cruciate ligament. *Am J Sports Med.* 2008;36(11):2196-2203.
9. Dargel J, Schmidt-Wiethoff R, Fischer S, Mader K, Koebke J, Schneider T. Femoral bone tunnel placement using the transtibial tunnel or the anteromedial portal in ACL reconstruction: a radiographic evaluation. *Knee Surg Sports Traumatol Arthrosc.* 2009;17(3):220-227.
10. Freedman KB, D'Amato MJ, Nedeff DD, Kaz A, Bach BR Jr. Arthroscopic anterior cruciate ligament reconstruction: a metaanalysis comparing patellar tendon and hamstring tendon autografts. *Am J Sports Med.* 2003;31(1):2-11.
11. Gavrilidis I, Motsis EK, Pakos EE, Georgoulis AD, Mitsionis G, Xenakis TA. Transtibial versus anteromedial portal of the femoral tunnel in ACL reconstruction: a cadaveric study. *Knee.* 2008;15(5):364-367.
12. Heming JF, Rand J, Steiner ME. Anatomical limitations of transtibial drilling in anterior cruciate ligament reconstruction. *Am J Sports Med.* 2007;35(10):1708-1715.
13. Jepsen CF, Lundberg-Jensen AK, Faunoe P. Does the position of the femoral tunnel affect the laxity or clinical outcome of the anterior cruciate ligament-reconstructed knee? A clinical, prospective, randomized, double-blind study. *Arthroscopy.* 2007;23(12):1326-1333.
14. Kopf S, Musahl V, Tashman S, Szczodry M, Shen W, Fu FH. A systematic review of the femoral origin and tibial insertion morphology of the ACL. *Knee Surg Sports Traumatol Arthrosc.* 2009;17(3):213-219.
15. Lawhorn KW, Howell SM. Principles for using hamstring tendons for anterior cruciate ligament reconstruction. *Clin Sports Med.* 2007;26(4):567-585.
16. Loh JC, Fukuda Y, Tsuda E, Steadman RJ, Fu FH, Woo SL. Knee stability and graft function following anterior cruciate ligament reconstruction: comparison between 11 o'clock and 10 o'clock femoral tunnel placement. 2002 Richard O'Connor Award paper. *Arthroscopy.* 2003;19(3):297-304.
17. McCulloch PC, Lattermann C, Boland AL, Bach BR Jr. An illustrated history of anterior cruciate ligament surgery. *J Knee Surg.* 2007;20(2):95-104.
18. Pearle AD, Shannon FJ, Granchi C, Wickiewicz TL, Warren RF. Comparison of 3-dimensional obliquity and anisometric characteristics of anterior cruciate ligament graft positions using surgical navigation. *Am J Sports Med.* 2008;36(8):1534-1541.
19. Piasecki DP, Bach BR Jr, Espinoza Orias AA, Verma NN. Anterior cruciate ligament reconstruction: can anatomic femoral placement be achieved with a transtibial technique? *Am J Sports Med.* In press.
20. Scopp JM, Jasper LE, Belkoff SM, Moorman CT III. The effect of oblique femoral tunnel placement on rotational constraint of the knee reconstructed using patellar tendon autografts. *Arthroscopy.* 2004;20(3):294-299.
21. Smith AH, Bach BR Jr. Anterior cruciate ligament reconstruction using nonirradiated fresh frozen patellar tendon allograft. In: ElAttrache NS, Harner CD, Mirzayan R, Sekiya JK, eds. *Surgical Techniques in Sports Medicine.* Philadelphia: Lippincott, Williams & Wilkins; 2007:351-358.
22. Stevenson WW III, Johnson DL. "Vertical grafts": a common reason for functional failure after ACL reconstruction. *Orthopedics.* 2007;30(3):206-209.
23. Zelle BA, Vidal AF, Brucker PU, Fu FH. Double-bundle reconstruction of the anterior cruciate ligament: anatomic and biomechanical rationale. *J Am Acad Orthop Surg.* 2007;15(2):87-96.