

Arthroscopic Management of Lateral Epicondylitis

KEVIN P. MURPHY AND RONALD A. LEHMAN, JR.

ARTHROSCOPIC MANAGEMENT OF LATERAL EPICONDYLITIS IN A NUTSHELL

History:

Traumatic or repetitive cause; lateral-sided elbow pain; pain with elbow motion, wrist extension

Physical Examination:

Tenderness over lateral epicondyle; pain with resisted wrist dorsiflexion; resisted middle finger extension; "chair test" with elbow in full extension, forearm pronated, and wrist dorsiflexed; diminished grip strength

Imaging:

Standard radiographs with rim of sclerotic bone, flattening; magnetic resonance imaging

Indications:

Failure of conservative management for at least 3 to 6 months

Contraindications:

Distorted anatomy (e.g., prior ulnar nerve transposition), ankylosed joint

Surgical Technique:

Patient positioned prone; elbow distention; routine arthroscopy portals; debride capsule, extensor carpi radialis brevis, and lateral epicondyle with shaver or bur

Postoperative Management:

Stiff, early range of motion, control of inflammation

Results:

More than 80% achieve significant improvement

Complications:

Neurovascular, failure to improve, stiffness

Lateral epicondylitis—also known as tennis elbow because of its early association with lawn tennis⁵²—is a common musculoskeletal problem that may result from minor trauma or as an overuse phenomenon. It was first described by Runge⁵³ in 1873 as a painful condition of the wrist and finger extensors on the lateral side of the elbow. Since then, various causes have been reported, including bursitis, synovitis, ligament inflammation, periostitis, extensor tendon tears, and microscopic rupture with formation of reparative tissue in the extensor carpi radialis brevis (ECRB) origin on the lateral epicondyle.^{8,19,20,39,52}

The hallmark of care is nonoperative treatment, although approximately 5% to 10% of patients develop chronic symptoms and may eventually require surgical intervention.^{11,13,16,18,29,39} Various open,^{2,15,16,20,39} percutaneous,^{10,60} and endoscopic²² surgical techniques have been described for recalcitrant cases. It appears that the percutaneous method is associated with less morbidity than are open techniques; however, inadequate resection and the inability to address intra-articular pathology are significant drawbacks.^{4,38,42,43} This may be particularly important because concurrent intra-articular pathology has been reported to occur in 11% to 19% of cases.^{38,44} In two recent series, we found that at 2-year follow-up, patients treated with arthroscopic ECRB release subjectively reported feeling “much better” to “better” in 83% to 95% of cases.^{9,44}

History

Several variables are important in the evaluation of patients with lateral epicondylitis. First, the nature and character of the patient's symptoms must be elicited. This includes whether the pain began after a single traumatic event or repetitive episodes. Also, one should inquire about the character and location of the pain and the presence or absence of catching, clicking, or locking, which may indicate loose intra-articular bodies.

Second, the patient should be asked about provocative maneuvers or insults that exacerbate the symptoms. For instance, a throwing athlete who reports a decrease in pitch velocity or an inability to “let the ball go” may have pain on forced extension, which could be a sign of posterior olecranon impingement.⁸ Posterior interosseous nerve (PIN) entrapment must also be differentiated from lateral epicondylitis. Pain in the extensor mass (distal to the radial head), weakness with wrist or finger extension, and pain with percussion over the course of the nerve points to PIN entrapment as the diagnosis. However, many authors believe that this diagnosis requires positive electromyographic testing changes in the PIN.³⁸ Radiocapitellar degenerative changes should also be considered and can be ruled out by physical examination and plain radiographs.⁴⁶ Patients with radiocapitellar pathology usually have pain and clicking with elbow motion and episodes of intermittent locking. Other causes of lateral elbow pain include C7 radiculitis, anconeus muscle compartment syndrome,¹ and posterolateral rotatory instability.⁴¹ These conditions must be considered and thoroughly evaluated.

Third, the patient's preoperative history is needed to assess previous surgical procedures and their possible role in a subluxating ulnar nerve or other associated problem. Less commonly, compression of the musculocutaneous nerve or a symptomatic posterolateral plica has been implicated as a cause of lateral elbow pain.

Finally, the patient should be asked about demographic data and age, hand dominance, occupation, length of conservative treatment, number of corticosteroid injections, and duration and magnitude of symptoms.

Physical Examination

All compartments about the elbow should be evaluated and carefully examined. In particular, the lateral epicondyle and extensor mass should be palpated for point tenderness consistent with lateral epicondylitis or other tendinopathies. Tenderness about the lateral epicondyle, most commonly 5 mm distal and anterior to the lateral epicondyle,⁴⁶ is present in nearly all patients with lateral epicondylitis. Patients usually exhibit pain with resisted wrist dorsiflexion with the elbow extended. Resisted extension of the middle finger also occurs in up to 78% of patients, and this can be confused with a PIN syndrome. Pain with resisted supination is also present in 51% of patients.⁵⁸ In addition, pain with handshaking and turning doorknobs is quite common. The “chair test,” which involves asking the patient to lift the back of a chair with the elbow in full extension, the forearm pronated, and the wrist dorsiflexed, generates apprehension before the attempt.⁴⁶ Grip strength is diminished in up to 78% of patients.⁵⁸

Imaging

Plain Radiographs

Routine diagnostic radiographs, including an anteroposterior view with the elbow in full extension and a lateral view with the elbow at 90 degrees of flexion, may be helpful if there is a history of trauma or if one suspects intra-articular pathology. Unfortunately, loose bodies located in the posterior compartment are often difficult to visualize with plain radiographs.^{8,12,22,40,59} Ward et al.⁵⁹ reported a 75% accuracy rate for radiographs, in comparison to arthrograms, which have an accuracy rate of 89% with 100% sensitivity. Calcification of the ECRB secondary to long-standing lateral epicondylitis with significant degenerative tissue can be visualized on plain films in up to 25% of cases.³⁰ Finally, an axial view may help outline the olecranon and its articulations.⁸

Magnetic Resonance Imaging

Although not routinely recommended, magnetic resonance imaging may be useful for the evaluation of osteochondral lesions and loose bodies, especially in the

radiocapitellar joint and posterior compartments, respectively.^{24,55} It may also show enhancement of the degenerative tissue of the ECRB or injuries to the soft tissues, especially the lateral collateral ligament complex. Magnetic resonance arthrography with saline or gadolinium further increases the sensitivity for detecting undersurface tears.

Indications and Contraindications

Historically, indications for elbow arthroscopy included diagnosis of elbow pain, removal of loose bodies, excision of osteophytes, synovectomy, lysis of adhesions, and debridement of osteochondritis dissecans lesions of the capitellum and chondromalacia of the radial head.⁶ Additional indications include the release of elbow contractures secondary to trauma or degenerative arthritis, tennis elbow release, olecranon bursectomy, radial head excision, and fracture treatment.¹ Specific indications for arthroscopic release include persistent pain of greater than 3 to 6 months' duration that is resistant to treatment with nonsteroidal anti-inflammatory drugs, physical therapy, rest, activity modification, ice, stretching, strengthening, counterforce band therapy, and injections.

Contraindications to elbow arthroscopy include any significant distortion of normal bony or soft tissue anatomy that precludes safe entry of the arthroscope into the joint, previous surgery or hardware (including previous ulnar nerve transposition) that may interfere with medial portal placement, a severely ankylosed joint, and local soft tissue infection or osteomyelitis.^{6,8}

Surgical Technique

Positioning and Examination under Anesthesia

The patient is placed in the prone position, and the arm is positioned with the olecranon superior and the elbow at 90 degrees of flexion to gravity (Fig. 36-1).⁴⁸ The surgeon is seated.

Ligamentous examination is performed for varus and valgus instability, as well as for posterolateral subluxation, before preparing and draping.⁴¹ Range of motion is also noted. Because the patient is often apprehensive while being examined in the clinic, these examinations are best performed in the operating room under anesthesia. The posterolateral instability examination is performed with the extremity placed over the patient's head with the shoulder in full external rotation. A valgus, supination, and axial compression load is applied to the fully extended elbow. When the elbow is flexed to 20 to 40 degrees, subluxation or dislocation of the radiohumeral joint occurs. This produces an obvious deformity proximal to the radial head (sulcus sign). Range of motion is

⁶See references 3,5,14,17,21,24,25,34,47,51,55.

⁸See references 7,22,27,28,30,31,35,40,45,48,49,57.

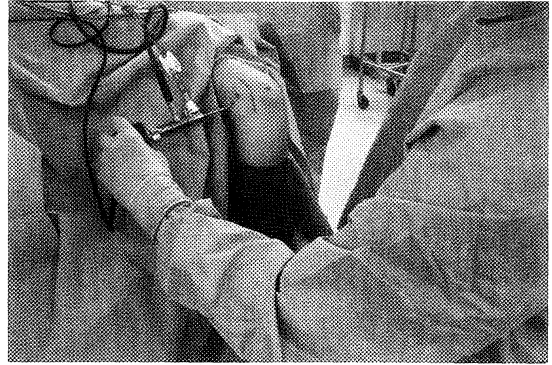


Figure 36-1 Patient in the prone position with the surgeon seated. A 2.7-mm arthroscope is in the proximal medial portal.

3
Elbow

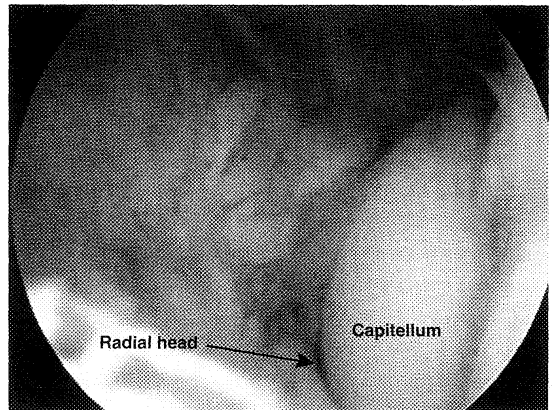


Figure 36-2 Arthroscopic image showing synovitis and fraying of the capsule—a type I lesion.

also evaluated in flexion and extension and compared with the contralateral elbow.

Diagnostic Arthroscopy

Diagnostic arthroscopy is performed to determine the presence and extent of concomitant intra-articular pathology. In addition, the nature and extent of the ECRB complex are classified.^{7,8,37} Type I lesions are characterized by fraying of the capsule and tendon undersurface without a distinct tear (Fig. 36-2). Type II lesions have linear tears along the undersurface of the capsule and ECRB tendon (Fig. 36-3). Type III lesions consist of minimally retracted partial avulsion or complete avulsion of the tendon (Fig. 36-4).

Specific Surgical Steps

After positioning, the anatomic landmarks about the elbow are palpated and outlined with a skin marker

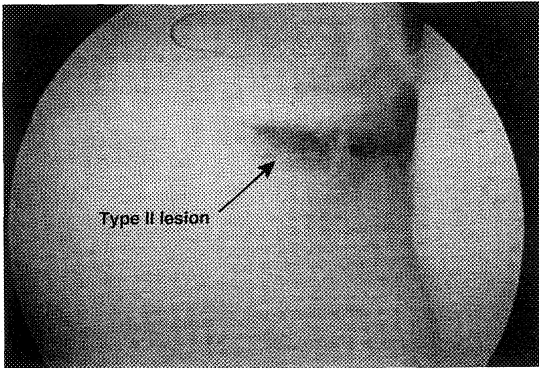


Figure 36-3 Type II lesion showing a linear tear along the undersurface of the capsule and extensor carpi radialis brevis (ECRB) tendon.

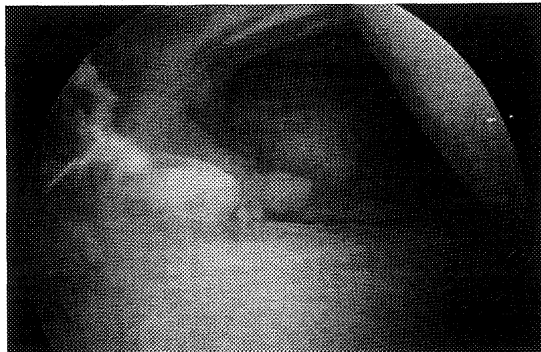


Figure 36-4 Arthroscopic image of a type III lesion with retraction and avulsion of the tendon.

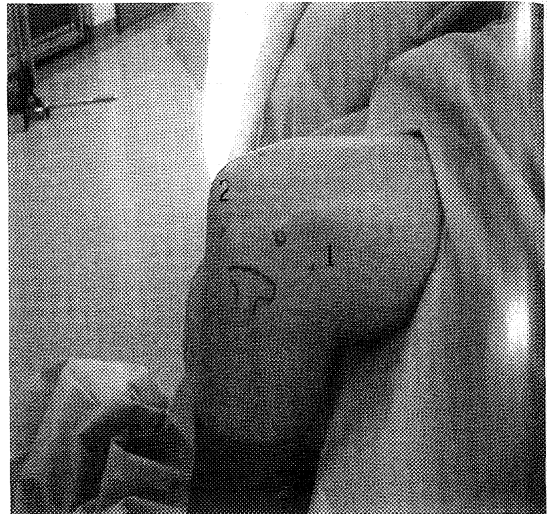


Figure 36-5 Proximal lateral (1) and direct lateral (2) portals.

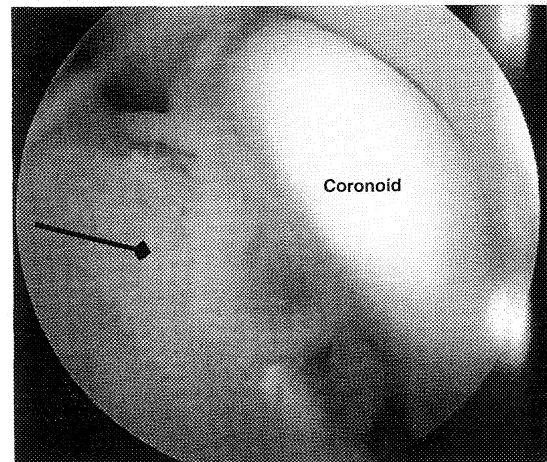


Figure 36-6 Synovitis of the anterior compartment (arrow).

(Fig. 36-5). This should be completed before distention of the joint with fluid or subsequent extravasation. First, the elbow joint is distended with 20 mL of saline injected with an 18-gauge spinal needle through a direct lateral approach. This also serves to displace the neurovascular structures anteriorly.²⁹ Next, the proximal medial portal (which is the standard viewing portal) is established approximately 2 cm proximal and 2 cm anterior to the intermuscular septum of the medial epicondyle through a 2-mm skin incision using a number 11 scalpel blade. The septum is palpated, and the subcutaneous tissue is spread bluntly with a small hemostat. This “nick and spread” technique protects the cutaneous nerves in the area. A blunt trocar is then introduced into the joint, followed by either a 2.7- or a 4-mm, 30-degree arthroscope. Care must be taken when inserting the cannula to ensure that the instruments remain anterior to the intermuscular septum and in direct contact with the anterior surface of the humerus. The joint is distended using a fluid pump with 40 mm Hg pressure, the anterior compartment of the elbow is thoroughly inspected, and any existing intra-articular pathology is noted and addressed

(Fig. 36-6). In particular, the radiocapitellar joint and the lateral portion of the capsule are examined for abnormalities and classified. The proximal lateral portal is then established approximately 2 cm proximal and 2 cm anterior to the lateral epicondyle under direct visualization using a spinal needle, followed by a similar skin incision and cannula insertion technique.

With visualization obtained through the proximal medial portal, the lateral capsule and undersurface of the ECRB tendon are easily visualized and evaluated. To visualize the undersurface of the ECRB tendon, the arthroscope is advanced past the radial head. This places the tendon directly in front of the camera, where it can be followed directly to its origin on the lateral

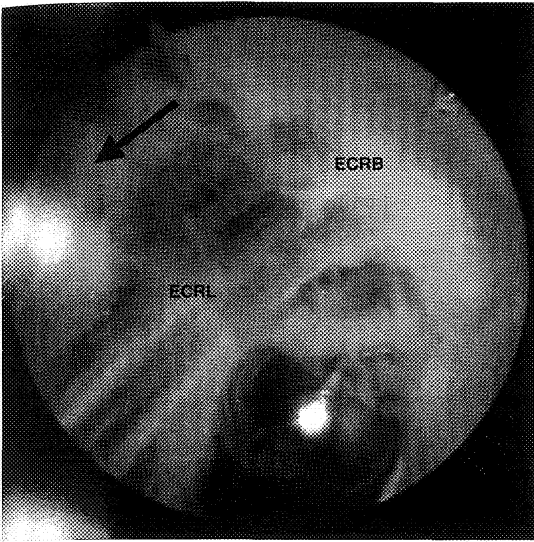


Figure 36-7 Fatty degenerative changes (black arrow) in the extensor carpi radialis brevis (ECRB) tendon overlying the extensor carpi radialis longus (ECRL).

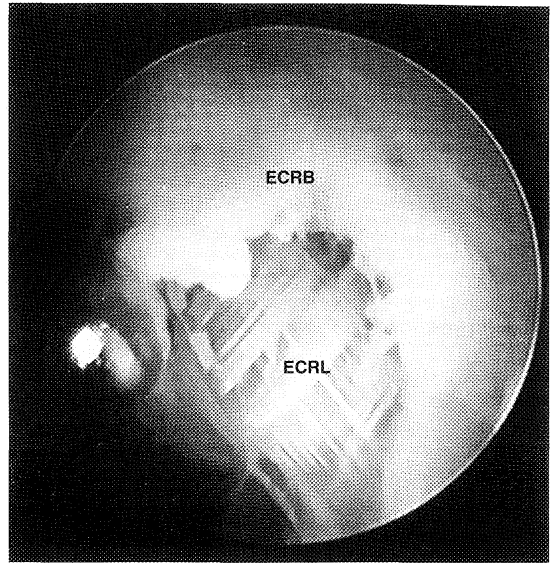


Figure 36-8 A 4.5-mm incisor is used to debride the extensor carpi radialis brevis (ECRB) tendon insertion on the lateral epicondyle. ECRL, extensor carpi radialis longus.

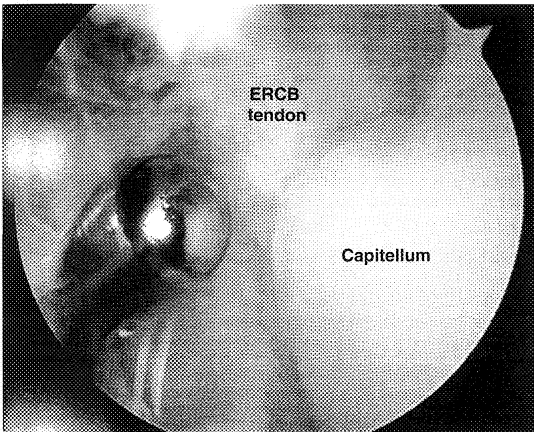


Figure 36-9 A 4.5-mm incisor is used to begin debridement of the extensor carpi radialis brevis (ECRB) tendon.

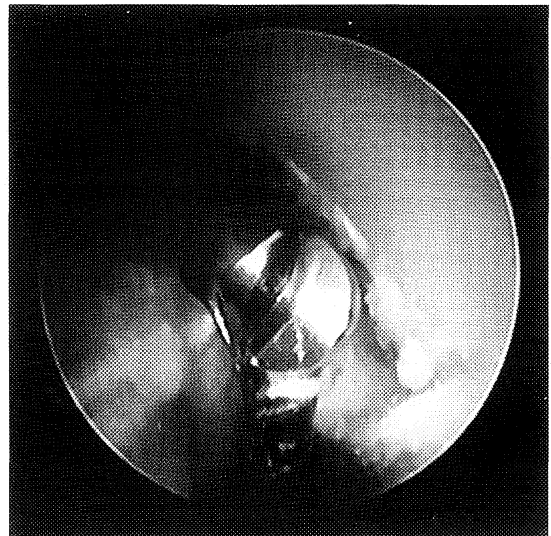


Figure 36-10 A 4.0-mm abrader is used to decorticate the lateral epicondyle. Extensor carpi radialis brevis (ECRB) release is completed.

epicondyle. The capsule adheres to the undersurface of the ECRB tendon and is often torn or may be thin and translucent. A 4.5-mm synovial resector is then introduced through the proximal lateral portal. The abnormal tissue appears grossly degenerative, with discolored tissue and varying degrees of fibrous changes and tears (Fig. 36-7). If the capsule is present, it is debrided to reveal the undersurface of the ECRB (Fig. 36-8). Release of the ECRB tendon is begun at the site of pathology (either degenerative tissue or tear) and is continued back to its origin on the lateral epicondyle (Fig. 36-9). Care

must be taken to avoid damage to the corresponding articular surface. After release of the visible ECRB origin, a 4.5-mm rounded bur is used to decorticate the lateral epicondyle and the distal portion of the lateral condylar ridge in the area of the ECRB origin (Fig. 36-10). The

cadaveric study by Kuklo et al.⁵⁹ showed that this release removes an average of 23 mm of the ECRB tendon. The 30-degree arthroscope provides adequate release (if taken to the limit of the visualization) while protecting the lateral collateral ligaments that are more posterior.⁵⁹

If needed, a direct lateral portal can be made with the elbow in 90 degrees of flexion.⁵⁴ The elbow is then extended, and the arthroscopic cannula is inserted into the posterior compartment of the elbow. The posterior compartment is visualized, and if any synovitis, loose bodies, or osteophytes are present, a straight posterior portal is created through the triceps tendon at a point equidistant between the medial and lateral epicondyles. This portal allows excellent access to the posterior joint without risk of neurologic injury. After completion, the portals are closed with 3-0 nylon and a soft dressing is applied.

Pearls and Pitfalls

Arthroscopic release of the ECRB tendon is technically challenging. With the patient placed in the prone position and the surgeon seated facing the elbow, the arthroscopic movements are not intuitive and take some time to perfect. When draping the patient, the surgeon takes a seated position with the arthroscopy drape across his or her thighs. By flexing the patient's wrist and placing the dorsal aspect of the wrist on the surgeon's thigh, elbow flexion and extension are easily controlled by simply raising and lowering the operating table. This is particularly helpful when visualizing the posterior compartment with the elbow in extension.

When establishing the portals, the "nick and spread" technique is particularly helpful to avoid injury to the sensory cutaneous nerves and the PIN.⁵⁰ The tip of the number 11 blade is placed through the skin, and the skin is pulled distally to create a small incision. A hemostat is then used to spread open the skin and mobilize the nerves away from the path of the cannula. The smaller 2.7-mm arthroscope is easily passed into the distended joint capsule, providing a distinct advantage over the 4-mm arthroscope. If a 4-mm arthroscope is desired, it can be placed over a switching stick after establishment of the portals. It is difficult to penetrate the capsule with either size arthroscope.

The ECRB tendon attaches along the distal and anterolateral aspect of the lateral epicondyle, covering an area of approximately 1.5 cm. When addressing the ECRB tendon insertion, it is imperative to carry the debridement up the lateral flare of the epicondyle until the entire insertion site is removed from bone. Decortication of the epicondyle may stimulate a healing response, but it also aids the surgeon by ensuring that the entire ECRB tendon has been released. Proper use of the abradar flattens this ridge and removes the last remaining fibers off the ECRB tendon. After releasing the ECRB tendon, the extensor carpi radialis longus tendon is easily visualized as it travels proximally toward its insertion site.

Decortication should not be extended posterior to the epicondyle, as this may disrupt the lateral collateral

ligament complex. Use of a 30-degree arthroscope prevents compromise of the lateral collateral ligaments because it does not allow significant posterior visualization. A 70-degree arthroscope provides better posterior visualization, which may actually allow the surgeon to access the posterior structures.

A postoperative intra-articular injection for pain relief is not recommended. The injection may extravasate and result in a transient radial nerve palsy, making both the patient and the surgeon uncomfortable until it resolves.

Postoperative Management

The elbow is placed in a soft dressing, and motion is encouraged immediately postoperatively. Patients should have met with a physical therapist preoperatively to discuss the following:

- Restoration of full active range of motion (ROM)
- Strengthening in pain-free ROM
- Proper use of a sling, icing, and hand gripping
- Ergonomic education
- Importance of protocol compliance to ensure the best functional outcome

Exercises begin as soon as symptoms subside, and patients progress through three phases of rehabilitation.

Acute Phase (Postoperative Days 1 to 7)

- Sling for comfort
- Ice for 20 to 30 minutes several times a day
- Active and active assisted ROM for elbow and wrist in all planes to tolerance
- Passive modalities as necessary

Subacute Phase (Weeks 1 to 4)

- Continue active and active assisted ROM and neural glides
- Progressive isotonic exercises to tolerance
- Friction massage to portal sites as they heal
- Ice and passive modalities as necessary

Return to Activity Phase (Week 4+)

- Address ergonomic issues for work and home
- Functional progression to work and sports activities
- Continue active ROM and strengthening exercises
- Ice and passive modalities as necessary
- Return to work and sports pain free

Results

Since 1994, arthroscopy has been used routinely when surgical intervention is indicated for lateral epicondylitis. In a series by the senior author (KPM), 16 patients were treated for recalcitrant lateral epicondylitis after an

average of 31.7 months of conservative treatment (including rest, activity modification, ice, nonsteroidal anti-inflammatory drugs, corticosteroid injections, and physical therapy).³⁶ On physical examination, patients consistently had point tenderness over the lateral epicondyle, as well as pain on resisted wrist dorsiflexion with the elbow extended. All patients underwent diagnostic arthroscopy and arthroscopic release of the origin of the ECRB tendon with decortication of the lateral epicondyle as described earlier. All 16 elbows in the series had lesions on the undersurface of the ECRB tendon. There were five type I lesions, five type II lesions, and six type III lesions as classified by Baker et al.,^{7,8} with associated pathology found in 18.8% of the elbows. All patients were followed for a minimum of 1 year, with four being lost to subsequent follow-up secondary to military reassignment. Twelve of the 16 patients (75%) were followed for an average of 24.1 months (range, 15 to 33 months). There were no complications and no need for additional procedures; the average return to unrestricted work was 6 days. Ten of the 12 patients (83.3%) reported feeling much better as a result of their surgery, 2 reported feeling better, and none reported feeling the same or worse. Using a pain analog scale (0 to 10, with 10 being the worst pain), the average pain at rest was 0.58 (range, 0 to 3), the average pain with activities of daily living was 1.58 (range, 0 to 5), and the average pain with sports and work was 3.25 (range, 0 to 8).

In the only other clinical study involving arthroscopic release of the ECRB, we assessed the clinical utility of 42 releases in 40 patients with an average follow-up of 2.8 years.⁹ In this series, 95% of the elbows were rated as either "much better" or "better" by the patients. Using a pain analog scale, the average pain score at rest was 0.87 (range, 0 to 8), the average pain score with activities of daily living was 1.5 (range, 0 to 10), and the average pain score with sports or work was 1.9 (range, 0 to 8). The average functional score was 11.1 points out of a possible 12 (range, 6 to 12 points). Among the patients who were working at the time of surgery (36 elbows), the average return to work was 2.2 weeks (range, 1 to 6 weeks). Most of the patients (62%) were pain free; however, 10% still had some pain with activities of daily living. This is consistent with published reports on open procedures. These early findings indicate that arthroscopic release for recalcitrant lateral epicondylitis is a safe and reliable procedure. It also provides several distinct advantages, including the ability to address concomitant intra-articular pathology, preservation of the common extensor origin,⁷ accelerated rehabilitation, and early return to work. In a comparative study of open procedures, only 8 of 44 patients who were employed returned to work by 6 weeks after surgery, with 13 patients not returning until 12 weeks postoperatively.⁵⁸ In addition, Nirschl and Pettrone³⁹ found that tennis players took more than 6 months to return to competitive play and an average of 2.6 months to be symptom free.

Thus, the arthroscopic approach may best balance the positive aspects of both open and percutaneous procedures. This treatment allows an earlier return to work and may be more anatomically compatible with the

elbow musculature, with minimal degradation of grip strength.^{9,58}

Complications

Elbow arthroscopy is fraught with potentially hazardous complications. The most frequent complications involve the neurovascular structures; however, complications are unusual.

When nerve injuries do occur, they are usually transient, but permanent injuries have been reported. Nonetheless, Marshall et al.³⁵ recommended placing the forearm in pronation to move the PIN farther from the portal site.

With the anteromedial and anterolateral portals, the radial and posterior interosseous nerves are at risk on the lateral side, whereas the posterior antebrachial cutaneous nerve is most at risk medially. A study by Kuklo et al.²⁹ showed that the distance from portals to neurovascular structures averaged 5.4 mm for the radial nerve and 26.1 mm for the lateral antebrachial cutaneous nerve using the proximal lateral portal. For the proximal medial portal, the posterior antebrachial cutaneous nerve was 8 mm from the portal on average, and the ulnar nerve averaged 30.3 mm from the portal. In independent studies, Guhl²³ and Rupp and Tempelhof⁵³ reported injury to the radial nerve sensory branch, and Jones and Savoie²⁶ and Thomas et al.⁵⁶ described damage to the PIN. The posteromedial portal is not recommended because of the proximity to the ulnar nerve. In a separate series, O'Driscoll and Morrey⁴¹ reported seven complications: three episodes of transient radial nerve palsy (attributed to extravasation of local anesthetic) and four episodes of persistent drainage.

References

1. Abrahamsson SO, Sollerman C, Soderberg T: Lateral elbow pain caused by anconeus compartment syndrome: A case report. *Acta Orthop Scand* 58:589-591, 1987.
2. Almquist EE, Necking L, Bach AW: Epicondylar resection with anconeus muscle transfer for chronic lateral epicondylitis. *J Hand Surg [Am]* 23:723-731, 1998.
3. Andrews JR, Carson WG: Arthroscopy of the elbow. *Arthroscopy* 1:97-107, 1985.
4. Andrews JR, Craven WM: Lesions of the posterior compartment of the elbow. *Clin Sports Med* 10:637-652, 1986.
5. Andrews JR, St Pierre RK, Carson WG Jr: Arthroscopy of the elbow. *Clin Sports Med* 5:653-662, 1986.
6. Baker CL, Brooks AA: Arthroscopy of the elbow. *Clin Sports Med* 15:261-281, 1996.
7. Baker CL, Cummings PD: Arthroscopic management of miscellaneous elbow disorders. *Oper Tech Sports Med* 6:16-21, 1998.
8. Baker CL, Jones GL: Current concepts: Arthroscopy of the elbow. *Am J Sports Med* 27:251-264, 1999.
9. Baker CL, Murphy KP, Gottlob CA, Curd DT: Arthroscopic classification and treatment of lateral epicondylitis: Two-year clinical results. *J Shoulder Elbow Surg* 9:475-482, 2000.
10. Baumgard SH, Schwartz DR: Percutaneous release of the epicondylar muscle for humeral epicondylitis. *Am J Sports Med* 0:223-226, 1982.

11. Boyd HB, McLeod AC: Tennis elbow. *J Bone Joint Surg Am* 55:1183-1187, 1973.
12. Brooks AA, Baker CL: Arthroscopy of the elbow. In Stanley D, Kay N (eds): *Surgery of the Elbow: Scientific and Practical Aspects*. London, Edward Arnold Limited, 1998, pp 71-81.
13. Calvert PT, Allum RL, Macpherson IS, Bentley G: Simple lateral release in treatment of tennis elbow. *J R Soc Med* 78:912-915, 1985.
14. Clarke RP: Symptomatic, lateral synovial fringe (plica) of the elbow joint. *Arthroscopy* 4:112-116, 1988.
15. Coonrad RW, Hooper WR: Tennis elbow: Its course, natural history, conservative and surgical management. *J Bone Joint Surg Am* 55:1177-1182, 1973.
16. Cyriax JH: The pathology and treatment of tennis elbow. *J Bone Joint Surg* 18:921-940, 1936.
17. Day B: Elbow arthroscopy in the athlete. *Clin Sports Med* 15:785-797, 1996.
18. Gardner RC: Tennis elbow: Diagnosis, pathology, and treatment. Nine severe cases treated by a new reconstructive operation. *Clin Orthop* 72:248-253, 1970.
19. Goldberg EJ, Abraham E, Siegal I: The surgical treatment of chronic lateral humeral epicondylitis by common extensor release. *Clin Orthop* 233:208-212, 1988.
20. Goldie I: Epicondylitis lateralis humeri (epicondylalgia or tennis elbow): A pathological study. *Acta Chir Scand Suppl* 339, 1964.
21. Greis PE, Halbrecht J, Plancher KD: Arthroscopic removal of loose bodies of the elbow. *Orthop Clin North Am* 26:679-689, 1995.
22. Grifka J, Boenke S, Kramer J: Endoscopic therapy in epicondylitis radialis humeri. *Arthroscopy* 11:743-748, 1995.
23. Guhl JF: Arthroscopy and arthroscopic surgery of the elbow. *Orthopedics* 8:1290-1296, 1985.
24. Janarv PM, Hesser U, Hirsch G: Osteochondral lesions in the radiocapitellar joint in the skeletally immature: Radiographic MRI, and arthroscopic findings in 13 consecutive cases. *J Pediatr Orthop* 17:311-314, 1997.
25. Jerosch J, Schroder M, Schneider T: Good and relative indications for elbow arthroscopy: A retrospective study on 103 patients. *Arch Orthop Trauma Surg* 117:246-249, 1998.
26. Jones GS, Savoie FH: Arthroscopic capsular release of flexion contractures (arthrofibrosis) of the elbow. *Arthroscopy* 9:277-283, 1993.
27. Kerr DR: Prepatellar and olecranon arthroscopic bursectomy. *Clin Sports Med* 12:137-142, 1993.
28. Kim SJ, Kim HK, Lee JW: Arthroscopy for limitation of motion of the elbow. *Arthroscopy* 11:680-683, 1995.
29. Kuklo TR, Taylor KR, Murphy KP, et al: Arthroscopic release for lateral epicondylitis: A cadaveric model. *Arthroscopy* 15:259-264, 1999.
30. Lee BPH, Morrey BF: Arthroscopic synovectomy of the elbow for rheumatoid arthritis: A prospective study. *J Bone Joint Surg Br* 79:770-772, 1997.
31. Lo IKY, King CJW: Arthroscopic radial head excision [case report]. *Arthroscopy* 10:689-694, 1994.
32. Major HP: Lawn-tennis elbow. *BMJ* 2:557, 1883.
33. Marshall PD, Fairclough JA, Johnson SR, et al: Avoiding nerve damage during elbow arthroscopy. *J Bone Joint Surg Br* 75:129-133, 1993.
34. Morrey BF: Arthroscopy of the elbow. *Instr Course Lect* 35:102-107, 1986.
35. Morrey BF: Acute and chronic instability of the elbow. *J Am Acad Orthop Surg* 4:117-128, 1996.
36. Murphy KP, Baker CL: Arthroscopic findings associated with lateral epicondylitis. *Orthop Trans* 22:1305, 1998.
37. Murphy KP, Kuklo TR, Baker CL: Arthroscopic findings associated with lateral epicondylitis. *Orthop Trans* 21:222, 1997.
38. Nirschl RP: Tennis elbow. *Orthop Clin North Am* 4:787-800, 1973.
39. Nirschl RP, Pettrone FA: Tennis elbow: The surgical treatment of lateral epicondylitis. *J Bone Joint Surg Am* 61:832-839, 1979.
40. Nowicki KD, Shali LM: Arthroscopic release of a posttraumatic flexion contracture in the elbow: A case report and review of the literature. *Arthroscopy* 8:544-547, 1992.
41. O'Driscoll SW, Morrey BF: Arthroscopy of the elbow. *J Bone Joint Surg Am* 74:84-94, 1992.
42. Ogilvie-Harris DJ, Schemitsch E: Arthroscopy of the elbow for removal of loose bodies. *Arthroscopy* 9:5-8, 1993.
43. Organ SW, Nirschl RP, Kraushaar BS, Guidi EJ: Salvage surgery for lateral elbow. *Am J Sports Med* 25:746-750, 1997.
44. Owens BD, Murphy KP, Kuklo TR: Arthroscopic release for lateral epicondylitis. *Arthroscopy* 17:582-587, 2001.
45. Phillips BB, Strasburger S: Arthroscopic treatment of arthrofibrosis of the elbow joint. *Arthroscopy* 14:38-44, 1998.
46. Plancher KD, Halbrecht J, Lourie GM: Medial and lateral epicondylitis in the athlete. *Clin Sports Med* 15:283-305, 1996.
47. Poehling GG, Ekman EF: Arthroscopy of the elbow. *Instr Course Lect* 44:217-223, 1995.
48. Poehling GG, Whipple TL, Sisco L, Goldman L: Elbow arthroscopy: A new technique. *Arthroscopy* 5:222-224, 1989.
49. Redden JF, Stanley D: Arthroscopic fenestration of the olecranon fossa in the treatment of osteoarthritis of the elbow. *Arthroscopy* 9:14-16, 1993.
50. Rodeo SA, Forster RA, Weiland AJ: Neurological complications due to arthroscopy. *J Bone Joint Surg Am* 75:917-926, 1993.
51. Ruch DS, Poehling GG: Arthroscopic surgery of the elbow: Therapeutic benefits and hazards. *Clin Orthop* 313:140-145, 1995.
52. Runge F: Zur Genese und Behandlung des Schreibekrampfes. *Berl Klin Wochenschr* 10:245-248, 1877.
53. Rupp S, Tempelhof S: Arthroscopic surgery of the elbow: Therapeutic benefits and hazards. *Clin Orthop* 313:140-145, 1995.
54. Stothers K, Day B, Regan WR: Arthroscopy of the elbow: Anatomy, portal sites, and a description of the proximal lateral portal. *Arthroscopy* 11:449-457, 1995.
55. Takahara M, Shundo M, Kondo M, et al: Early detection of osteochondritis dissecans of the capitellum in young baseball players: Report of three cases. *J Bone Joint Surg Am* 80:892-897, 1998.
56. Thomas MA, Fast A, Shapiro D: Radial nerve damage as a complication of elbow arthroscopy. *Clin Orthop* 215:130-131, 1987.
57. Timmerman LA, Andrews JR: Arthroscopic treatment of posttraumatic elbow pain and stiffness. *Am J Sports Med* 22:230-235, 1994.
58. Verhaar J, Walenkamp G, Kester A, et al: Lateral extensor release for tennis elbow: A prospective long-term follow-up study. *J Bone Joint Surg Am* 75:1034-1043, 1993.
59. Ward WG, Belhobek GH, Anderson TE: Arthroscopic elbow findings: Correlation with preoperative radiographic studies. *Arthroscopy* 8:498-502, 1992.
60. Yergler B, Turner T: Percutaneous extensor tenotomy for chronic tennis elbow: An office procedure. *Orthopedics* 8:1261-1263, 1985.