

Traumatic Anterior

Instability:

Arthroscopic Solutions

1

Augustus D. Mazzocca Robert A. Arciero Brian J. Cole

INTRODUCTION

Instability of the shoulder is a common and complex problem. Classifying traumatic unidirectional instability from those patients with a traumatic multidirectional instability is important in the successful treatment of these patients.³⁴

One of the most common mechanisms of an acute dislocation involves a collision or fall when the arm is in an abducted and externally rotated position. Although open Bankart repair has been the gold standard for treatment of this problem, arthroscopic techniques have improved and now provide results approaching the open method. The main tenet of the arthroscopic technique is to perform the same procedure that is done in the open technique, using arthroscopic methods. This entails the use of suture anchors, permanent sutures, and a method to address capsular redundancy. This will allow the surgeon to have all of the advantages of the arthroscopic technique while also assimilating all of the advantages of the open technique.

This chapter will review the pathology and biomechanics of specific lesions encountered in patients with traumatic anterior instability.

It will review various imaging techniques for assistance in preoperative planning. The chapter will describe various arthroscopic techniques for capsular plication, anterior labrum repair, and rotator interval closure. Rehabilitation, postoperative care, results of surgery, and complications will also be detailed.

PATHOLOGY OF ANTERIOR INSTABILITY

This section will describe the specific pathoanatomy associated with various diagnoses. Understanding the anatomy and biomechanics of lesions observed in patients with traumatic anterior instability will facilitate repair of these lesions, essential in a successful outcome. The arthroscope is a tool that will allow the surgeon to evaluate tissue both visually and tactilely.

The overall stability of the glenohumeral joint involves passive and active mechanisms. Static or passive factors include joint conformity, adhesion/cohesion, finite joint volume, and ligamentous restraints, including the labrum.³⁵ The ligaments and capsule are aided by receptors that provide proprioceptive feedback. When capsuloligamentous structures are damaged, alterations in proprioception occur that is partially restored with operative repair.²⁹ The active mechanisms are primarily provided by the rotator cuff muscles. The static stabilizers are affected by congenital factors, which include glenoid hypoplasia, and disorders of

A. D. Mazzocca: Department of Orthopaedic Surgery, University of Connecticut, Connecticut.

R. A. Arciero: Department of Orthopaedic Surgery, University of Connecticut, Connecticut.

B. J. Cole: Department of Orthopaedic Surgery, Rush Presbyterian-St. Luke's Medical Center, Chicago, Illinois.

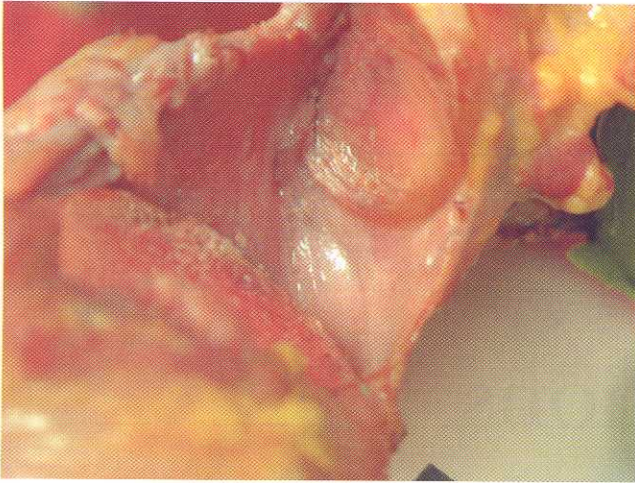


Figure 1-1 Cadaveric image of the inferior glenoid humeral ligament (IGHL) and anterior inferior labral complex.

collagen structure that result in excessive joint laxity. The severity of the instability pattern may be influenced by patient age, seizure disorders, and psychological or secondary gain factors.

The Bankart Lesion

The inferior glenohumeral ligament (IGHL) complex is the primary ligamentous restraint to anterior glenohumeral translation, specifically with the arm in an abducted and externally rotated position⁶⁰ (Fig. 1-1). The specific anatomy of the IGHL has been described as having anterior and posterior bands with an intervening axillary pouch.⁴¹ In a classic description of the pathology associated with a traumatic anterior dislocation, detachment of the anterior-inferior labrum and capsule (comprising the anterior band of the IGHL as a capsulolabral complex) is considered one of the major pathoanatomical features. This has subsequently been named the Perthes-Bankart lesion^{5,43} (Fig. 1-2).

The mechanism of how the Bankart lesion leads to instability has been studied extensively. A study was conducted that demonstrated that detachment of the anterior inferior labrum and capsule from the glenoid resulted in a nearly doubling of anterior translation. A Bankart repair was then performed, repairing the anterior IGHL and labrum back to the glenoid, which restored glenohumeral stability.²¹ In a follow-up study, the strain before failure for all bone-ligament-bone preparations was 27% in a cadaver study, and the authors concluded that plastic deformation of the capsule was a fundamental component of anterior instability.⁶ This is an important concept in capsular plication. It is important to mention that, in contradiction to Harryman's study, Speer et al. reported that, after creating a Bankart lesion, there were only small increases in anterior translation when the specimens were loaded. These data have not been duplicated.

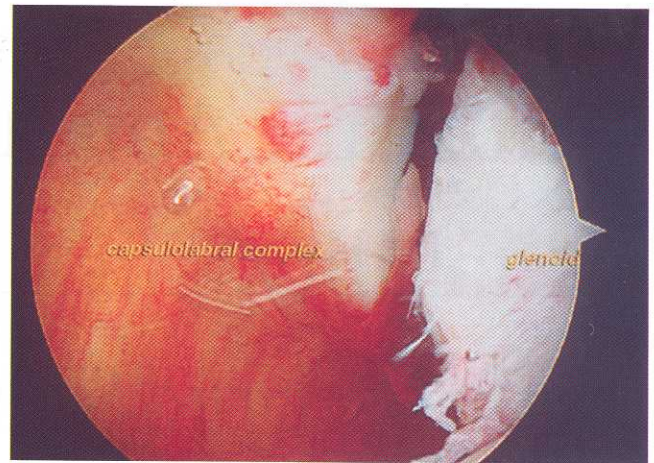


Figure 1-2 Arthroscopic view of a Bankart lesion, left shoulder, sitting position viewed from posterior (70-degree arthroscope).

There was also some evidence that suggests that age plays a role in the type of pathology seen with anterior dislocations.^{21,52} Age has been determined to have an impact on instability. In a 1969 study of young and old primates, Reeves observed that IGHL detachment occurred in young shoulders and that the capsular ligaments tended to tear in the older ones.⁴⁴ In a similar study of computed tomography (CT) arthrograms in humans, Ribbons found avulsion of the anterior glenoid labrum in 100% of the young patients and 75% of the older ones (greater than 50 years old).⁴⁵ Associated fractures, tears of the rotator cuff, and capsular injuries were more common in those patients over 50 years of age.

Neviaser in 1993 added a differentiation between the Bankart lesion and what he termed the *anterior labral ligamentous periosteal sleeve avulsion* (ALPSA) lesion (Fig. 1-3).

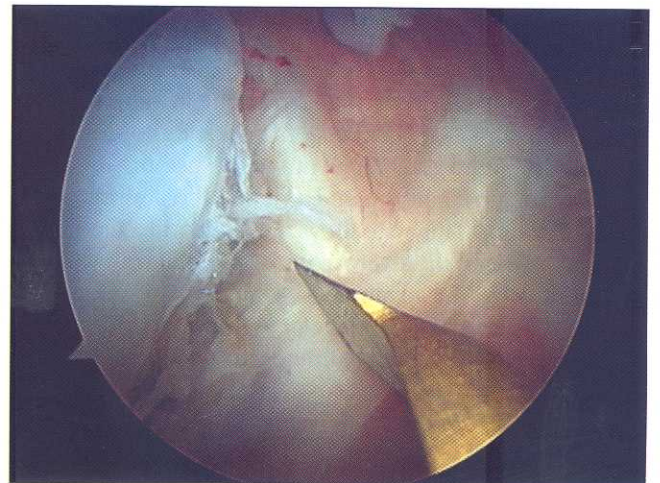


Figure 1-3 Arthroscopic anterior labrum periosteal sleeve avulsion lesion (ALPSA). Anterior view of left shoulder. Lesion being mobilized.

In his description of both acute and chronic anterior dislocations, the anterior scapular periosteum does not rupture as in a Bankart lesion, and the anterior IGHL, labrum, and the anterior scapular periosteum are stripped and displaced in a sleeve-type fashion medially on the glenoid neck. This is an important diagnostic variant to recognize, because, in a chronic situation, a cursory inspection of the anterior inferior quadrant of the glenoid may not reveal evidence of trauma. However, closer inspection more medially will elicit a large, scarred labrum on the anterior portion of the glenoid neck³⁸ in a medial location.

Superior Labrum Extension

The advantage of an arthroscopic examination of the shoulder joint frequently leads to observations of additional lesions associated with anterior instability. Occasionally, the injury may extend inferiorly into the capsule or the axillary pouch. Taylor and Arciero reported one capsular tear in a series of 63 primary shoulder dislocations.⁵⁶ These same authors described injuries that may also extend superiorly into attachment of the biceps tendon, producing a concomitant superior labrum anterior posterior (SLAP) lesion (Fig. 1-4, A and B). This lesion is generally observed when the dislocation involves an extreme type of trauma.¹⁴

In a variation of the anterior superior labrum lesion, the anterior supraspinatus can have partial or complete tears resulting in various amounts of instability. This has been called the SLAC (superior labrum, anterior cuff) lesion. This can be caused by both acute and chronic trauma and is addressed with suture anchor fixation.⁵¹

Humeral Avulsion of Glenohumeral Ligament Lesions

A third type of lesion can be observed, which is a lateral detachment of the IGHL from the humeral neck.³⁹ This has been subsequently described as a humeral avulsion of glenohumeral ligament (HAGL)^{3,32} lesion (Fig. 1-5, A and B). Nicola described this entity and its proposed mechanism in 1942.³⁹ A force applied in continued abduction tears the capsule from the neck of the humerus. A force started in abduction of 90 to 105 degrees, supplemented by impaction, tears the capsule from the neck of the humerus. Bach, in 1988, reported two cases fixed by open repair.³ Wolf et al., in 1995, found an incidence of 9.3% in a series of anterior instability patients. They also described an arthroscopic technique for repair. In this repair, a standard anterior inferior portal is made, and the bone is burred through this portal. An anterior lateral portal is created 2 cm lateral and 2 cm inferior to the coracoid process. A suture hook places monofilament absorbable suture through the capsule, and these are tied through the anterolateral portal over the subscapularis tendon.⁶³ Both Field and Warner, in 1997, cited case reports of anterior instability

treated with open techniques. Bokor et al., in 1999, reported 41 cases of a HAGL lesion in 547 shoulders, an incidence of 7.5%. Bui-Mansfield, in 2002, in a retrospective review of 307 patients with anterior instability, identified six cases, an incidence of 2%. Although relatively rare, this lesion must be examined for any anterior instability arthroscopic case. Taylor and Arciero described HAGL lesions after an acute anterior dislocation.⁵⁶

Traumatic Bone Deficiency

Fractures or various bone deficiencies can exist, involving both glenoid and humeral surfaces (Fig. 1-6). The anatomy of the glenoid and proximal humerus is consistent. The articular surface of the proximal humerus is similar to that of a sphere. It is composed of cartilage, subchondral and trabecular bone and is relatively soft even in young athletes. The glenoid has a consistent morphology

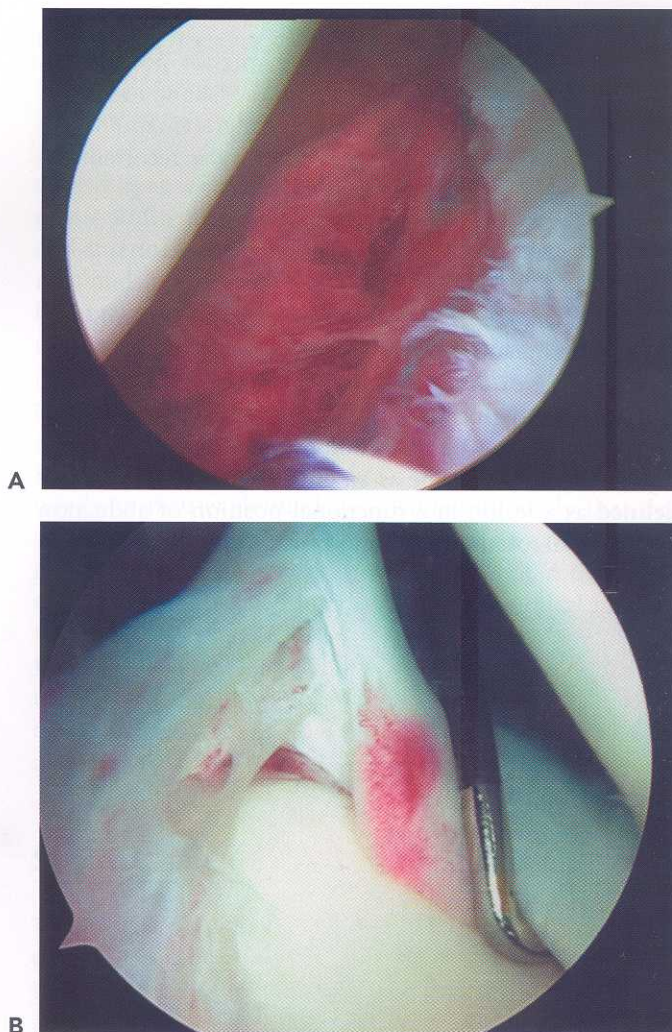


Figure 1-4 (A) Arthroscopic capsular tear. Sitting position, left shoulder viewed from posterior. (B) Arthroscopic superior labrum anterior to posterior lesion (SLAP), type IV.

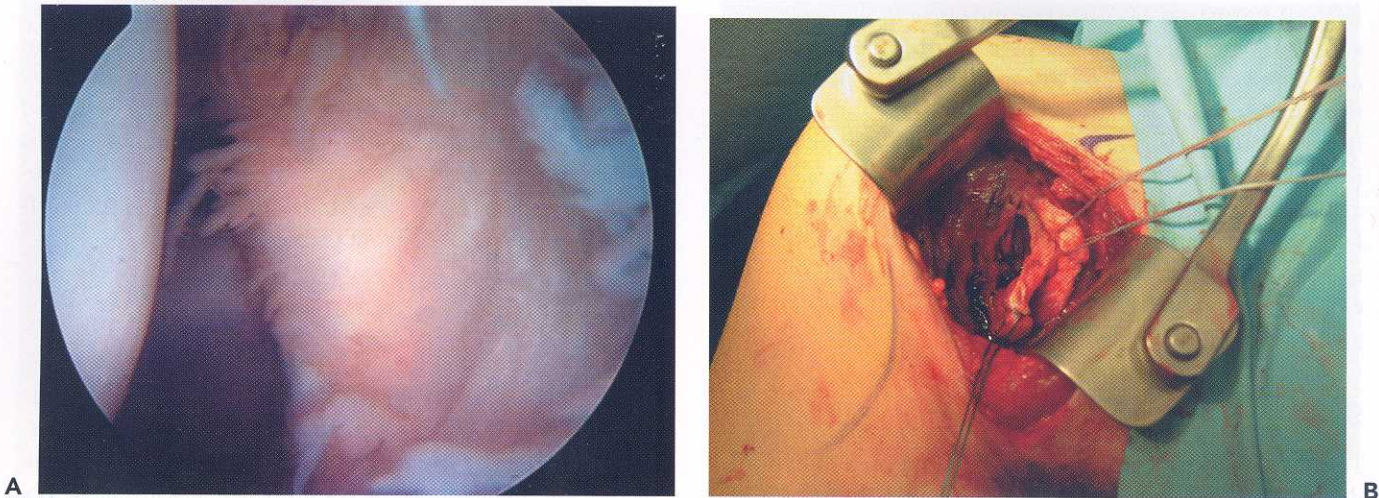

Figure 1-5 (A) Arthroscopic view of a humeral avulsion glenohumeral ligament lesion (HAGL), sitting posterior, left shoulder, scapularis muscle seen as shadowed area in background. (B) Open example of HAGL lesion—right shoulder, subscapularis tagged with suture to the right. HAGL lesion tagged with sutures inferiorly.

as well. It is pear-shaped with the inferior portion approximating that of a true circle enface.⁵⁵ Bone lesions of the glenoid or humeral head place greater demand of soft tissue repairs and have been shown to cause recurrent anterior instability of the shoulder.^{6,23,50}

Humeral Bone Deficiency

The Hill-Sachs lesion is found on the humerus and is an impression fracture caused by the humeral head being dislocated anterior and impacting on the anterior glenoid. This is generally located on the posterior superior part of the humeral head. Burkhart and De Beer reported and defined what they describe as an engaging Hill-Sachs lesion, defined as a lesion in a functional position of abduction and external rotation. The long axis of the Hill-Sachs lesion

is parallel to the glenoid and engages its anterior corner. A nonengaging Hill-Sachs lesion is where the impression fracture occurs when the arm is in a nonfunctional position of shoulder extension or shoulder abduction is less than 70 degrees. The nonengaging Hill-Sachs lesion passes diagonally across the anterior glenoid with external rotation, so there is continual contact with the articular surfaces. These shoulders are reasonable candidates for arthroscopic Bankart repair.⁹ It is important to understand that the Hill-Sachs lesion is created by the position of the arm when the dislocation occurs. The Hill-Sachs lesion that develops when the arm is at one's side but with some extension of the shoulder will be located more vertically and superiorly than the lesion that occurs with the shoulder abducted and externally rotated. The Hill-Sachs lesion that develops with the arm at the side is generally a nonengaging lesion.

Burkhart and De Beer report three ways to address the engaging Hill-Sachs lesion. The first is with an open capsular shift procedure that restricts external rotation, not allowing the lesion to engage. The second approach fixes the impression fracture with a size-matched humeral osteoarticular allograft, which is reserved for large defects. The third is a rotational proximal humeral osteotomy that internally rotates the articular surface of the humerus.

Glenoid Bone Deficiency

Two types of lesions can occur involving the anterior inferior glenoid: the impression fracture and the avulsion fracture. The compression Bankart lesion is secondary to compression of the anterior inferior bony articulation of the glenoid or the humeral head. Repeated episodes of instability create the "inverted pair" lesion as well as a typical bony Bankart. Investigators in the past have recommended cora-

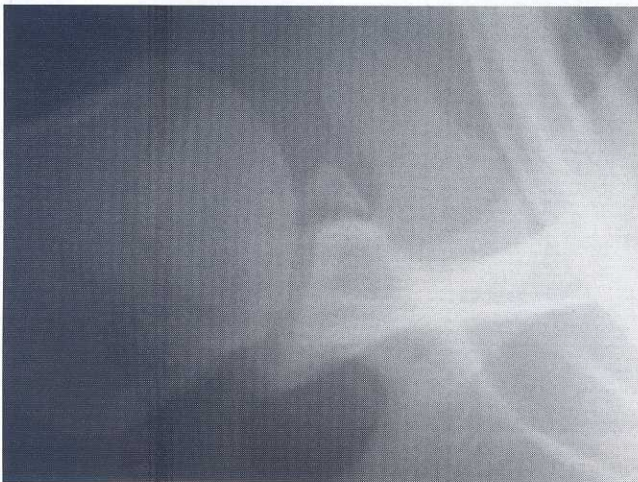

Figure 1-6 Radiograph of a bony Bankart lesion.

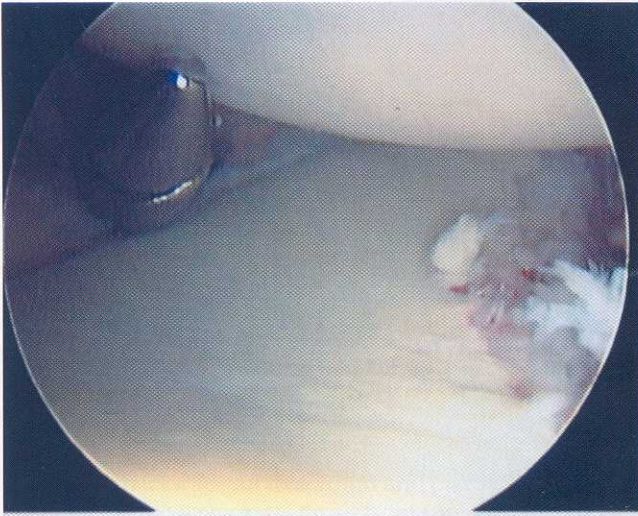


Figure 1-7 Arthroscopic example of an inverted pear-shaped glenoid. Left shoulder, anterior–superior viewing portal, lateral posterior. Note the bony deficiencies of the anteroinferior glenoid to the right.

coiled transfer when the glenoid rim fracture comprised 25% of the anterior/posterior diameter of the glenoid.⁷ Burkhart et al. comment on the containment of the humeral head by the glenoid as a result of two geometric variables.¹⁰ The first is the deepening effect of a wire glenoid due to the longer arc of its concave surface; the second is the arc length of the glenoid itself. They caution in their article that if the bony fragment is excised or if there is an “inverted pair”-shaped glenoid, and if there is no bone augmentation, arthroscopic techniques may fail (Fig. 1-7). To diagnose this arthroscopically, the arthroscope is placed in the anterior superior portal, looking inferiorly on the glenoid. The bare spot of the glenoid is roughly in the center of the glenoid, and, with a calibrated probe, the distance from the anterior rim of the glenoid to the bare spot is measured, as well as the distance from the bare spot to the posterior glenoid rim. If there is a 25% reduction in the length from the anterior glenoid to the bare spot compared to the bare spot to the posterior glenoid, a bone procedure is indicated.¹⁰

Version and Hypoplasia Lesions

Increased glenoid retroversion and glenoid hypoplasia have been implicated in posterior or multidirectional instability.

IMAGING

Radiographs

Radiographic evaluation is required in assessment of shoulder instability. Fractures as well as assessment of anatomy are critical to evaluate prior to treatment. A standard

anterior-posterior view of the arm in slight internal rotation is used to identify a fracture of the greater tuberosity. A true scapular anterior-posterior radiograph permits evaluation of a glenoid fossa fracture, if present. The West Point axillary view is used to assess bony avulsions of the attachment of the IGHL or bony Bankart lesions,⁴⁷ or anterior-inferior glenoid deficiency. The Hill-Sachs lesion can be quantified and evaluated by examining the Stryker Notch view.

Computed Tomography Scan

The CT scan can be a very accurate means of determining glenoid version and overall glenoid morphology. The ability to reconstruct the anatomy of the glenoid in three dimensions by subtracting the humerus is an excellent technique. Knowing the character and shape of the articular surface can aid the surgeon in preoperative planning. Substantial bone loss may be a contraindication to arthroscopic stabilization.

Magnetic Resonance Imaging

Magnetic resonance imaging (MRI) is used for assessment of associated pathology. Stoller, in 1997, reviewed contrast enhancement with intra-articular gadolinium diethylenetriamine pentaacetic acid (Gd/dtpa), which improved diagnostic ability for assessment of labral tears (both superior and anterior inferior), rotator cuff tears (both partial thickness and full), and articular lesions. When identifying a humeral avulsion of the glenoid labrum, MRIs identifying the humeral detachment of the inferior glenoid labrum (IGL) show that, as the IGL drops inferiorly, a midsagittal coronal oblique arthrographic image located toward the axillary pouch is converted from a full, distended U-shaped structure to a J-shaped structure⁵³ (Fig. 1-8, A and B). This has been further defined by a follow-up study that describes the MRI appearance of a HAGL as an avulsion fracture from the neocortex in the humeral neck. A thin radiolucency was observed inferior to the anatomical neck of the humerus, and once again as the fluid-filled distended U-shaped axillary pouch transforms into a J-shaped structure by the extravasation of contrast material.⁸ The pressure of this lesion may also be a relative contraindication to arthroscopic stabilization.

SURGICAL OPTIONS: DECISION MAKING

The controversy surrounding open versus arthroscopic techniques for anterior labral stabilization has been ongoing since Johnson published his technique of arthroscopic staple fixation in *Techniques of Anterior Glenohumeral Ligament Repair*.²⁶ Both open and arthroscopic procedures have involved using bone tunnels, staples, transglenoid sutures, rivets, bioabsorbable tacks, and suture anchors. Initial

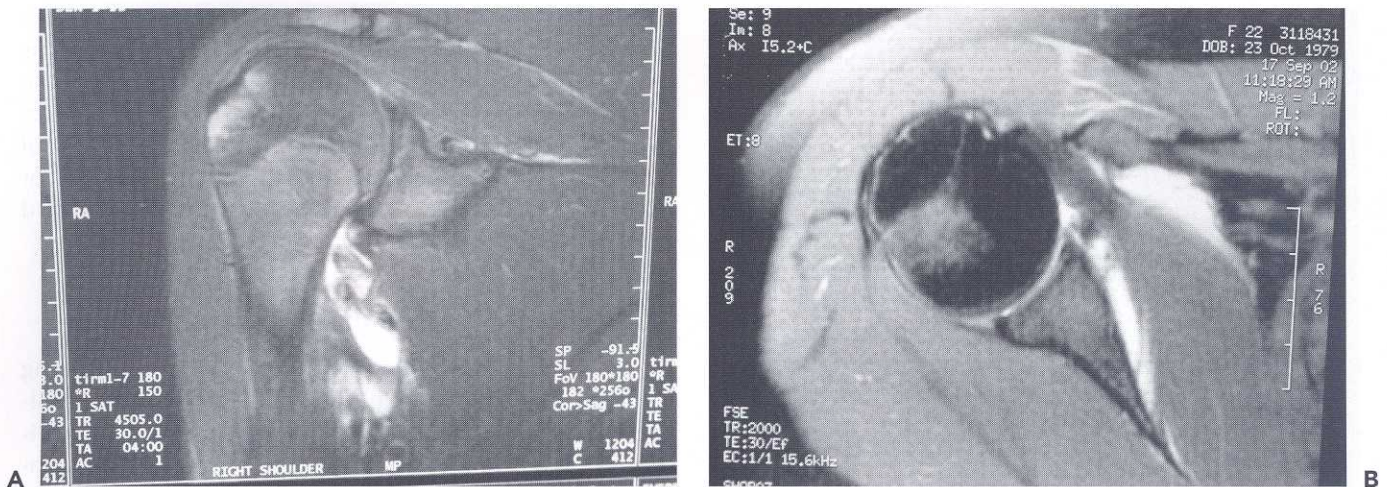


Figure 1-8 (A) Magnetic resonance imaging (MRI) example of a HAGL lesion. (B) MRI example of a Bankart lesion.

studies reported recurrence rates of arthroscopic techniques from 0% to 44%. The earlier arthroscopic techniques were applied to many types of instability patterns and featured techniques that did not resemble principles of established open methods. The major advantage of arthroscopic repair for instability is the ability to accurately identify and treat the specific pathoanatomy, less iatrogenic damage to normal tissues (subscapularis), lower postoperative pain, and improved cosmesis. Some authors also report an easier functional recovery and improved motion than with the open repair method.¹¹ Greater than five dislocations/subluxations has been thought of as a relative contraindication for arthroscopic repair.^{28,62} Indications for open technique would be bone abnormality, such as an “inverted pair” glenoid or a Hill-Sachs lesion involving greater than 20% to 30% of the articular surface. Some surgeons still advocate the open procedure in high-demand athletes; however, as arthroscopic techniques continue to improve and closely mimic what is done in an open procedure, recurrence rates are similar compared to open.

SURGICAL TECHNIQUES

A surgical technique, based on the idea of a 180-degree repair (Fig. 1-9), that is currently used with various modifications. This technique involves an inferior capsular plication, an anterior shift, a Bankart lesion repair with suture anchors, and a rotator interval closure. In operative treatment of an acute anterior dislocation within three weeks, only the Bankart lesion or the anterior inferior glenoid labrum tear is repaired with suture anchors. Generally, the inferior capsular plication and rotator interval closure are deferred for the late repair of the recurrent dislocation. When the repair is later than 3 weeks after the acute

dislocation, capsular imbrication and rotator interval closure will be required because it is thought that there is capsular elongation that is commonly associated with repetitive microtrauma. Bigliani et al., in 1992, reported that there was a significant amount of elongation with any type of capsular failure, suggesting a plastic deformation of the capsule occurred.⁶ Some type of shortening is then required to return the capsule to its anatomical length.

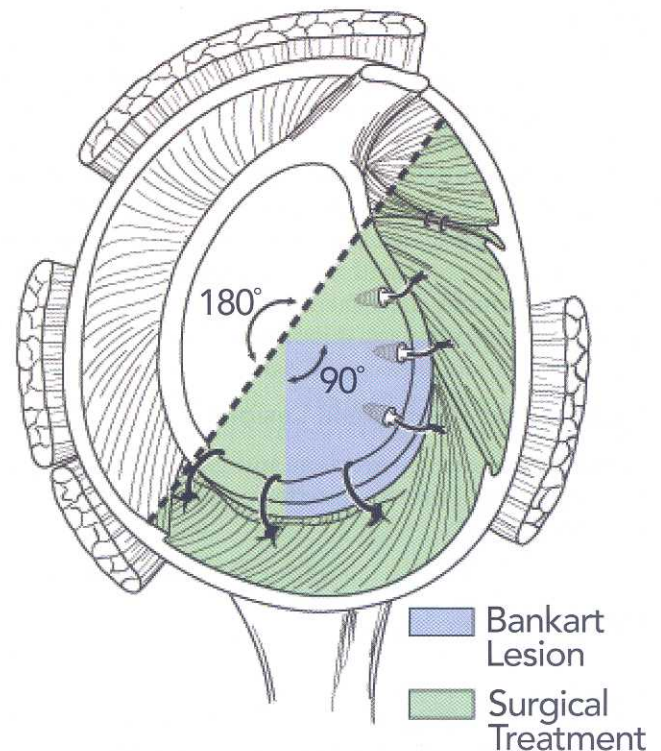


Figure 1-9 180-degree arthroscopic repair. Diagrammatic representation of surgical reconstruction.

Patient Position

The lateral decubitus, or beach-chair, position can be employed for instability surgery. The beach-chair position offers the advantage of being able to convert to an open procedure easily. When the beach-chair position is used, a sterile arm holder (Tennet Medical Engineering, McConnell, TX) is helpful for both holding a desired arm position and for applying a distraction force to the arm. For the lateral decubitus, a three-point distraction device that allows both longitudinal and vertical traction, enabling the humeral head to be lifted reproducibly from the glenoid, is used (Arthrex Inc., Naples, FL) (Fig. 1-10, A and B). A beanbag is used to stabilize the patient, and a hip-holder is used to stabilize the beanbag in case air is liberated. The patient is positioned in a 30-degree backward tilt to account and place the glenoid in a parallel orientation to the floor. In most cases, general endotracheal intubation is used for anesthesia, with an interscalene block for pain control. Due to the uncomfortable nature of the position, we advocate general anesthesia with or without the block. Preoperative antibiotics are administered intravenously prior to skin incision for portal placement.

Exam Under Anesthesia

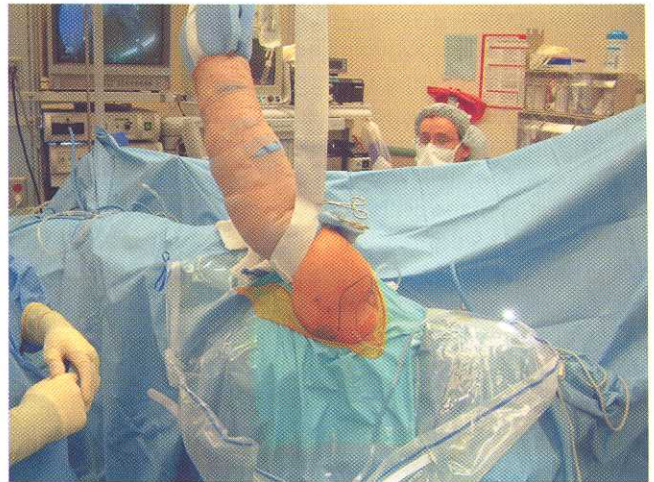An examination of both shoulders, with the patient under anesthesia and in the supine position, is performed, documenting forward elevation, external and internal rotation with the arm at the side, and external and internal rotation with the arm abducted to 90 degrees. An anterior load shift, a posterior "jerk" test, and sulcus tests are performed to assess dominance in instability. This exam under anesthesia is used to confirm and add further information, such as crepitus and/or other pathology that may be present, *not* to make the diagnosis. When performing the load and shift testing, care should be taken to compare both shoulders for the degree of humeral head translation. In addition, the amount of translation should be noted for each arm position with respect to the degree of humeral rotation and the position of the arm in relation to the plane of the scapula. Arm rotation and position will influence the degree of translation because of the changes that they have on ligament length.

Portal Placement

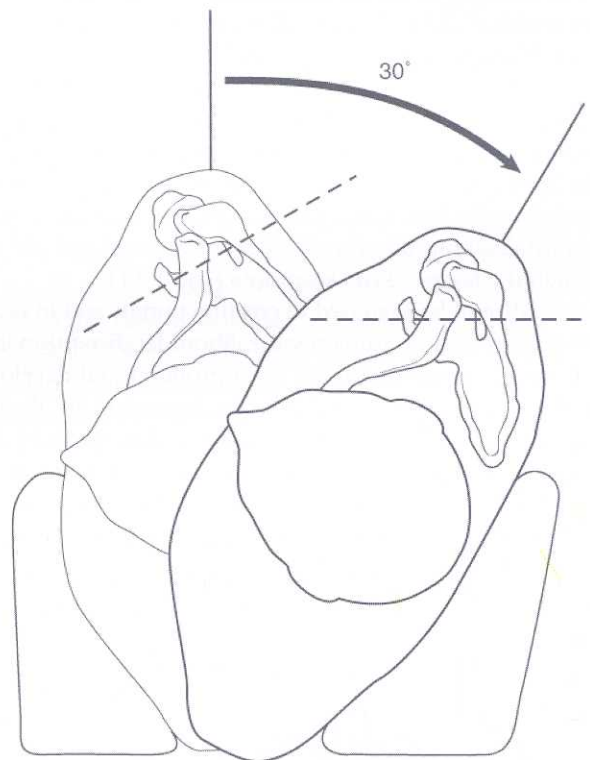
A standard posterior portal should be placed slightly more lateral than the joint line. If the portal is placed medial to the joint line, then it will require the surgeon to lever the arthroscope against the glenoid, making the stabilization procedure quite difficult.

An 8- to 10-mm incision is made, and then the blunt scope sheath and trocar is inserted atraumatically into the space between the glenoid rim and humeral head.

The anterior series of portals are then made using spinal needles for localization. The first anterior portal is made su-



A



B

Figure 1-10 (A) Lateral position traction device (Arthrex Inc., Naples, FL). (B) 30-degree tilt positioning.

perior and lateral in the rotator interval, which should be made as high in the anterior superior quadrant as possible, still allowing the cannula to be placed anterior to the biceps tendon. Medial placement of the cannula will compromise access to the glenoid. Care should be taken not to allow the cannula to be posterior to the biceps tendon to avoid entrapment of the tendon with sutures. In general, a 7-mm by 7-cm cannula, either smooth or ridged, is placed for suture shuttling.

The second portal is the anterior inferior portal. This portal can be created in two different manners. The first creates a 5 o'clock portal, which, by needle localization, is through

the subscapularis tendon. This allows accurate and easy inferior anchor placement. The difficulty is in placing an 8.25-mm by 7-cm cannula through the subscapularis tendon. This is accomplished after accurate placement by needle localization with a pointed switching stick and then a dilator system. The second is the standard anterior inferior portal that is made at the superior rolled edge of the subscapularis, angled inferiorly. Once again, this is also made with spinal needle localization and avoids the trauma of going through the subscapularis tendon. Potential difficulties involve inferior anchor placement because the angle is more oblique. If this does happen, a stab incision can be made, and the anchor can be placed through the subscapularis tendon with the standard anterior inferior portal maintained and sutures shuttled through that cannula after insertion.

The final portal that is made is the 7 o'clock portal. This is a posterior inferior portal, allowing inferior capsular plication. This portal is made roughly 2 cm lateral and 1 cm inferior to the standard posterior portal. An 18-gauge spinal needle is used under direct visualization to assess the position, and an 8.25-cm by 9-cm cannula is then placed. This allows very accurate inferior capsular plication under direct visualization, as the arthroscope is kept in the posterior portal, and suture shuttling devices are used and placed through the large 7 o'clock cannula (Fig. 1-11).

Care should be exercised in creating portals and in evaluating pumps and pump pressure. Shoulder distention is a problem and is compounded by improper portal development and a lengthy procedure. It is important to always establish accurate and small portals eliminating fluid extravasation, to use cannulas at all times to create a seal in the glenohumeral joint, and to monitor the amount of fluid pressure at all times. An ideal pressure to perform

arthroscopic stabilization has not been reported. However, analysis and evaluation of pressure and shoulder distention as the procedure progresses are critical.

Diagnostic Arthroscopy

In an attempt to accurately diagnose the amount of synovitis and other abnormalities found, the initial part of the arthroscopic examination is performed dry. This allows assessment of synovitis, specifically in the anterior superior quadrant of the shoulder, as well as evaluation of the biceps tendon and articular defects. Once the dry exam is completed, fluid is then allowed to flow into the joint.

A systematic evaluation and recoding of the anatomical findings in each region of the glenohumeral joint is one of the major advantages to arthroscopy. These regions include the superior, superoanterior, anterior, inferior, posterior, and rotator cuff insertion.

Superior Region

The superior region includes the triangle formed by the biceps tendon superiorly, the humeral head laterally, and the subscapularis inferiorly. The biceps tendon and the glenoid labrum surrounding the entire glenoid have the appearance of an inverted comma or Q.¹⁵ The biceps tendon attaches to the supraglenoid tubercle at the posterior superior aspect of the glenoid rim. The biceps origin is either attached to the superior labrum or sends fibers to the anterosuperior and posterosuperior labrum. The first portion of this exam can be done prior to distention of the capsule with fluid. This allows visualization and quantification of the amount of erythema on the biceps tendon. Once the fluid has been introduced, the pressure tamponades the microinflammation and "washes it out." This can be a helpful adjunct to diagnosis of biceps tendinosis (Yamaguchi K. Personal Communication, AAOS Advanced Shoulder Course, July 2002).

The superior labrum should be evaluated for tears, detachment, or other abnormalities representing the clinical entity known as the SLAP lesion. A probe can be used from the anterior portal to look under the labrum to evaluate whether it is detached. Rao et al., in 2003, have quantified the four types of anatomical variants of the anterosuperior aspect of the labrum that evaluate the size of the sublabral foramen and type of middle glenohumeral ligament (MGHL). They found a 13.4% incidence of anatomical variability in their group of 546 patients.

Anterosuperior Region

The coracohumeral ligament (CHL) should be evaluated because it encircles the biceps tendon. This ligament originates at the base of the coracoid and then spans out, sending fibers that encircle the biceps tendon, intertwine with

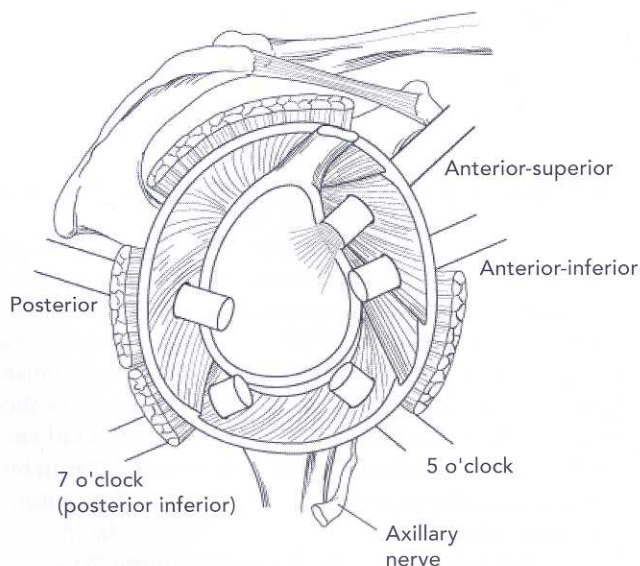


Figure 1-11 Portals that can be utilized for "180-degree" repair technique.

the supraspinatus tendon, and insert in front of the subscapularis tendon insertion. The superior glenohumeral ligament (SGHL) also attaches to the superior portion of the glenoid, but is in a different plane than the CHL. The SGHL runs from the anterior superior aspect of the glenoid to the upper part of the lesser tuberosity and is considered by some to be the medial wall and floor of the bicipital groove. The SGHL works with the CHL in preventing anterior translation of the humeral head with the arm adducted and externally rotated. The SGHL also prevents inferior subluxation of the humeral head (sulcus sign) with the arm at the side. It becomes taught with external rotation of the arm, further decreasing the inferior translation of the humeral head. The biceps can be followed distally into the bicipital groove. Forward elevation with the elbow flexed, combined with internal rotation of the arm, may assist in viewing the biceps as it passes underneath the transverse humeral ligament. The probe can also be placed superior to the tendon and the tendon "pulled" down into the joint, allowing visualization of the biceps tendon that is located in the intertubercular groove.

The bicipital groove is further bordered by the subscapularis tendon medially and the supraspinatus tendon laterally. The supraspinatus tendon can be seen adjacent to the biceps with abduction and external rotation. The SGHL and CHL form the medial sling of the biceps. Damage to these structures can result in biceps instability and/or pain.

Finally, the anterosuperior labrum can be evaluated. The labrum has been described as being triangular in cross section with its free edge directed at the glenoid center. It is made up of dense fibrous connective tissue and anchored to the osseous rim of the glenoid. The hyaline cartilage of the glenoid articular surface frequently extends under and beyond this free edge. Significant normal variability exists in the appearance of the anterosuperior labrum that can include physiologic detachment and confluence with the MGHL (Buford Complex), simple detachment (sublabral hole), or complete absence. A probe can be inserted through the anterior portal, as previously described, and used to examine all labral and ligamentous structures. Noting labral atrophy, fraying, and/or amount of movement should always be done because this information may aid in establishing or confirming the diagnosis and aid in treatment.

Anterior Region

With the arthroscope in the posterior portal and the 30-degree objective facing laterally, the rolled upper edge of the subscapularis is examined. The MGHL is variable in thickness and intersects the subscapularis at a 60-degree angle.³⁹ The MGHL arises from the anterior humeral neck just medial to the lesser tuberosity and inserts on the medial and superior glenoid rim and scapular neck. Its function is to resist anterior translation of the humeral head at 45 de-

grees of abduction.²⁴ In a diagnostic glenohumeral arthroscopy, it is also important to examine the subscapularis recess. Loose bodies can be lodged here and will not be discovered unless this area is actually visualized. Inferiorly, the anterior and anterior inferior labrum can be inspected. Any detachment of the labrum below the glenoid equator, however (at the level of the rolled-edge insertion of the subscapularis), is generally considered pathologic.

The articular surface of the glenoid and humerus must be examined in detail. The articular cartilage of the glenoid thins at the center. The surrounding cartilage should be examined for full-thickness lesions, fibrillation, and softening. The treatment of these lesions is still controversial, but they must be noted. Large articular lesions can manifest in a patient as a feeling of instability because the humeral head articulates with the lesion and "clunks" in various positions of rotation and abduction.

Inferior Region

The inferior region is examined for evidence of synovitis and presence of loose bodies. Inferiorly, with the assistant holding traction in 20 to 30 degrees of abduction on the arm in a beach-chair position, the anterior band of the IGHL can be inspected. The IGHL runs from the glenoid to the anatomical neck of the humerus. The anterior band of the IGHL prevents anterior translation of the humeral head when the arm is abducted 90 degrees and externally rotated. It also restricts inferior translation when the arm is abducted and internally rotated. The humeral attachment of the anterior band is best visualized from the anterior portal. It is from this view that a HAGL lesion can be seen. The axillary pouch is then inspected. The capsule of the axillary pouch is thin, and beneath it lays the axillary nerve. This relationship should always be considered when doing suture capsular plication or thermal capsulorrhaphy.

Posterior Region

The posterior inferior labrum and the posterior band of the inferior glenohumeral ligament can be inspected sequentially. The posterior band of the IGHL prevents inferior translation of the humeral head when the arm is abducted 90 degrees and externally rotated. It also prevents posterior translation when the arm is abducted and internally rotated.²⁵ From this position, the posterior insertion of the rotator cuff can be evaluated for fraying associated with internal impingement. The arm should be abducted to 90 to 110 degrees and maximally externally rotated. Fraying and contact of the posterior labrum and the rotator cuff tendon in a patient with pain can be indicative of internal impingement.

Evaluating the supraspinatus tendon insertion beginning just posterior to the biceps tendon is performed with slight forward elevation, abduction, and external rotation

of the humerus. Placing an 18-gauge spinal needle percutaneously and passing a monofilament suture into the joint assists in identifying partial thickness tears by viewing the suture from within the subacromial space following intra-articular arthroscopy. By observing the posterior and inferior humerus, the bare area can be visualized. This is an area of bare bone with remnants of old vascular channels. This bare area also correlates to the attachment of the infraspinatus tendon. It can be used as a landmark in rotator cuff surgery to align the infraspinatus to its footprint. Once the glenohumeral exam is complete, preparation of the tissue can begin.

Preparation

Preparation of the capsule prior to plication has been advocated to “excite the synoviocytes.” This has not been scientifically proven, but makes logical sense and can be accomplished with either a shaver or a handheld burr from either the anterior or 7 o’clock portal. Preparation of the glenoid bed for the labrum is also critical. With the viewing arthroscope in the posterior portal, the soft tissue and cortical surface can be removed. This is completed after the periosteal-labral-IGHL complex has been dissected free from the subscapularis tendon. A sharp elevator combined with an arthroscopic shaver or tissue ablation device are used to dissect and liberate the entire labrum, IGHL, and periosteum of the glenoid neck until the subscapularis muscle is seen. The anterior inferior labrum should be released so that it “floats” to the glenoid rim. A small burr is then used to create a bleeding surface on the anterior glenoid neck (Fig. 1-12). To evaluate this preparation of the bed the arthroscope is placed in the anterosuperior or inferior portal. This allows excellent visualization of the labral complex and bone preparation.⁶

Inferior Plication

Inferior plication is accomplished by imbricating the axillary pouch. The importance of capsular plication (capsulorrhaphy) has been shown by the irreversible plastic deformation of the capsule that occurs during an anterior dislocation.⁶ Arthroscopically, this can be completed with suture, suture anchors, or thermal energy. Tibone et al., in 2000, reported that thermal treatment to the IGHL produced a 41% decrease in anterior translation and a 36% decrease in posterior translation of the humeral head to the glenoid with a 15N load.⁵⁷ Arthroscopic plication with suture or suture anchor has recently been evaluated. Alberta et al., in 2003, reported a 61% decrease in anterior and a 11% decrease in posterior translation with a 1-cm imbrication of the capsule.²

There are multiple methods to plicate or decrease capsular redundancy. One such method, the pinch-tuck method, involves penetrating the tissue approximately 1 cm away

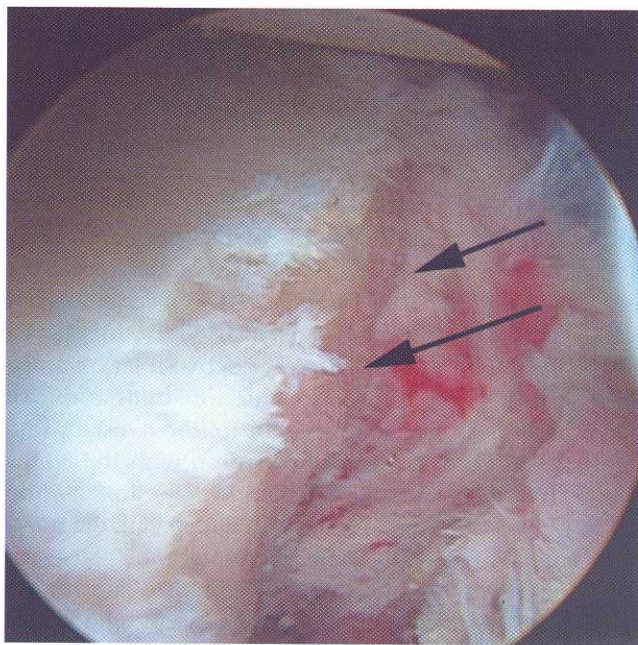


Figure 1-12 Arthroscopic example of anterior glenoid preparation. Left shoulder, lateral position viewed from anterosuperior portal.

from the labrum, then penetrating the labrum itself, with a suture-passing device in a “corkscrew configuration” (Fig. 1-13, A–C). When this knot is tied, it creates a blind pouch that then scars in. If the labrum is friable, or an adequate bite cannot be secured, a suture anchor can be placed into the labrum. The suture can then be shuttled through the inferior capsule and then tied. Two to three of these inferior capsular plication sutures are then placed from posterior inferior to anterior inferior positions (Positions 8, 7, 6 on a right shoulder). An accessory posterior portal can be used (7 o’clock portal), or the camera can be changed to the anterior superior portal and a cannula placed in the posterior portal. Suture management at this stage is important. The surgeon can tie individual sutures, which makes suture management more straightforward but can run the risk of “closing yourself out.” The second method involves shuttling the suture out the anterior cannula, then removing the cannula and replacing it, thus removing the suture pair from within. All pairs can then be shuttled back at the end for tying. Once two or three inferior capsular plication sutures are made, attention is turned to the anterior inferior Bankart lesion.

Bankart Repair with Suture Anchors

Repair of the Bankart lesion is the critical step in this procedure. The suture anchor repair is the most similar to the open repair technique and is extremely versatile and reproducible. Two variations of execution are the suture-first or

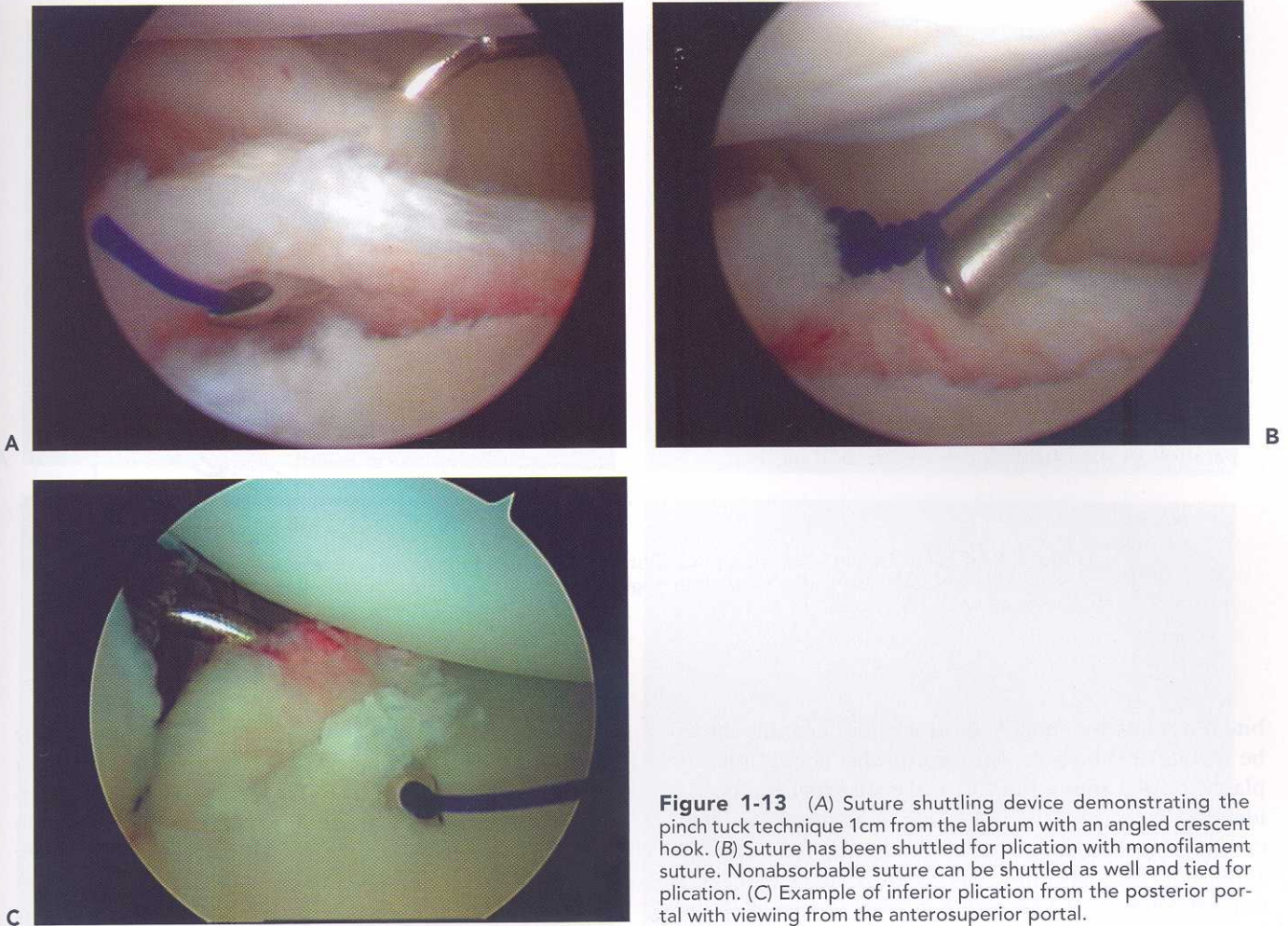


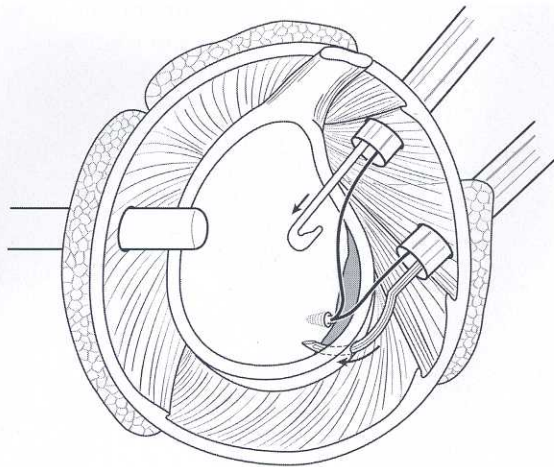
Figure 1-13 (A) Suture shuttling device demonstrating the pinch tuck technique 1cm from the labrum with an angled crescent hook. (B) Suture has been shuttled for plication with monofilament suture. Nonabsorbable suture can be shuttled as well and tied for plication. (C) Example of inferior plication from the posterior portal with viewing from the anterosuperior portal.

the anchor-first techniques. A third, highly successful technique is that of the Knotless Suture Anchor (Mitek Inc., Norwood, MA). Clinically, there is no reported difference between any of these techniques, and use is based on surgeon preference. The anchors themselves can be either metal or bioabsorbable. We recommend bioabsorbable anchors because most instability patients are young and we attempt to avoid the theoretical possibility of migration. There are no differences reported clinically based on the material of the anchor. Proper anchor placement is the most critical, and no material can help an improperly placed anchor.

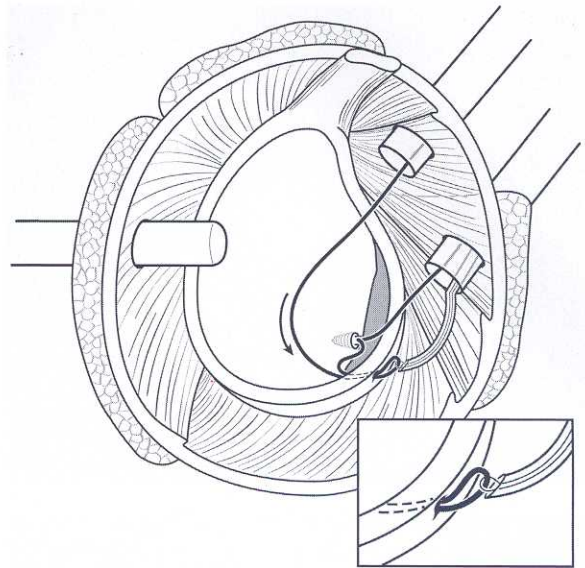
Anchor-First Technique

The anchor-first technique involves placing an anchor first through the anterior inferior cannula and then shuttling the suture limb (Fig. 1-14, A and B). It is important to note at this time the position of the anterior inferior cannula and the position in which the anchor should be placed into the glenoid. There are times when the position of the cannula is appropriate for suture shuttling but not

for placement of the anchor. In this case, a percutaneous approach can be followed to insert an anchor into the glenoid at the 5:30 position. The advantage of this technique is that it allows a more appropriate perpendicular placement of the anchor into the glenoid face at approximately 2 to 3 mm over the articular surface without “bubbling” or causing any articular damage. After the anchor has been successfully inserted, one of the suture limbs is passed out of the anterior superior cannula. This limb, if using a metal anchor or an anchor with fixed eyelet, is the limb on the tissue side of the suture. The eyelet should be perpendicular to the labrum. A tissue penetrator or suture shuttling device is used to place a passing suture into the tissue inferior to the anchor. The end of the suture will then be grasped and pulled out of the anterior superior cannula. A small square knot will be tied in the line, and then the monofilament suture line will be tied to the nonabsorbable braided suture and pulled through the anterior inferior cannula, hence shuttling the suture through labrum, inferior-glenoid ligament, and scapular periosteal complex. Upon tightening this suture, a shift of tissue from inferior to superior should be observed. If the tissue



A



B

Figure 1-14 (A) Example of an anchor first shuttling technique with tissue penetrator inferior to anchor. (B) Nonabsorbable suture shuttled through inferior labrum and inferior glenohumeral ligament complex.

bite is not inferior enough to the anchor, then this should be redone at the point. The knot pusher should then be placed on the suture limb to make sure that the post is identified and is on the tissue side. A sliding knot (Duncan Loop, SMC knot, Tennessee slider, etc.) can be tied, or a nonslider knot (multiple half hitches) can be tied at this time. It has been determined that, after placing a sliding knot or multiple half hitches, three alternating half hitches, while switching the post, is the most secure final fixation.³³ The knot should be on the tissue side so that the labrum can create a bumper effect. The next two or three anchors are then placed approximately 5 to 7 mm apart from each other in the same fashion as has been previously described. Upon completing this portion of the procedure, a "bumper" should be observed at the anterior inferior glenoid between the 3 and 6 o'clock positions.

Suture-First Technique

The suture-first technique involves placing a suture to ensure adequate soft tissue shift and then placement of the anchor (Fig. 1-15, A–D). A suture-passing device is placed thru the anterior inferior cannula. The tissue is clamped inferior to what would be the 5 o'clock anchor position, thus enabling the tissue from anterior inferior or inferior glenohumeral ligament to be shifted superiorly. The suture is passed through the tissue and shuttled through the anterior superior portal. The suture-passing device is then removed, and the suture limb that is in the anterior inferior portal is switched to the anterior superior portal. Tension is placed on this suture to observe the amount of shift that can be ac-

complished by placement of the anchor in the appropriate position. If it is determined that this suture was not inferior enough, a second suture can be placed. When an appropriate amount of tissue tension is established by direct visualization, the anchor can be placed through the anterior inferior portal in the exact location. As was described before, once the anchor is placed the two limbs of the suture are separated one through the anterior superior cannula, and the other limb is then shuttled through the tissue. This is repeated two or three times depending on repair quality and injury (Fig. 1-16).

Extension of Anterior Inferior Labrum Tear into the Superior Labrum

If the labral tear extends from the anterior inferior up into the superior labrum, the same cannula can be used to continue placing anchors. We recommend two to three anchors for superior labrum tears, one being placed in front of the biceps tendon anchor with one or two behind, depending on the instability being placed behind the biceps tendon anchor. The anchor that is placed in front of the biceps tendon anchor can be placed through the anterior superior portal. The one to two anchors placed posterior to the biceps anchor can be placed percutaneously in a spot that is 1 cm lateral and 1 cm anterior to the posterior lateral corner of the acromion. This portal or area of entrance is known as the "Port of Wilmington."³⁷ This allows placement of the anchor through the musculotendinous junction of the rotator cuff to the appropriate position on the superior glenoid rim poste-

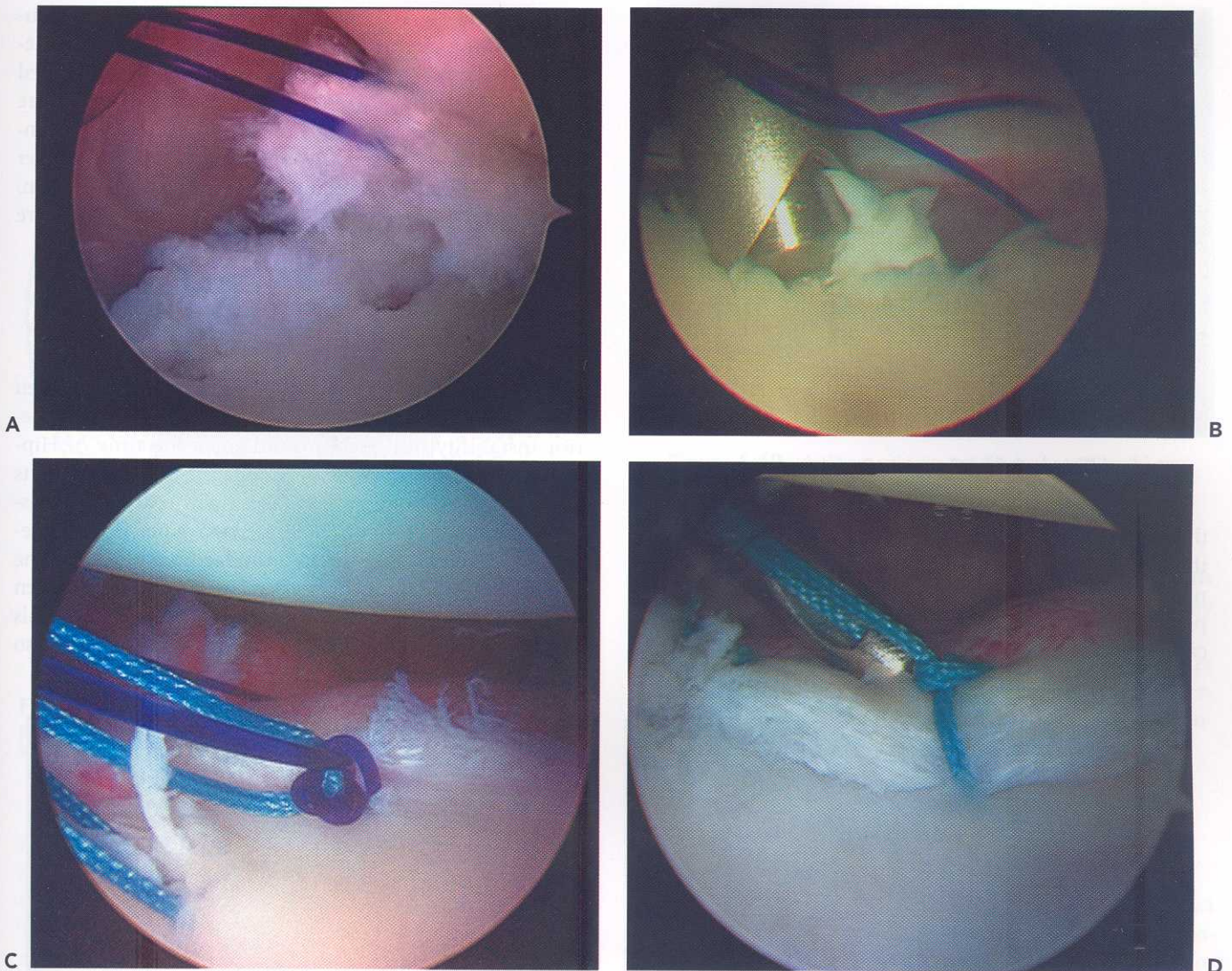


Figure 1-15 (A) Arthroscopic view of suture first technique. "O" PDS placed inferiorly and traction applied. (B) Anchor placement more cephalad to suture so that with eventual knot tying labrum and capsule shifted superiorly. (C) Nonabsorbable suture being shuttled with "O" PDS. (D) Knot tying.

rior to the biceps anchor. Generally, the anchor anterior to the biceps can be placed, using the anterior superior portal.

The Rotator Interval

The rotator interval is an important anatomical region with respect to anterior inferior shoulder stability. The anatomical region is defined as the articular capsule bounded superiorly by the anterior portion of the supraspinatus tendon, inferiorly by the superior portion of the subscapularis tendon, medially by the base of the coracoid process, and laterally by the long head of the biceps tendon. The capsular tissue is reinforced by the coracohumeral ligament and the superior glenohumeral ligament.

The rotator interval is of variable size and is present in the fetus as well as in the adult.¹² Harryman et al. found that sectioning the rotator interval in cadaveric specimens resulted in increased glenohumeral translation in all planes tested.²² Imbrication of rotator interval lesions resulted in a decreased posterior and inferior glenohumeral translation when compared to the intact state. Gartsman found that repair of the rotator interval was a critical factor in 14 of 53 shoulders treated arthroscopically for anterior inferior glenohumeral instability and contributed to the improved clinical outcomes observed in the study.¹⁸ Field et al. reported good or excellent results in 15 patients who underwent surgical repair of isolated rotator interval defects.¹⁷

Many authors have reported techniques enclosing the rotator interval.^{13,19,27,40,59} There are various techniques

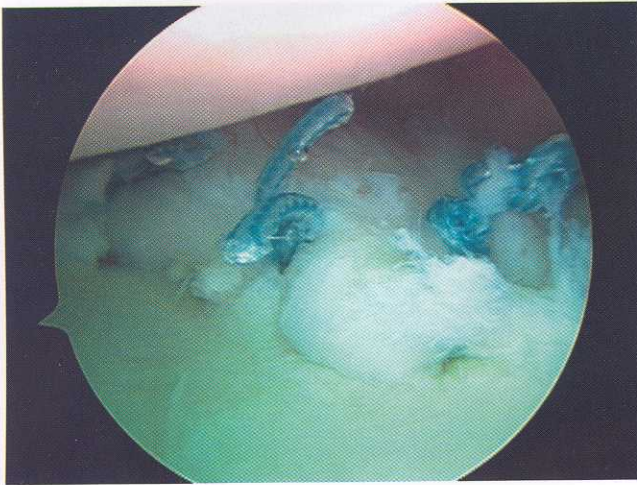


Figure 1-16 Complete Bankart repair.

that have been published. There is no literature evaluating the type of suture material that ensures success. One technique involves removing the anterior inferior cannula and placing all instrumentation through the anterior superior cannula. The MGHL and/or a small portion of the sub-

scapularis is pierced with either a spinal needle or suture shuttling device, and a monofilament suture is deployed (Fig. 1-17A). The SGHL/CHL complex is pierced with a penetrator and grasps the monofilament suture (Fig. 1-17B). This tissue can then be tied through a cannula internally or externally with a guillotine knot cutter (Fig. 1-17C). The final repair involves capsular plication, anterior inferior labral repair, and rotator interval closure (Fig. 1-18).

Thermal Energy Applied to the Anterior Inferior Instability

The concept of using heat to alter the structure of collagen and affect changes in tissue length in treating anterior inferior instability has been around since the time of Hippocrates. Thermal treatment of collagen molecules affects the heat-labile bonds, and, as these re-form, the overall tissue length decreases.¹⁶ There are two types of radiofrequency circuitry for the use in orthopaedic application. The monopolar radiofrequency system uses a current between the treatment probe and the grounding pad or plate. This current passes through the tissue, releasing energy into it so

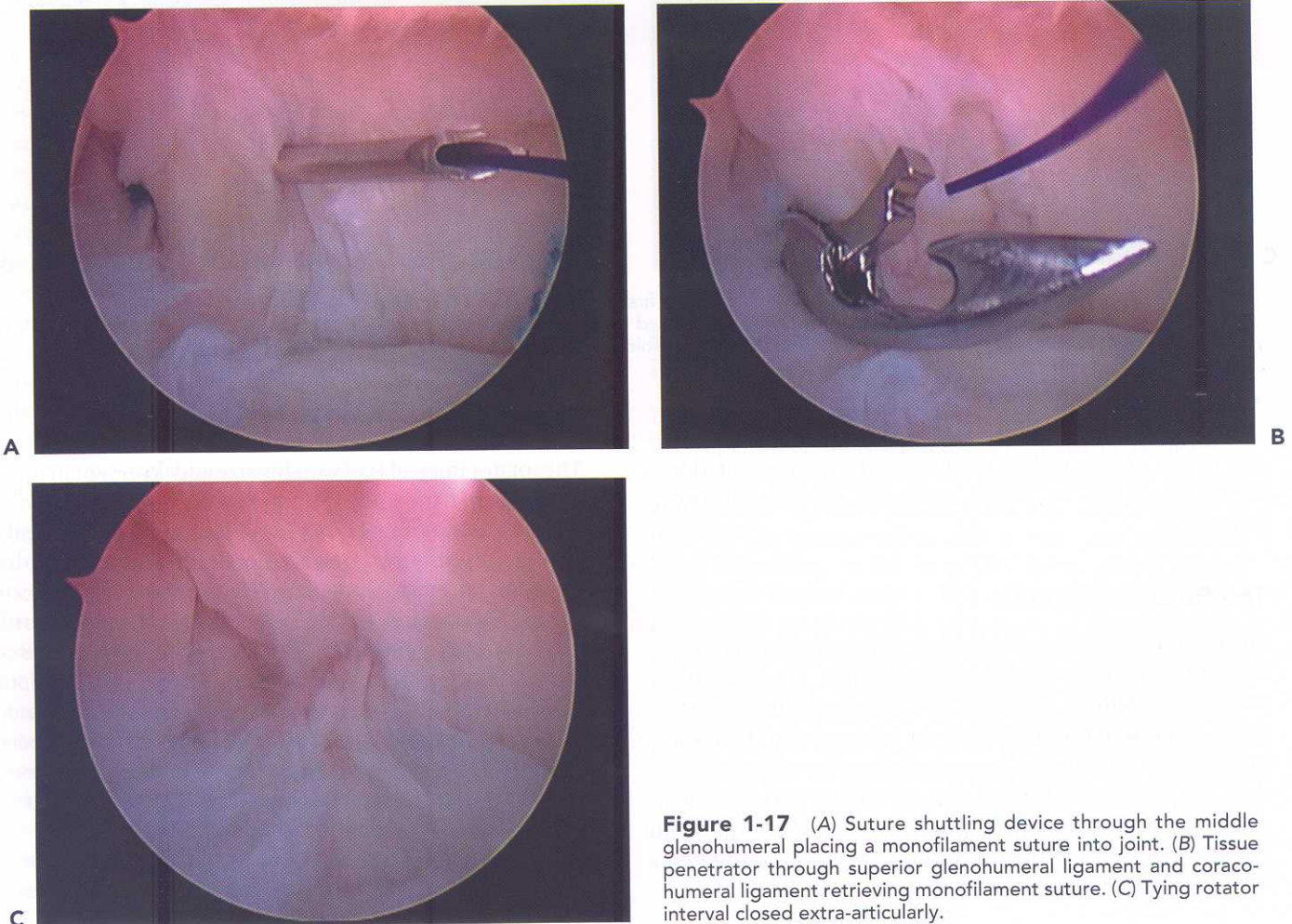


Figure 1-17 (A) Suture shuttling device through the middle glenohumeral placing a monofilament suture into joint. (B) Tissue penetrator through superior glenohumeral ligament and coracohumeral ligament retrieving monofilament suture. (C) Tying rotator interval closed extra-articularly.

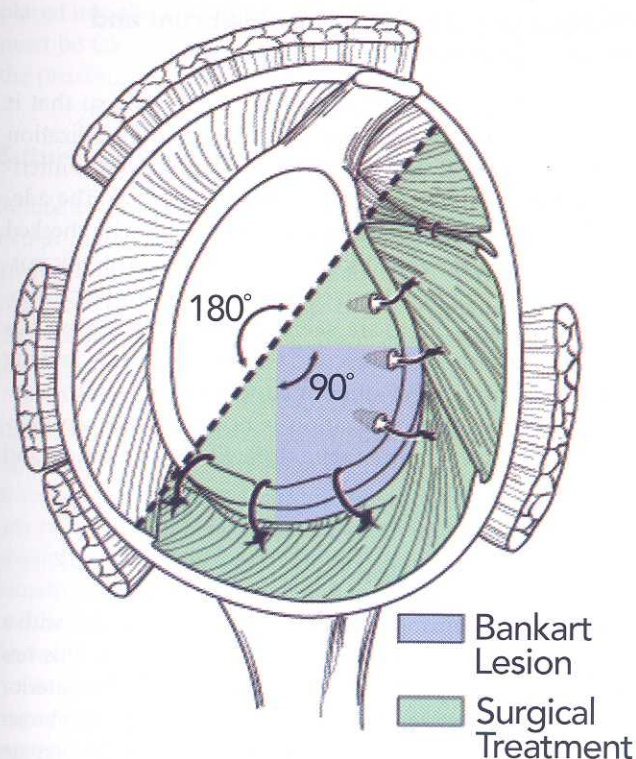


Figure 1-18 Example of 180-degree repair with three inferior plication sutures, three anchors repairing the labrum, and rotator interval closure.

that the tissue becomes hot, not the probe. Lintner and Speer have shown that the thermal effect gradient seen up to a depth of 4.5 mm is adequate for capsular response.³² The bipolar radiofrequency device applies energy by having a current flow from the tip of the probe through the irrigating solution and back to the probe. This causes very high temperatures at the probe. This applies a very high tissue temperature with the very little or low depth of penetration, which is 1 mm or less.

The proposed technique offering the greatest benefit with the least amount of potential complication is the "striping" pattern technique, which leaves a 1- to 2-mm space between each row (Fig. 1-19). This is done to the anterior band, posterior band, and axillary pouch of the shoulder. This has been shown to significantly reduce the anterior translation of the humeral head.⁵⁸ Clinically, success has been found with this technique in high-level throwing athletes who have been treated with thermal augmentation for internal impingement.³¹

There have also been cases of dramatic failures to go along with this success. Cases of complete capsular necrosis and ablation following thermal treatment have been reported.⁴⁹ There has also been injury to the axillary nerve that lies close to the inferior capsule at the 6 o'clock position.¹⁶ The overall axillary nerve injury incidence has been reported at 1.4% (196 out of 236,015), with most cases involving the sensory portion of the nerve and then sponta-

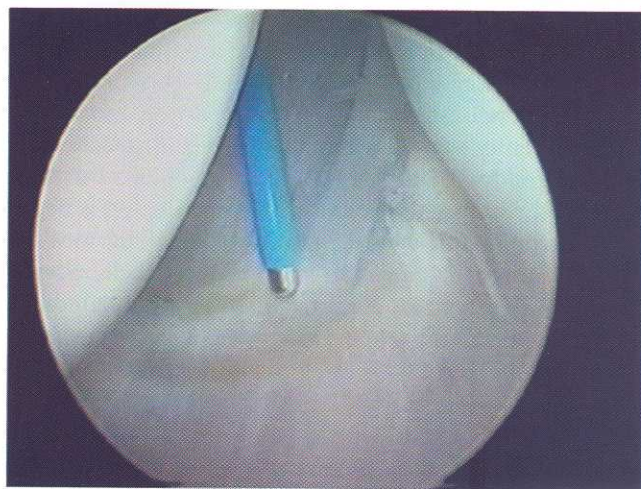

Figure 1-19 Arthroscopic view of thermal capsulorrhaphy.

neously resolving. Stiffness is also a complication of this procedure.⁶⁴ Shoulder proprioception is not influenced by the application of thermal energy.³⁰

The use of thermal alteration in the aid of elite athletes with traumatic anterior instability has yet to be determined. The indications for thermal energy are for augmentation after the anatomy has been repaired.

POSTOPERATIVE CARE

The biological healing response of the inferior capsule after plication, the inferior glenohumeral ligament and the anterior inferior labral complex to bone, and the rotator interval must be respected. One observation that may have led to some of the earlier anterior inferior arthroscopic failures has been the concept that due to significant reduction in pain postoperatively, these patients move their arms more with stress to the repair and eventually failure of it. The first concern when addressing postoperative success is maintenance of anterior inferior stability. The second concern is the restoration of adequate motion, specifically external rotation. The third concern is a successful return to sports or the physical activities of daily living in a reasonable amount of time.

The University of Connecticut postoperative protocol for anterior inferior instability treated by arthroscopy involves immobilization in an abduction arthrosis. This allows the arm to be fixed in a slight amount of external rotation. Codman exercises combined with pendulum exercises are started immediately. Active assisted range-of-motion exercises, external rotation (0–30 degrees), and forward elevation (0–90 degrees) are started at this time. This regime is maintained for the first 6 weeks. From 6 weeks to 12 weeks, active assisted as well as active range-of-motion exercises are started, with the goal as establish-

ing full range of motion. No strengthening exercises or any type of repetitive exercises are started until after full range of motion has been established. This protocol is based on tendon-to-bone healing in a dog model.^{46,54} Early resistance exercises and aggressive postoperative rehabilitation do not appear to offer substantial advantages and could compromise the repair. Strengthening is begun once there is full, painless, active range of motion. Strengthening is begun at 12 weeks to 16 weeks. Sports-specific exercises are then started at 16 weeks to 20 weeks, and between 20 and 24 weeks contact athletics are initiated. The use of cold therapy devices has been successful in reducing postoperative pain.

Pagnani and Dome reported on open stabilization in American football players.⁴² Their postoperative program is quite similar to ours as mentioned here for further reference. At 0 to 4 weeks, the arm is immobilized with a sling and internal rotation, double range-of-motion, and pendulum exercises are begun. From 4 to 8 weeks, passive- and active-assisted shoulder range-of-motion exercises with external rotation limited to 45 degrees is done. When 140 degrees of active forward elevation is obtained, rotator cuff strengthening is begun, with internal and external rotation strengthening completed with the arm at a low abduction. From 8 to 12 weeks, they start deltoid isometric exercises with the arm in low abduction angles, as well as body blade exercises. They then slowly increase abduction during rotator cuff and deltoid strengthening. Scapular rotator strengthening and horizontal abduction exercises are also begun. From 12 to 18 weeks, restoration of terminal external rotation is achieved. Proprioceptive neuromuscular feedback patterns are employed, and plyometric exercises as well as sports-specific motion using pulley, wand, or manual resistance are begun. After 18 weeks or later, conventional weight training is begun and rehabilitation is orientated toward return to sports, progressing from field drills to contact drills. They report using an abduction harness for selected football positions (linemen). They return to full contact when abduction and external rotation strength are symmetrical on manual muscle testing.⁴²

TECHNICAL ERRORS

For successful treatment of arthroscopic anterior inferior instability adequate visualization is imperative. The lateral decubitus position with a traction device has been able to provide both vertical distraction, enabling the humeral head to float superiorly, and horizontal distraction, pulling the humeral head inferiorly. Traction allows the surgical team to work unencumbered by not having to hold the arm. If adequate visualization of the anterior inferior glenoid and pathology cannot be established, an open procedure is recommended.

Mobilization of the Glenoid Labrum and Inferior Glenohumeral Ligament

The labral capsular complex must be elevated so that it floats to the level of the glenoid. Adequate mobilization both anteriorly off the neck of the glenoid as well as inferiorly down to the 6 o'clock position is essential. The adequate release and mobilization of the tissue can be checked in two ways. First, while looking through the posterior portal, the scope can be advanced over the anterior labral rim; if subscapularis fibers are seen, an adequate release has been accomplished. The second way to check is by moving the arthroscope to the anterior superior portal and visualizing inferiorly. If mobilization is not complete capsulorrhaphy, labral repair and tissue shift will be incomplete and may lead to failure.

Glenoid Preparation

The anterior inferior glenoid neck must be debrided with a shaver or burr to a bleeding bed. To ensure that this has been adequately performed, viewing through the anterior superior portal or viewing with a 70-degree scope can be accomplished. A rasp or shaver blade can be used to prepare the inferior capsule. Failure to prepare the bed for soft tissue placement may lead to incomplete healing.

Incorrect Portal Placement

Portal placement is critical to the adequate visualization as well as execution of an arthroscopic anterior inferior stabilization using capsular plication and suture anchors. In establishing the first portal, generally the posterior portal, in the lateral position, it is important to make this slightly more lateral than normal. Obviously, a direct entrance from the posterior skin through the infraspinatus muscle through the capsule is ideal. However, if an error is going to be made, or if the patient is a large person, the portal should be placed more laterally. Medial portal placement in the lateral position will force the arthroscope to be placed at an angle where it has to look over the posterior glenoid. This will make many of the following procedures more difficult. If the surgeon needs to look over the top of the glenoid, a new posterior inferior portal should be established immediately. If the surgeon is worried about extravasation of fluid into the posterior compartment, or fluid dynamics are altered by making a second portal posteriorly, a cannula can be placed in this portal and just not used. This will seal off all potential extravasation of fluid.

When establishing the anterior portals, two important concepts must be maintained. The first is the concept that the two cannulas should be separated as far from each other as possible both internally and externally. This allows for easier passage when shuttling sutures. The second concept is to make sure that the anterior superior portal is not

placed into the posterior aspect of the biceps. If it does, care must be taken not to shuttle sutures around, thus locking the proximal biceps tendon in the suture loop.

Suture Anchors

Suture anchor placement should be 2 to 3 mm on the articular margin. Visualization should be maintained as the anchor is inserted. An improper anchor insertion angle can cause articular surface damage or inadequate bone placement, allowing anchor migration and possible articular cartilage damage.

Two types of anchors are available on the market, metal and bioabsorbable. Each has its advantages and disadvantages. Metal anchors can generally be inserted after drilling or punching, thus eliminating a potential step in the process of insertion. Also, these are mechanically stronger, so physical anchor breakage is not as common. The problem sometimes encountered is that in long-term follow-ups, the anchor or cartilage will subside and there may be erosion of the metal anchor on the articular surface.

Bioabsorbable anchors have the advantage of being incorporated into the body over time but have the disadvantage of having various amounts of reactions to this process. They generally require an additional step, which would be a drill or punch, tap, then anchor placement. This can lead to anchor-hole mismatch, which may cause anchor fracture. The advantage of the bioabsorbable anchor at this point is that a second anchor can be placed right on top of the first anchor by either retapping or drilling the original hole. The bioabsorbable anchors also have the advantage of having a suture loop placed inside of them (Arthrex, BioFastTac, and BioSutureTac, Naples, FL), in which a suture is embedded into the bioabsorbable anchor. This will allow for consistent sliding of variable sutures.

Suture Shuttling and Knot Tying

A significant amount of frustration can surround passing the suture through the tissue. It is important to make sure that the suture shuttled through the tissue is inferior to the anchor, allowing a superior shift of tissue. This can be done either directly, with a sharp penetrator, by penetrating the tissue, grabbing the sutures, and then pulling the sutures out, or indirectly, with a shuttle system, by using a suture-passing device that passes a monofilament suture into the tissue. This is then retrieved through a cannula, and the suture to be shuttled through is then tied to this and is brought back through the tissue. Tangling and confusion of the sutures can occur at this time, and it is important to be very methodical. Also, anchor unloading can occur at this point. To prevent this, the arthroscope should visualize the anchor directly. If both limbs of the suture are seen moving, then the anchor is being unloaded. This is fine for the initial portion because the loop is pulled out of the cannula.

However, once the loop is out of the cannula, special attention should be paid that no further suture is removed from the anchor. It may be difficult to determine which one this is, so, while looking at the anchor, pull on one limb and, if there is no further movement of the suture through the anchor, then this is the free limb and it can be removed without further concern. For further safety, a hemostat can be placed on the limb that is not sutured, not allowing it to be pulled through the cannula. Although sometimes time-consuming and cumbersome, these small checks can prevent the unfortunate complication of an unloading anchor. If sutures do become tangled intra-articularly (Fig. 1-20), the suture needs to be withdrawn from the joint, pulled out of the cannula, the suture untied, before the process can proceed. If there is not enough room or remaining suture length, a second suture can be tied to the end of the tangled suture, and this can be pulled through, allowing more length of the suture to be untied outside of the cannula and then easily brought back in through the anchor.

There are two classifications of knots that can be tied. The first is the sliding knot; the second, the nonsliding knot. It is not the purpose of this chapter to describe all of the different knots that are available. However, it is important to realize that this is a potential area of difficulty, if the knot prematurely locks or if there is not either knot security or loop security. It is important to observe in the tissue after tying the initial throw that all the excess suture has been taken out of the system and that the knots and loops are indenting the tissue. If this has not been achieved, then the knots should not be locked until this is observed. To avoid twisting of the sutures and loose knots, the knot pusher can be placed on one of the limbs. This is then slid down, and, if there is a twist, it can be untwisted at this time; also, any other abnormalities in the suture can be observed. If a knot prematurely locks or if it is tied and it is not securing the tissue adequately, a second anchor and suture must be placed

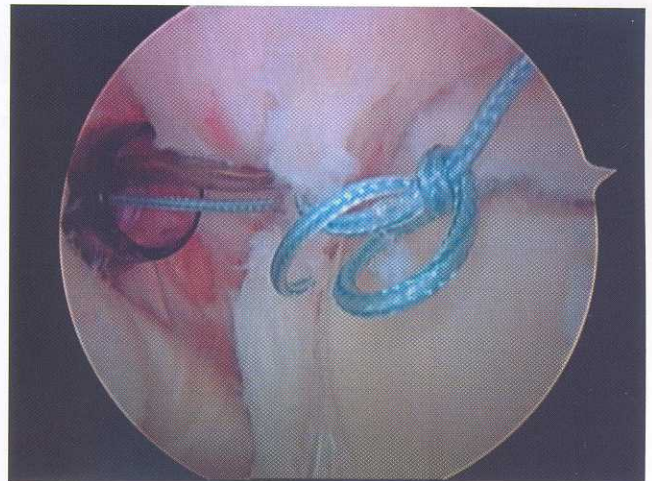

Figure 1-20 Example of suture tangled in the shoulder.

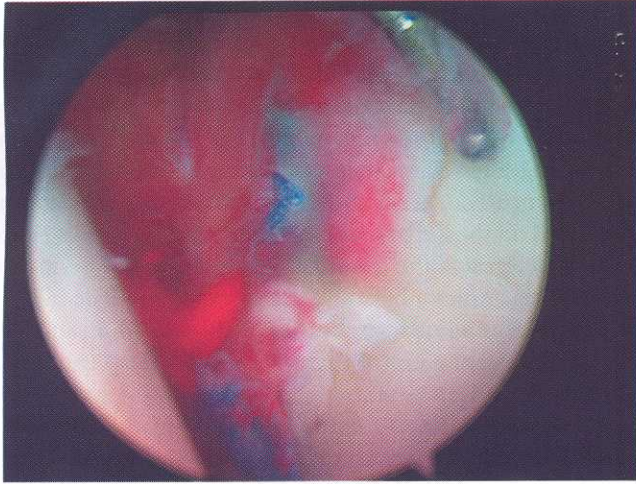


Figure 1-21 Example of labral repair three weeks after arthroscopic repair.

as close to the original knot as possible. A loose knot will never get stronger over time.

Postoperative Glenohumeral Noise

This is an inconsistent physical exam finding that occasionally plagues the postoperative course. Normally, there is a synovialization of the sutures (Fig. 1-21). If this does not happen, a squeak can be detected that may necessitate the removal of the knot after healing has been established.

Overall Operative Failure/Redislocation

Arthroscopic stabilization for anterior inferior instability has evolved over the past 25 years. It is quite difficult to compare redislocation rates and subluxation rates with

those techniques used in the past. This discussion will attempt to focus on techniques that are similar to what have been described previously. Abrams et al. reported on 662 patients with traumatic anterior instability treated by suture anchor reconstruction techniques with a minimum of a 2-year follow-up. They reported 35 recurrences for a stabilization rate of 95%.¹ Romeo et al. reported on 45 patients with a follow-up of 2 years, with no reports of recurrent dislocation and 96% experiencing good-to-excellent results.⁴⁸ In patients at the highest risk, which were high-school contact athletes, specifically football players, Mazzocca et al. reported on 18 collision athletes in high school.³⁶ They had an average return to contact competition after 6 months and had two subluxation events for a recurrence rate of 15%. It is important to note when evaluating the literature whether recurrences are subluxations that prevent the athletes from returning to their sport versus redislocation. A recurrence is any subluxation event that causes the athlete to lose a day of practice. It is then noted whether they require further stabilization or whether they can return to play unencumbered. The 15% arthroscopic recurrence rate is quite similar to that noted by Uhorchak.⁶¹ Bacilla et al. reported a 10% failure rate with recurrent subluxation in a study population that included 21 American football players.⁴ Pagnani et al. reported 52 out of 58 patients returned to full participation in American football for at least one year. They had two patients, with subluxation events, who did not require further treatment.⁴²

Current arthroscopic stabilization techniques utilize suture anchors, permanent suture, and address capsular redundancy with plication techniques. The arthroscopic technique now mirrors more closely the open method and, consequently, more recent reports demonstrate results that are comparable. The rates of recurrence (dislocation and

TABLE 1-1
ARTHROSCOPIC RECONSTRUCTION USING SUTURE ANCHORS

Author	# of Pt	Mean F/U(mon)	Recurrence (%)	Comments
Wolf (1993)	50	"short"	0	
Belzer (1995)	37	22	11	13%→"Apprehension"
Hoffman (1995)	30	24	11	
Guanche (1996)	25	27	33	Comparative series
Bacilla (1997)	40	30	7	High-demand patients
Sisto (1998)	27	47	13	Refined indications
Field (1999)	50	33	8	Comparative series
Romeo(2000)	32	26	0	3-4 anchors/shoulder
Gartsman (2000)	53	33	8	"Rx all pathology"
Mishra (2001)	42	28	7	RF augmentation
Kim (2002)	58	39	10	Comparative series
Abrams (2002)	61	35	6.6	

SUMMARY: Current techniques can lead to "success" rate greater than 90%.

TABLE 1-2
COMPARISON OF SAME SURGEON ARTHROSCOPIC VS. OPEN STABILIZATION (VARIED TECHNIQUES)

Author	# of Pt Scope/Open	Mean F/U(mo) Scope/Open	Recurrence (%) Scope/Open
Geiger (1993)	16/8	23/24	43/8
Guanche (1996)	25/12	27/25	33/8
Steinbeck (1998)	30/32	36/40	17/6
Field (1999)	50/50	33/30	8/0
Cole (2000)	37/22	52/55	24/18
Karlsson (2001)	66/53	32	15/10
Sperber (2001)	30/26	13/10	23/12
Kim (2002)	30/58	39	10/10

subluxation) results in at-risk collision athletes, and outcomes have been similar with both methods. Table 1-1 and Table 1-2 are a compilation of studies addressing the open-versus-arthroscopic issue.

In cases of recurrent subluxation or recurrent dislocation, either open stabilization for recurrence or arthroscopic stabilization can be performed. In either case, we recommend arthroscopic examination of the glenohumeral joint to assess any or all pathology. If, upon assessment of the intra-articular pathology, there is a recurrent Bankart lesion, or if, in the original surgery, inferior plication and rotator interval closure were not accomplished, there does not seem to be a contraindication to revising with arthroscopic techniques. If in fact this is not the case, and the surgeon along with the patient feel that an open procedure would be more reliable, then this is absolutely indicated at this time as well.

ACKNOWLEDGMENTS

The authors would like to specifically acknowledge the following people for their efforts in preparation of this manuscript. These efforts all go beyond their job description: Anita M. Fowler, Sue Ellen Pelletier, Nancy Ortiz, Sandy Tolisano, Steve Santangelo, Carl W. Nissen, MD, and Joanne D'Aprile. We would also like to acknowledge the residents and fellows at both the University of Connecticut Health Center and Rush-Presbyterian St. Luke's Medical Center for their inspiration.

REFERENCES

- Abrams JF, Savoie FH, Tauro JC, et al. Recent advances in the evaluation and treatment of shoulder instability: anterior, posterior, and multidirectional. *Arthroscopy* 2002;18(9):1.
- Alberta FG, Teruhisa Mihata, McGarry MH, et al. Arthroscopic antero-inferior suture plication results in decreased glenohumeral translation and external rotation in an anterior instability model. Submitted for presentation at the AAOS 2004 Specialty Day, San Francisco, CA, March 13, 2004.
- Bach BR Jr, Warren RF, Fronck J. Disruption of the lateral capsule of the shoulder: a cause of recurrent dislocation. *J Bone Joint Surg Br* 1988;70(2):274.
- Bacilla P, Field LD, Savoie FH. Arthroscopic Bankart repair in a high demand patient population. *Arthroscopy* 1997;13(1):51.
- Bankart ASB. The pathology and treatment of recurrent dislocation of the shoulder joint. *Br J Surg* 1938;26:23.
- Bigliani LU, Pollack RG, Soslowsky LG. Tensile properties of the inferior glenohumeral ligament. *J Orthop Res* 1992;10:187.
- Bigliani LU, Newton PM, Steinmann SP, et al. Glenoid rim fractures associated with a current anterior dislocation of the shoulder. *Am J Sports Med* 1998;26:41.
- Bui-Mansfield LT, Taylor DC, Uhorchak JM, et al. Humeral avulsion to the glenohumeral ligament: imaging features in a review of the literature. *Am J Roentgenol* 2002;179(3):649.
- Burkhart SS, De Beer JF. Traumatic glenohumeral bone defects and their relationship to failure of arthroscopic Bankart repairs: significance of the inverted pear glenoid and the humeral engaging Hill-Sachs lesion. *Arthroscopy* 2000;16(7):677.
- Burkhart SS, DeBeer JF, Tehrany AM, et al. Quantifying glenoid bone loss arthroscopically in shoulder instability. *Arthroscopy* 2002;18(5):488.
- Cole BJ, Romeo AA. Arthroscopic shoulder stabilization with suture anchor: technique, technology, and pitfalls. *Clin Orthop* 2001;390:17.
- Cole BJ, Rodeo SA, O'Brien SJ, et al. The anatomy and histology of the interval capsule of the shoulder. *Clin Orthop* 2001;390:129.
- Cole BJ, Mazzocca AD, Meneghini RM. Indirect arthroscopic rotator interval repair. *Arthroscopy* 2003;19(6):E28-31.
- DeBerardino TM, Tenuta JJ, Arciero RA. Combined Bankart and unstable superior labral lesions associated with acute initial anterior shoulder dislocations: evaluation, treatment, and early results. Presented at the 66th annual meeting of the American Academy of Orthopedic Surgeons, Anaheim, CA, February 7, 1999.
- Ellman H, Gartsman GM. *Arthroscopic shoulder surgery and related procedures*. Philadelphia, Lea & Febiger, 1993.
- Fanton GS. Monopolar electrothermal arthroscopy for treatment of shoulder instability in the athlete. In: Drez D, DeLee JC, eds. *Operative techniques in sports medicine*. vol 8. Philadelphia, WB Saunders, 2000:242.
- Field LD, Warren RF, O'Brien SJ, et al. Isolated closure of rotator interval defects for shoulder instability. *Am J Sports Med* 1995;23(5):557.
- Gartsman GM, Roddey TS, Hammerman SM. Arthroscopic treatment of anterior inferior glenohumeral instability: two- to five-year follow-up. *J Bone Joint Surg* 2000;82A:991.

19. Gartsman GM, Taverna E, Hammerman SM. Arthroscopic rotator interval repair in glenohumeral instability: description of an operative technique. *Arthroscopy* 1999;15(3):330.
20. Gohlke F, Essigkrug B, Schmitz F. The pattern of the collagen fiber bundles of the capsule of the glenohumeral joint. *J Shoulder Elbow Surg* 1994;3:111.
21. Harryman DT, Ballmer FP, Harris SL, et al. Arthroscopic labrum repair to the glenoid rim. *Arthroscopy* 1994;10:20.
22. Harryman DT, Sidles JA, Harris SL, et al. The role of the rotator interval capsule in passive motion and stability of the shoulder. *J Bone Joint Surg* 1992;74A:53.
23. Itoi S, Newman SR, Kuechle DK, et al. Dynamic anterior stabilizers of the shoulder with the arm in abduction. *J Bone Joint Surg Br* 1994;76B:834.
24. Jobe CM. Posterior superior glenoid impingement: expanded spectrum. *Arthroscopy* 1995;11:530.
25. Jobe FW, Giangarra CE, Kvitne RS, et al. Anterior capsulolabral reconstruction of the shoulder in athletes in overhand sports. *Am J Sports Med* 1991;19:428.
26. Johnson L. Techniques of anterior glenohumeral ligament repair. In: Johnson L, ed. *Arthroscopic surgery: principles and practice*. 3rd ed, vol 2. St. Louis, CV Mosby, 1986:1405.
27. Karas SG. Arthroscopic rotator interval repair and anterior portal closure: an alternative technique. *Arthroscopy* 2002;18:436.
28. Koss S, Richmond JC, Woodward JS. Two- to five-year follow-up of arthroscopic Bankart reconstruction using suture anchor technique. *Am Orthop Soc Sports Med* 1997;25(6):809.
29. Lephart SM, Warner JP, Borsa PA, et al. Proprioception of the shoulder joint in healthy, unstable, and surgically repaired shoulder. *JSES* 1994;3(6):371.
30. Lephart SM, Myers JB, Bradley JP, et al. Shoulder proprioception and function following thermal capsulorrhaphy. *Arthroscopy* 2002;18(7):770.
31. Levitz CL, Dugas J, Andrews JR. The use of arthroscopic thermal capsulorrhaphy to treat internal impingement in baseball players. *Arthroscopy* 2001;17(6):573.
32. Lintner SA, Speer KE. Traumatic anterior glenohumeral instability: the role of arthroscopy. *J Am Acad Orthop Surg* 1997;5:233.
33. Lo IK, Burkhart SS. Biomechanical principles of arthroscopic repair of the rotator cuff. In: Romeo AA, Mazzocca AD, eds. *Oper Tech Orthop* 2002;12(3):152.
34. Matsen FA, Thomas FC, Rockwood CA Jr. Anterior glenohumeral instability. In: Rockwood CA Jr., Matsen FA, eds. *The shoulder*. 1st ed, vol 1. Philadelphia, JB Lippincott, 1990:526.
35. Matsen FA, Thomas FC, Rockwood CA, et al. Glenohumeral instability. In: Rockwood CA Jr., Matsen FA, eds. *The shoulder*. 2nd ed, vol 2. Philadelphia, WB Saunders, 1990:633.
36. Mazzocca AD, Brown FM, Carrier DS, et al. Arthroscopic anterior stabilization of collision and contact athletes. *Am J Sports Med* 2005;33:52-60.
37. Morgan CD, Burkhart SS, Palmeri M, et al. Type II SLAP lesions: three subtypes and their relationships to superior instability and rotator cuff tears. *Arthroscopy* 1998;14(6):553.
38. Neviaser TJ. The anterior labral ligamentous periosteal sleeve avulsion lesion: a cause of anterior instability of the shoulder. *Arthroscopy* 1993;9(1):17.
39. Nicola T. Anterior dislocation of the shoulder: the role of the articular capsule. *J Bone Joint Surg* 1942;25:614.
40. Nobuhara K, Ikeda H. Rotator interval lesion. *Clin Orthop* 1987;223:44.
41. O'Brien SJ, Neves MC, Arnoczky SP. The anatomy and histology of the inferior glenohumeral ligament complex to the shoulder. *Am J Sports Med* 1990;18:579.
42. Pagnani MJ, Dome DC. Surgical treatment of traumatic anterior shoulder instability in American football players. *J Bone Joint Surg* 2002;84A(5):711.
43. Perthes G. Über operationen bei: habitueller schulterluxation. *Dtsch Ztschr Chir* 1906;85:199.
44. Reeves B. Acute anterior dislocation of the shoulder: clinical and experimental studies. *Ann R Coll Surg Engl* 1969;44:65.
45. Ribbans WJ, Mitchel R, Taylor JG. Computerized arthrotopography of primary anterior dislocation of the shoulder. *J Bone Joint Surg* 1990;72B:181.
46. Rodeo SA, Arroczhy SP, Tobilli PA, et al. Tendon healing in a bone tunnel: a biomechanical and histological study in the dog. *J Bone Joint Surg* 1993;75A(12):1795.
47. Rokous JR, Feagin JA, Abbott HG. Modified axillary roentgenogram. A useful adjunct in the diagnosis of recurrent instability of the shoulder. *Clin Orthop* 1972;82:84.
48. Romeo AA, Cohen BS, Carreira DF. Traumatic anterior shoulder instability. In: Drez D, DeLee JC, eds. *Operative techniques in sports medicine*. vol 8. Philadelphia, WB Saunders, 2000:188.
49. Romeo AA, Cole BJ, Mazzocca AD, et al. Autologous chondrocyte repair of an articular defect in the humeral head. *Arthroscopy* 2002;18(8):925.
50. Rowe CR, Zarins B. Recurrent transient subluxation of the shoulder. *J Bone Joint Surg* 1981;63:863.
51. Savoie FH, Field LD, Atchinson S. Anterior superior instability with rotator cuff tearing: SLAC lesion. *Oper Tech Sports Med* 2000;8(3):221.
52. Spear KP, Deng X, Borero S. Biomechanical evaluation of a simulated Bankart lesion. *J Bone Joint Surg* 1994;76A:1819.
53. Stoller DW. MR arthrography of the glenohumeral joint. *Radiol Clin N Am* 1997;35(1):97.
54. St Pierre P, Olsen E, Elliott JJ, et al. Tendon healing to cortical bone compared with healing to a cancellous trough. *J Bone Joint Surg* 1995;77A(12):1858.
55. Sugaya H, Moriishij J, Dohi M, et al. Glenoid rim morphology in recurrent anterior glenohumeral instability. *J Bone Joint Surg* 2003;85A(5):878.
56. Taylor BC, Arciero RA. Pathologic changes associated with shoulder dislocations. Arthroscopic and physical examination findings in first-time traumatic anterior dislocations. *Am J Sports Med* 1997;25:306.
57. Tibone JE, Lee TQ, Black Ad, et al. Glenohumeral translation after arthroscopic thermal capsuloplasty. *J Shoulder Elbow Surg* 2000;9(6):514.
58. Tibone JE, McMahon RJ, Shrader TA, et al. Glenohumeral translation after arthroscopic, nonablative, thermal capsuloplasty with a laser. *Am J Sports Med* 1998;26:495.
59. Treacy SH, Field LD, Savoie FH. Rotator interval capsule closure: an arthroscopic technique. *Arthroscopy* 1997;13(1):103.
60. Turkel SJ, Panio MW, Marshall JL. Stabilizing mechanism preventing anterior dislocation of the glenohumeral joint. *J Bone Joint Surg* 1981;63B:1208.
61. Uhorchak JM, Arciero RA, Huggard D, et al. Recurrent shoulder instability after open reconstruction in athletes involved in collision and contact sports. *Am J Sports Med* 2000;28:794.
62. Uribe JW, Heckman KS, Vijac JE. Arthroscopic Bankart suture repair for recurrent anterior shoulder instability: 51 cases with a minimum two-year follow-up. *Arthroscopy* 1994;10(3):349.
63. Wolf EM, Cheng JC, Dickson K. Humeral avulsion of glenohumeral ligaments as a cause of anterior shoulder instability. *Arthroscopy* 1995;11(5):600.
64. Wong KL, Williams GR. Complications of thermal capsulorrhaphy of the shoulder. *J Bone Joint Surg* 2001;83A(suppl 2):151.