

# Reconstruction of the glenohumeral joint using a lateral meniscal allograft to the glenoid and osteoarticular humeral head allograft after bipolar chondrolysis

L. Pearce McCarty, III, MD,<sup>a</sup> and Brian J. Cole, MD, MBA,<sup>b</sup> Edina, MN, and Chicago, IL

**C**hondrolysis of the glenohumeral joint has been reported to occur after the use of thermal energy, bioabsorbable intraarticular implants, intraarticular infusion of bupivacaine, and intraarticular injection of gentian violet dye, as well as after otherwise uncomplicated cases of shoulder arthroscopy during which no such etiologic factors can be identified.<sup>2,7,11,14,18,22</sup> Chondrolysis can result in devastating loss of cartilage, producing significant pain and functional impairment. Treatment can be challenging, because patients are often young and otherwise healthy and place high functional demands on their shoulders.

Nonoperative therapy is often inadequate given the high functional demands.<sup>2,6</sup> Arthroscopic débridement may provide temporary relief, but having no restorative properties, is not likely to be a durable treatment option. Reparative and restorative treatment options such as microfracture and autologous chondrocyte implantation may prove successful in the context of focal chondral lesions but are unlikely to be viable strategies for the diffuse cartilage loss associated with chondrolysis.<sup>9,19,21</sup> Total joint arthroplasty with traditional bearing surfaces may not be an attractive option in a young population because of concerns about functional limitation, prosthetic loosening, destruction of glenohumeral bone stock, and difficulty of revision surgery.<sup>14</sup>

In young, active patients who have failed nonoperative and arthroscopic modalities, a biologic joint resurfacing procedure may offer a salvage option that is preferable to traditional total shoulder arthroplasty. We present a case of bipolar glenohumeral chondrolysis after arthroscopic thermal capsulorrhaphy treated with a humeral head osteochondral allograft and interpositional lateral meniscal allograft to the glenoid.

From the <sup>a</sup>Sports and Orthopaedic Specialists, PA, and <sup>b</sup>Department of Orthopedics and Anatomy, Rush Cartilage Restoration Center, Rush University Medical Center.

Reprint requests: L. Pearce McCarty, III, MD, Sports and Orthopaedic Specialists, PA, 8100 W 28th St, Suite 225, Edina, MN 55439. [E-mail: pmccaty@alumni.brown.edu].

J Shoulder Elbow Surg 2007;xx:xxx.

Copyright © 2007 by Journal of Shoulder and Elbow Surgery Board of Trustees.

1058-2746/2007/\$32.00

doi:10.1016/j.jse.2006.10.018

## CASE REPORT

A 16-year-old right-hand-dominant girl, who was a competitive gymnast, complained of chronic right shoulder pain during activity. She was evaluated at another institution and diagnosed with anterior instability of the glenohumeral joint. Physical therapy was unsuccessful, and she underwent right shoulder arthroscopic stabilization, during which the anterior capsule was treated with a radiofrequency energy (RFE) device.

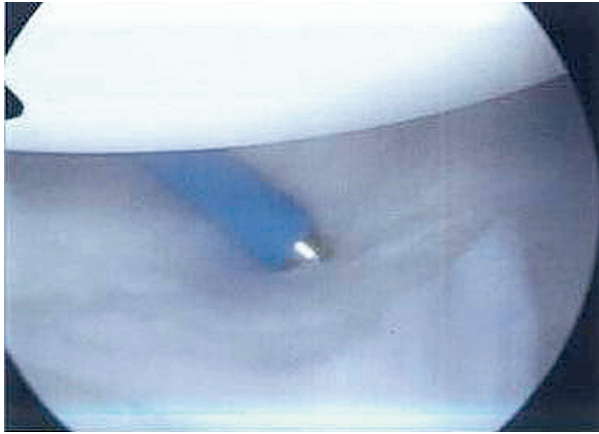
Arthroscopic images at the time of the index procedure showed normal appearing anterior capsular structures and normal appearing articular cartilage covering both glenoid and humeral head (Figure 1). An intraarticular pain catheter or pain pump was not used postoperatively.

Several months after the procedure, she reported continued right shoulder pain and progressive loss of motion. One year postoperatively, because of her unremitting symptoms and failure to respond to nonoperative modalities, she underwent arthroscopic débridement and capsular release. This provided minimal symptomatic relief, and she was referred to our institution.

Our initial evaluation revealed active range of motion of 90° of total forward elevation (compared with 180° for the unaffected shoulder), 40° of external rotation with the arm in a neutral position (90° for the unaffected shoulder), and internal rotation to L5 (T5 for the unaffected shoulder). Marked crepitus was noted throughout the patient's range of motion. Radiographs of the right shoulder revealed narrowing of the glenohumeral joint space and osteophyte formation along the inferior aspect of the surgical neck of the humerus (Figure 2).

She underwent repeat right shoulder arthroscopy to evaluate the status of the glenohumeral cartilage. The shoulder capsule was markedly attenuated anteriorly, and significant cartilage loss was noted on both the glenoid and humeral head (Figure 3). An open revision capsular release was then performed, followed by glenoid microfracture and resurfacing using small intestine submucosa (SIS, Depuy, Warsaw, IN). Initially, her condition improved, with pain relief and increased range of motion.

At 4 months postoperatively, however, she was involved in a high-energy motor vehicle collision. This accident was followed by a return of right shoulder pain and progressive loss of motion. A magnetic resonance image suggested progressive degenerative changes in the glenohumeral joint. Continued physical therapy failed to alleviate her symptoms. Because of the patient's young age, high functional demands, and desire to avoid total shoulder arthroplasty, the glenoid resurfacing was revised by using a



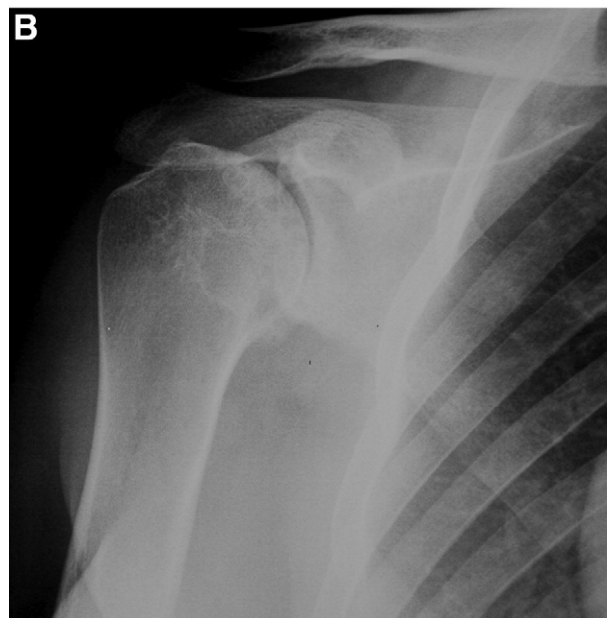
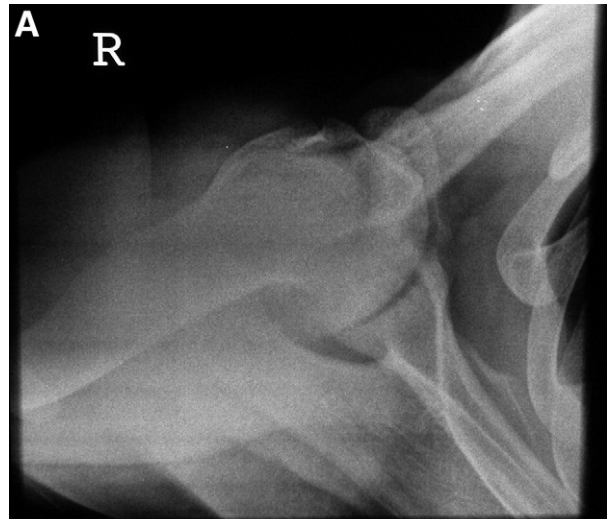
**Figure 1** Arthroscopic view of normal-appearing cartilage on both glenoid and humeral surfaces at the time of thermal capsulorrhaphy. The tip of a radiofrequency energy probe is observed centrally.

meniscal allograft, and the proximal humerus was reconstructed by using a side-matched and size-matched fresh-frozen humeral osteoarticular allograft.

The glenohumeral joint was approached through the previous deltopectoral interval. The previously placed SIS patch appeared to have integrated onto the surface of the glenoid. This layer was left undisturbed and was covered using a size-matched lateral meniscal allograft. Preparation of the meniscal allograft was accomplished by detaching it from its bony insertions and suturing the anterior and posterior horns together with two 2-0 nonabsorbable sutures, creating a concave, ovoid structure (Figure 4). Fixation of the meniscal allograft was achieved by using bioabsorbable suture anchors placed at 45° increments around the circumference of the glenoid edge.

Proximal humerus reconstruction was accomplished by using a side-matched and size-matched fresh-frozen humeral head osteoarticular allograft. The graft was shaped in the form of a mushroom, and a matching socket was created in the proximal humerus to accept the stem. The allograft was shaped by first making a cut 1 cm distal to the anatomic neck of the allograft humerus, followed by positioning a Cloward drill with a 15-mm diameter centrally and perpendicular to the plane of the cut. It was then drilled to a depth of 1 cm. With the Cloward drill left in place, an oscillating saw was used to cut around the circumference of the drill, thereby excising a ring of allograft bone. The drill was then removed, creating the stalk of the mushroom graft (Figure 5).

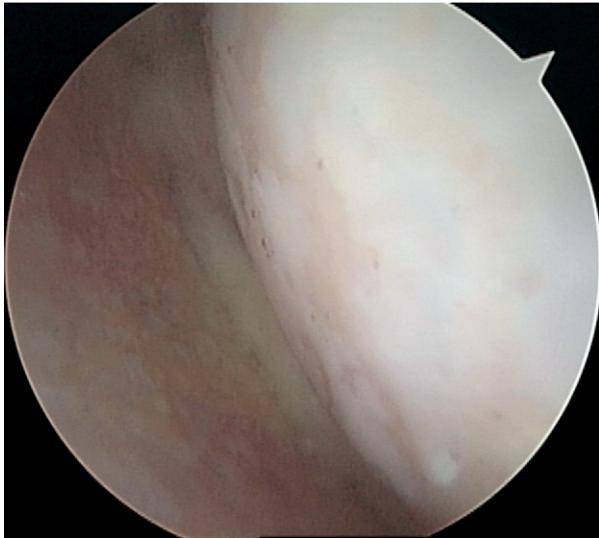
The recipient site in the proximal humerus was prepared by positioning a 2-mm guidewire centrally and perpendicular to the plane of the native humeral cut and using a cannulated cylindrical reamer matching the inner diameter of the Cloward drill to ream a socket 1 cm in depth. The central peg of the graft was impacted into the recipient site, and fixation to the proximal humerus was achieved with the use of 4 countersunk, variable-pitch compression screws (Accutrak, Acumed, Hillsboro, OR) inserted retrograde from the lateral aspect of the proximal humerus into the graft.



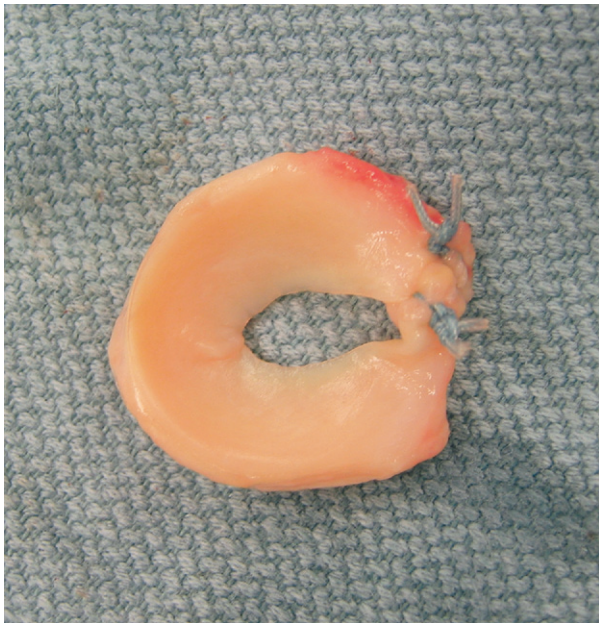**Figure 2 A**, An axillary lateral radiograph of the right shoulder 2 years after thermal capsulorrhaphy demonstrates loss of glenohumeral joint space and cyst formation on both the glenoid and humeral side of the joint. **B**, An anteroposterior view of the right shoulder 2 years after thermal capsulorrhaphy demonstrates osteophyte formation along the surgical neck of the proximal humerus.

For the first 6 postoperative weeks, the patient was permitted passive and active-assisted range of motion only, limited to 90° of forward flexion, 40° of external rotation without abduction, and 75° of abduction without rotation. No active internal rotation or extension beyond neutral was permitted until week 7. At postoperative week 12 and beyond, she was permitted active range of motion, as tolerated, with low-intensity strengthening exercises in all planes.

At the 6-month follow-up, she had no pain and had 120° of active forward elevation, 45° of active external rotation,

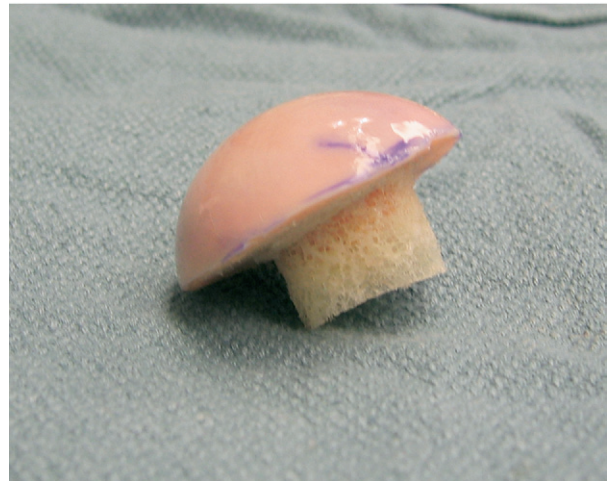

**Figure 3** An arthroscopic view 2 years after thermal capsulorrhaphy shows bipolar chondrolysis of the glenohumeral joint.



**Figure 4** Prepared lateral meniscal allograft.

and active internal rotation to T12. At the 12-month follow-up, her visual analog pain score had decreased from 4 to 0, her rating using the Simple Shoulder Test had improved from 1 to 8, her assessment using the American Shoulder and Elbow Surgeons patient self-evaluation scale had improved from 50 to 83, her Mental Component Score of the SF-12 had remained constant at 59, and her Physical Component Score had increased from 29 to 46.<sup>12,15</sup> At the 2-year follow-up, she still had no pain and had 160° of active forward elevation, 50° of active external rotation, and active internal rotation to T12. Radiographs showed



**Figure 5** Prepared mushroom osteoarticular humeral head allograft.

preservation of joint space and no evidence of allograft collapse or hardware migration (Figure 6).

## DISCUSSION

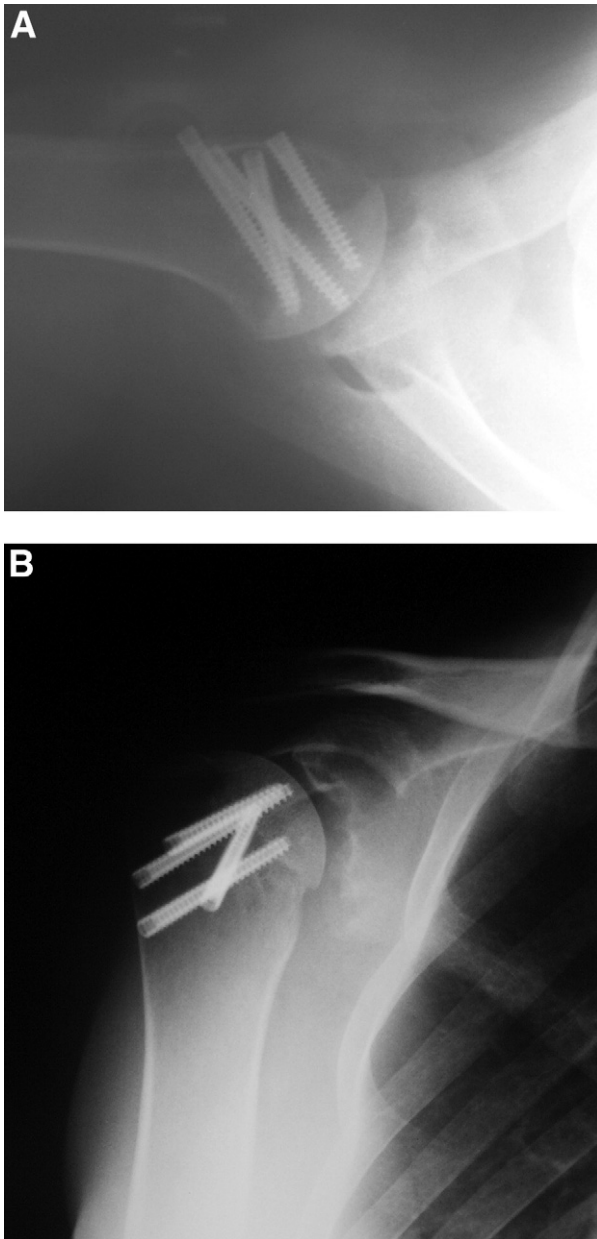
The presented case was one of bipolar glenohumeral chondrolysis after use of a RFE device for arthroscopic treatment of anterior glenohumeral instability. Petty et al<sup>18</sup> reported 2 similar cases of glenohumeral chondrolysis after the arthroscopic use of thermal energy and a third after an arthroscopic procedure during which no thermal energy was used. Levine et al<sup>14</sup> recently presented 2 additional cases of young athletes who developed chondrolysis of the glenohumeral joint after thermal treatment for instability. They sustained extensive, bipolar cartilage loss and were treated in a fashion similar to our patient, although allograft-prosthetic composites were selected for reconstruction in their 2 patients.

The incidence of glenohumeral chondrolysis after thermal capsulorrhaphy is difficult to ascertain. Wong et al<sup>23</sup> surveyed members of the American Shoulder and Elbow Surgeons, the Arthroscopy Association of North American, and the American Orthopaedic Society for Sports Medicine about complications from the use of thermal capsulorrhaphy to treat shoulder instability. They reported no cases of chondrolysis, but their survey focused on rate of recurrence, number of axillary nerve injuries, and prevalence of capsular insufficiency. Whether the survey addressed chondrolysis was not stated in their review.

With respect to thermal energy, almost all commercial devices offered for arthroscopy use RFE rather than electrocautery or laser. Electrocautery uses electrical current to heat an integrated heating element, which is then applied to the tissue being treated. No electrical current is transferred into the target tissue. RFE, conversely, transfers an alternating electrical current directly into the target tissue, resulting in ohmic heating of fluid within the target tissue as tissue ions attempt to follow the direction of the applied current.<sup>6</sup>

Edwards et al<sup>6</sup> have demonstrated in ex vivo testing that monopolar RFE devices (mRFE), which rely on passage of the current from the tip of the electrode to a dispersing





**Figure 6 A,** An axillary lateral radiograph 2 years after lateral meniscal allograft reconstruction shows fixation of the osteoarticular allograft using multiple variable pitch compression screws. **B,** An anteroposterior radiograph 2 years after lateral meniscal allograft reconstruction demonstrates radiographic evidence that the glenohumeral joint space has been maintained by meniscal allograft interposition.

electrode located somewhere on the patient's body, easily generate cartilage surface temperatures of 61°C to 68°C after 20 seconds of continuous use. Furthermore, bipolar RFE devices, where current flows between active and dispersive electrodes located at the tip of the instrument, generated cartilage surface temperatures of 95°C to 100°C after 20 seconds of use, regardless of fluid flow through the

joint.<sup>6</sup> More important, the same study found bipolar RFE produced temperatures greater than 70°C at a depth of 2000  $\mu$ m from the cartilage surface.<sup>6</sup> Temperatures of about 55°C are thought to result in chondrocyte death.<sup>5</sup> The data in the Edwards et al study concern the direct use RFE on cartilage, an application that is seldom needed within the glenohumeral joint. Less is known about the effect of indirect use of RFE on cartilage.

Although no use of an intraarticular pain catheter was recorded in this particular patient, postoperative infusion of bupivacaine has been correlated with chondrocyte toxicity and clinical chondrolysis.<sup>3,10,11</sup>

Biologic resurfacing of the glenoid has been described by multiple authors.<sup>1,4,13,24</sup> In our opinion, biologic resurfacing of the glenoid should be viewed as a soft tissue procedure intended to provide a durable solution for reduction glenohumeral contact forces. Burkhead et al<sup>4</sup> published a group of 14 young, high-demand patients with end-stage osteoarthritis of the glenohumeral joint. Anterior capsule or fascia lata autograft was used to cover the glenoid in this series in conjunction with traditional hemiarthroplasty. With minimum 2-year follow-up, the authors reported impressive pain relief and increased range of motion in all patients.

Krishnan et al<sup>13</sup> have reported excellent results after combined biologic resurfacing of the glenoid and acromion by using an Achilles tendon allograft performed along with humeral hemiarthroplasty in the context of rotator cuff tear arthropathy. Yamaguchi et al<sup>24</sup> presented a composite technique of biologic glenoid resurfacing by using lateral meniscal allograft combined with prosthetic humeral resurfacing, and Argo et al<sup>1</sup> recently presented a novel arthroscopic technique for isolated biologic glenoid resurfacing by using a porcine xenograft (Restore Orthobiologic Implant, Depuy Orthopaedics, Warsaw, IN), but published results for these techniques are lacking at this time.

On the humeral side, successful treatment with osteoarticular allografts has been reported for osteochondral defects of the humeral head. Gerber<sup>8</sup> described the use of a femoral head osteoarticular allograft to treat reverse Hill-Sachs lesions of the humeral head. Miniaci et al<sup>16</sup> described the use of fresh frozen side-matched and size-matched osteoarticular humeral head allografts to reconstruct large Hill-Sachs lesions in a series of 18 patients who had failed previous instability repairs.

Given this patient's young age, high functional demands, and devastating scope of cartilage loss, we elected to combine biologic resurfacing of the glenoid by using a lateral meniscal allograft with osteoarticular allograft replacement of the humeral head rather than use a prosthetic component. The failure of the initial glenoid resurfacing procedure may have been traumatic in nature, but it is also likely that a unilateral resurfacing represents an inadequate reconstructive procedure in the setting of bipolar chondrolysis. Although this represents but a single case report with short-term follow-up, we did observe marked improvement in several validated functional outcomes instruments as well as radiographic stability of the construct. The long-term fate of this procedure, however, remains to be seen. Nevertheless, for young, high-demand patients with bipolar chondrolysis who have failed alternative nonoperative and operative treatment modalities, allograft reconstruction is a

potential addition to the armamentarium of salvage treatment options.<sup>17, 20</sup>

## REFERENCES

- Argo D, Savoie F, Field L. Arthroscopic treatment of glenohumeral arthritis with interpositional grafting. Presented at: Arthroscopy Association of North America Annual Meeting. Vancouver, British Columbia, Canada, 2005.
- Athwal GS, Shridharani SM, O'Driscoll SW. Osteolysis and arthropathy of the shoulder after use of bioabsorbable knotless suture anchors. A report of four cases. *J Bone Joint Surg Am* 2006;88:1840-5.
- Bojescul JA, Wilson G, Taylor DC. Idiopathic chondrolysis of the ankle. *Arthroscopy* 2005;21:224-7.
- Burkhead WZ Jr, Hutton KS. Biologic resurfacing of the glenoid with hemiarthroplasty of the shoulder. *J Shoulder Elbow Surg* 1995;4:263-70.
- Edwards RB, 3rd Lu Y, Markel MD. The basic science of thermally assisted chondroplasty. *Clin Sports Med* 2002;21:619-47, viii.
- Edwards RB, 3rd, Lu Y, Rodriguez E, Markel MD. Thermometric determination of cartilage matrix temperatures during thermal chondroplasty: comparison of bipolar and monopolar radiofrequency devices. *Arthroscopy* 2002;18:339-46.
- Freehill MQ, Harms DJ, Huber SM, Atlihan D, Buss DD. Poly-L-lactic acid tack synovitis after arthroscopic stabilization of the shoulder. *Am J Sports Med* 2003;31:643-7.
- Gerber C, Lambert SM. Allograft reconstruction of segmental defects of the humeral head for the treatment of chronic locked posterior dislocation of the shoulder. *J Bone Joint Surg Am* 1996;78:376-82.
- Gill TJ, McCulloch PC, Glasson SS, Blanchet T, Morris EA. Chondral defect repair after the microfracture procedure: a non-human primate model. *Am J Sports Med* 2005;33:680-5.
- Gomoll AH, Kang RW, Williams JM, Bach BR, Cole BJ. Chondrolysis after continuous intra-articular bupivacaine infusion: an experimental model investigating chondrotoxicity in the rabbit shoulder. *Arthroscopy* 2006;22:813-9.
- Hansen B, Beck C, Townsley R. Post-arthroscopic shoulder chondrolysis with associated intraarticular pain pump catheter use. Presented at: Annual Meeting of the American Academy of Orthopaedic Surgeons. Chicago, IL, 2006.
- King GJ, Richards RR, Zuckerman JD, et al. A standardized method for assessment of elbow function. Research Committee, American Shoulder and Elbow Surgeons. *J Shoulder Elbow Surg* 1999;8:351-4.
- Krishnan SG, Burkhead WZ Jr, Nowinski RJ. Humeral hemiarthroplasty with biologic resurfacing of the glenoid and acromion for rotator cuff tear arthropathy. *Tech Shoulder Elbow Surg* 2004;5:51-9.
- Levine WN, Clark AM Jr, D'Alessandro DF, Yamaguchi K. Chondrolysis following arthroscopic thermal capsulorrhaphy to treat shoulder instability. A report of two cases. *J Bone Joint Surg Am* 2005;87:616-21.
- Lippitt S, Harryman DJ, Matsen FI. A practical tool for evaluation function: The simple shoulder test. In: Matsen FI, Fu F, Hawkins R, editors. *The shoulder: a balance of mobility and stability*. Rosemont, IL: American Academy of Orthopaedic Surgeons; 1993. p. 501-18.
- Miniaci A, Gish MW. Management of anterior glenohumeral instability associated with large Hill-Sachs defects. *Tech Shoulder Elbow Surg* 2004;5:170-5.
- Nakagawa Y, Ueo T, Miki T, Kotani H, Onishi E, Nakamura T. Glenohumeral osteoarthritis following a "color test" during rotator cuff repair. A case report and a review of the literature. *Bull Hosp Jt Dis* 1998;57:216-8.
- Petty DH, Jazrawi LM, Estrada LS, Andrews JR. Glenohumeral chondrolysis after shoulder arthroscopy: case reports and review of the literature. *Am J Sports Med* 2004;32:509-15.
- Romeo AA, Cole BJ, Mazzocca AD, Fox JA, Freeman KB, Joy E. Autologous chondrocyte repair of an articular defect in the humeral head. *Arthroscopy* 2002;18:925-9.
- Shibata Y, Midorikawa K, Koga T, Honjo N, Naito M. Chondrolysis of the glenohumeral joint following a color test using gentian violet. *Int Orthop* 2001;25:401-3.
- Steadman JR, Rodkey WG, Rodrigo JJ. Microfracture: surgical technique and rehabilitation to treat chondral defects. *Clin Orthop* 2001;391(suppl):S362-9.
- Tamai K, Higashi A, Cho S, Yamaguchi T. Chondrolysis of the shoulder following a "color test"-assisted rotator cuff repair—a report of 2 cases. *Acta Orthop Scand* 1997;68:401-2.
- Wong KL, Williams GR. Complications of thermal capsulorrhaphy of the shoulder. *J Bone Joint Surg Am* 2001;83(suppl 2 Pt 2):151-5.
- Yamaguchi K, Ball C, Galatz L. Meniscal allograft interposition arthroplasty of the arthritic shoulder: early results and a review of the technique. Presented at: 18th Open Meeting American Shoulder and Elbow Surgeons, Dallas, TX, 2002.