

# Effect of Highly Purified Capsaicin on Articular Cartilage and Rotator Cuff Tendon Healing: An In Vivo Rabbit Study

Nicole A. Friel,<sup>1</sup> Allison G. McNickle,<sup>2</sup> Michael J. DeFranco,<sup>3</sup> FanChia Wang,<sup>4</sup> Elizabeth F. Shewman,<sup>5</sup> Nikhil N. Verma,<sup>5</sup> Brian J. Cole,<sup>5</sup> Bernard R. Bach Jr.,<sup>5</sup> Susan Chubinskaya,<sup>5,6</sup> Susan M. Kramer,<sup>7</sup> Vincent M. Wang<sup>5</sup>

<sup>1</sup>Department of Orthopedic Surgery, University of Pittsburgh, Pittsburgh, Pennsylvania, <sup>2</sup>Department of Surgery, Mount Sinai Hospital Medical Center, Chicago, Illinois, <sup>3</sup>CGH Medical Center, Sterling, Illinois, <sup>4</sup>BioCare Corporation, Lujhu Township, Taiwan, <sup>5</sup>Department of Orthopedic Surgery, Rush University Medical Center, Chicago, Illinois, <sup>6</sup>Department of Biochemistry, Rush University Medical Center, Chicago, Illinois, <sup>7</sup>Annexon Bioscience, South San Francisco, California

Received 6 January 2015; accepted 16 June 2015

Published online 7 July 2015 in Wiley Online Library (wileyonlinelibrary.com). DOI 10.1002/jor.22971

**ABSTRACT:** Highly purified capsaicin has emerged as a promising injectable compound capable of providing sustained pain relief following a single localized treatment during orthopedic surgical procedures. To further assess its reliability for clinical use, the potential effect of highly purified capsaicin on articular cartilage metabolism as well as tendon structure and function warrants clarification. In the current study, rabbits received unilateral supraspinatus transection and repair with a single 1 ml injection of capsaicin (R+C), PEG-only placebo (R+P), or saline (R+S) into the glenohumeral joint (GHJ). An additional group received 1 ml capsaicin onto an intact rotator cuff (I+C). At 18 weeks post-op, cartilage proteoglycan (PG) synthesis and content as well as cell viability were similar ( $p > 0.05$ ) across treatment groups. Biomechanical testing revealed no differences ( $p > 0.05$ ) among tendon repair treatment groups. Similarly, histologic features of both cartilage and repaired tendons showed minimal differences across groups. Hence, in this rabbit model, a single injection of highly purified capsaicin into the GHJ does not induce a deleterious response with regard to cartilage matrix metabolism and cell viability, or rotator cuff healing. These data provide further evidence supporting the use of injectable, highly purified capsaicin as a safe alternative for management of postoperative pain following GHJ surgery. © 2015 Orthopaedic Research Society. Published by Wiley Periodicals, Inc. *J Orthop Res* 33:1854–1860, 2015.

**Keywords:** capsaicin; anesthetic; cartilage; rotator cuff; tendon

As effective pain relief is a paramount post-surgical concern, alternative types and classes of compounds are being investigated for orthopedic surgical procedures performed on major joints such as the shoulder and knee. Pain management strategies have evolved to include longer-acting regional blocks and direct intra-articular administration of analgesics, which both have proven to be effective.<sup>1,2</sup> Unfortunately, when delivered intra-articularly, bupivacaine and other amino amides negatively affect articular cartilage as documented in clinical case series,<sup>3,4</sup> animal models,<sup>5–7</sup> and in vitro studies.<sup>8–10</sup> Furthermore, the use of pain pumps in shoulder surgery have given rise to concerns of chondrolysis and potential toxicity to the peri-articular soft tissues.<sup>11</sup>

Capsaicin, a natural product of capsicum peppers, acts by binding to the Vanilloid Receptor-1 (VR-1) on unmyelinated nociceptive C-fibers and thin A-myelinated fibers. Binding depletes the nerve endings of neurotransmitters (e.g., substance P, calcitonin gene related peptide [CGRP]), and in high doses, it significantly reduces the number of nerve endings via excitotoxicity.<sup>12</sup> Topical (i.e., patch or cream) application of capsaicin has shown moderate efficacy in treating chronic musculoskeletal pain and arthritis<sup>13</sup> or neuropathic pain associated with post-herpetic neuralgia (Qutenza<sup>®</sup>)<sup>14</sup> but has been impacted by the pain response associated with the drug application, limiting the dose level and area of applica-

tion. Purified capsaicin, when injected into the joint space of patients under anesthesia, has emerged as a promising, non-opioid candidate for achieving long-acting, site specific relief of acute pain following orthopedic surgery or osteoarthritic pain<sup>15–17</sup> as well as in non-orthopedic procedures such as hernia repair.<sup>18</sup>

In order to more rigorously evaluate capsaicin as a safe (i.e., non-deleterious to soft tissue integrity) analgesic agent for use in orthopedic surgery, an improved understanding of effects of capsaicin treatment on tendon and cartilage are needed. Therefore, the purpose of the present study was to evaluate the effect of highly purified capsaicin on articular cartilage as well as tendon healing. We hypothesized that, in an in vivo rabbit model, a single intra-operative, intra-articular administration of highly purified capsaicin would not impair supraspinatus tendon healing nor induce histopathological changes in glenohumeral joint articular cartilage.

## METHODS

### Experimental Design

All protocols and procedures were approved by the authors' Institutional Animal Care and Use Committee. Forty-four skeletally mature, male New Zealand White rabbits approximately 4 months old with a mean body mass of  $4.1 \pm 0.1$  kg (range, 3.6–4.4 kg) at the time of surgery were randomly assigned to one of four treatment groups (11 animals/group): intact tendon (exposure of the supraspinatus tendon) with application of highly purified capsaicin (250  $\mu$ g of Capsaicin 4975 in 1 ml 25% PEG 300 solution, Anesiva, Inc., South San Francisco, CA) (I+C), or unilateral rotator cuff repair with instillation of saline (R+S), placebo (25% PEG) (R+P), or Capsaicin 4975 (R+C). All injections of the drug or control solutions into the GHJ followed creation of a rotator cuff

Grant sponsor: Anesiva, Inc. (South San Francisco, CA).

Correspondence to: Vincent M. Wang (T: +312-563-3859; F: 312-942-4491; E-mail: vmwang@vt.edu)

© 2015 Orthopaedic Research Society. Published by Wiley Periodicals, Inc.

defect, which was repaired following the injection (see below). Incising the supraspinatus tendon vented the superior joint capsule, facilitating delivery of the aqueous solution both into the joint and to the opposing edges of the transected tendon. Furthermore, this study design enabled investigation of the effect of capsaicin on both uninjured and healing tendons. A placebo group was included for consistency with the design of clinical trials. The capsaicin dosage was based on effective doses reported in clinical trials.<sup>16,19</sup> Each rabbit received a contralateral shoulder sham procedure. Rabbits were euthanized 18 weeks after surgery, weighed, and relevant tissues harvested for analysis.

### **Surgical Procedure**

Using a methodology recently developed by our research group,<sup>20</sup> the left supraspinatus tendon was transected approximately 1 mm medial to its insertion and repaired through two transosseous tunnels within the lateral aspect of the proximal humerus. In accordance with the specific treatment group, using a syringe, 1 ml of aqueous solution was instilled into the joint, and the rotator cuff was subjected to gentle passive motion to facilitate distribution of the aqueous solution into both the rotator cuff tendon–bone insertion site, transosseous tunnels, as well as into the joint space. A standard bathing period of 5 min for all treatment groups was followed before supraspinatus tendon was repaired. In the right (sham treated) shoulder, the surgical approach to the rotator cuff was identical to that of the left shoulder, and the intact supraspinatus tendon was exposed for a duration equivalent to that of the left shoulder's surgical procedure prior to skin closure. For analgesia post-operatively, rabbits received subcutaneous administration of buprenorphine for 3 days and were housed in individual cages with no limitations on their motion.

### **Cartilage Analyses**

Humeral head cartilage was analyzed using methods previously described by our research group.<sup>5,6</sup> Biochemical and cell viability data were available for six of the seven rabbits allocated for these assays within each treatment group. Data from one animal was not available due to technical errors in sample harvesting and preparation. Four full-thickness cartilage cores (4 mm diameter each) were removed from each humeral head for proteoglycan (PG) assessment. Sulfate incorporation (10  $\mu$ Ci/ml), an index of PG synthesis, was measured using the alcian blue precipitation method<sup>21</sup> and normalized by DNA content using Hoechst dye.<sup>22</sup> For the same samples used to determine PG synthesis, the dimethyl-methylene blue (DMMB) assay<sup>23</sup> was then utilized to quantify PG content in the matrix and media, expressed for each sample as normalized to its wet weight. From the remaining (intact) central strip of humeral head cartilage, 2 mm portions were removed and incubated in sterile PBS with 4- $\mu$ mol/L calcein AM and 8- $\mu$ mol/L ethidium homodimer (Molecular Probes, Invitrogen, Carlsbad, CA) for 1 h to label live and dead cells, respectively.<sup>24</sup> Images were captured on a FluoView confocal microscope (Olympus America, Inc.), and viability measurements were reported as the average value determined from three independent, blinded observers.

For four rabbits per group, the entire humeral head was processed for histologic characterization. H&E and Safranin-O stained paraffin sections were graded using a modified Mankin scale<sup>25</sup> by three independent, blinded observers experienced in cartilage histopathologic assessment. Sub-scores were summed for a total histologic grade for each

specimen, and the averaged scores across observers were compared. Slides for TUNEL staining were prepared<sup>26</sup> using an ApopTag™ Plus peroxidase detection kit (Chemicon International, Temecula, CA). For each sample, TUNEL positive cells were manually counted from at least two histologic slides within each cartilaginous zone: superficial, middle, and deep as well as the zone of calcification.

### **Rotator Cuff Analyses**

Eight rabbits per group were allocated for biomechanical analysis while the remaining three were designated for histologic study. Tensile testing of rotator cuff–bone complexes were performed as described by Friel et al.<sup>20</sup> Cross-sectional area was determined from precision caliper and laser displacement sensor measurements of tissue width and thickness, respectively. Following a 5 N preload for 1 min, specimens were loaded to failure at 0.1 mm/s.

For histology, rotator cuff tendon–bone complexes were paraffin embedded, sectioned longitudinally, and stained with H&E or Safranin-O/Fast Green. A custom scoring system<sup>20</sup> was used to evaluate the tendon with respect to (i) cellularity, (ii) collagen fiber orientation, (iii) transition zone architecture, and (iv) proteoglycan staining. Scores were assigned as 0 for normal appearance, 1 for mild change, 2 for moderate change, and 3 for severe change. Scores from the four aforementioned features were averaged to give a single histologic grade per specimen. The overall histologic grade per treatment was then determined as the averaged scores from two independent, blinded observers experienced in tendon histopathologic assessment.

### **Statistical Analyses**

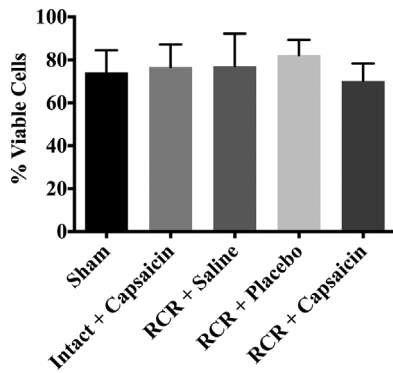
For each biochemical and biomechanical parameter, no significant differences ( $p > 0.2$ ) were observed among sham treated (i.e., right) shoulders across groups, and therefore, results were pooled into a single sham group for comparison to the remaining four groups. In order to test our study hypothesis, all non-histologic outcomes were analyzed using a one-way ANOVA followed by a Holm–Sidak multiple comparison post-hoc test to determine pairwise differences among groups. Cartilage and tendon histologic scores were compared using a Kruskal–Wallis test. All analyses were performed with a significance level set at  $p < 0.05$  using GraphPad Prism 6 software (La Jolla, CA).

## **RESULTS**

Weight gain during the 18-week post-operative period was similar among treatment groups ( $p = 0.56$ , mean across groups: 16.4% of weight on day of surgery). Qualitatively, there were no obvious differences in the overall post-operative health status (including the mobility of left forelimbs or observed joint pain) of rabbits across the groups.

### **Cartilage Analyses**

No differences were observed between groups with respect to cartilage wet weight ( $p = 0.31$ , pooled mean across groups: 66.6  $\pm$  5.9 mg), cell viability ( $p = 0.38$ , Fig. 1), matrix PG content ( $p = 0.63$ ), media PG content ( $p = 0.28$ ), and total PG content ( $p = 0.64$ , Table 1). PG synthesis was significantly lower for the I+C group relative to R+S ( $p = 0.047$ ) and R+P ( $p = 0.015$ ); however, mean synthesis for the I+C group was



**Figure 1.** Cell viability results (mean and standard deviation). No significant differences were detected across treatment groups ( $p = 0.38$ ). RCR, rotator cuff repair.

similar to that of the sham ( $p = 0.59$ ) and R + C ( $p = 0.10$ ) groups, and no differences were detected among the three tendon repair groups (Table 1). Humeral head histologic grades showed minimal differences among groups ( $p = 0.78$ , Fig. 2). TUNEL staining revealed four apoptotic cells in the cartilage layer of only one sample (R + S group). Apoptotic cells in the zone of calcification were  $4.0 \pm 3.3$  for I + C,  $2.8 \pm 3.1$  for R + S,  $0.8 \pm 1.5$  for R + P,  $4.0 \pm 5.2$  for R + C, and  $3.9 \pm 3.5$  for the pooled shams. The number of apoptotic cells was not statistically different ( $p = 0.42$ ) between treatment groups.

#### Tendon Analyses

Maximum load, displacement at maximum load, and maximum stress results from specimens which failed at the cryogrip or via bone fracture were excluded from the analysis, as they do not accurately represent tendon or insertion site properties. Among the three tendon repair groups, no significant differences were noted for cross-sectional area or any of the biomechanical parameters (Table 2). Stiffness was significantly higher ( $p < 0.001$ ), while cross-sectional area was lower ( $p < 0.001$ ) for both I + C and sham groups, compared to each of the tendon repair groups (Table 2). In both sham and I + C groups, all tendons failed at the base of the cryogrip. For the R + C group, seven specimens ruptured at the bone insertion while

one failed via bony avulsion. In the R + P group, three specimens each failed at the cryogrip and insertion site, and two ruptures occurred within the repair tissue region. Finally, for the R + S group, three specimens failed at the grip with the remaining five rupturing at the insertion site.

Total rotator cuff histologic scores showed no significant differences ( $p = 0.36$ ) across treatment groups (sham:  $0.3 \pm 0.2$ , I + C:  $0.3 \pm 0.3$ , R + S:  $0.6 \pm 0.2$ , R + P:  $0.4 \pm 0.3$ , R + C:  $0.4 \pm 0.4$ ). As the mean total histologic score was below 1.0 in each group, the healing supraspinatus enthesis showed relatively minor changes in structure, composition, and cellularity in comparison to both sham-operated tendons as well as intact tendons treated with capsaicin. In repaired rotator cuffs, the tendon matrix consisted of well-aligned collagen bundles and the normal four-zone direct insertion site was observed, with tendon gradually transitioning to bone via uncalcified and calcified fibrocartilage regions (Fig. 3). Analysis of histologic subscores revealed no significant differences among treatment groups with respect to PG staining ( $p = 0.65$ ) or cellularity ( $p = 0.9$ ). Collagen orientation ( $p = 0.10$ ) and transition architecture (0.07) subscores showed a trend toward statistical significance.

#### DISCUSSION

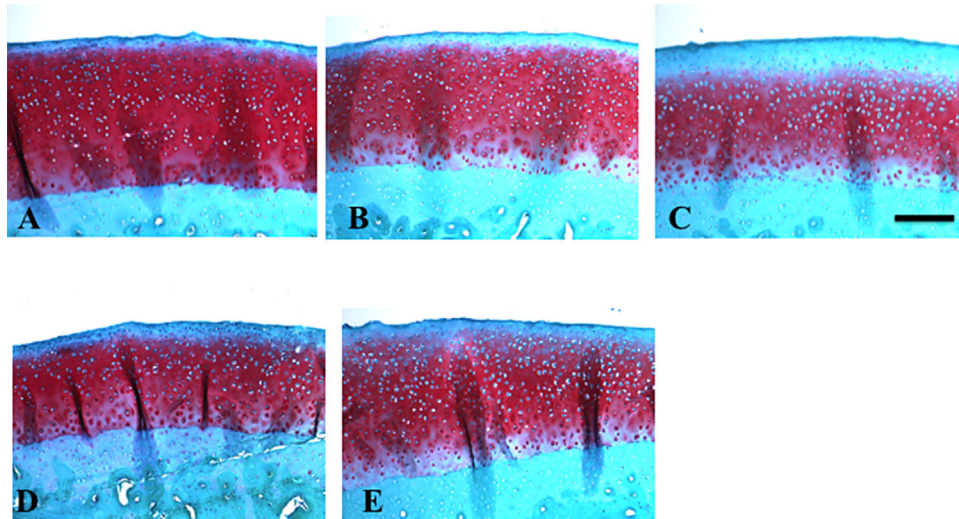
Proposed orthopedic clinical applications for capsaicin treatment include those that target a focus of chronic pain or inflammation, such as a degenerating joint, inflamed tendon, painful neuroma, as well as those in the setting of postoperative pain relief.<sup>16,19,27</sup> The excitotoxic effect of capsaicin manifests itself as desensitization to mechanical, chemical or thermal stimulation, and the scientific rationale for its clinical use is that the anesthetic effect of capsaicin can last until nerve fibers repopulate the treated region, which can take several weeks.<sup>28,29</sup> In clinical trials, a single injection of highly purified capsaicin has been shown to reduce pain for durations of weeks to months for site-specific, acute, and chronic musculoskeletal pain. Following unilateral total knee arthroplasty, patients receiving intraoperative, intra-articular capsaicin not only exhibited improved pain scores in comparison to those receiving placebo but also improvements in

**Table 1.** Cartilage Biochemical Results by Treatment Group (Mean and Standard Deviation)

Treatment Group	Sulfate Uptake (cpm/mg wet weight)	PG Content (media, $\mu\text{g}/\text{mg}$ wet wt)	PG Content (matrix, $\mu\text{g}/\text{mg}$ wet wt)	PG Content (total, $\mu\text{g}/\text{mg}$ wet wt)
Sham	$176 \pm 33$	$0.8 \pm 0.3$	$14.1 \pm 6.6$	$14.9 \pm 6.8$
Intact + Capsaicin	$146 \pm 10^a$	$0.7 \pm 0.3$	$10.8 \pm 4.5$	$11.5 \pm 4.8$
RCR + Saline	$210 \pm 36$	$1.0 \pm 0.3$	$11.1 \pm 3.1$	$12.1 \pm 3.3$
RCR + Placebo	$219 \pm 70$	$0.9 \pm 0.4$	$13.1 \pm 8.0$	$14.0 \pm 8.4$
RCR + Capsaicin	$204 \pm 26$	$1.2 \pm 0.5$	$14.7 \pm 4.1$	$15.9 \pm 4.5$
<i>p</i> -Value	0.005	0.28	0.63	0.63

PG, proteoglycan; cpm, counts per minute. *p*-value corresponds to one-way ANOVA comparison among the five groups.

<sup>a</sup>Significantly lower than RCR + Saline and RCR + Placebo groups.



**Figure 2.** Safranin-O stained glenoid cartilage sections demonstrated very similar histologic features among the experiments groups. (A) sham treatment, (B) intact tendon with capsaicin, (C) tendon repair with saline, (D) tendon repair with placebo, and (E) tendon repair with capsaicin. Scale bar = 200  $\mu$ m.

active range-of-motion at 14 days post-op, suggestive of longer-lasting pain relief.<sup>17</sup> Despite these encouraging clinical outcomes, when considering therapeutic alternatives for pain control, existing reports of the chondrotoxic properties of intra-articular analgesics such as bupivacaine<sup>3,5,7</sup> strongly suggest that attention to the integrity of articular cartilage and/or peri-articular tissues is warranted.

In vivo animal studies of capsaicin administration to diarthrodial joints have typically examined its effects on nociception and innervation of the joint synovial tissues.<sup>30–35</sup> Furthermore, in such studies, capsaicin administration often precedes a chemical induction of arthritis, thereby confounding the analysis of articular cartilage histopathology. The novelty of the present study lies in its examination of the isolated effect of intra-articular capsaicin on cartilage structure and metabolism as well as functional properties of both uninjured and healing tendon. The current investigation used the same formulation of a compound (Capsaicin 4975) which has been shown (upon a single intraoperative injection delivery, similar to the

current study) to provide long-lasting pain relief in both clinical<sup>16,19</sup> and pre-clinical studies.<sup>36,37</sup> Eighteen weeks post-operatively, cartilage proteoglycan content, histologic scores, and cell viability were found to be similar across all treatment groups (Figs. 1 and 2 and Table 1). Although there were no significant differences among the three RCR groups, administration of capsaicin to an intact supraspinatus tendon resulted in decreased cartilage PG synthesis relative to the repair with saline and repair with placebo groups. This may indicate that chondrocytes within shoulders that underwent surgery are in a higher metabolic state. Therefore, these results indicate that a single injection of highly purified capsaicin into the GHJ does not induce a deleterious response with regard to matrix metabolism and cell viability of glenohumeral cartilage at the time point studied.

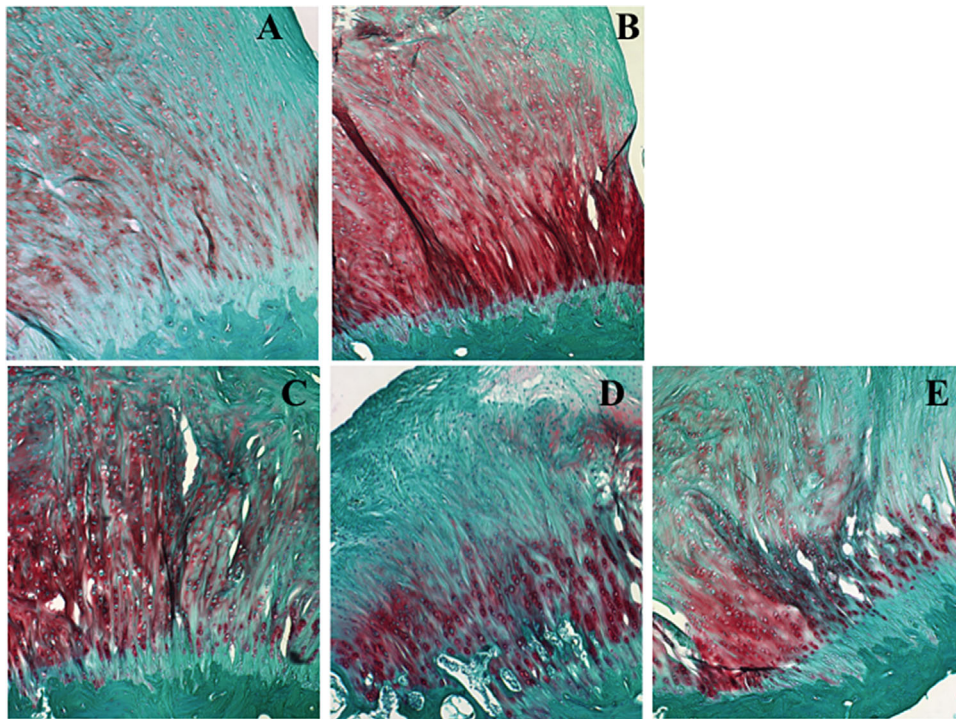
Of particular relevance to the present investigation, Kassis et al.<sup>36</sup> reported that, although intra-articular injection (200  $\mu$ g capsaicin in 1 ml diluent) of highly purified capsaicin significantly reduced synovial innervation 7 days following injection into rabbit knees,

**Table 2.** Summary of Tendon Geometric and Biomechanical Results (Mean and Standard Deviation)

Treatment Group	Area (mm <sup>2</sup> )	Stiffness (N/mm)	Maximum Load (N)	Displacement to Max Load (mm)	Maximum Stress (MPa)
Sham	11.4 $\pm$ 7.1	117.7 $\pm$ 37.1	n/a	n/a	n/a
Intact + Capsaicin	8.0 $\pm$ 4.6	117.4 $\pm$ 23.8	n/a	n/a	n/a
RCR + Saline	43.6 $\pm$ 13.2 <sup>a,b</sup>	68.8 $\pm$ 21.5 <sup>a,b</sup>	264.0 $\pm$ 40.9	8.11 $\pm$ 4.10	7.5 $\pm$ 2.5
RCR + Placebo	50.2 $\pm$ 15.0 <sup>a,b</sup>	74.8 $\pm$ 12.2 <sup>a,b</sup>	251.7 $\pm$ 42.9	5.72 $\pm$ 1.19	5.0 $\pm$ 0.8
RCR + Capsaicin	59.1 $\pm$ 30.1 <sup>a,b</sup>	65.2 $\pm$ 13.5 <sup>a,b</sup>	266.2 $\pm$ 66.8	6.52 $\pm$ 1.81	5.8 $\pm$ 2.9
<i>p</i> -Value	<0.0001	<0.0001	0.89	0.35	0.28

*p*-Value corresponds to one-way ANOVA comparison among treatment groups.

<sup>a</sup>Significantly different from intact. <sup>b</sup>Significantly different from sham. Maximum load, displacement to maximum load, and maximum stress data are not reported for the sham or intact + capsaicin groups as each of these specimens failed at the base of the cryogrip.



**Figure 3.** Safranin-O stained supraspinatus tendon sections demonstrated very similar histologic features (collagen fiber orientation, PG staining and insertion site organization) between sham (A) and intact tendons treated with capsaicin (B). Repaired tendons exhibited minimal differences among saline (C), placebo (D), and capsaicin (E) treatments. Tendons demonstrated a robust healing response, as evidenced by aligned collagen fibers and similar PG staining to that exhibited by the unoperated tendons (A and B). Original magnification  $\times 20$ .

administration of this compound neither induced an acute inflammatory response nor cartilage degradation at time intervals ranging from 3 days to 6 months. The current study expands upon the findings of Kassis et al. by analyzing cell viability and cartilage metabolism, neither of which were altered by capsaicin treatment. Additional studies have reported that highly purified capsaicin is non-detrimental when applied to nerve, muscle, and bone. Direct application of highly purified capsaicin to the sciatic nerve and surrounding muscle in rats showed no adverse effects on sensory-motor behavior when compared with vehicle-treated animals.<sup>37</sup> In the same study, rats received a femoral osteotomy injury, and no significant differences were noted with respect to bone area, mineral content, mineral density, or stiffness between the capsaicin and vehicle groups.

With respect to rotator cuff tendon properties, the only statistically significant differences observed regarded the maximum load, maximum stress, and stiffness of the sham and intact (with drug) groups in comparison to the surgical repair groups (Table 2). Histologic analysis revealed minimal differences by group with respect to either the tendon proper or insertion site morphology (Fig. 3). Consistent with the findings of Nho et al.,<sup>38</sup> the morphology of the healing supraspinatus tendon in each of the repair groups closely resembled that of the native tendon at 18 weeks post-surgery. The finding that no differences in mechanical

properties were evident among the three tendon repair groups implies that a single injection of highly purified capsaicin does not impede the functional quality of tendon healing following acute injury. To our knowledge, there have been no reports on the effect of direct capsaicin application to normal or healing tendon. Bring et al.<sup>39</sup> developed a rat Achilles tendon healing model in which capsaicin was injected subcutaneously for four consecutive days to induce sensory denervation. Interestingly, although capsaicin was not utilized as a therapeutic agent in this model, capsaicin-injected rats exhibited a higher load to failure in comparison to an untreated control group of tendons at the 8-week healing time point, while no differences were noted at 1 or 4 weeks post-op. Furthermore, a correlation was reported between residual substance P levels in the dorsal root ganglia and tendon tensile properties. While numerous reports suggest an important role for nociception in both the pathogenesis of symptomatic pain in tendon disease as well as in the repair process,<sup>40–42</sup> characterization of neuropeptides such as substance P and CGRP were beyond the scope of the current investigation.

In summary, the current results indicate that a single injection of highly purified capsaicin into the GHJ neither induces a deleterious response with regard to cartilage matrix metabolism and cell viability, or rotator cuff healing. Limitations of the present study include the potential specificity of its results to the shoulder (glenohumeral joint and rotator cuff); it is

unclear whether similar outcomes would be achieved for the intra-articular environment of the knee. Furthermore, rotator cuff healing and cartilage analyses were conducted at a single post-operative time point of 18 weeks, at which time the rabbit supraspinatus tendon achieves restoration of its insertion site following acute injury and repair.<sup>38</sup> Tissue responses to capsaicin may be sensitive to the local biologic and neuronal environment (e.g., inflammatory phase of tendon healing). Nonetheless, these findings appear to be very favorable with respect to the safety profile (i.e., tissue metabolism and function) of purified capsaicin as a candidate therapeutic pain treatment during orthopedic surgical procedures as well as for the treatment of osteoarthritis and epicondylitis, each of which has been the focus of clinical trials using this compound.<sup>16,19</sup> When viewed collectively with the encouraging results from prior human and animal studies, purified capsaicin appears to provide a safe alternative to manage postoperative pain.

#### AUTHORS' CONTRIBUTIONS

Research design, or the acquisition, analysis or interpretation of data: NAF, AGM, MJD, FW, EFS, NNV, SC, SMK, VMW; manuscript writing: NAF, AGM, EFS, NNV, BJC, BRB, SC, SMK, VMW. All authors have read and approved the final submitted manuscript.

#### ACKNOWLEDGEMENTS

This study was partially supported by Anesiva, Inc. (South San Francisco, CA), which also supplied the capsaicin for this investigation, and by funds from the Rush Orthopedic Surgery Section of Sports Medicine. The technical assistance of Arnavaz Hakimiyani and Lev Rappoport is gratefully acknowledged. Funding from Anesiva, but none of the authors' other professional and financial affiliations, may be perceived to have biased this presentation.

#### REFERENCES

1. Park JY, Lee GW, Kim Y, et al. 2002. The efficacy of continuous intrabursal infusion with morphine and bupivacaine for postoperative analgesia after subacromial arthroscopy. *Reg Anesth Pain Med* 27:145–149.
2. Ullah H, Samad K, Khan FA. 2014. Continuous interscalene brachial plexus block versus parenteral analgesia for postoperative pain relief after major shoulder surgery. *Cochrane Database Syst Rev* 2:CD007080.
3. Bailie DS, Ellenbecker TS. 2009. Severe chondrolysis after shoulder arthroscopy: a case series. *J Shoulder Elbow Surg* 18:742–747.
4. Hasan SS, Fleckenstein CM. 2013. Glenohumeral chondrolysis: part I-clinical presentation and predictors of disease progression. *Arthroscopy* 29:1135–1141.
5. Gomoll AH, Kang RW, Williams JM, et al. 2006. Chondrolysis after continuous intra-articular bupivacaine infusion: an experimental model investigating chondrotoxicity in the rabbit shoulder. *Arthroscopy* 22:813–819.
6. Gomoll AH, Yanke AB, Kang RW, et al. 2009. Long-term effects of bupivacaine on cartilage in a rabbit shoulder model. *Am J Sports Med* 37:72–77.
7. Chu CR, Coyle CH, Chu CT, et al. 2010. In vivo effects of single intra-articular injection of 0.5% bupivacaine on articular cartilage. *J Bone Joint Surg Am* 92:599–608.
8. Chu CR, Izzo NJ, Coyle CH, et al. 2008. The in vitro effects of bupivacaine on articular chondrocytes. *J Bone Joint Surg Br* 90:814–820.
9. Piper SL, Kim HT. 2008. Comparison of ropivacaine and bupivacaine toxicity in human articular chondrocytes. *J Bone Joint Surg Am* 90:986–991.
10. Rao AJ, Johnston TR, Harris AH, et al. 2014. Inhibition of chondrocyte and synovial cell death after exposure to commonly used anesthetics: chondrocyte apoptosis after anesthetics. *Am J Sports Med* 42:50–58.
11. Matsen FA 3rd, Papadonikolakis A. 2013. Published evidence demonstrating the causation of glenohumeral chondrolysis by postoperative infusion of local anesthetic via a pain pump. *J Bone Joint Surg Am* 95:1126–1134.
12. Sharma SK, Vij AS, Sharma M. 2013. Mechanisms and clinical uses of capsaicin. *Eur J Pharmacol* 720:55–62.
13. Laslett LL, Jones G. 2014. Capsaicin for osteoarthritis pain. *Prog Drug Res* 68:277–291.
14. Mou J, Paillard F, Turnbull B, et al. 2013. Efficacy of qutenza(R) (capsaicin) 8% patch for neuropathic pain: a meta-analysis of the qutenza clinical trials database. *Pain* 154:1632–1639.
15. Cantillon M, Vause E, Sykes D, et al. 2005. Safety, tolerability and efficacy of ALGRX 4975 in osteoarthritis (OA) of the knee. *J Pain* 6:S39.
16. Knotkova H, Pappagallo M, Szallasi A. 2008. Capsaicin (TRPV1 agonist) therapy for pain relief: farewell or revival? *Clin J Pain* 24:142–154.
17. Hartrick CT, Pestano C, Carlson N, et al. 2011. Capsaicin instillation for postoperative pain following total knee arthroplasty: a preliminary report of a randomized, double-blind, parallel-group, placebo-controlled, multicentre trial. *Clin Drug Investig* 31:877–882.
18. Aasvang EK, Hansen JB, Malmstrom J, et al. 2008. The effect of wound instillation of a novel purified capsaicin formulation on postherniotomy pain: a double-blind, randomized, placebo-controlled study. *Anesth Analg* 107:282–291.
19. Remadevi R, Szallasi A. 2008. Adlea (ALGRX-4975), an injectable capsaicin (TRPV1 receptor agonist) formulation for longlasting pain relief. *IDrugs* 11:120–132.
20. Friel NA, Wang VM, Slabaugh MA, et al. 2013. Rotator cuff healing after continuous subacromial bupivacaine infusion: an in vivo rabbit study. *J Shoulder Elbow Surg* 22:489–499.
21. Masuda K, Shiota H, Thonar EJ. 1994. Quantification of 35S-labeled proteoglycans complexed to alcian blue by rapid filtration in multiwell plates. *Anal Biochem* 217:167–175.
22. Kim YJ, Sah RL, Doong JY, et al. 1988. Fluorometric assay of DNA in cartilage explants using hoechst 33258. *Anal Biochem* 174:168–176.
23. Chandrasekhar S, Esterman MA, Hoffman HA. 1987. Microdetermination of proteoglycans and glycosaminoglycans in the presence of guanidine hydrochloride. *Anal Biochem* 161:103–108.
24. Grogan SP, Aklin B, Frenz M, et al. 2002. In vitro model for the study of necrosis and apoptosis in native cartilage. *J Pathol* 198:5–13.
25. Thomas CM, Fuller CJ, Whittles CE, et al. 2007. Chondrocyte death by apoptosis is associated with cartilage matrix degradation. *Osteoarthritis Cartilage* 15:27–34.
26. Pascual Garrido C, Hakimiyani AA, Rappoport L, et al. 2009. Anti-apoptotic treatments prevent cartilage degradation after acute trauma to human ankle cartilage. *Osteoarthritis Cartilage* 17:1244–1251.

27. Richards PT, Vasko G, Stasko I, et al. 2006. ALGRX 4975 reduces pain of acute lateral epicondylitis: preliminary results from a randomized, double-blind, placebo-controlled, phase II multicenter clinical trial. *J Pain* 7:S53.
28. Simone DA, Nolano M, Johnson T, et al. 1998. Intradermal injection of capsaicin in humans produces degeneration and subsequent reinnervation of epidermal nerve fibers: correlation with sensory function. *J Neurosci* 18:8947–8959.
29. Nolano M, Simone DA, Wendelschafer-Crabb G, et al. 1999. Topical capsaicin in humans: parallel loss of epidermal nerve fibers and pain sensation. *Pain* 81:135–145.
30. Lam FY, Ferrell WR. 1989. Capsaicin suppresses substance P-induced joint inflammation in the rat. *Neurosci Lett* 105:155–158.
31. Lam FY, Ferrell WR. 1991. Neurogenic component of different models of acute inflammation in the rat knee joint. *Ann Rheum Dis* 50:747–751.
32. Ferrell WR, Lam FY, Montgomery I. 1992. Differences in the axon composition of nerves supplying the rat knee joint following intra-articular injection of capsaicin. *Neurosci Lett* 141:259–261.
33. Mapp PI, Kerslake S, Brain SD, et al. 1996. The effect of intra-articular capsaicin on nerve fibres within the synovium of the rat knee joint. *J Chem Neuroanat* 10:11–18.
34. Gouze-Decaris E, Philippe L, Minn A, et al. 2001. Neurophysiological basis for neurogenic-mediated articular cartilage anabolism alteration. *Am J Physiol Regul Integr Comp Physiol* 280:R115–R122.
35. Kalf KM, El Mouedden M, van Egmond J, et al. 2010. Pretreatment with capsaicin in a rat osteoarthritis model reduces the symptoms of pain and bone damage induced by monosodium iodoacetate. *Eur J Pharmacol* 641:108–113.
36. Kassis EN, Moore DC, Ehrlich MG. 2005. Intraarticular capsaicin does not lead to joint degeneration. *Trans Orthop Res Soc* 30:1037.
37. Kramer SM, May JR, Patrick DJ, et al. 2009. Instilled or injected purified natural capsaicin has no adverse effects on rat hindlimb sensory-motor behavior or osteotomy repair. *Anesth Analg* 109:249–257.
38. Nho SJ, Cole BJ, Mazzocca AD, et al. 2006. Comparison of ultrasonic suture welding and traditional knot tying in a rabbit rotator cuff repair model. *J Shoulder Elbow Surg* 15:630–638.
39. Bring DK, Paulson K, Renstrom P, et al. 2012. Residual substance P levels after capsaicin treatment correlate with tendon repair. *Wound Repair Regen* 20:50–60.
40. Ackermann PW, Li J, Lundeberg T, et al. 2003. Neuronal plasticity in relation to nociception and healing of rat achilles tendon. *J Orthop Res* 21:432–441.
41. Lian O, Dahl J, Ackermann PW, et al. 2006. Pronociceptive and antinociceptive neuromediators in patellar tendinopathy. *Am J Sports Med* 34:1801–1808.
42. Andersson G, Backman LJ, Scott A, et al. 2011. Substance P accelerates hypercellularity and angiogenesis in tendon tissue and enhances paratendinitis in response to achilles tendon overuse in a tendinopathy model. *Br J Sports Med* 45:1017–1022.