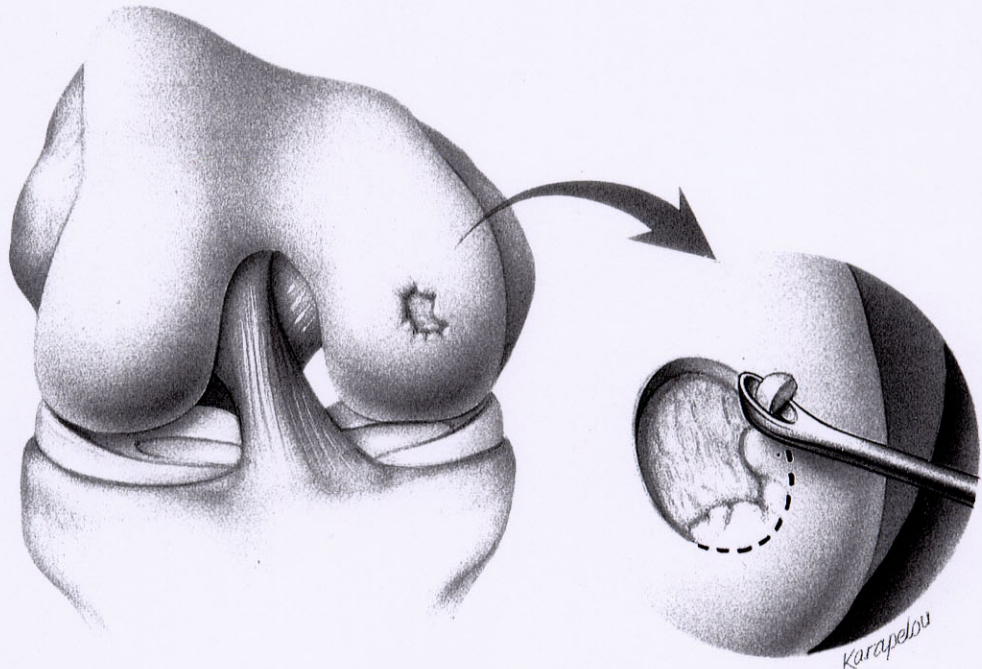


# ATLAS OF CHONDRAL INJURY TREATMENT

MARK D. MILLER, MD, and BRIAN J. COLE, MD

**Fig 1.** Most of the techniques presented in this issue are proposed for treatment of chondral lesions, commonly located on the medial femoral condyle. Most techniques begin with debridement of the edges of the lesion as shown here.



From the University of Virginia, Department of Orthopaedic Surgery, Charlottesville, VA; and Rush University, Department of Orthopaedics, Rush Cartilage Restoration Center, Chicago, IL.

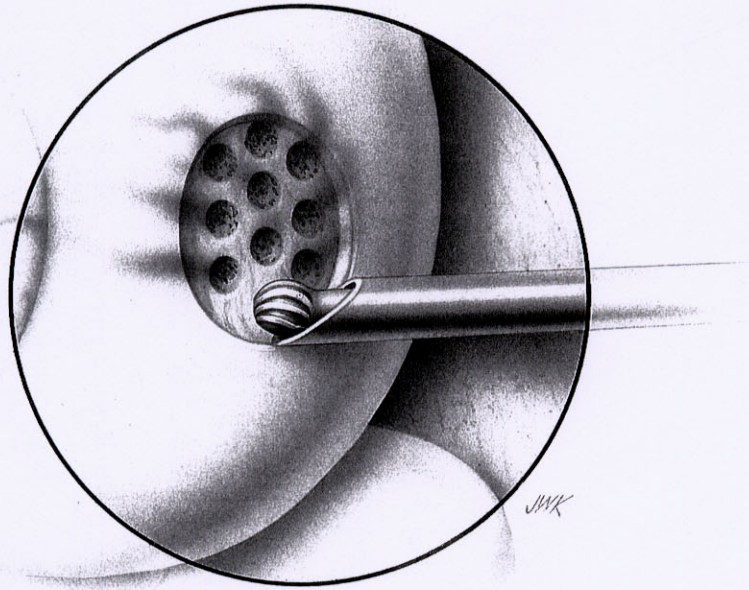
Address reprint requests to Mark D. Miller, MD, University of Virginia, Department of Orthopaedic Surgery, PO Box 800753, Charlottesville, VA 22908.

Modified and reprinted with permission from Miller MD: Atlas of Chondral Injury Treatment. *Op Tech Orthop* 7:289-293, 1997.

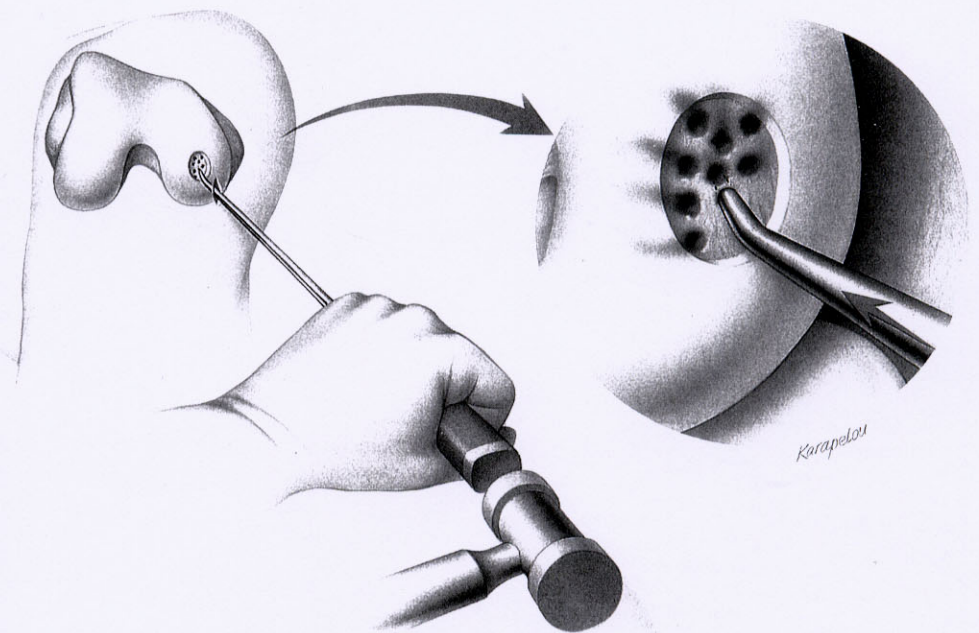
Copyright © 2001 by W.B. Saunders Company

1048-6666/01/1102-0014\$35.00/0

doi:10.1053/otor.2001.23465

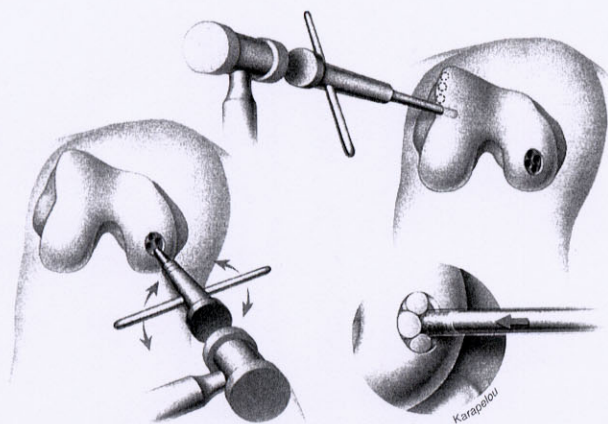
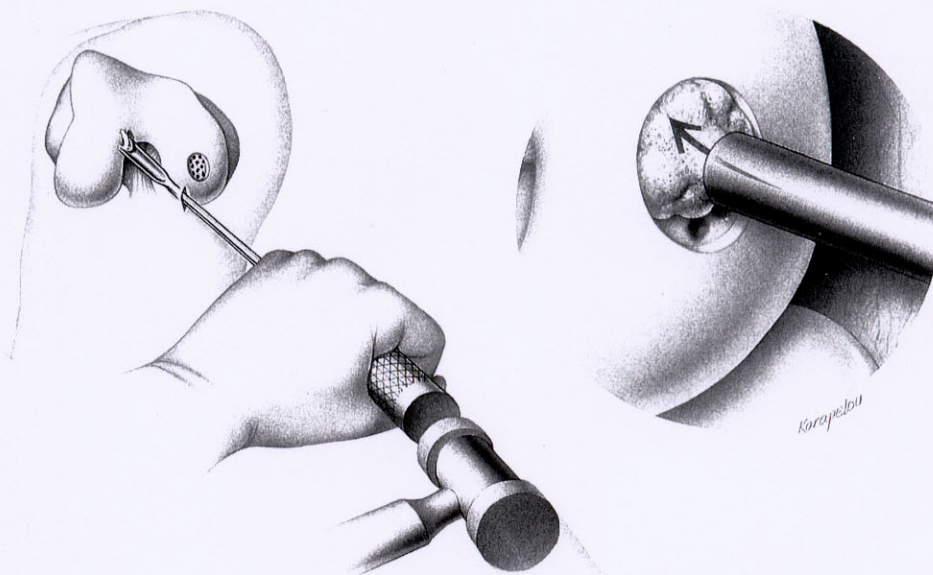


**Fig 2. Abrasion chondroplasty.** This technique, popularized by Dr Lanny Johnson, involves abrasion of the exposed subchondral bone to allow vascular ingrowth and stem cell production of fibrocartilage.

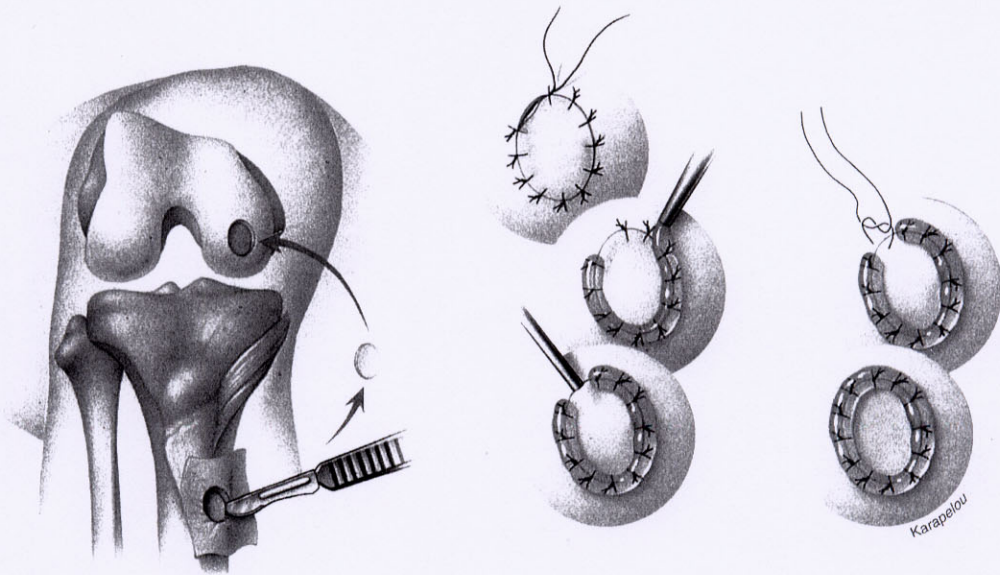


**Fig 3. Microfracture.** This technique, developed by Dr Richard Steadman, is a variation of abrasion chondroplasty. Awls, with various degrees of angulation, are introduced through the ipsilateral arthroscopic portal and are used to penetrate the subchondral bone and encourage stem cell production of cartilage-like tissue.

**Fig 4. Slurry grafting.** This procedure has been proposed by Dr Kevin Stone and begins with defect preparation and microfracture. Next, bone and articular cartilage is harvested from the intercondylar notch and is run through a bone mill, creating a bone-cartilage slurry. This is then introduced into the defect with a special plunger. A plug is delivered through a cylinder and the pusher rod is gently tapped into place to insert the plug into the defects. According to Dr Stone, the bone and cartilage reform their normal relationships and repair the defect.

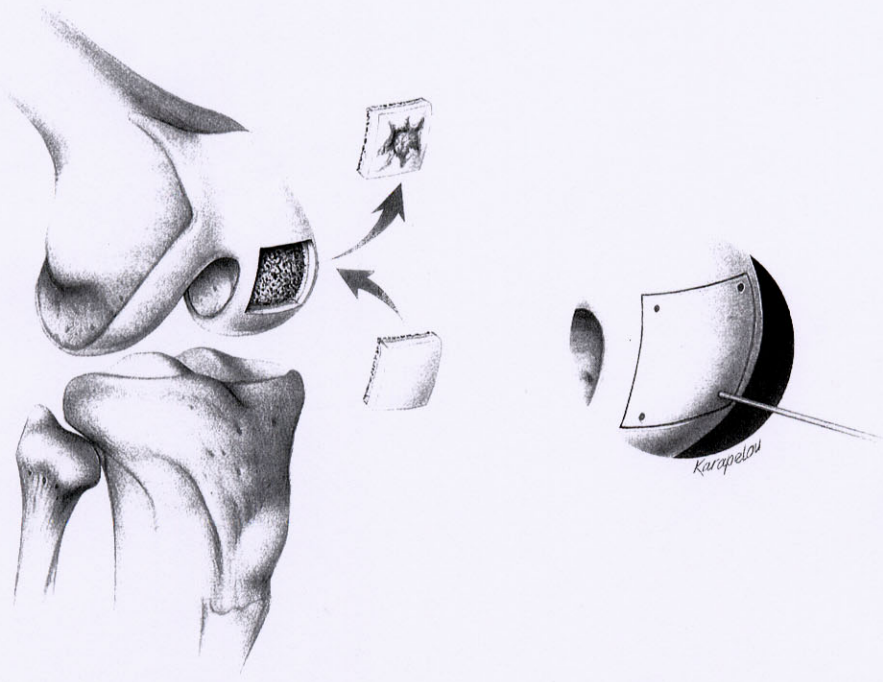
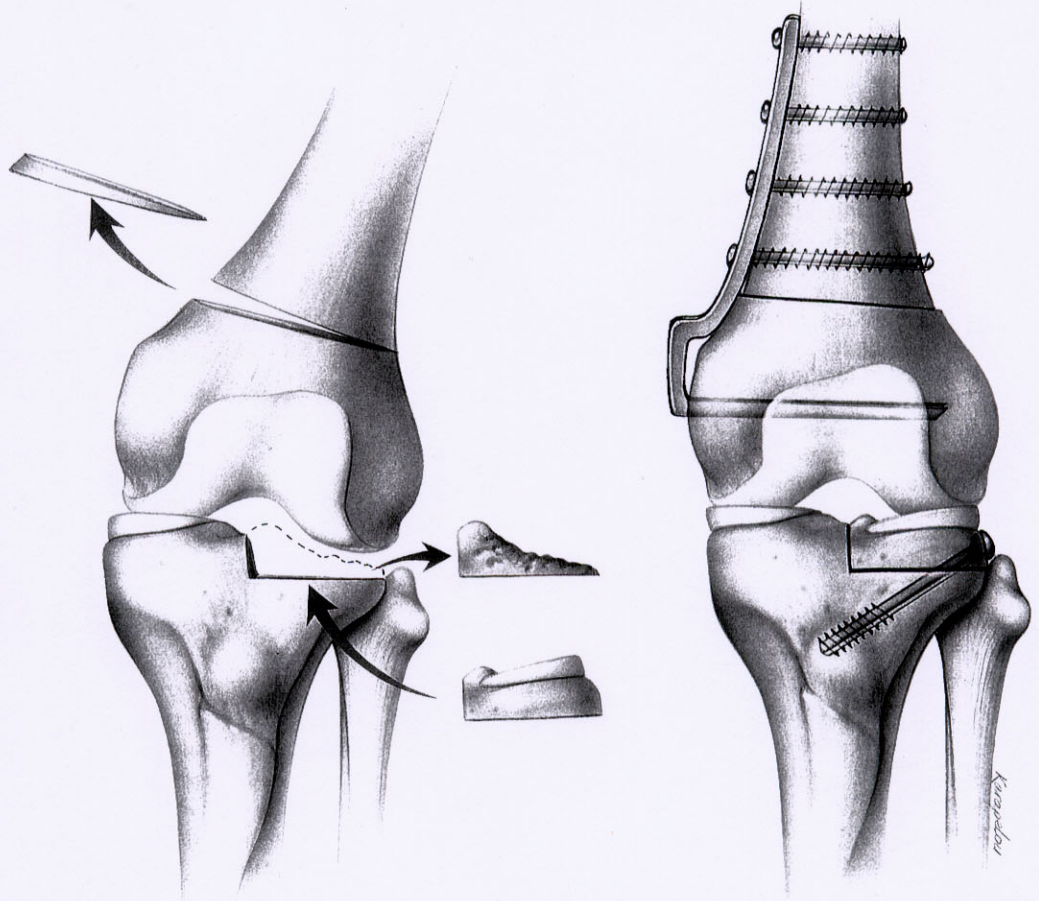


**Fig 5. Osteochondral plugs.** There are at least 3 companies that have commercially available equipment for this technique, which is analogous to changing the pin position on a golf green. Cylindrical plugs of exposed bone are removed from the defect and plugs of normal nonweightbearing cartilage and bone are harvested and placed into the defect. Plugs can be created in various sizes and geometrically placed to maximally fill the area.



**Fig 6. Chondrocyte transplant.** This technique, developed in Sweden, has received the most media attention and has generated a lot of excitement in the medical community and lay public. Articular cartilage is harvested arthroscopically from the non-weight-bearing area of the knee during the index procedure. This cartilage is sent to a laboratory where cartilage cells are grown. A second open procedure is then completed several weeks or months later after the cells are available. Periosteum is harvested and sewn into the prepared defect with the cambium layer facing inward (A). Fibrin glue, which is prepared from a unit of the patient's own blood obtained at least 24 hours before the procedure, is used to seal the patch (B). The cartilage cell mixture is then injected under the patch (C). The cells are injected and the superiorly gap is closed and the fibrin glue is placed over the edges of the patch. It is said to stimulate normal cartilage regeneration in the defect.

**Fig 7. Osteochondral allograft.** This procedure, popularized by Dr Allen Gross and Dr John Garrett, involves transplantation of a fresh osteoarticular allograft into an excised area of injured cartilage and subchondral bone. An important part of this procedure is to correct the normal mechanical alignment of the joint.



**Fig 8. Shell allograft.** This procedure, developed by researchers in San Diego, is analogous to repairing a defect in your lawn with a piece of sod. The defect is excised and a matched fresh osteoarticular allograft is inserted into this area. It can be secured with mechanical interface or absorbable K-wires.

Fig 9. Periosteal graft. This procedure, currently under investigation by Dr Shawn O'Driscoll, is similar to the technique for fixing a puncture in an innertube. Periosteum is used for the patch, but unlike the chondrocyte transplant technique, the inner cambium layer is rotated so that it is facing outward. The patch is carefully sewn in place and cartilage may grow out from the undifferentiated cambium layer of the graft.

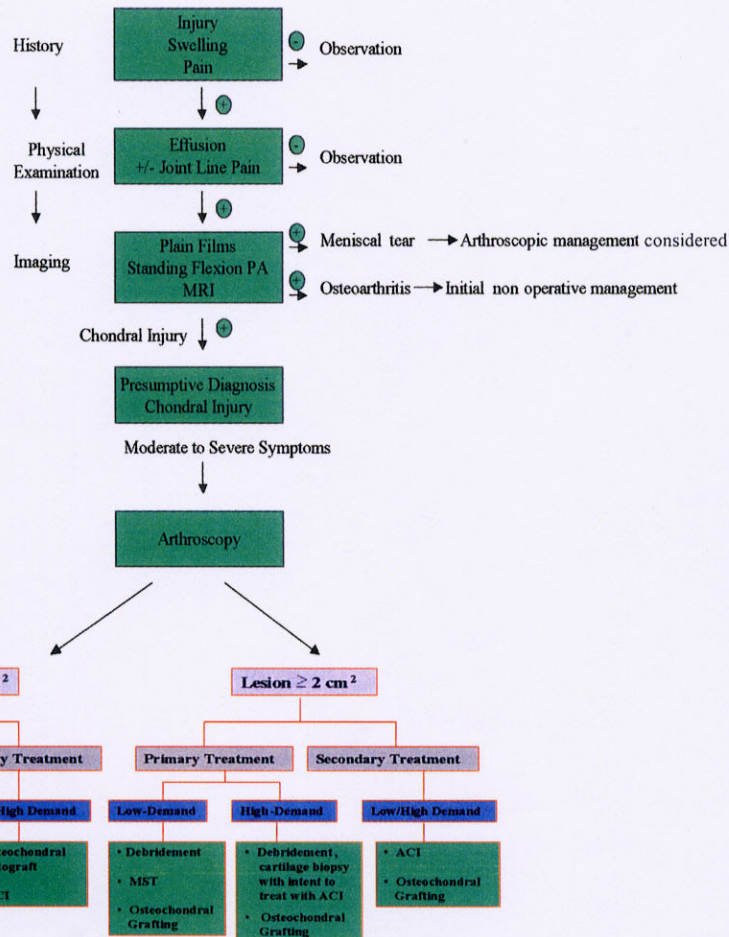
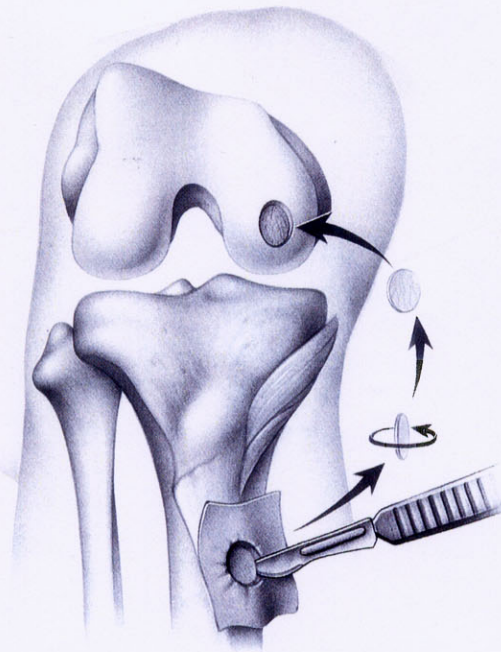


Fig 10. Evaluation and treatment algorithm for the management of chondral injury. MST, marrow stimulating technique (ie, microfracture, abrasion arthroplasty, drilling); ACI, autologous chondrocyte implantation.