



Closure of Patellar Tendon Defect in Anterior Cruciate Ligament Reconstruction With Bone–Patellar Tendon–Bone Autograft: Systematic Review of Randomized Controlled Trials

Rachel M. Frank, M.D., Randy Mascarenhas, M.D., Marc Haro, M.D.,
Nikhil N. Verma, M.D., Brian J. Cole, M.D., M.B.A., Charles A. Bush-Joseph, M.D., and
Bernard R. Bach Jr., M.D.

Purpose: This study aimed to systematically review the highest level of evidence on anterior cruciate ligament (ACL) reconstruction with bone–patellar tendon–bone (BPTB) autografts with patellar tendon defect closure versus no closure after surgery. **Methods:** We performed a systematic review of multiple medical databases using Preferred Reporting Items for Systematic Reviews and Meta-Analyses (PRISMA) guidelines. Level I and Level II randomized controlled trials comparing patellar tendon defect closure to no closure during ACL reconstruction with BPTB autografts were included. Two independent reviewers analyzed all studies. Descriptive statistics were calculated. Study methodological quality was analyzed using the Modified Coleman Methodology Score (MCMS) and Jadad scale. **Results:** Four studies with a combined 221 patients (154 male patients and 67 female patients) with an average age of 26.6 ± 2.4 years (range, 17 to 54 years) were included. All studies randomized patients before surgery into ACLR with BPTB autografts either with patellar tendon defect closure or without closure. There were no differences in clinical outcomes (Lysholm score, Tegner scale, International Knee Documentation Committee [IKDC] classification, modified Larsen score, and Lauridsen rating) between groups. There were no significant differences in knee pain between groups. All studies reported imaging findings of the patellar tendon defect, with 2 studies showing no difference in appearance between groups, one study showing excessive scar formation with defect repair, and one study showing improved restoration of normal tendon appearance with defect repair. The overall quality of the studies was poor, with all studies scoring less than 46 (average, 40.5 ± 4.7) on the MCMS and scoring 1 on the Jadad scale. **Conclusions:** Based on this systematic review of 4 randomized trials, there are no statistically significant or clinically relevant differences in outcomes between patients who have the patellar tendon defect closed and those who have it left open after ACLR with BPTB autografts. The methodology of the included studies limits the interpretation of the data, as evidenced by low MCMS and Jadad scores. **Level of Evidence:** Level II, systematic review of Level I and Level II studies.

Anterior cruciate ligament (ACL) injuries remain extremely common in the young athletic patient population, with an estimated 250,000 ACL injuries sustained per year in the United States.^{1,2} For the majority of these patients, ACL reconstruction (ACLR) is

performed, with the goal of restoring knee stability, improving function for activities of daily living and sport, and preventing future articular cartilage or meniscal deterioration, or both.³ ACLR can be performed through a variety of techniques and with a variety of grafts. Graft choices include either autogenous tissue (central-third bone–patellar tendon–bone [BPTB], hamstring, and quadriceps autografts) or allograft tissue (BTPB, hamstring, Achilles, tibialis anterior, and so on).⁴

The most commonly used graft for ACLR is the BPTB autograft, especially in high-level athletes and high-demand patients.^{5–9} Outcomes after ACLR with BTPB autografts are encouraging, with excellent subjective and objective outcomes, high return-to-play rates, and low overall failure rates.^{9–14} Complications after ACLR with BPTB autografts are uncommon but can include

From Department of Orthopedic Surgery, Rush University Medical Center, Chicago, Illinois, U.S.A.

The authors report the following potential conflict of interest or source of funding: B.J.C. and N.N.V. receive support from Arthrex, DJ Orthopedics, Zimmer, Regentis, Carticept, Smith & Nephew, Johnson & Johnson, and Medipost.

Received August 11, 2014; accepted September 8, 2014.

Address correspondence to Rachel M. Frank, M.D., Rush University Medical Center, 1611 West Harrison Street, Ste 201, Chicago, IL 60612, U.S.A. E-mail: rmfrank3@gmail.com

© 2015 by the Arthroscopy Association of North America
0749-8063/14687/\$36.00

<http://dx.doi.org/10.1016/j.arthro.2014.09.004>

patellar fractures, patellar tendon rupture, patellar subluxation, diminished extensor mechanism function, and anterior knee pain.¹⁵⁻¹⁹

The surgical technique for ACLR with BTPB a autograft has been previously described^{7,8} and involves harvesting the central third of the ipsilateral patellar tendon with bone plugs from the patella and tibia. After incision through the skin and subcutaneous tissue, the peritenon surrounding the patellar tendon is incised, allowing full exposure of the patellar tendon, followed by harvest of the central third of the tendon. At the conclusion of the procedure, closure techniques are variable and can include closing both the patellar tendon and peritenon defects, closing either the patellar tendon or peritenon defect alone, or leaving both defects unrepaired. Currently, there is no consensus regarding the standard of care for management of the patellar tendon defect after ACLR with a BPTB autograft.

The purpose of this study was to review the published literature on ACLR with a BPTB autograft with patellar tendon defect closure versus no closure after surgery. We hypothesized that there would be no significant difference in clinical outcomes between patients undergoing patellar tendon defect closure compared with those without closure.

Methods

We performed a systematic review of multiple medical databases using Preferred Reporting Items for Systematic Reviews and Meta-Analyses (PRISMA)

guidelines.²⁰ Before conducting the search, a systematic review registration was completed on August 12, 2013 using the PROSPERO International prospective register of systematic reviews (registration number CRD42013005357).²¹ Two independent reviewers (R.M.F., R.M.) completed the search, which was performed on August 13, 2013. The following databases were used: Medline (PubMed), CINAHL (Cumulative Index to Nursing and Allied Health Literature), and Cochrane Central Register of Controlled Trials. The following terms were searched: “anterior cruciate ligament,” “patellar tendon defect,” and “randomized.” The electronic search citation algorithm used was: ac[All Fields] AND (“patellar ligament”[MeSH Terms] OR (“patellar”[All Fields] AND “ligament”[All Fields]) OR “patellar ligament”[All Fields] OR (“patellar”[All Fields] AND “tendon”[All Fields]) OR “patellar tendon”[All Fields]) AND defect[All Fields] AND closure[All Fields].

Inclusion criteria included English-language, Level I and Level II randomized controlled trials comparing patellar tendon defect closure to no closure with a minimum of a 6-month follow-up after ACLR with a BPTB autograft. Exclusion criteria included non-English language studies, basic science or imaging studies, novel technique studies, scientific meeting abstracts/proceedings, and systematic reviews/meta-analyses. Levels of Evidence I and II were deemed inclusive (per the Oxford Centre for Evidence-Based Medicine used by the American version of the *Journal of Bone and Joint Surgery*²² and *Arthroscopy*). All references within included

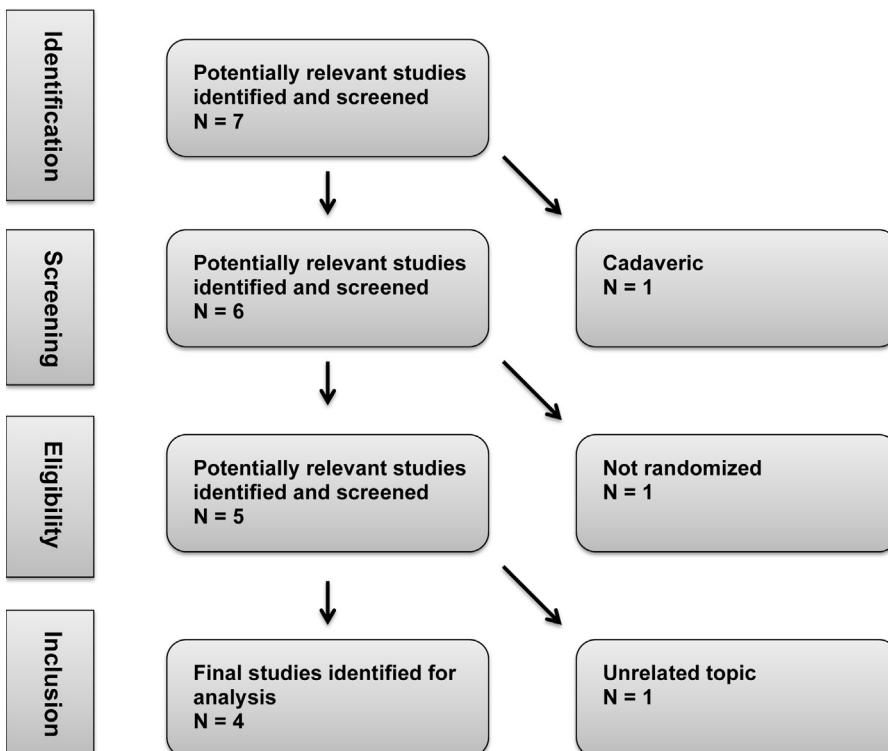


Fig 1. Systematic review search algorithm using Preferred Reporting Items for Systematic Reviews and Meta-Analyses (PRISMA) guidelines within Medline database. After application of all exclusion criteria, 4 studies were identified for final analysis.

Table 1. Summary of Study Demographic Information

Author	Year	Journal	Level of Evidence	Number of Patients	Average Age, yr	Age Range, yr	Number of Male Patients	Number With PT Closed	Number With PT Open	Average Follow-up Duration, mo	Number of Patients Available for Follow-up (%)	No. of Right Knees	Graft Used	Surgical Technique
Adriani et al. ²⁵	1995	KSSTA	I	61	26	17-52	40 (66%)	36 (59%)	25 (41%)	6	61 (100%)	33	BPTB autograft	Arthroscopically assisted ACLR with inside-out technique Side-to-side repair of tendon defect in 25 Tendon left open; peritenon closed in 36
Kohn et al. ¹⁷	1994	KSSTA	I	50	29	19-37	31 (62%)	25 (50%)	25 (50%)	30	40 (80%)	NA	BPTB autograft	Two-incision arthroscopically assisted ACLR with notchplasty Similar tunnel and screw sizes within groups Closed (group I): patellar defect packed with reamed bone ± additional cancellous bone from tibial head; peritenon closed with running No. 2-0 Vicryl sutures Open (group II): patellar defect loosely covered with gel foam, peritenon left open
Cerullo et al. ²⁶	1995	KSSTA	I	50	23.5	17-34	43 (86%)	25 (50%)	25 (50%)	6	40 (80%)	NA	BPTB autograft	Closed group: 3 full-thickness simple interrupted No. 0 Vicryl sutures, followed by peritenon closure in same way if possible Open group: peritenon closure in same way if possible
Brandsson et al. ²⁴	1998	KSSTA	I	60	28	17-48	40 (67%)	29 (48%)	31 (52%)	24	50 (83%)	NA	BPTB autograft	Two-incision arthroscopically assisted outside-in technique; meniscal pathologic process addressed as needed; notchplasty in 100%; paratenon closed in all with interrupted sutures Closed group: patellar tendon defect closed, patellar bone grafted Open group: neither of above
Average				55.25	26.63					16.50				
Standard deviation				6.08	2.43					12.37				

ACLR, anterior cruciate ligament reconstruction; BPTB, bone–patellar tendon–bone; KSSTA, *Knee Surg Sports Traumatol Arthrosc*; NA, not available; PT, patellar tendon.

Table 2. Summary of Study Outcomes: Imaging

Author	Ultra-sonography at 6 Mo: Closed (% Normal)	Ultra-sonography at 6 Mo: Open (% Normal)	Ultra-sonography at 12 Mo: Closed (% Normal)	Ultra-sonography at 12 Mo: Open (% Normal)	Ultrasonographic Appearance At 6 Mo: Closed	Ultrasonographic Appearance At 6 Mo: Open	Vertical Position of Patella on Lateral XR at 6 Mo: Closed	Vertical Position of Patella on Lateral XR at 6 Mo: Open
Adriani et al. ²⁵	26.91 (111.11)	37.54 (90.15)	16.47 (32.23)	30.5 (16.66)	"Binocular" appearance of 2 cords separated by a hyperechogenic bridge; with echogenic core surrounded by hyperechogenic ring; at 1 yr, echogenicity returned to normal; patellar bone defect evident at 1 yr	"Binocular" appearance of 2 cords separated by a hyperechogenic bridge; with echogenic core surrounded by hyperechogenic ring; at 1 yr, the cords still distinct with new tissue filling central area but different from true tendon structure; patellar bone defect evident at 1 yr	Patella alta ×1	Patella alta ×1; patellar lengthening ×1
Kohn et al. ¹⁷	NA	NA	NA	NA	Normal appearance of PT after 2 yr; earlier healing of patellar defect	No healing of PT after 2 yr	NA	NA
Cerullo et al. ²⁶	NA	NA	NA	NA	NA	NA	No significant shortening	No significant shortening
Brandsson et al. ²⁴	NA	NA	NA	NA	Central scar or gap at middle third with varying degree of tendon healing; lateral and medial thirds with oval-shaped hypertrophy (no difference between groups) Closed: complete healing in 11, partial healing in 5, no healing in 7	NA	NA	NA

NA, not available; PT, patellar tendon; XR, radiograph.

studies were cross-referenced for potential inclusion if somehow omitted from the initial search. Figure 1 shows the search strategy used according to PRISMA guidelines to generate the final study list.

After the original search, studies were reviewed for relevance by using previously described inclusionary and exclusionary criteria. Two independent reviewers (R.M.F., R.M.) analyzed studies deemed appropriate for inclusion. For all included studies, data collected included demographic data; intraoperative data, including type of graft, surgical technique, and method of defect closure (when performed); postoperative data, including rehabilitation, physical examination findings, pain level and other subjective outcomes, imaging findings (when available), return to activity, return to sport, reoperation rate, and complications. Study methodological quality was analyzed using the Modified Coleman Methodology Score (MCMS)²³ and Jadad scale.²⁴ Given the different methodology used in each

of the studies, quantitative statistical analysis of the studies as a whole was not possible, and descriptive analysis was performed. Continuous variable data were reported as mean ± standard deviation. Weighted means and standard deviations were calculated for all participant, surgical, and outcomes parameters. Categorical variable data were reported as frequencies with percentages.

Results

Seven studies were identified with the initial search. Three of these studies were excluded, including one cadaveric study, one study that was not randomized, and one study that discussed topics unrelated to closure of the patellar tendon defect during ACLR with a BTPB autograft. Thus, a total of 4 studies^{18,25-27} met the inclusion criteria and underwent further analysis (Fig 1). These studies are described in detail in Table 1.

Patellar Height on Lateral XR at 1 Yr: Closed	Patellar Height on Lateral XR at 1 Yr: Open	Patellar Shortening on XR: Closed	Patellar Shortening on XR: Open	Inferior Pole Spurs on PA-Frik View at 6 Mo: Closed	Inferior Pole Spurs on PA-Frik View at 6 Mo: Open	Inferior Pole Spurs on PA-Frik View at 1 Yr: Closed	Inferior Pole Spurs on PA-Frik View at 1 Yr: Open	Computed Tomographic Findings at 6 Mo: Closed	Computed Tomographic Findings At 6 Mo: Open
NA	NA	NA	NA	NA	NA	NA	NA	NA	NA
<2 mm: 14; 3-10 mm: 2; constant: 9 NA	<2 mm: 13; 3-10 mm: 2; constant: 10 NA	<2 mm: 14; 3-10 mm: 2; constant: 9 NA	<2 mm: 13; 3-10 mm: 2; constant: 10 NA	6 NA	0 NA	9 NA	0 NA	NA N = 20 14 thickened 2x; 6 thickened 1.5x; width 15% less than normal; scar tissue throughout medial and lateral thirds NA	NA N = 20 15 normal; 5 slightly thickened; normal width; scar tissue central third NA
NA	NA	NA	NA	NA	NA	NA	NA	NA	NA

All studies randomized patients before surgery into ACLR with a BPTB autograft either with patellar tendon defect closure or without closure. There were a combined 221 patients (154 male patients and 67 female patients) in the 4 studies. The average age of the patients was 26.6 ± 2.4 years (range, 17 to 54 years). The average postoperative follow-up was 16.5 ± 12.4 months (range, 6 to 30 months), with an average 85.8% ± 9.6% follow-up rate. A total of 52% (n = 115) of knees underwent patellar tendon defect closure, whereas 48% (n = 106) of knees did not.

Surgical technique, including closure of the patellar tendon defect, varied by study, with the most common technique involving side-to-side closure with Vicryl suture (Ethicon, Somerville, NJ). Adriani et al.²⁵ performed arthroscopically assisted ACLR using an inside-out technique, followed by either side-to-side repair of the tendon defect (n = 25 knees) or closure of the peritenon while leaving the defect open (n = 36 knees).

Brandsson et al.²⁴ performed 2-incision arthroscopically assisted ACLR using an outside-in technique, followed by either closure of the patellar tendon defect with patellar bone grafting (n = 29) or no-closure/no-grafting (n = 31); in both groups, all patients underwent closure of the peritenon with interrupted sutures. Cerullo et al.²⁶ performed arthroscopically assisted ACLR in all patients followed by either patellar tendon closure with 3 full-thickness simple interrupted No. 0 Vicryl sutures (n = 25) or no closure of the defect (n = 25); all patients underwent peritenon closure with interrupted Vicryl sutures as well. Kohn et al.¹⁷ performed 2-incision arthroscopically assisted ACLR followed by either bone grafting of the patellar defect with reamed bone and peritenon closure with a running No. 2-0 Vicryl suture (n = 25) or loose coverage of the patellar defect with gel foam and no peritenon closure (n = 25). Only 2 of the 4 studies reported on their rehabilitation protocol, as illustrated in Table 1.

Table 3. Summary of Study Outcomes: Clinical

Author	Larsen and Lauridsen Rating Scale Modified (Mean Score) at 6 Mo: Closed	Larsen and Lauridsen Rating Scale Modified (Mean Score) at 6 Mo: Open	ROM (°) at 2 Wk: Closed	ROM (°) at 2 Wk: Open	IKDC Score at 2 Yr: Closed	IKDC Score at 2 Yr: Open	Lysholm Score at 2 Yr: Closed	Lysholm Score at 2 Yr: Open
Adriani et al. ²⁵	9.88	9.36	NA	NA	NA	NA	NA	NA
Kohn et al. ¹⁷	NA	NA	NA	NA	No significant differences at 2 yr (only graphs; no actual numbers given)	No significant differences at 2 yr (only graphs; no actual numbers given)	NA	NA
Cerullo et al. ²⁶	NA	NA	3.6-101	3.2-98.5	NA	NA	NA	NA
Brandsson et al. ²⁴	NA	NA	NA	NA	9 A, 13 B, 1 C, 1 D; no significant difference between groups	13 A, 11 B, 2 C, 0 D; no significant difference between groups	74 preoperatively to 95 postoperatively (significant improvement); no significant difference between groups; 3 < 84	76 preoperatively to 95 postoperatively (significant improvement); no significant difference between groups; 2 < 84

ACL, anterior cruciate ligament; IKDC, International Knee Documentation Committee; NA, not available; PT, patellar tendon; ROM, range of motion.

A summary of the physical examination findings, clinical outcomes scores, and imaging data is provided in Tables 2 and 3. Physical examination findings were inconsistently reported. One study²⁷ commented on postoperative range of motion at 2 weeks after surgery, with nearly identical values in the open-defect (3.2° to 98.5°) and closed-defect (3.6° to 101°) groups. Also at 2 weeks postoperatively, the authors noted that 40% (n = 10) of patients in the open-defect group had pain while performing an isometric quadriceps contraction, compared with 56% (n = 14) with pain in the closed-defect group. Three^{18,25,27} of the 4 studies (75%) commented on postoperative inferior pole patellar pain, with essentially no differences between the open and closed groups. Pain ranged from 13% to 60% in the closed-defect group compared with 15% to 80% in the open-defect group.

Clinical outcomes scores, including Lysholm scores, Tegner scores, International Knee Documentation Committee (IKDC) scores, and modified Larsen and Lauridsen ratings, were variably reported. When provided, there were no differences in these outcomes between the defect-open and defect-closed groups in any of the studies. There were no significant differences in knee pain between groups, although one study noted increased painful spur formation in 36% of patients, which the authors attributed to bone grafting of the patellar defect.²⁷ All studies reported on some form

of imaging follow-up, including radiographs of the knee^{18,26,27} or advanced imaging (ultrasonography^{18,25,26} or computed tomography,²⁷ or both) findings (or both) of the patellar tendon defect. Fifty percent (2 studies) found no difference in patellar tendon appearance between groups,^{25,26} 25% (one study) found excessive scar formation with defect repair,²⁷ and 25% (one study) showed improved restoration of normal tendon appearance with defect repair.¹⁸

Only one of the 4 (25%) studies²⁵ reported on reoperation rates, with 7% (2 of 29) of patients undergoing reoperation in the closed-defect group, both for meniscal injuries. In the open-defect group, 6% (2 of 31) of patients underwent reoperation for either meniscal injury (one patient) and a recurrent traumatic ACL tear (one patient).

By definition, all 4 studies were considered Level of Evidence I or II. The overall quality of the 4 studies per the MCMS was poor, with all studies scoring less than 46 (average 40.5 ± 4.7). Similarly, all studies achieved a score of one on the Jadad scale.

Discussion

The principal findings of this study are as follows: (1) the data is inconsistent regarding the effect of patellar tendon defect closure on postoperative pain and function after ACLR with a BTPB autograft and (2) despite including only randomized clinical trials, the

Tegner Score at 2 Yr: Closed	Tegner Score at 2 Yr: Open	Local Tenderness to Palpation Above Inferior Pole: Patella Closed	Local Tenderness to Palpation Above Inferior Pole: Patella Open	Reoperations: Closed	Reoperations: Open	Main Conclusions
NA	NA	NA	NA	NA	NA	No important differences between the groups
NA	NA	60% at 6 mo	80% at 6 mo	NA	NA	Suturing peritendineum enhances healing and restores normal appearance of tendon; bone grafting patellar defect increases risk of painful spurs
NA	NA	32% at 5-8 mo	35% at 5-8 mo	NA	NA	No important differences between the groups, but closing tendon results in exuberant scar, so "probably" better to leave defect open
8 preoperatively to 6 postoperatively (significant worsening); no significant difference between groups	7 preoperatively to 5 postoperatively (significant worsening); no significant difference between groups	12.5% at 2 yr	15.4% at 2 yr	2 for meniscal injury within 2 yr postoperatively	1 for meniscal injury within 2 yr postoperatively; 1 for rupture of ACL after new trauma	No important differences between groups; bone grafting patella and suturing tendon do not improve outcomes or reduce donor site morbidity

methodology of the included studies limits the interpretation of the data, as evidenced by the low MCMS and Jadad scores.

In the younger athletic high-demand patient population, ACLR with a BPTB autograft is the most commonly used graft choice.⁵⁻⁹ Even at the most competitive level with professional athletes, ACLR with a BPTB autograft is a reproducible surgical technique that uses a graft with high tensile strength, optimal fixation with bone-to-bone healing, and high return-to-play rates, with low overall complication and failure rates.⁹⁻¹⁴ Potential complications²⁸ are rare, but dysfunction of the extensor mechanism,^{19,29-31} including patellar fracture,^{17,32-36} tibial tubercle fracture, or failure of the patellar tendon itself, remain the most worrisome. Lee et al.¹⁸ described a series of 1,725 consecutive ACLRs with BPTB autografts over a 20-year period and noted 3 complications related to patellar tendon harvest (0.2% complication rate), including 2 patellar fractures (one intraoperative and one postoperative) and one patellar tendon rupture (postoperative).

The critical contribution of the patellar tendon to the knee extensor mechanism, combined with the large central-third defect within the patellar tendon after a patellar tendon autograft harvest, certainly calls into question the role of patellar tendon defect closure after patellar tendon autograft harvest. Although ideally the decision to perform patellar tendon defect closure

should be evidence based, given the paucity of data available in the literature, the intraoperative decision often comes down to balancing the potential perceived risks of closure (patella baja, decreasing patellar tendon length, suture irritation, increased operative time) with the potential perceived benefits (biological graft coverage by decreasing the large void created by an otherwise empty space left by harvest of the central third of the patellar tendon). Further, the relative individual contributions of bone grafting of the patellar defect versus closure of the patellar tendon defect versus closure of the peritendon on improving functional outcomes and decreasing postoperative pain are unclear.

Recently, Sobieraj et al.³⁶ studied the mechanical implications of patellar tendon defect closure on the remaining patellar tendon after BPTB harvest. Using matched (by tendon dimension) pairs of fresh-frozen cadaveric patellar tendons, the authors harvested BPTB grafts from all the specimens and then performed defect closure in one half of the knees. After biomechanical testing, the authors noted no difference in load to failure, failure stress, stiffness, or modulus between the repaired tendons and those with the defect left open. In a separate cadaveric study, Eilerman et al.³⁷ assessed the effect of patellar tendon harvest on patellofemoral contact pressures. The authors found no differences in patellofemoral joint pressures at varying

degrees of knee flexion (30°, 60°, and 90°) with and without side-to-side patellar tendon defect repair after central-third BPTB harvest. These cadaveric studies call into question the biomechanical role of patellar tendon defect closure.

In addition to biomechanical studies, several magnetic resonance imaging studies^{38,39} have found evidence of patellar tendon reconstitution after graft harvest. Nixon et al.³⁸ reported that the size and intensity of the signal defect decreased over time, with an appearance identical to normal tendon tissue at 2 years after surgery. The authors performed biopsy procedures on 8 patients undergoing additional ipsilateral knee surgery after ACLR with BPTB autografts and noted essentially no histologic differences when compared with normal tendon histologic characteristics at 2 years after surgery. In a separate imaging study of 20 patients undergoing ACLR with BPTB harvest followed by defect closure, Coupens et al.³⁹ found a nearly normal appearance of the patellar tendon at 1.5 years after surgery. Interestingly, the authors noted that throughout the follow-up period, the patellar tendon was found to have increased thickness compared with the contralateral leg but without any change in tendon width, despite the defect undergoing closure at the time of surgery.

Similar to the relatively inconclusive results found in these cadaveric and imaging studies, the results from the present systematic review are unable to provide evidence supporting or negating the routine use of patellar tendon defect closure after ACLR with a BPTB autograft. Although Adriani et al.²⁵ noted increased scar formation on ultrasonography in the open-defect group compared with the closed-defect group at 1 year after surgery, their clinical, imaging and isokinetic findings were similar between the groups by 6 months after surgery. This finding led the authors to conclude that patellar tendon defect closure does not influence the extensor mechanism. Similarly, Brandsson et al.²⁴ concluded that patellar tendon defect closure and bone grafting showed no improvement when compared with leaving the defect open based on finding no differences in pain, ultrasonographic findings, donor site morbidity, knee stability, or overall functional outcome at 2 years after surgery. In contrast, Cerullo et al.²⁶ found computed tomographic evidence of a substantially thickened patellar tendon with scar tissue in the central third as well as the medial/lateral thirds in all patients undergoing defect closure compared with only 25% of patients in the open-defect group. Although there were no significant clinical or functional differences between the groups, the authors stated that it is "probably better" to leave the defect open after ACLR with BPTB autograft harvest. The results from the final study included in this systematic review¹⁷ further

cloud the data because the authors found restoration of a normal tendon-like appearance with peritenon closure when compared with not closing the defect. Interestingly, the authors did find painful bone spur formation at the inferior pole of the patella in more than one third of patients who underwent patellar defect bone grafting, leading the authors to discontinue grafting while continuing with peritenon closure.

In a separate clinical study, Shaffer and Tibone⁴⁰ used both intraoperative measurements and postoperative radiographs to determine the potential effect of patellar tendon defect closure on patellar tendon length and overall patellar position. In this study, 36 patients underwent ACLR with BPTB, with half of the patients undergoing patellar tendon defect closure and all patients undergoing peritenon closure. The authors found no evidence of clinically relevant patellar tendon shortening in the closure group and also found no evidence of patella baja. Other studies, however, have found evidence of patellar tendon shortening after ACLR with BPTB autografts.^{41,42}

Overall, the included studies represent the highest level of available evidence regarding the effect of patellar tendon defect closure on postoperative pain and function after ACLR with BPTB autografts. Nevertheless, it remains difficult to draw conclusions or make clinical recommendations based on this pooled data set. As noted, these studies did not assess kneeling pain or consistently measure any potential shortening of the extensor mechanism compared with the nonoperative knee, and this information would certainly be helpful in determining the clinical effects of patellar tendon closure. Similarly, it would have been clinically helpful for the patients in these studies to have subjectively assessed the presence or absence of pain along the anterior aspect of the knee postoperatively, especially with potentially provocative activities such as kneeling or stair climbing. As noted in a prospective study by Martin et al.⁴³ in 1996, bone grafting the patellar defect significantly decreases patellofemoral pain compared with leaving the defect unfilled. In addition, a subjective assessment of the cosmetic appearance of the knee would have been interesting, because this type of data likely ties into overall patient satisfaction, an increasingly important entity in the current health care system.

The senior author (B.R.B.) has performed more than 2,200 primary and revision ACLR procedures with BPTB autografts and allografts. Our preference has been to graft the patellar and tibial tubercle defects with bone gathered at the time of tibial and femoral tunnel reaming. The patellar tendon defect is then loosely closed with the knee flexed at approximately 75° to 85° to reduce the likelihood of overconstraining the patella. The paratenon is subsequently closed with Vicryl suture. We have advocated patellar tendon defect closure

and bone defect grafting⁴⁴ so that patients are not kneeling on the patellar defect or focused on the palpable defect in a nonclosed harvest site.

Limitations

The present study has several limitations. Because of the strict inclusionary criteria of including only randomized trials, the sample size is small with only 4 studies comprised of 221 patients. However, all studies included were of the highest possible level of evidence available on this topic. Despite using only Level I and Level II studies, the overall quality of the studies was low, as evidenced by the low MCMS and Jadad scores. Several of the studies omitted details from their methodology, which resulted in lower MCMS and Jadad scores; however, it is possible that those points were lost simply because of omission of details from the text of the manuscripts and not because of the quality of the actual studies. The major limitation is the lack of standardization between the studies with respect to the outcomes and imaging data collected, limiting the analysis to descriptive statistics and making comparisons between studies difficult.

Conclusions

Based on this systematic review of 4 randomized trials, there are no statistically significant or clinically relevant differences in outcomes between patients who have the patellar tendon defect closed and those who have it left open after ACL reconstruction with a BPTB autograft. Further, the data is inconsistent regarding the effect of patellar tendon defect closure on scar formation. The methodology of the included studies limits the interpretation of the data, as evidenced by low MCMS and Jadad scores.

References

1. Dragoo JL, Braun HJ, Durham JL, Chen MR, Harris AH. Incidence and risk factors for injuries to the anterior cruciate ligament in National Collegiate Athletic Association football: Data from the 2004-2005 through 2008-2009 National Collegiate Athletic Association Injury Surveillance System. *Am J Sports Med* 2012;40:990-995.
2. Swenson DM, Collins CL, Best TM, Flanigan DC, Fields SK, Comstock RD. Epidemiology of knee injuries among U.S. high school athletes, 2005/2006-2010/2011. *Med Sci Sports Exerc* 2013;45:462-469.
3. Murawski CD, van Eck CF, Irrgang JJ, Tashman S, Fu FH. Operative treatment of primary anterior cruciate ligament rupture in adults. *J Bone Joint Surg Am* 2014;96:685-694.
4. Reinhardt KR, Hetsroni I, Marx RG. Graft selection for anterior cruciate ligament reconstruction: A level I systematic review comparing failure rates and functional outcomes. *Orthop Clin North Am* 2010;41:249-262.
5. Erickson BJ, Harris JD, Fillingham YA, et al. Anterior cruciate ligament reconstruction practice patterns by NFL and NCAA football team physicians. *Arthroscopy* 2014;30:731-738.
6. Nedeff DD, Bach BR. Arthroscopic anterior cruciate ligament reconstruction using patellar tendon autografts. *Orthopedics* 2002;25:343-357. quiz 358-359.
7. Bach BR, Tradonsky S, Bojchuk J, Levy ME, Bush-Joseph CA, Khan NH. Arthroscopically assisted anterior cruciate ligament reconstruction using patellar tendon autograft. Five- to nine-year follow-up evaluation. *Am J Sports Med* 1998;26:20-29.
8. Erickson BJ, Harris JD, Cvetanovich GL, et al. Performance and Return-to-sport after anterior cruciate ligament reconstruction in male major league soccer players. *OJSM* 2013;1:2325967113497189.
9. Namdari S, Scott K, Milby A, Baldwin K, Lee GC. Athletic performance after ACL reconstruction in the Women's National Basketball Association. *Phys Sportsmed* 2011;39:36-41.
10. Frank RM, McGill KC, Cole BJ, et al. An institution-specific analysis of ACL reconstruction failure. *J Knee Surg* 2012;25:143-149.
11. Kraeutler MJ, Bravman JT, McCarty EC. Bone-patellar tendon-bone autograft versus allograft in outcomes of anterior cruciate ligament reconstruction: A meta-analysis of 5182 patients. *Am J Sports Med* 2013;41:2439-2448.
12. Barber FA, Cowden CH, Sanders EJ. Revision rates after anterior cruciate ligament reconstruction using bone-patellar tendon-bone allograft or autograft in a population 25 years old and younger. *Arthroscopy* 2014;30:483-491.
13. Andernord D, Björnsson H, Petzold M, et al. Surgical predictors of early revision surgery after anterior cruciate ligament reconstruction: Results from the Swedish National Knee Ligament Register on 13,102 patients. *Am J Sports Med* 2014;42:1574-1582.
14. Heard WMR, Chahal J, Bach BR. Recognizing and managing complications in ACL reconstruction. *Sports Med Arthrosc* 2013;21:106-112.
15. Busam ML, Provencher MT, Bach BR. Complications of anterior cruciate ligament reconstruction with bone-patellar tendon-bone constructs: Care and prevention. *Am J Sports Med* 2008;36:379-394.
16. Carreira DA, Fox JA, Freedman KB, Bach BR. Displaced nonunion patellar fracture following use of a patellar tendon autograft for ACL reconstruction: Case report. *J Knee Surg* 2005;18:131-134.
17. Kohn D, Sander-Beuermann A. Donor-site morbidity after harvest of a bone-tendon-bone patellar tendon autograft. *Knee Surg Sports Traumatol Arthrosc* 1994;2:219-223.
18. Lee GH, McCulloch P, Cole BJ, Bush-Joseph CA, Bach BR. The incidence of acute patellar tendon harvest complications for anterior cruciate ligament reconstruction. *Arthroscopy* 2008;24:162-166.
19. Liberati A, Altman DG, Tetzlaff J, et al. The PRISMA statement for reporting systematic reviews and meta-analyses of studies that evaluate health care interventions: Explanation and elaboration. *J Clin Epidemiol* 2009;62:e1-e34.
20. University of York Centre for Reviews and Dissemination. PROSPERO— International prospective register of systematic reviews. 2013. Available at: <http://www.crd.york.ac.uk/>

- ac.uk/PROSPERO/. Updated November 28, 2013. Accessed August 17, 2013.
21. Obremskey WT, Pappas N, Attallah-Wasif E, Tornetta P, Bhandari M. Level of evidence in orthopaedic journals. *J Bone Joint Surg Am* 2005;87:2632-2638.
 22. Cowan J, Lozano-Calderon S, Ring D. Quality of prospective controlled randomized trials. Analysis of trials of treatment for lateral epicondylitis as an example. *J Bone Joint Surg Am* 2007;89:1693-1699.
 23. Moher D, Jadad AR, Tugwell P. Assessing the quality of randomized controlled trials. Current issues and future directions. *Int J Technol Assess Health Care* 1996;12:195-208.
 24. Brandsson S, Faxén E, Eriksson BI, et al. Closing patellar tendon defects after anterior cruciate ligament reconstruction: Absence of any benefit. *Knee Surg Sports Traumatol Arthrosc* 1998;6:82-87.
 25. Adriani E, Mariani PP, Maresca G, Santori N. Healing of the patellar tendon after harvesting of its mid-third for anterior cruciate ligament reconstruction and evolution of the unclosed donor site defect. *Knee Surg Sports Traumatol Arthrosc* 1995;3:138-143.
 26. Cerullo G, Puddu G, Gianni E, Damiani A, Pigozzi F. Anterior cruciate ligament patellar tendon reconstruction: It is probably better to leave the tendon defect open! *Knee Surg Sports Traumatol Arthrosc* 1995;3:14-17.
 27. Tjoumakaris FP, Herz-Brown AL, Bowers AL, Legath-Bowers A, Sennett BJ, Bernstein J. Complications in brief: Anterior cruciate ligament reconstruction. *Clin Orthop Relat Res* 2012;470:630-636.
 28. Camillieri G, Di Sanzo V, Ferretti M, Calderaro C, Calvisi V. Patellar tendon ossification after anterior cruciate ligament reconstruction using bone-patellar tendon-bone autograft. *BMC Musculoskelet Disord* 2013;14:164.
 29. Shino K, Nakagawa S, Inoue M, Horibe S, Yoneda M. Deterioration of patellofemoral articular surfaces after anterior cruciate ligament reconstruction. *Am J Sports Med* 1993;21:206-211.
 30. Rosenberg TD, Franklin JL, Baldwin GN, Nelson KA. Extensor mechanism function after patellar tendon graft harvest for anterior cruciate ligament reconstruction. *Am J Sports Med* 1992;20:519-525. Discussion 525-526.
 31. McCarroll JR. Fracture of the patella during a golf swing following reconstruction of the anterior cruciate ligament. A case report. *Am J Sports Med* 1983;11:26-27.
 32. Chouteau J, Laptoiu D, Lerat J-L, Moyon B. [Patellar fracture after anterior cruciate ligament reconstruction using a bone patellar tendon bone transplant: a comparative study of two harvesting techniques]. *Rev Chir Orthop Reparatrice Appar Mot* 2008;94:561-565 [in French].
 33. Milankov M, Kecojević V, Ninković S, Gajdobranski D. [Patellar fracture after reconstruction of the anterior cruciate ligament—case report]. *Med Pregl* 2003;56:574-577 [in Serbian].
 34. Piva SR, Childs JD, Klucinec BM, Irrgang JJ, Almeida GJM, Fitzgerald GK. Patella fracture during rehabilitation after bone-patellar tendon-bone anterior cruciate ligament reconstruction: 2 case reports. *J Orthop Sports Phys Ther* 2009;39:278-286.
 35. Stein T, Mehling AP, Welsch F, von Eisenhart-Rothe R, Jäger A. Long-term outcome after arthroscopic meniscal repair versus arthroscopic partial meniscectomy for traumatic meniscal tears. *Am J Sports Med* 2010;38:1542-1548.
 36. Sobieraj MC, Egol AJ, Kummer FJ, Strauss EJ. Mechanical effects of defect closure following BPTB graft harvest for ACL reconstruction. *Int J Sports Med* 2014;35:438-442.
 37. Eilerman M, Thomas J, Marsalka D. The effect of harvesting the central one-third of the patellar tendon on patellofemoral contact pressure. *Am J Sports Med* 1992;20:738-741.
 38. Nixon RG, SeGall GK, Sax SL, Cain TE, Tullos HS. Reconstitution of the patellar tendon donor site after graft harvest. *Clin Orthop Relat Res* 1995;317:162-171.
 39. Coupens SD, Yates CK, Sheldon C, Ward C. Magnetic resonance imaging evaluation of the patellar tendon after use of its central one-third for anterior cruciate ligament reconstruction. *Am J Sports Med* 1992;20:332-335.
 40. Shaffer BS, Tibone JE. Patellar tendon length change after anterior cruciate ligament reconstruction using the mid-third patellar tendon. *Am J Sports Med* 1993;21:449-454.
 41. Dandy DJ, Edwards DJ. Problems in regaining full extension of the knee after anterior cruciate ligament reconstruction: Does arthrofibrosis exist? *Knee Surg Sports Traumatol Arthrosc* 1994;2:76-79.
 42. Tria AJ, Alicea JA, Cody RP. Patella baja in anterior cruciate ligament reconstruction of the knee. *Clin Orthop Relat Res* 1994;299:229-234.
 43. Martin RP, Galloway MT, Daigneault JP. Patellofemoral pain following ACL reconstruction: Bone grafting the patellar defect. *Orthop Trans* 1996;20:9.
 44. Ferrari JD, Bach BR. Bone graft procurement for patellar defect grafting in anterior cruciate ligament reconstruction. *Arthroscopy* 1998;14:543-545.