

# Complex Cartilage Cases in the Athletic Patient: Advances in Malalignment, Instability, Articular Defects, and Meniscal Insufficiency

DOI: 10.3810/psm.2013.11.2035

Rachel M. Frank, MD<sup>1</sup>  
Brian J. Cole, MD, MBA<sup>1</sup>

<sup>1</sup>Department of Orthopaedic Surgery,  
Rush University Medical Center,  
Chicago, IL

**Abstract:** For sports medicine specialists, patients presenting with multiple coexisting knee pathologies can be some of the most difficult to treat patients, especially those with cartilage pathology. In particular, articular cartilage lesions are often incidental findings, and the decision to treat patients must be based on the lesions' confirmed contribution to patient symptomatology. The combination of malalignment, ligamentous instability, and chondral/meniscal damage in patients is challenging to treat because of the difficulty in determining both the relative contribution of each of the pathologies to patient clinical condition and the timing of performing specific corrective procedures. Corrective operations performed in isolation to treat each of the pathologies have historically produced reasonable results in patients; however, combined procedures for treatment of combined pathologies may prove essential for the success of any single procedure. This review describes the clinical evaluation of patients with multiple coexisting knee pathologies and highlights current evidence-based treatment strategies for the management of these combined disorders.

**Keywords:** cartilage; meniscus; allograft; knee

## Introduction

Knee pain in the young athletic patient population can be a challenging presentation to workup and treat because these patients often present with multiple complaints at the index clinic visit that may all be related to a single underlying diagnosis or, more commonly, to a variety of etiologies. Examples of common coexisting knee pathologies in young and active patients include meniscal deficiency, malalignment, chondral defect, and ligamentous instability. One of the main challenges in young and active patients is determining which of the multiple coexisting pathologies need to be treated and which pathologies can be left alone. For example, some articular chondral defects in patients may be incidental findings on either advanced imaging studies or arthroscopy; deciding to treat disorders must be based on the confirmed contribution of each finding to patient symptomatology.

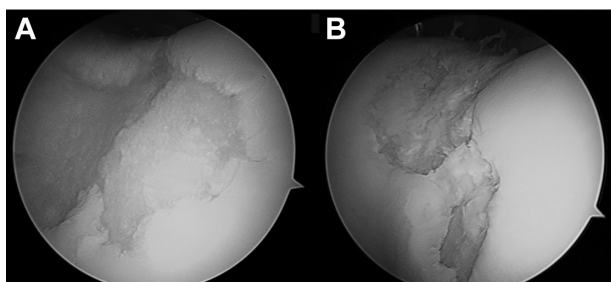
The combination of multiple knee pathologies presents multiple challenges for both patients and sports medicine specialists.<sup>1</sup> First, clinicians must establish the lesion or lesions contributing to the presenting symptoms. Next, clinicians determine which patient pathologies should be surgically addressed. If > 2 pathologies require treatment, surgeons consider either staged or combined procedures; if combined, the order of each procedure should be specified. Corrective procedures for each of the pathologies performed in isolation have historically produced adequate results in patients; however, combined procedures to treat multiple coexisting pathologies may prove essential for the success of any single procedure in patients.<sup>1,2</sup> Although

Correspondence: Rachel M. Frank, MD,  
Department of Orthopaedic Surgery,  
Rush University Medical Center,  
1611 West Harrison St, Suite 300,  
Chicago, IL 60612.  
Tel: 312-243-4244  
Fax: 312-942-1517  
E-mail: rmfrank3@gmail.com

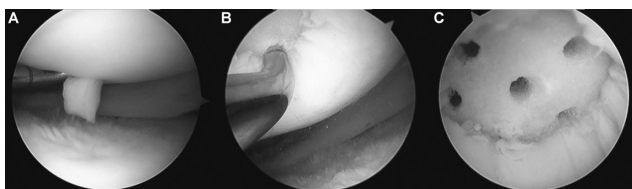
the literature provides some foundation for understanding patients with complex knee pathologies and the challenging decision-making process, no consensus has been reached within the sports medicine community regarding the optimal treatment options for these patients. Consideration of both patient-specific (ie, age, activity level, etc) and disease-specific factors are necessary for surgical decision-making. Additionally, patient expectations should be discussed before any surgical intervention, especially in situations of revision surgery and salvage procedures.

For appropriately indicated patients with multiple knee problems, a variety of surgical treatments are available and often performed in combination. The majority of these procedures can be performed arthroscopically or through arthroscopic-assisted minimally-invasive techniques. Meniscal pathology can be treated arthroscopically with debridement, direct repair, or meniscus allograft transplantation (MAT). Ligamentous patient pathologies, including acute and/or chronic anterior cruciate ligament (ACL) and posterior cruciate ligament insufficiency, can be treated with reconstruction. Medial and/or lateral collateral ligament and posterolateral corner injuries can be treated with direct repair or reconstruction, depending on the specific injury. Focal articular cartilage defects in patients (Figure 1) can be treated with multiple procedures, including debridement, microfracture (Figure 2), autologous chondrocyte implantation (ACI), and osteochondral autograft/allograft transplantation

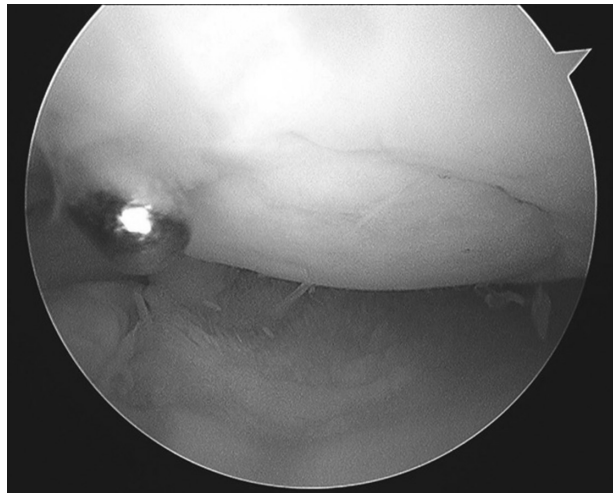
**Figure 1.** Intraoperative photos **A**) and **B**) demonstrate a full-thickness cartilage defect of the femoral trochlea.



**Figure 2.** Intraoperative photographs demonstrate **A**) a full-thickness chondral defect of the lateral femoral condyle. **B**) The use of a microfracture awl to penetrate the subchondral bone approximately 3 to 4 mm. **C**) Marrow elements beginning to flow out of the microfracture holes and into the defect with the goal of containment by vertical walls.



**Figure 3.** Intraoperative photograph showing successful osteochondral allograft transplantation of a 2 × 2 cm donor plug to the lateral femoral condyle.



(Figure 3). Lastly, medial compartment chondral damage with varus malalignment can be treated with a high tibial osteotomy (HTO) that unloads the diseased medial compartment, whereas lateral compartment disease with valgus malalignment can be treated with a distal femoral osteotomy (DFO) that unloads the lateral compartment. Recently, HTO was described in multiple studies as being useful in correcting concomitant malalignment in patients undergoing cartilage and/or meniscus surgery in an attempt to unload the diseased compartment.<sup>1-4</sup>

Each of the previously mentioned procedures is relatively straightforward to perform in isolation for experienced surgeons. Although combined procedures are technically considered to be more demanding upon surgeons, performing them can be successfully accomplished with appropriate preoperative planning. Whether performed in isolation or concomitantly, the main challenge of these procedures is proper patient selection. Appropriate indications for surgery are essential when deciding how to treat patients, and clinicians must develop an appreciation for differentiating between symptomatic and incidental lesions.

## Pathophysiology

To properly evaluate and treat patients with multiple coexisting knee problems, it is critical to understand each of the underlying pathologies individually and to determine the effect each one has on the otherwise healthy structures within the knee. For example, patients who present with multiple coexisting knee pathologies often have underlying meniscal deficiency. Although meniscal deficiency may be the direct result of a traumatic injury, meniscal deficiency is often attributed to a previous partial or subtotal meniscectomy in patients with complex knee problems.

Meniscectomy is one of the most common procedures performed in orthopedic surgery.<sup>5</sup> The operation is safe, minimally invasive, and typically produces satisfactory outcomes in the majority of patients, especially in patients who want a quick return to activity. Nevertheless, removal of even part of the meniscus can be problematic for patients. Subtotal meniscectomy has been shown to decrease joint contact area<sup>6</sup> and increase peak stress within the joint, which together place more demand on the articular cartilage.<sup>6</sup> Following subtotal or total meniscectomy, there is a 14-times increased relative risk of patients developing unicompartmental arthritis.<sup>7-9</sup> Furthermore, multiple studies have shown worse outcomes after meniscectomy in patients with risk factors<sup>10,11</sup> such as young age, chondral damage at time of meniscectomy, ligamentous instability,<sup>12-14</sup> or tibiofemoral malalignment. Moreover, meniscal repair and transplantation have less favorable patient outcomes when performed on patients with untreated concomitant instability, malalignment, or articular cartilage disease.<sup>1,4,15-17</sup>

Articular cartilage disease occurs in patients for a variety of reasons, including mechanical overload, developmental defects, genetic failures, and traumatic impact. Similar to a meniscus injury, knees are more likely to develop degenerative joint disease after the articular cartilage is damaged. Full-thickness articular chondral injuries can be very problematic for patients and cause swelling in the knee, pain at night and at rest, and severe activity-related pain.<sup>18,19</sup> Further complicating articular cartilage disease is the potential for underlying subchondral bone pathology to alter treatment strategies when present in patients.

Knee malalignment has become an increasingly recognized risk factor for the development of osteoarthritis in patients.<sup>20</sup> The mechanical axis of the leg (center of femoral head to intercondylar eminence to center of ankle) is different from the weight-bearing axis of the leg (center of femoral head to center of ankle). The anatomic axis of the femur differs from the mechanical axis of the femur, causing the normal anatomic weight-bearing knee axis to be within approximately 5° to 7° of valgus, with approximately 60% of compressive forces transmitted through the medial compartment. Varus malalignment shifts the center of the joint lateral to the mechanical axis, leading to medial tibial cartilage volume and thickness loss, in addition to increasing the tibial and femoral denuded bone.<sup>21</sup> Alternatively, valgus malalignment shifts the center of the knee medial to the mechanical axis, leading to increased lateral-sided forces that are unbalanced. Osteotomy procedures (HTO, DFO) alter the mechanical axis by shifting the load away from the damaged compartment. The pathophysiologic principle of these bony procedures is to

change the weight-bearing axis of the joint to avoid rapid and irreversible progression of unicompartmental arthritis.<sup>22-24</sup>

## Patient Presentation

A patient presenting with combined knee pathologies will not have a straightforward history compared with the typical sports medicine patient who presents with a defined traumatic twisting, pivoting, or instability event. Patients with multiple knee complaints can be very difficult to evaluate, especially at an initial office visit. These patients have often experienced symptoms for such long periods that they are unable to recall specific injuries. Instead, patients may describe vague or nonspecific knee-related complaints. Patients with multiple knee problems have often experienced multiple injuries and/or surgical procedures. At time of presentation, patients are often unsure if their current symptoms are similar to original symptoms, if they are related to a new injury, or if they are potentially related to a previous surgery.

Patients with such complex combined knee pathologies will typically complain of unicompartmental knee pain, although some may have involvement of 2 or all 3 compartments. Some symptoms may be chronic, as detrimental effects from any single pathology on other structures within the knee often materialize over time, whereas other symptoms may be more acute. Determining whether the symptoms are acute or chronic is at the core of the complexity of treating patients with multiple knee pathologies. Additionally, it can be difficult to understand which pathology is responsible for the presenting symptoms at any given time, as many of these patients present after undergoing prior unsuccessful surgical interventions for pathologies that were actually asymptomatic. Patient complaints such as intermittent pain, swelling, and rest/night pain are commonly seen in articular cartilage injuries and malalignment. Mechanical symptoms, such as clicking, locking, and catching, are more common in meniscal pathology. The sensation of instability is most often seen with ligamentous injuries, whereas joint line pain may be experienced in any of the previously described situations.

## Physical Examination

Patients presenting with knee pain should undergo a standard physical examination of both lower extremities. All patients should undergo leg-length and gait assessment, because these findings may have significant implications for surgical planning. Examinations should always include a visual inspection, including evaluation of the overall alignment and presence of genu valgum or genu varum. Any prior surgical scars should be discussed with patients and documented.

After the visual inspection, standard physical examinations will also include palpation, range of motion testing, strength assessment, vascular status assessment, flexibility assessment, evaluation of the patella, and provocative testing, including stability testing. When palpating, clinicians should evaluate patients for specific joint-line tenderness and crepitation. Range of motion testing in the hips and knees should be performed, which should be relatively preserved in the young and active patient population. However, patients who have undergone previous surgeries may have residual stiffness, which should be documented before any procedures begin. Strength should be assessed in both legs, with a specific focus on quadriceps, hamstring, and core strength; side-to-side differences should be noted. Patients will benefit occasionally from presurgical physical therapy in an effort to augment any substantial deficits. A distal neurovascular examination of patients should also be performed, including assessment for excessive lower extremity edema and palpation of the dorsalis pedis and posterior tibialis pulses. Patellar examination, complete with assessment of patellar tilt, apprehension, and crepitus should be performed. Patients should be assessed for presence of the J sign, which is indicative of lateral patellar tracking (as knee is extended from 90° of flexion, the patella will deviate laterally at full extension). Both the static and dynamic Q angle should be assessed for each knee, however it should be noted that this measurement can be poorly reproducible.<sup>25</sup>

Lastly, patients should undergo special tests including provocative and stability testing maneuvers. Tests for ACL integrity include the pivot shift, Lachman, and anterior drawer tests, whereas the posterior cruciate ligament can be assessed with the posterior drawer and reverse pivot shift tests. The collateral ligaments can be tested with varus and valgus stress tests, both at full extension and 30° of flexion (to better isolate the collaterals). The McMurray's test can be used to evaluate patients for meniscal pathology. Anteromedial rotary instability should be assessed with the knee at 90° of flexion with the patient supine. In contrast, posterolateral rotary instability should be assessed with the patient prone while applying external rotation to both knees at 30° and 90° of flexion for side-to-side comparison (dial test).

Patients with a unilateral joint effusion are likely to have cartilage pathology, although this physical examination finding is not specific. Patients with tenderness to palpation posterior to the midline of joint line are more likely to have meniscal pathology, whereas patients with tenderness anterior to the midline of the joint may have patellofemoral, chondral, or meniscal (displaced tears) pathologies. Nevertheless, with

combined pathologies, symptoms can be difficult to differentiate. Most patients will have preserved strength and range of motion, unless their degenerative disease has progressed to cause weakness and/or stiffness. Multiple prior surgical procedures can also lead to residual stiffness and/or weakness in patients with complex knee pathologies.

## Diagnostic Studies

After a complete history and thorough physical examination, all patients with knee pain believed to be related to multiple coexisting knee pathologies should undergo further evaluation with imaging studies. Radiographs are usually the first study patients undergo and several other films should be taken in addition to a standard knee series, including anterior-posterior (AP), lateral, and merchant views of the knee. Other specialized views, including weight-bearing AP in extension; bilateral weight-bearing posterior-anterior at 45° of flexion; and weight-bearing, double stance, long-leg mechanical axis views are appropriate in the workup of patients with potential meniscal, chondral, and/or malalignment-related pathologies. Additionally, sizing radiographs with appropriate magnification markers for meniscus transplantation and osteochondral allograft transplantation candidates may be necessary.

Advanced imaging, such as magnetic resonance imaging (MRI) or computed tomography, is also useful in evaluating these patients. It is important to remember that not every "abnormality" observed on advanced imaging studies is pathologic; some patients may have incidental findings that are completely asymptomatic. Therefore, it is crucial to evaluate each advanced imaging study and correlate the findings to the patient's specific complaints and symptoms. An extremely useful tool in examining soft tissue integrity is an MRI scan; specific sequences can be used to identify articular cartilage, menisci, ligamentous structures, and other intra-articular structures and pathology in patients. Furthermore, bone marrow edema is best viewed with MRI and can be indicative of unicompartamental overload in patients. Computed tomography scans are useful as adjunctive imaging modalities, especially in patients with previous surgeries (ie, bone tunnels in previous ACL reconstruction). Other imaging modalities, including bone scans, may provide information regarding degenerative activity in the condyles, plateaus, and patella.

## Treatment Options

### Nonoperative

The treatment options for young patients with multiple coexisting knee pathologies vary. Symptomatic control in



patients is the common treatment and has been attempted with activity modification and pain medications. Surgical intervention is frequently required to address  $\geq 1$  of the underlying pathologies of patients; however, nonoperative treatment options can be attempted for temporary symptom relief. Nonoperative options for patients vary depending on the specific pathology, but can include physical therapy, nonsteroidal anti-inflammatory medications, intra-articular corticosteroid injections, and platelet-rich plasma therapy. Although nonoperative options are usually effective at symptomatic relief, these modalities typically only provide temporary relief for patients with complex knee problems.

## Operative

Particular attention must be given to surgical indications for the operative management of patients with combined knee pathologies. Treatment should focus only on the pathology that is causing patient symptoms. This is especially important during diagnostic arthroscopy, during which a previously unknown cartilage injury may be detected, but may simply be an incidental finding that is not responsible for any clinical symptoms.

Whether multiple procedures are performed in a staged or combined fashion, they will only be effective in patients with appropriate indications for surgery. Young and active patients are ideal candidates for non-arthroplasty procedures, whereas older, less active patients may benefit from arthroplasty-based options. Furthermore, only patients who are able to tolerate and comply with protocols for a potentially long and tedious rehabilitation should be considered for surgery. Addressing patient expectations is crucial because the patient must understand that they will not have a normal knee and that activity restrictions after several of these procedures may exist. Relative contraindications for these procedures are listed in Table 1.

Surgical approaches for patients with combined knee pathologies depend on the specific pathologies. Treatments may be performed in 1 operative setting, may be staged, or may consist of multiple combinations of individual procedures (Table 2). As previously described, corrective procedures for each of these pathologies performed in

**Table 2.** Potential Surgical Options for Combined Knee Pathologies

Pathology	Surgical Options
• Malalignment	• Osteotomy
• Ligamentous instability	• Ligamentous repair
	• Ligamentous reconstruction
• Meniscal deficiency	• Meniscus debridement
	• Meniscus repair
	• MAT
• Articular cartilage defect	• Articular cartilage debridement
	• Microfracture
	• ACI
	• OATS
	• Osteochondral allograft transplantation

**Abbreviations:** ACI, autologous chondrocyte implantation; MAT, meniscus allograft transplantation; OATS, osteochondral autograft transfer.

isolation have historically produced adequate results in patients, whereas combined procedures may improve the success of any single procedure.<sup>1,2</sup> Potential patient advantages to undergoing staged procedures include a shorter operative time and potentially easier recovery periods. Conversely, staged procedures require multiple operations, which also include anesthesia-associated risks and the need for multiple separate recoveries. A single surgery with multiple concomitant procedures is advantageous for patients because it is 1 procedure and 1 course of anesthesia; however, disadvantages include increased surgical time and the potential for more patient complications. The following treatment section focuses on less commonly encountered clinically complex patient presentations.

## Treatment Options for Uncommon Pathologies

### Malalignment With Chondral or Meniscal Defect

High tibial osteotomy<sup>26,27</sup> procedures treat varus malalignment by decreasing the biomechanical load in the medial knee compartment of patients. Similarly, DFO procedures treat valgus malalignment by decreasing the biomechanical load in the lateral compartment of patients. Osteotomy procedures are preferable in the young patient population when properly indicated, especially when compared with less desirable alternative options such as arthroplasty. Partial or total knee arthroplasty (TKA) is not ideal in young and active patients because running and impact activities are not recommended after arthroplasty; however, these activities are permitted after HTO. In fact, pending other concomitant knee pathologies and corrective surgeries, there are no major

**Table 1.** Relative Contraindications for Surgery

- Generalized (tricompartamental) osteoarthritis
- Inability to comply with rehabilitation
- Unrealistic patient expectations
- Obesity with BMI > 40

**Abbreviation:** BMI, body mass index.

activity restrictions on patients after they undergo HTO. Additionally, HTO procedures use newer techniques and instrumentation, such as locking plates with variable screw angles that have improved fixation, and have good to excellent early postoperative results with high levels of patient satisfaction.<sup>28,29</sup> Furthermore, recent literature suggests that there is no difference in clinical outcomes after TKA in patients with previous HTO.<sup>30–33</sup>

Cartilage restoration procedures performed in isolation in the presence of tibiofemoral malalignment may have worse patient outcomes and higher failure rates because of mechanical overload of the repaired tissue. Alignment correcting procedures, such as HTO, may unload the damaged compartment enough to facilitate patient healing and protect the cartilage and/or meniscal restorative procedure being performed. Similarly, osteotomy procedures are becoming increasingly popular treatments for patients otherwise contraindicated for meniscal and/or chondral reconstructive procedures because of malalignment.<sup>1</sup> Recent studies have shown that patients with uncorrected varus malalignment do not achieve optimal outcomes with cartilage restorative procedures<sup>34,35</sup>; additionally, both biomechanical and clinical studies have shown the benefits of restoring alignment before or concomitant with cartilage restoration procedures.<sup>1,17,24,36–46</sup> Recent biomechanical evidence from Van Thiel et al<sup>23</sup> demonstrated the mechanical benefits of performing HTO with meniscus transplantation.

Osteotomy procedures are not appropriate for every patient, even in cases of significant malalignment. Relative contraindications to HTO include multicompartamental degenerative disease; even mild lateral compartment disease at the time of HTO can be detrimental to the success of the procedure, because the lateral compartment will be forced to sustain substantially higher contact pressures postoperatively. Similarly, patellofemoral compartment disease is a relative contraindication for treating patients with osteotomy procedures; if HTO is the procedure of choice, it may be possible to concomitantly perform a Maquet (anterior) or Fulkerson (anteromedial) tibial tubercle osteotomy to treat the patellofemoral disease. Other relative contraindications to HTO include lateral meniscus deficiency, inflammatory arthritis, and patients unwilling to comply with the prescribed rehabilitation after the procedure.

Although encouraging patient results with HTO have been reported, other authors have reported less than ideal long-term patient outcomes.<sup>47–51</sup> In addition to forcing increased weight-bearing load onto the noninvolved knee compartments, the results observed in patients who underwent HTO progressively worsen over time. In contrast,

medium to long-term arthroplasty results in patients are excellent.<sup>47</sup> Following HTO, Coventry et al<sup>48</sup> reported a 10-year survival rate of 63% in patient knees with 5° of valgus angulation. The authors noted improved results in patients with greater degrees of correction, and significantly worse results in overweight patients. More recently, Efe et al<sup>49</sup> reported the outcomes of 199 patients undergoing closing wedge HTO and described an 84% postoperative survivorship at 9.6 years with good or excellent knee function outcomes in 64% of patients. A second finding of note was that 36 HTOs (18%) underwent by patients were ultimately converted to TKA.<sup>49</sup> Specific patient complications<sup>49–51</sup> after HTO include loss of correction, lateral cortex fracture, thromboembolic disease, delayed union, nonunion, painful hardware, infection, and neurovascular damage.

## Malalignment With Ligamentous Instability

Underlying malalignment as a cause for failed ACL reconstruction has been well studied in the literature.<sup>52–54</sup> Patient malalignment and medial compartment overload should be considered a factor that leads to failure of the initial ACL reconstruction. Malalignment of the tibia, and thus an abnormal mechanical axis of the leg, may place excessive force across a newly reconstructed ACL graft, leading to attritional failure in patients; correcting the weight-bearing axis with HTO before or during the ACL revision may be an appropriate method to prevent failure in patients. In patients with ACL deficiency, it may also be beneficial to decrease the tibial slope by placing the osteotomy plate more posterior along the tibia.<sup>55</sup>

## Meniscal Defect With Femoral Condylar Cartilage Defect

The biomechanical and functional relationship between the meniscus and femoral articular cartilage is complex and damage to one of these structures is often associated with damage to the other. Unicompartamental arthritis of the involved compartment is a known outcome in  $\leq 70\%$  of patients following near-total meniscectomy and carries a relative risk  $\leq 14$ -times higher for patients than matched controls.<sup>6–9</sup> Even partial meniscectomy can significantly increase tibiofemoral contact pressures, particularly in the lateral compartment.<sup>56</sup> Treatment options for isolated meniscal pathology are outlined in Table 2. Meniscus allograft transplantation is indicated for patients who are symptomatic in the ipsilateral compartment after previous subtotal meniscectomy. A variety of transplantation techniques have been

described as treatments for patients, including the bridge-in-slot technique, bone-plug technique, dovetail technique, and free-end technique.<sup>57,58</sup>

With regard to focal chondral defects, several surgical techniques for articular cartilage disease are available to patients (Table 2). The most important treatment consideration is whether or not the lesion is responsible for the symptoms being exhibited in patients. Incidental findings in patients, whether found on MRI or diagnostic arthroscopy, should not be surgically addressed. For lesions deemed appropriate for surgical intervention, treatment options vary and the appropriate choice must be specific to the patient and the defect. Arthroscopic debridement is usually the first-line arthroscopic approach for small articular cartilage defects in patients. This technique is simply palliative in nature, and patients should be counseled that their symptoms may recur over time. Reparative procedures include ACI and microfracture, which is a marrow-stimulating technique ideal for small (< 2 cm<sup>2</sup>) unipolar lesions. Microfracture is highly dependent on appropriate technical execution, including the creation of vertical walls to contain the resultant mesenchymal stem cell clot that attempts to fill in the full-thickness chondral defect with fibrocartilage. With an appropriately employed surgical technique, highly successful long-term outcomes have been reported in patients, in some cases reaching > 20 years.<sup>59,60</sup> Similar to microfracture, ACI and matrix-induced ACI are reparative procedures with the goal of creating new cartilage to fill the articular defect in patients. This technique is employed in 2 separate stages, with the first stage involving a biopsy of the patient's articular cartilage. After 4 to 6 weeks of processing and exponential growth in the laboratory, the second stage involves implanting the patient's own articular cartilage cells into the defect and securing them with a periosteal flap or collagen membrane. These procedures are best for large condylar lesions (> 4 cm<sup>2</sup>) or patellar lesions without significant bony involvement.

Cartilage reconstructive procedures, including osteochondral autograft transfer (OATS) and osteochondral allograft transplantation, are surgical options for medium to large articular cartilage lesions (2–4 cm<sup>2</sup>). The OATS procedure is usually reserved for patients who have medium-sized lesions that can be adequately filled with 1 or 2 donor site plugs taken from the non-weight-bearing region of the ipsilateral knee and transferred to the damaged area. Reconstructive procedures are preferred in cases of patients with non-contained defects, or defects associated with significant bony loss or subchondral edema in addition to the chondral disease.<sup>4,18,61</sup> Osteochondral allograft transplantation

takes osteoarticular plugs from fresh or prolonged fresh size-matched hemicondyle cadaveric donors and transplants them into the patient defect. Allograft transplantation is preferred in cases of combined procedures because the autograft harvest and subsequent transfer may add further injury to the knee. Allograft transplantation allows surgeons to specifically size-match the donor plug to the patient defect size and also allows for decreased surgical time (no harvest needed). Disadvantages of this procedure include the potential risk, although it is extremely low, of disease transmission and the higher associated cost. Additionally, allograft tissue is not always immediately available; therefore, patients may need to wait to undergo allograft transplantation until a suitable match is found.

Many options exist for patients with articular chondral defects. While each patient must be evaluated on a case-by-case basis, several recommendations for specific cartilage defects and clinical scenarios are outlined in Table 3. In general, patients who have osteochondral lesions with underlying bone marrow edema or lesions that have otherwise failed prior cartilage restoration procedures should undergo osteochondral allograft transplantation. New techniques in articular cartilage repair are currently being investigated, including the transplantation of particulated articular cartilage autograft, as well as the transplantation of particulated articular cartilage from juvenile allograft donors.<sup>62–66</sup> Although the basic science is promising and early clinical outcomes in patients are encouraging, larger clinical studies with longer follow-up periods are necessary before these techniques can be recommended to treat any specific cartilage defect.

## Terrible Triad: Meniscal Deficiency, Chondral Defect, and Malalignment

Perhaps the most challenging clinical situation in the context of articular cartilage surgery is the triad of meniscal deficiency, articular chondral defect, and malalignment.

**Table 3.** Preferred Treatments for Articular Cartilage Defects

Medial or lateral femoral condyle lesion	Microfracture, OATS, or osteochondral allograft transplantation
Prior failed cartilage procedure for medial or lateral femoral condyle lesion	Osteochondral allograft transplantation
Patellofemoral lesions	ACI, MACI ± tibial tubercle osteotomy

**Abbreviations:** ACI, autologous chondrocyte implantation; MACI, matrix-induced autologous chondrocyte implantation; OATS, osteochondral autograft transfer.

Historically, patients who are meniscal-deficient and may benefit substantially from meniscal allograft transplantation have been contraindicated for this procedure if they are known to have a concomitant full-thickness chondral defect on the ipsilateral side.<sup>67</sup> Even if both the meniscal deficiency and chondral defects are addressed concomitantly (single or staged approaches), a subset of patients will continue to have diminished outcomes because of malalignment and the resulting continuous overload of the newly reconstructed compartment. However, encouraging outcomes have been reported recently in a subset of patients undergoing concomitant MAT, cartilage restoration, and realigning osteotomy.<sup>1,2</sup> There are several factors that should be taken into consideration with regard to the surgical technique and the appropriate order of procedures including staged versus concomitant procedures (Table 4). Of utmost importance is patient counseling, including a detailed discussion of expectations and desired postoperative activity level. The majority of patients with these 3 pathologies has undergone multiple previous operations, and must understand that these complex procedures are essentially salvage operations; the ultimate goal is to provide symptom relief and restore function.

## Meniscal Deficiency or Chondral Defect With Ligamentous Deficiency

One challenging and commonly encountered clinical situation involves finding a chondral lesion at the time of surgery in patients who are undergoing planned ligamentous reconstruction. The key to handling these cases is to determine whether a cartilage lesion found at the time of ligament reconstruction (for example a small, isolated, full-thickness medial femoral chondral defect noted arthroscopically during a planned ACL reconstruction) is symptomatic or an incidental finding. In

the acutely ligamentously injured knee, chondral defects are rarely treated with more than simple debridement or microfracture; it is considered appropriate to reconstruct the ligament and observe the newly discovered chondral lesion without any further treatment. It is possible that the patient may be completely pain and symptom free after appropriate rehabilitation for the ligament reconstruction, despite the presence of a known chondral defect. More challenging cases occur when a significant amount of time lapses between ACL injury and reconstruction because both the frequency<sup>68–70</sup> and severity or pain of meniscal and chondral injury<sup>69,71,72</sup> increase when surgical treatment is delayed. In the setting of chronic ACL deficiency and medial meniscus tear in patients, biomechanical evidence indicates that meniscus repair improves AP tibial translation and overall rotatory stability of the joint.<sup>73</sup> Similarly, in chronically ligament-deficient patients with a concomitant chondral lesion, it is more likely that addressing both the ligament and cartilage defect will improve pain and functional outcomes.

Timing is extremely important in this specific patient cohort, and the chronicity of the tear in conjunction with the patient's symptoms will dictate which meniscus and/or cartilage lesions are appropriate for surgical treatment. In the specific case of combined ligamentous reconstruction and MAT, specific attention must be paid to the order and employment of surgical steps. For example, in cases of medial MAT, the tibial bone tunnel should be made as obliquely as possible when entering the lateral aspect of the tibial footprint in order to avoid interfering with the slot for the MAT bone bridge. After the MAT is complete, the ACL graft should then be passed and fixated on the femoral side. Any articular cartilage work (osteochondral allograft transplantation) should be performed by a medial or lateral

**Table 4.** Recommended Steps in Combined Meniscal Deficiency, Chondral Defect, and Malalignment

Medial or Lateral Femoral Condyle Lesion	Patellofemoral Procedures
<ol style="list-style-type: none"> <li>1. Diagnostic knee arthroscopy → confirm need for planned operation</li> <li>2. MAT: <ul style="list-style-type: none"> <li>• Inside-out repair using vertical mattress sutures; sutures are tied in extension</li> </ul> </li> <li>3. Realigning osteotomy: <ul style="list-style-type: none"> <li>• Performed after MAT to protect osteotomy from the abduction/adduction movements required during meniscus transplantation</li> </ul> </li> <li>4. Midline incision followed by medial vastus sparing or lateral parapatellar arthrotomy, followed by fresh osteochondral allograft transplantation <ul style="list-style-type: none"> <li>• Performed last to protect the fresh articular cartilage from the other procedures</li> </ul> </li> </ol>	<ol style="list-style-type: none"> <li>1. Longitudinal midline incision followed by lateral parapatellar arthrotomy</li> <li>2. Tibial tubercle osteotomy is performed first; fixation with 2 cortical screws (4.5 mm)</li> <li>3. If associated MPFL reconstruction is performed, 2 patellar holes (5-mm) drilled to a depth of 20 mm <ul style="list-style-type: none"> <li>• Hamstring allograft is fixed with 2 swivel-lock anchors.</li> <li>• Other end of the graft is passed through a 7-mm hole through the MPFL origin in femur</li> <li>• Fixation is on the femoral side in final step (after ACL)</li> </ul> </li> <li>4. Patella is everted; ACL procedure is performed</li> <li>5. Finally, fixation and tensioning of the MPFL graft on the femoral side is performed</li> </ol>

**Abbreviations:** ACL, autologous chondrocyte implantation; MAT, meniscus allograft transplantation; MPFL, medial patellofemoral ligament.



arthrotomy. Finally, the ACL should undergo fixation on the tibial side.

## Outcomes

Encouraging patient outcomes have been reported after the performance of isolated procedures such as osteotomies for malalignment,<sup>27,48,74–78</sup> ACL reconstruction for ligamentous instability,<sup>12,13,79–81</sup> cartilage restoration for chondral disease,<sup>82–84</sup> and meniscus repair/transplantation for meniscal disease.<sup>15–17,19,85–87</sup> When considering concomitant treatment for combined lesions, the reported patient outcomes are not as consistent. As the number of knee pathologies increase, positive patient outcomes are generally diminished irrespective of the treatment used. Central to the complexity of these clinical challenges is that each of these conditions are essentially interrelated.<sup>61</sup> For example, chondral disease can be caused by malalignment, which leads to excessive stress on articular cartilage and meniscal pathology.

A limited number of patient outcome studies for combined procedures are available, which makes it difficult to draw definitive conclusions about the success of these procedures (Table 5).<sup>1,3,4,46,85,88</sup> The majority of studies reporting on patient outcomes after procedures involving articular cartilage repair are often low-level cohort studies

without control groups or randomization, which causes the results to be difficult to interpret correctly.<sup>89</sup> A recent systematic review by Harris et al<sup>2</sup> analyzed clinical outcomes in patients undergoing combined MAT with cartilage repair or restoration. Out of the 6 studies included in the review, 110 patients underwent MAT and either ACI (n = 73), osteochondral allograft transplantation (n = 20), OATS (n = 17), or microfracture (n = 3). A total of 33% of patients underwent additional concomitant procedures including HTO, DFO, ligament reconstruction, or hardware removal. The authors noted improved patient outcomes in combined procedures compared with isolated surgery in 4 of the 6 studies. Overall, 12% of patients were considered failures and required revision surgery. Interestingly, 85% of these failures were observed to be related to the meniscus procedure compared with the cartilage procedure.<sup>2</sup>

## Summary

The interrelationship between malalignment, meniscus pathology, articular cartilage disease, and instability is complex. Successful operative intervention relies on appropriate patient selection. Determining the etiology of symptoms can be especially difficult in patients with multiple pathologies; however, a concerted effort against treating incidental lesions must be

**Table 5.** Outcomes of Combined Procedures

Author	Procedures	Total Patients	Follow-up	Outcomes
Gomoll et al <sup>1</sup>	MAT, chondral repair, osteotomy	7	24.0 months	<ul style="list-style-type: none"> <li>6 patients returned to unrestricted activities</li> <li>7 patients with significant increases in KOOS, IKDC, Lysholm scales</li> </ul>
Cameron and Saha <sup>84</sup>	MAT ± concomitant procedures	67	31.0 months	<ul style="list-style-type: none"> <li>58 (87%) patients with good to excellent outcomes</li> <li>5 patients with ACL reconstruction; 80% had good to excellent outcomes</li> <li>34 patients with osteotomy; 85% had good to excellent outcomes</li> <li>7 patients with osteotomy and ACL reconstruction; 86% had good to excellent outcomes</li> </ul>
Farr et al <sup>3</sup>	MAT + ACI (16 with additional procedures including TTO, ACLR, and/or HTO)	36 (29 for follow-up)	≥ 2.0 years	<ul style="list-style-type: none"> <li>Significant improvements in surveys, VAS, satisfaction</li> <li>No difference between subgroups</li> <li>4 failures, 2 revision procedures</li> </ul>
Rue et al <sup>4</sup>	MAT + cartilage restoration (52% ACI, 48% osteochondral allograft)	31	3.1 years	<ul style="list-style-type: none"> <li>76% satisfied (80% ACI, 71% osteochondral allograft); statistical improvements in Lysholm and IKDC scales</li> <li>No significant differences between groups</li> </ul>
Bhosale et al <sup>88</sup>	MAT + ACI	8	3.2 years	<ul style="list-style-type: none"> <li>75% improved function and pain relief at 1 year</li> <li>62.5% improved function at 3.2 years</li> </ul>
Verdonk et al <sup>45</sup>	MAT ± HTO	27	10.0 years	<ul style="list-style-type: none"> <li>Patients with concomitant HTO have significantly greater improvements in pain and functional scores</li> <li>10-year survival rates in patients were 83.3% with HTO, 74.2% with isolated MAT</li> </ul>

**Abbreviations:** ACI, autologous chondrocyte implantation; ACL, anterior cruciate ligament; ACLR, anterior cruciate ligament reconstruction; HTO, high tibial osteotomy; IKDC, International Knee Documentation Committee; KOOS, knee injury and osteoarthritis outcome score; MAT, meniscus allograft transplantation; TTO, tibial tubercle osteotomy; VAS, visual analog scale.

employed. Current biomechanical and clinical studies suggest a role for combined surgical procedures (either single or staged) to treat patients with complex pathologies, but further long-term studies are needed to determine if these results stand over time.

## Conflict of Interest Statement

Brian J. Cole, MD, MBA, is a consultant for and receives royalties and research support from Arthrex, Inc.; receives royalties and research support from DJ Orthopedics, LLC and Smith and Nephew; is a consultant for and receives research support from DePuy Companies and Zimmer, Inc.; receives royalties from Elsevier, Lippincott, and WB Saunders; is a consultant for AlloSource, BioMimetic Therapeutics, Inc., and Cardicept Medical, Inc.; receives research support from Regentis Biomaterials Ltd.; and is a speaker for Genzyme Corporation. Rachel M. Frank, MD, discloses no conflicts of interest.

## References

- Gomoll AH, Kang RW, Chen AL, Cole BJ. Triad of cartilage restoration for unicompartmental arthritis treatment in young patients: meniscus allograft transplantation, cartilage repair and osteotomy. *J Knee Surg.* 2009;22(2):137–141.
- Harris JD, Cavo M, Brophy R, Siston R, Flanigan D. Biological knee reconstruction: a systematic review of combined meniscal allograft transplantation and cartilage repair or restoration. *Arthroscopy.* 2011;27(3):409–418.
- Farr J, Rawal A, Marberry KM. Concomitant meniscal allograft transplantation and autologous chondrocyte implantation: minimum 2-year follow-up. *Am J Sports Med.* 2007;35(9):1459–1466.
- Rue JP, Yanke AB, Busam ML, McNickle AG, Cole BJ. Prospective evaluation of concurrent meniscus transplantation and articular cartilage repair: minimum 2-year follow-up. *Am J Sports Med.* 2008;36(9):1770–1778.
- Abrams GD, Frank RM, Gupta AK, Harris JD, McCormick FM, Cole BJ. Trends in meniscus repair and meniscectomy in the United States, 2005–2011. *Am J Sports Med.* 2013;41(10):2333–2339.
- Lee SJ, Aadalen KJ, Malaviya P, et al. Tibiofemoral contact mechanics after serial medial meniscectomies in the human cadaveric knee. *Am J Sports Med.* 2006;34(8):1334–1344.
- McNicholas MJ, Rowley DI, McGurty D, et al. Total meniscectomy in adolescence. A thirty-year follow-up. *J Bone Joint Surg Br.* 2000; 82(2):217–221.
- Roos EM, Ostenberg A, Roos H, Ekdahl C, Lohmander LS. Long-term outcome of meniscectomy: symptoms, function, and performance tests in patients with or without radiographic osteoarthritis compared to matched controls. *Osteoarthritis Cartilage.* 2001;9(4):316–324.
- Roos H, Laurén M, Adalberth T, Roos EM, Jonsson K, Lohmander LS. Knee osteoarthritis after meniscectomy: prevalence of radiographic changes after twenty-one years, compared with matched controls. *Arthritis Rheum.* 1998;41(4):687–693.
- Burks RT, Metcalf MH, Metcalf RW. Fifteen-year follow-up of arthroscopic partial meniscectomy. *Arthroscopy.* 1997;13(6): 673–679.
- Maletius W, Messner K. The effect of partial meniscectomy on the long-term prognosis of knees with localized, severe chondral damage. A twelve- to fifteen-year followup. *Am J Sports Med.* 1996;24(3):258–262.
- Hart AJ, Buscombe J, Malone A, Dowd GS. Assessment of osteoarthritis after reconstruction of the anterior cruciate ligament: a study using single-photon emission computed tomography at ten years. *J Bone Joint Surg Br.* 2005;87(11):1483–1487.
- Ruiz AL, Kelly M, Nutton RW. Arthroscopic ACL reconstruction: a 5–9 year follow-up. *Knee.* 2002;9(3):197–200.
- Shirazi R, Shirazi-Adl A. Analysis of partial meniscectomy and ACL reconstruction in knee joint biomechanics under a combined loading. *Clin Biomech (Bristol, Avon).* 2009;24(9):755–761.
- Kang RW, Lattermann C, Cole BJ. Allograft meniscus transplantation: background, indications, techniques, and outcomes. *J Knee Surg.* 2006;19(3):220–230.
- Noyes FR, Barber-Westin SD. Meniscus transplantation: indications, techniques, clinical outcomes. *Instr Course Lect.* 2005;54:341–353.
- Packer JD, Rodeo SA. Meniscal allograft transplantation. *Clin Sports Med.* 2009;28(2):259–283, viii.
- Cole BJ, Pascual-Garrido C, Grumet RC. Surgical management of articular cartilage defects in the knee. *J Bone Joint Surg Am.* 2009;91(7):1778–1790.
- Cole BJ, Carter TR, Rodeo SA. Allograft meniscal transplantation: background, techniques, and results. *Instr Course Lect.* 2003;52:383–396.
- Tanamas S, Hanna FS, Cicuttini FM, Wluka AE, Berry P, Urquhart DM. Does knee malalignment increase the risk of development and progression of knee osteoarthritis? A systematic review. *Arthritis Rheum.* 2009;61(4):459–467.
- Sharma L, Eckstein F, Song J, et al. Relationship of meniscal damage, meniscal extrusion, malalignment, and joint laxity to subsequent cartilage loss in osteoarthritic knees. *Arthritis Rheum.* 2008;58(6):1716–1726.
- Sharma L, Song J, Felson DT, Cahue S, Shamiyeh E, Dunlop DD. The role of knee alignment in disease progression and functional decline in knee osteoarthritis. *JAMA.* 2001;286(2):188–195.
- Van Thiel G, Frank R, Gupta A, et al. Biomechanical evaluation of a high tibial osteotomy with a meniscal transplant. Presented at the 8th World Congress of the International Cartilage Repair Society; May 23–26, 2009; Miami, Florida.
- Verdonk PC, Demurie A, Almqvist KF, Veys EM, Verbruggen G, Verdonk R. Transplantation of viable meniscal allograft. Survivorship analysis and clinical outcome of one hundred cases. *J Bone Joint Surg Am.* 2005;87(4):715–724.
- Smith TO, Hunt NJ, Donell ST. The reliability and validity of the Q-angle: a systematic review. *Knee Surg Sports Traumatol Arthrosc.* 2008;16(12):1068–1079.
- Anbari A. Proximal tibial and distal femoral osteotomy. In: Cole B, Gomoll A, eds. *Biologic Joint Reconstruction: Alternatives to Arthroplasty.* Thorofare, NJ: SLACK Inc; 2009:203–210.
- Wright JM, Crockett HC, Slawski DP, Madsen MW, Windsor RE. High tibial osteotomy. *J Am Acad Orthop Surg.* 2005;13(4):279–289.
- Schroter S, Mueller J, van Heerwaarden R, Lobenhoffer P, Stockle U, Albrecht D. Return to work and clinical outcome after open wedge HTO. *Knee Surg Sports Traumatol Arthrosc.* 2013;21(1):213–219.
- Brosset T, Pasquier G, Migaud H, Gougeon F. Opening wedge high tibial osteotomy performed without filling the defect but with locking plate fixation (TomoFix) and early weight-bearing: prospective evaluation of bone union, precision and maintenance of correction in 51 cases. *Orthop Traumatol Surg Res.* 2011;97(7):705–711.
- Meding JB, Wing JT, Ritter MA. Does high tibial osteotomy affect the success or survival of a total knee replacement? *Clin Orthop Relat Res.* 2011;469(7):1991–1994.
- Meding JB, Keating EM, Ritter MA, Faris PM. Total knee arthroplasty after high tibial osteotomy. *Clin Orthop Relat Res.* 2000;(375):175–184.
- van Raaij TM, Bakker W, Reijman M, Verhaar JA. The effect of high tibial osteotomy on the results of total knee arthroplasty: a matched case control study. *BMC Musculoskelet Disord.* 2007;8:74.
- van Raaij TM, Reijman M, Furlan AD, Verhaar JA. Total knee arthroplasty after high tibial osteotomy. A systematic review. *BMC Musculoskelet Disord.* 2009;10:88.
- Minas T. The role of cartilage repair techniques, including chondrocyte transplantation, in focal chondral knee damage. *Instr Course Lect.* 1999;48:629–643.
- Minas T. Autologous chondrocyte implantation in the arthritic knee. *Orthopedics.* 2003;26(9):945–947.

36. Van Thiel GS, Frank RM, Gupta A, et al. Biomechanical evaluation of a high tibial osteotomy with a meniscal transplant. *J Knee Surg.* 2011;24(1):45–53.
37. Verma NN, Kolb E, Cole BJ, et al. The effects of medial meniscal transplantation techniques on intra-articular contact pressures. *J Knee Surg.* 2008;21(1):20–26.
38. Gallo RA, Feeley BT. Cartilage defects of the femoral trochlea. *Knee Surg Sports Traumatol Arthrosc.* 2009;17(11):1316–1325.
39. Sterett WI, Steadman JR. Chondral resurfacing and high tibial osteotomy in the varus knee. *Am J Sports Med.* 2004;32(5):1243–1249.
40. Willey M, Wolf BR, Kocaglu B, Amendola A. Complications associated with realignment osteotomy of the knee performed simultaneously with additional reconstructive procedures. *Iowa Orthop J.* 2010;30:55–60.
41. Sterett WI, Steadman JR, Huang MJ, Matheny LM, Briggs KK. Chondral resurfacing and high tibial osteotomy in the varus knee: survivorship analysis. *Am J Sports Med.* 2010;38(7):1420–1424.
42. Garrett JC. Meniscal transplantation. *Am J Knee Surg.* 1996;9(1):32–34.
43. Peters G, Wirth CJ. The current state of meniscal allograft transplantation and replacement. *Knee.* 2003;10(1):19–31.
44. Bonasia DE, Amendola A. Combined medial meniscal transplantation and high tibial osteotomy. *Knee Surg Sports Traumatol Arthrosc.* 2010;18(7):870–873.
45. Noyes FR, Barber-Westin SD, Hewett TE. High tibial osteotomy and ligament reconstruction for varus angulated anterior cruciate ligament-deficient knees. *Am J Sports Med.* 2000;28(3):282–296.
46. Verdonk PC, Verstraete KL, Almqvist KF, et al. Meniscal allograft transplantation: long-term clinical results with radiological and magnetic resonance imaging correlations. *Knee Surg Sports Traumatol Arthrosc.* 2006;14(8):694–706.
47. Morgan MC, Gillespie B, Dedrick D. Survivorship analysis of total knee arthroplasty. Cumulative rates of survival of 9200 total knee arthroplasties. *J Bone Joint Surg Am.* 1992;74(2):308–309.
48. Coventry MB, Ilstrup DM, Wallrichs SL. Proximal tibial osteotomy. A critical long-term study of eighty-seven cases. *J Bone Joint Surg Am.* 1993;75(2):196–201.
49. Efe T, Ahmed G, Heyse TJ, et al. Closing-wedge high tibial osteotomy: survival and risk factor analysis at long-term follow up. *BMC Musculoskelet Disord.* 2011;12:46.
50. Miller BS, Downie B, McDonough EB, Wojtys EM. Complications after medial opening wedge high tibial osteotomy. *Arthroscopy.* 2009;25(6):639–646.
51. Spahn G. Complications in high tibial (medial opening wedge) osteotomy. *Arch Orthop Trauma Surg.* 2004;124(10):649–653.
52. Hohmann E, Bryant A, Reaburn P, Tetsworth K. Does posterior tibial slope influence knee functionality in the anterior cruciate ligament-deficient and anterior cruciate ligament-reconstructed knee? *Arthroscopy.* 2010;26(11):1496–1502.
53. LaFrance RM, Gorczyca JT, Maloney MD. Anterior cruciate ligament reconstruction failure after tibial shaft malunion. *Orthopedics.* 2012;35(2):E267–E271.
54. Savarese E, Bisicchia S, Romeo R, Amendola A. Role of high tibial osteotomy in chronic injuries of posterior cruciate ligament and posterolateral corner. *J Orthop Traumatol.* 2011;12(1):1–17.
55. Giffin JR, Vogrin TM, Zantop T, Woo SL, Harner CD. Effects of increasing tibial slope on the biomechanics of the knee. *Am J Sports Med.* 2004;32(2):376–382.
56. Alford JW, Lewis P, Kang RW, Cole BJ. Rapid progression of chondral disease in the lateral compartment of the knee following meniscectomy. *Arthroscopy.* 2005;21(12):1505–1509.
57. Lee AS, Kang RW, Kroin E, Verma NN, Cole BJ. Allograft meniscus transplantation. *Sports Med Arthrosc.* 2012;20(2):106–114.
58. Brophy RH, Matava MJ. Surgical options for meniscal replacement. *J Am Acad Orthop Surg.* 2012;20(5):265–272.
59. Steadman JR, Miller BS, Karas SG, Schlegel TF, Briggs KK, Hawkins RJ. The microfracture technique in the treatment of full-thickness chondral lesions of the knee in National Football League players. *J Knee Surg.* 2003;16(2):83–86.
60. Steadman JR, Rodkey WG, Briggs KK. Microfracture to treat full-thickness chondral defects: surgical technique, rehabilitation, and outcomes. *J Knee Surg.* 2002;15(3):170–176.
61. Cole BJ, Harner CD. Degenerative arthritis of the knee in active patients: evaluation and management. *J Am Acad Orthop Surg.* 1999;7(6):389–402.
62. Cerrato R. Particulated juvenile articular cartilage allograft transplantation for osteochondral lesions of the talus. *Foot Ankle Clin.* 2013;18(1):79–87.
63. Farr J, Cole BJ, Sherman S, Karas V. Particulated articular cartilage: CAIS and DeNovo NT. *J Knee Surg.* 2012;25(1):23–29.
64. Kruse DL, Ng A, Paden M, Stone PA. Arthroscopic De Novo NT(®) juvenile allograft cartilage implantation in the talus: a case presentation. *J Foot Ankle Surg.* 2012;51(2):218–221.
65. Hatic SO 2nd, Berlet GC. Particulated juvenile articular cartilage graft (DeNovo NT Graft) for treatment of osteochondral lesions of the talus. *Foot Ankle Spec.* 2010;3(6):361–364.
66. Ahmed TA, Hincke MT. Strategies for articular cartilage lesion repair and functional restoration. *Tissue Eng Part B Rev.* 2010;16(3):305–329.
67. Alford W, Cole BJ. The indications and technique for meniscal transplant. *Orthop Clin North Am.* 2005;36(4):469–484.
68. Chhadia AM, Inacio MC, Maletis GB, Csintalan RP, Davis BR, Funahashi TT. Are meniscus and cartilage injuries related to time to anterior cruciate ligament reconstruction? *Am J Sports Med.* 2011;39(9):1894–1899.
69. Slauterbeck JR, Kousa P, Clifton BC, et al. Geographic mapping of meniscus and cartilage lesions associated with anterior cruciate ligament injuries. *J Bone Joint Surg Am.* 2009;91(9):2094–2103.
70. Tayton E, Verma R, Higgins B, Gosal H. A correlation of time with meniscal tears in anterior cruciate ligament deficiency: stratifying the risk of surgical delay. *Knee Surg Sports Traumatol Arthrosc.* 2009;17(1):30–34.
71. Fok AW, Yau WP. Delay in ACL reconstruction is associated with more severe and painful meniscal and chondral injuries. *Knee Surg Sports Traumatol Arthrosc.* 2013;21(4):928–933.
72. Maffulli N, Binfield PM, King JB. Articular cartilage lesions in the symptomatic anterior cruciate ligament-deficient knee. *Arthroscopy.* 2003;19(7):685–690.
73. Ahn JH, Bae TS, Kang KS, Kang SY, Lee SH. Longitudinal tear of the medial meniscus posterior horn in the anterior cruciate ligament-deficient knee significantly influences anterior stability. *Am J Sports Med.* 2011;39(10):2187–2193.
74. Coventry MB. Upper tibial osteotomy for osteoarthritis. *J Bone Joint Surg Am.* 1985;67(7):1136–1140.
75. Gardiner A, Gutiérrez Sevilla GR, Steiner ME, Richmond JC. Osteotomies about the knee for tibiofemoral malalignment in the athletic patient. *Am J Sports Med.* 2010;38(5):1038–1047.
76. Preston CF, Fulkerson EW, Meislin R, Di Cesare PE. Osteotomy about the knee: applications, techniques, and results. *J Knee Surg.* 2005;18(4):258–272.
77. Wolcott M. Osteotomies around the knee for the young athlete with osteoarthritis. *Clin Sports Med.* 2005;24(1):153–161.
78. Wolcott M, Traub S, Efid C. High tibial osteotomies in the young active patient. *Int Orthop.* 2010;34(2):161–166.
79. Asano H, Muneta T, Ikeda H, Yagishita K, Kurihara Y, Sekiya I. Arthroscopic evaluation of the articular cartilage after anterior cruciate ligament reconstruction: a short-term prospective study of 105 patients. *Arthroscopy.* 2004;20(5):474–481.
80. Kessler MA, Behrend H, Henz S, Stutz G, Rukavina A, Kuster MS. Function, osteoarthritis and activity after ACL-rupture: 11 years follow-up results of conservative versus reconstructive treatment. *Knee Surg Sports Traumatol Arthrosc.* 2008;16(5):442–448.
81. Louboutin H, Debarge R, Richou J, et al. Osteoarthritis in patients with anterior cruciate ligament rupture: a review of risk factors. *Knee.* 2009;16(4):239–244.
82. Alford JW, Cole BJ. Cartilage restoration, part 2: techniques, outcomes, and future directions. *Am J Sports Med.* 2005;33(3):443–460.

83. Alford JW, Cole BJ. Cartilage restoration, part 1: basic science, historical perspective, patient evaluation, and treatment options. *Am J Sports Med.* 2005;33(2):295–306.
84. Buckwalter JA, Mankin HJ. Articular cartilage: degeneration and osteoarthritis, repair, regeneration, and transplantation. *Instr Course Lect.* 1998;47:487–504.
85. Cameron JC, Saha S. Meniscal allograft transplantation for unicompartamental arthritis of the knee. *Clin Orthop Relat Res.* 1997; (337):164–171.
86. Hergan D, Thut D, Sherman O, Day MS. Meniscal allograft transplantation. *Arthroscopy.* 2011;27(1):101–112.
87. Noyes FR, Barber-Westin SD, Rankin M. Meniscal transplantation in symptomatic patients < fifty years old. *J Bone Joint Surg Am.* 2004;86-A(7):1392–1404.
88. Bhosale AM, Myint P, Roberts S, et al. Combined autologous chondrocyte implantation and allogenic meniscus transplantation: a biological knee replacement. [*Knee*]. 2007;14(5):361–368.
89. Harris JD, Erickson BJ, Abrams GD, et al. Methodologic quality of knee articular cartilage studies. *Arthroscopy.* 2013;29(7):1243–1252, E1245.

The Physician and Sportsmedicine Downloaded from informahealthcare.com by Jonathan Patience on 04/07/15  
For personal use only.