

# Fixation of Tissue-Engineered Human Neocartilage Constructs with Human Fibrin in a Caprine Model

Paul B. Lewis, MD, MS  
L. Pearce McCarty, III, MD  
Jian Q. Yao, PhD, MBA  
James M. Williams, PhD  
Richard Kang, MD, MS  
Brian J. Cole, MD, MBA

**ABSTRACT:** The primary objective of this study was to determine the retention rate of neocartilage constructs in caprine full-thickness cartilage defects by fibrin sealant alone. Two defects, one each on the trochlea and the medial femoral condyle, were created in the stifle joint in 12 goats. Eight goats (16 defects) were treated with neocartilage constructs and 4 goats (8 defects) with fibrin glue alone. Postoperative activity was protected weight bearing for 6 weeks and then unrestricted for 18 weeks. At 24-week procurement, 4 neocartilage constructs were retained in 8 medial femoral defects and 4 in 8 trochlear defects. In gross comparison, the defects that retained the construct had a mean grade significantly higher than defects treated with fibrin glue alone. The mean histological score of defects with retained constructs was also higher than those treated with fibrin sealant alone. There was no appreciable immunologic reaction to the human neocartilage xenograft or human fibrin sealant.

[*J Knee Surg.* 2009;22:196-204.]

*Drs Lewis and Kang are from the Department of Orthopaedic Surgery, Dr Williams is from the Department of Anatomy and Cell Biology, Dr Cole is from the Department of Orthopedics, Department of Orthopaedic Surgery, and the Department of Anatomy and Cell Biology, Rush University Medical Center, Chicago, Ill; Dr McCarty is from Sports and Orthopaedic Specialists, Minneapolis, Minn; and Dr Yao is from Cartilage and Soft Tissue Biologics R&D, Zimmer Inc, Austin, Tex.*

*Financial support of this study was provided by Zimmer Inc in the form of a research grant, and the neocartilage constructs were supplied by ISTO Technologies Inc.*

*Correspondence: Brian J. Cole, MD, MBA, Rush University Medical Center, 1725 West Harrison Street, Suite 1063, Chicago, IL 60612.*

## INTRODUCTION

Focal injury to articular cartilage in the knees of young, active individuals can produce significant functional impairment, resulting in inability to participate in athletics, loss of employment, and difficulty with activities of daily living. Current cartilage restoration techniques can minimize this morbidity. However, these techniques have some limitations. Marrow stimulation procedures, such as microfracture, produce predominantly type-I collagen repair tissue and are best suited for smaller, well-contained lesions. Osteochondral autografting is limited by donor-site morbidity, and osteochondral allografting is restricted by graft tissue availability. Autologous chondrocyte implantation (ACI) is a technically demanding, 2-stage procedure that results in a heterogeneous repair tissue of hyaline cartilage and fibrocartilage.<sup>3,19</sup>

Development of a hyaline neocartilage construct that could be grafted in a single-stage procedure may hold promise as a markedly improved technique for cartilage restoration. A biomechanically stable, hyaline-like cartilage tissue construct described by Adkisson et al<sup>1</sup> fits these criteria. The significance of this construct is 3-fold. First, it biochemically resembles the native articular cartilage and is notably free of measurable type-I and type-X collagen.<sup>1</sup> Second, the chondrocytes are not dedifferentiated and hence preserve the chondrogenic phenotype.<sup>1</sup> Finally, the self-sustained neocartilage disk contains juvenile chondrocytes that are several orders of magnitude better in biosynthetic activities than adult chondrocytes implanted in ACI, osteochondral autografting, or osteochondral allografting.<sup>1</sup> The potential benefits of this graft are well appreciated, and additional studies of the graft fixation have been conducted.<sup>5,10,27,38</sup>

This study investigated the fixation of human neocartilage grafts in caprine, full-thickness cartilage defects by fibrin sealant (Crosseal Fibrin Sealant; Johnson & Johnson, New Brunswick, NJ). The primary hypothesis of the study was that fibrin sealant would retain the neocartilage xenograft in the cartilage defect. The standard for retention was an outcome of a smooth, intact cartilage repair that maintains the integrity of adjacent cartilage and subchondral bone. The outcomes of defects repaired by neocartilage graft were also compared with the outcomes of defects filled with fibrin sealant alone. In the comparison, it was hypothesized that lesions treated via neocartilage grafts, fixed to the defects with fibrin sealant, would produce outcomes superior in both gross structure and histologic characteristics (ie, predominant tissue, cellularity, degree of degeneration of adjacent cartilage, integrity of subchondral bone) to those lesions treated via the use of fibrin sealant alone.

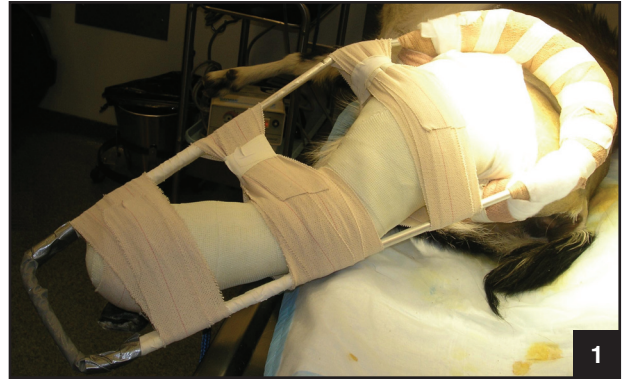### MATERIALS AND METHODS

All study protocols, experimental procedures, and animal care methods were approved by the Institutional Animal Care and Use Committee. All animal care procedures were performed in compliance with the *Guide for the Care and Use of Laboratory Animals*.<sup>20</sup>

Twelve female Spanish goats between the ages of 2 and 4 and weighing 25 to 55 kg were used in this study. The animals were obtained from a United States Department of Agriculture (USDA) licensed vendor (Thomas D. Morris Inc; Reisterstown, Md). Animal health was based on physical examination and blood chemistries by the attending veterinarian on receipt. During the study, animals were housed in an Assessment and Accreditation of Laboratory Animal Care (AAALAC) International-accredited research animal facility.

This study was a randomized animal experiment. The caprine model was chosen for its anatomic similarities to the human knee and for its wide use in previous cartilage repair studies.<sup>5,7,10,21,25,29,38</sup> The size of the stifle joint has been cited as proportionally half that of the human knee.<sup>26</sup> In designing the study, we expected there would be little to no probability that the neocartilage construct would be retained without formal fixation. However, with the use of fibrin glue for fixation, we expected a  $\geq 50\%$  rate of graft retention.<sup>6</sup>

Preoperative prophylactic antibiotics were administered (ceftiofur, 1.1 mg/kg intramuscularly). The animals were then anesthetized (induction: xylazine, 0.03 to 0.05 mg/kg intravenously, ketamine 2 to 3 mg/kg intravenously; maintenance: isoflurane in oxygen). The stifle knee joint was then reached through a lateral parapatellar approach. Analgesia was provided (buprenorphine, 0.003 to 0.007 mg/kg subcutaneously) at the end of the surgery, 4 to 6



**Figure 1.** Custom-made modified Thomas splint. The purpose of the splint was to focus the limb weight bearing to the hip joint and to restrict knee range of motion.

hours postoperatively, and subsequently on an as-needed basis as determined by the attending veterinarian.

Defects were created using a punch biopsy instrument on the medial femoral condyle and the trochlea. Care was taken to avoid penetration of the subchondral plate. The medial femoral condyle defect measured 6 mm in diameter and was located 15 mm distal to the condylar groove junction and aligned with the medial crest of the trochlear groove. The trochlear defect measured 4 mm in diameter and was located in the centralmost portion of the anatomic trochlea. These defect sizes were chosen because of previous evidence that goat defects of  $\leq 3$  mm can spontaneously repair.<sup>5,7,22</sup>

Each subject was then randomized to receive either the neocartilage construct with fibrin glue (8 goats, 16 defects) or fibrin glue alone (4 goats, 8 defects). Adkisson et al<sup>1</sup> previously described the neocartilage construct used in this study. The construct is cartilage tissue grown in vitro and created by culturing disaggregated chondrocytes derived from juvenile human donor articular cartilage.<sup>1</sup> Therefore, the neocartilage constructs were xenografts for the animals.

Following closure of the surgical incision, a custom-made, modified Thomas splint was applied to the limb. The splint allowed weight bearing through the hip only and restricted knee joint range of motion (Figure 1). After 6 weeks of protected weight bearing, the animals progressed to weight bearing as tolerated. Necropsy was allowed at 24 weeks postoperatively.

At the time of necropsy, gross evaluation was performed on fresh specimens by 2 blinded evaluators (J.M.W., B.J.C.). In that evaluation, 4 parameters were categorically described<sup>40</sup>:

- Degree of filling.
- Edge integration.
- Smoothness.
- Color.

Each categorical description was assigned a numeric scale (Table 1). Successfully repaired defects were to have

**TABLE 1**

## SCORING CRITERIA FOR GROSS APPEARANCE

Characteristic	Grading	Score
Degree of filling	Complete	2
	Partial	1
	No filling	0
Edge integration	Full	2
	Partial	1
	None	0
Smoothness	Smooth	2
	Intermediate	1
	Rough	0
Color	Opaque	2
	Translucent	1
	Transparent	0
Total maximum score		8

complete filling (>50%) and a smooth graft-cartilage interface. Grafts not retained were identified by an erythematous, well-shouldered focal chondral lesion.

After gross evaluation, the specimens were fixed in 10% phosphate-buffered formalin containing 5% acetyl pyridinium chloride, decalcified, and embedded in paraffin for histologic evaluation. Histologic staining of 5 µm- to 10 µm-thick sections with hematoxylin-eosin was used for evaluation of the general morphology of the graft and surrounding native tissues. Safranin O/fast green staining was used to evaluate extracellular proteoglycan matrix organization and picrosirius red staining was used to evaluate collagen orientation. Histologic scores were measured through a semiquantitative scale adopted from Frenkel et al<sup>13</sup> and based on 11 different characteristics (Table 2).<sup>32</sup>

The quantitative scale for both gross and histology have been used previously by the authors of this study and in additional studies.<sup>13,32,40</sup> To maintain transparency in the metrics of our evaluation, we have included both scales (Tables 1 and 2). This provides an opportunity to review the reproducibility and significance of the data.

Statistics on mean gross and histologic scores were conducted with two-tailed *t* tests. Independent pairs were used to compare the neocartilage construct with fibrin glue defects with the fibrin glue-only defects. Statistical significance was  $P < .05$ . All mean values are presented with the standard deviation.

## RESULTS

All 12 goats tolerated the surgical procedure well and there were no operative complications. Postoperatively,

1 animal (neocartilage construct with fibrin glue) fell below the standard of life established in the research protocol secondary to rampant laminitis of a nonoperated extremity. This animal was euthanized 9 weeks postoperatively. The implanted graft and fibrin sealant were ruled out as a cause of the laminitis.

Fibrin glue retained the neocartilage graft in 4 of 8 medial femoral condyle defects and in 4 of 8 trochlear defects. All 8 retained grafts demonstrated substantial filling (50% to 80%) and a smooth graft-cartilage interface (Figure 2). The degree of filling was complete in 6 defects and partial in 2 defects. Eight defects had no filling (Table 3). Each of the defects that did not retain the graft were identified by an erythematous, well-shouldered focal chondral lesion (Figure 3). There was no observed evidence of fibrosis, immunologic response, osteophytic growth, or synovitis in any of the joints receiving a neocartilage graft.

By gross evaluation, the mean overall grade of defects that retained the neocartilage graft (6.78, SD = 0.44) was significantly greater than that of fibrin glue only-treated defects (4.50, SD = 1.31,  $P < .01$ ). Medial femoral condyle defects retaining neocartilage grafts demonstrated a mean overall score of 6.75 (SD = 0.50). This mean overall score was significantly higher ( $P = .03$ ) than that of fibrin glue only-treated medial femoral condyle defects (4.25, SD = 1.71). Defects in the trochlea treated with the neocartilage were measured to have a mean overall score of 6.75 (SD = 0.50). When treated with fibrin glue alone, the mean overall score was 4.75 (SD = 0.96). The superior mean overall score of neocartilage-treated defects was significantly higher ( $P = .01$ ) (Table 4). The neocartilage construct with fibrin glue-treated defects were more often determined to be *nearly normal* in gross macroscopic appearance (37.5%) than were the fibrin glue only-treated defects (12.5%), which was a 3-fold difference. With the exception of 1 fibrin glue only-treated trochlear defect, all fibrin glue only-treated defects showed collapse of subchondral bone such that the defect was recessed, compared with the surrounding host articular cartilage.

The mean histologic score of defects that retained the cartilage construct was 24.1 of 28 (SD = 5.4) and higher, but not significantly, than that of the fibrin glue only-treated defects (15.8, SD = 8.7,  $P = .15$ ). Retained neocartilage grafts demonstrated excellent lateral integration into neighboring cartilage and basally with the subchondral bone (Figure 4). The subchondral bone was found to be fully maintained and had no appreciable reactive inflammatory response or change in the distribution of cells in all neocartilage construct with fibrin glue-treated samples (Figure 4). The 8 samples that retained the neocartilage construct with fibrin glue demonstrated deep staining with safranin O, representing proteoglycan content (Figure 5).

TABLE 2

## SCORING CRITERIA FOR HISTOLOGIC CHARACTERISTICS

Characteristic	Grading	Score
Nature of predominant tissue	100% hyaline cartilage, 0% fibrocartilage	4
	>75% hyaline cartilage, <25% fibrocartilage	3
	>50% hyaline cartilage, <50% fibrocartilage	2
	>25% hyaline cartilage, <75% fibrocartilage	1
	>0% hyaline cartilage, <100% fibrocartilage	0
Structural characteristics		
Surface regularity	Smooth and intact	3
	Superficial horizontal lamination	2
	Fissures	1
	Severe disruption, including fibrillation	0
Structural integrity	Normal	2
	Slight disruption, including cysts	1
	Severe disintegration	0
Thickness	100% of normal adjacent cartilage	2
	50%-100% of normal cartilage	1
	0%-50% of normal cartilage	0
Bonding to adjacent cartilage	Bonded at both ends of graft	2
	Bonded at 1 end or partially at both ends	1
	Not bonded	0
Cellular changes of degeneration		
Hypocellularity	Normal cellularity	2
	Slight hypocellularity	1
	Moderate hypocellularity or hypercellularity	0
Chondrocyte clustering	No clusters	2
	<25% of the cells	1
	25%-100% of the cells	0

Samples from the neocartilage construct with fibrin glue-treated group stained with picosirius red also demonstrated good integration but showed evidence of changes in fiber orientation (Figure 6).

### DISCUSSION

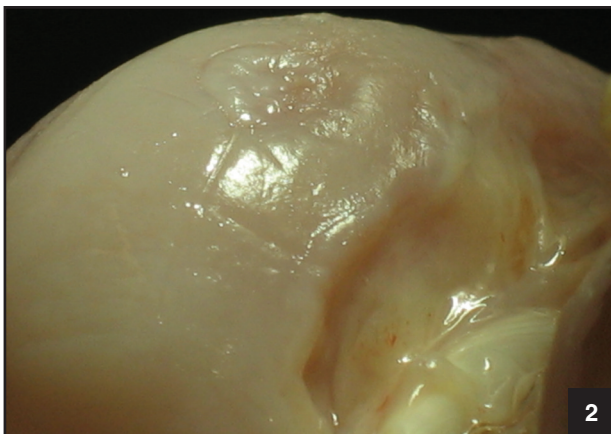
This study evaluated the use of fibrin sealant for the fixation of human neocartilage constructs in surgically created, full-thickness chondral defects in the caprine model. In addition, we examined repair by the neocartilage graft versus repair generated by fibrin sealant alone. Fixation of the neocartilage construct was achieved in 8 (50%) of 16 defects. The gross evaluation was superior for defects retaining the neocartilage graft, compared with defects treated with fibrin sealant alone ( $P < .01$ ). Simi-

larly, the histologic evaluation was better, but not statistically significant, for the defects treated with neocartilage graft versus those treated with fibrin glue alone ( $P = .15$ ). The absolute difference of 8.3 between the mean scores was quantitatively large, compared with the absolute difference of 3.9 between the mean score of neocartilage constructs versus native cartilage. The relative difference between the mean scores of the neocartilage-treated group and fibrin glue only-treated group was not statistically significant because of the large variation of scores for the fibrin glue only-treated defects (SD = 8.7, approximately 60% of the mean value of 13.8). In this respect, the neocartilage constructs were more similar to native cartilage grossly and histologically than they were to fibrin glue only-treated defects. Finally, it is important to note that at 24 weeks postoperatively, there was no gross or histologic

**TABLE 2**

## SCORING CRITERIA FOR HISTOLOGIC CHARACTERISTICS (CONTINUED)

Characteristic	Grading	Score
Degeneration in adjacent cartilage	Normal cellularity, no clusters, normal staining	3
	Normal cellularity, mild clusters, moderate staining	2
	Mild or moderate hypocellularity, slight staining	1
	Severe hypocellularity, poor or no staining	0
Integrity of subchondral bone		
	Reconstitution of subchondral bone	
	Normal	3
	Reduced subchondral bone reconstitution	2
Inflammatory response in subchondral bone	Minimal subchondral bone reconstitution	1
	No subchondral bone reconstitution	0
	None or mild	2
	Moderate	1
Safranin O staining	Severe	0
	Normal	3
	Moderate	2
	Slight	1
Total maximum score	None	0
		28



**Figure 2.** Successful neocartilage construct with fibrin glue-treated defect, demonstrating an excellent repair. Filling was >50% to 80% with a smooth graft-cartilage interface.

evidence that the xenografts induced either hypertrophy at the graft interface or an immunologic reaction.

There was no appreciable evidence for chondral hypertrophy after implantation of the neocartilage construct. This lack of hypertrophy is significant. The incidence rate of hypertrophy after ACI using a periosteal graft is  $\leq 36\%$ .<sup>10,17,18,24,28</sup> This associated hypertrophy after ACI has been correlated to clinical symptoms and found to warrant further surgical intervention in 8 (28%) of 29 cases.<sup>24</sup>

The lack of an immune response to the xenogeneic fibrin sealant is significant. In the investigation of autologous cartilage construct fixation by Brehm et al,<sup>5</sup> the article identified the use of human (xenogeneic) fibrin sealant to cause cellular infiltration into the subchondral bone. Their finding was reported at 8 weeks postoperatively. In contrast, in our study at 24 weeks postoperatively, no immunogenic response occurred. This finding is not stated to deny the possibility of an immunologic reaction to the human fibrin. We hypothesize the host response to human fibrin may have occurred close to or during fibrin degradation. In this respect, if a reaction did occur, it may have subsided by necropsy at 24 weeks postoperatively. To our knowledge, there is no information available on the timeline of exogenous fibrin degradation within the joint. However, clinical human fibrin will be allografted, not xenografted. In addition, fibrin is already routinely used for hemostasis without adverse reactions.

An immunologic response to the human neocartilage construct is considered unlikely. First, unpublished animal studies of human neocartilage constructs in the knee joints of sheep, without the use of human fibrin, have not demonstrated host immunological response to the implants (ISTO Technologies, unpublished data, 2004). Second, there is no osseous component to the implantation of neocartilage constructs. Thorough independent investigations by Elves,<sup>11</sup> Elves and Zervas,<sup>12</sup>

TABLE 3

GROSS EVALUATION RESULTS OF INDIVIDUAL NEOCARTILAGE CONSTRUCT WITH FIBRIN GLUE-TREATED DEFECTS

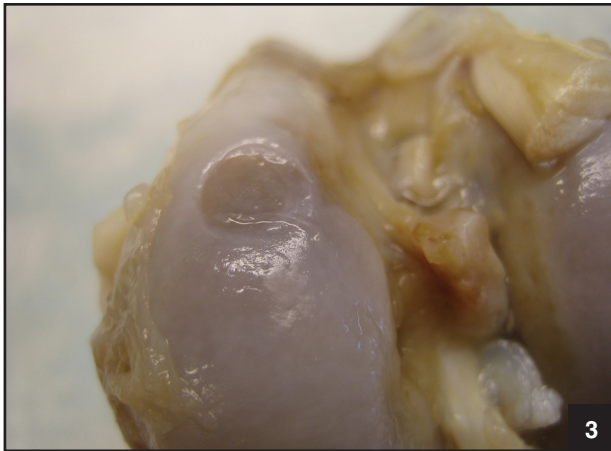Defect	Smoothness	Color	Integration	Filling	Overall Grade
Medial femoral condyle lesion					
1	Smooth	Translucent	Full	Complete	Nearly normal
2	Smooth	Opaque	Partial	Partial	Nearly normal
3	Rough	Transparent	None	No filling	No repair
4	Smooth	Opaque	Partial	Complete	Nearly normal
5	Smooth	Opaque	Partial	Complete	Nearly normal
6	Rough	Transparent	None	No filling	No repair
7	Rough	Transparent	None	No filling	No repair
8	Rough	Transparent	None	No filling	No repair
Trochlear lesion					
1	Rough	Transparent	None	No filling	No repair
2	Rough	Transparent	None	No filling	No repair
3	Intermediate	Translucent	Partial	No filling	Severely abnormal
4	Smooth	Opaque	Partial	Complete	Nearly normal
5	Smooth	Opaque	Partial	Complete	Nearly normal
6	Smooth	Translucent	Full	Complete	Nearly normal
7	Smooth	Opaque	Partial	Partial	Nearly normal
8	Rough	Transparent	None	No filling	No repair

Goldberg and Stevenson,<sup>16</sup> Stevenson,<sup>36</sup> and Vasseur et al<sup>39</sup> have demonstrated that the immune responses with osteochondral allografts are elicited by either the bone or residual marrow elements. To reduce this concern, Gibson<sup>14</sup> titrated the osseous thickness of allografts to identify the thickness that results in the best clinical outcome. This thickness was found to be 2 to 3 mm.<sup>14</sup> Third, cartilage is immune privileged, as found in 2 historical studies.<sup>4,8</sup> In 1968, Chesterman and Smith<sup>8</sup> found that chondrocytes and cartilage transplanted into the cancellous bone of separate animals failed to demonstrate histological evidence for immunogenicity. The lack of an immune response was confirmed by an investigation by Bentley et al<sup>4</sup> in which epiphyseal chondrocyte allografts were transplanted into the joint surface of adult rabbits but failed to produce a smooth cartilage repair. It is suspected this was a result of failed fixation into the tibial articular surface.

Use of fibrin fixation has important advantages over alternative methods of fixation. First, the ease of the surgical application of fibrin sealant and the potential adaptability to arthroscopic surgeries has significant advantages over the use of a periosteal flap requiring open surgery and technically demanding suturing. In addition, fibrin glue preserves graft integrity. Direct suturing of

neocartilage grafts to surrounding native cartilage can fail with shearing action during joint articulation. The fibrin glue selected at the time of our study design was chosen because all of its protein components were human derived. There have been further developments in human-derived fibrin sealants since then. Fibrinogen, whether human or animal derived, is one of the biological active components in fibrin sealants. The content of fibrinogen in the fibrin sealant used in this study was 40 to 60 mg/mL.<sup>9</sup> Fibrinogen sealants are now demonstrating a fibrinogen content of 67 to 107 mg/mL (Tisseel; Baxter, Deerfield, Ill).<sup>37</sup> This increased fibrinogen concentration may yield a stronger fibrin matrix, leading to improved graft retention.<sup>35,42</sup> In addition, natural growth factors within novel fibrin sealants may affect graft retention rates.<sup>31</sup>

The results of this study, at an extended 24-week follow-up period, correspond to the results of 3 previously reported studies.<sup>5,27,38</sup> Brehm et al<sup>5</sup> studied 4 fixation methods. In that study, fixation with platelet-rich plasma and a periosteal flap together demonstrated the best results (4 of 8 defects).<sup>5</sup> When the periosteal flap was used in combination with fibrin glue, the implant was maintained in 3 (37%) of 8 defects. The explanation for decreased retention with the use of fibrin glue



**Figure 3.** Failed neocartilage construct with fibrin glue-treated defect. The step-off into an erythematous defect depicted here represents a medial femoral condyle defect that lost the implant.

was the hosts' adverse reaction to xenogeneic material (fibrin glue).<sup>5</sup> Lu et al<sup>27</sup> used tissue transglutaminase to augment suture fixation and did not find a significant improvement in integration, compared with the use of suture alone. In a study of ACI, Vasara et al<sup>38</sup> investigated the use of suture and fibrin glue for fixation. Despite this relatively secure fixation, all treated defects lost the transplant. The study concluded that the model failed due to graft delamination secondary to a lack of immobilization.<sup>38</sup>

Successful immobilization has been cited as lowering flap delamination and raising retention rates.<sup>2,5,10,27,38</sup> Driesang and Hunziker<sup>10</sup> investigated this specifically and found that immobilization reduced the failure of periosteal and fascial flaps from 100% to 33% and 5%, respectively. The failure rate of 20% to 30% reported

by Lu et al<sup>27</sup> was primarily attributed to unsuccessful immobilization after surgery. In the current study, weight bearing and range of motion of the stifle joint were restricted by the immediate postoperative application of a custom-made Thomas splint.<sup>23</sup> Despite the application of this splint, maintaining adequate immobilization was challenging. Goats had freed their legs from the splint and endured full range of motion or underwent unrestricted weight bearing. It is possible the rate of graft retention would be improved in a more compliant period of immobilization. However, the interval of joint immobilization must be balanced with dynamic biomechanical stimulation to facilitate graft integration and maturation.<sup>33</sup> Animal subjects are not easily managed with such a protocol of immobilization and remobilization.

The use of an animal model in this study limits its clinical relevance. Human subjects more adherent to a carefully designed rehabilitation protocol presumably will demonstrate higher rates of graft retention. This can parallel the successful evolution in ACI. The rate of delamination of the periosteal flap in ACI was 50% in animal studies<sup>2,10,30</sup> and 7% to 23% in human clinical experiences.<sup>3,15,34,41</sup>

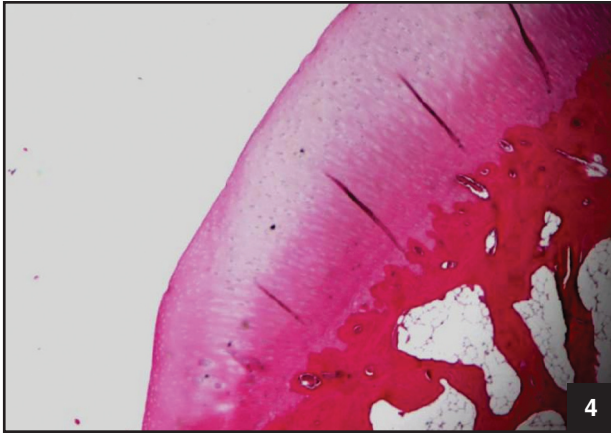
Tissue-engineered neocartilage constructs produced with juvenile chondrocytes offer potential benefits, including:

- The use of neocartilage avoids the need for harvesting autologous osteochondral plugs and therefore eliminates the concern of donor-site morbidity.
- Implantation of durable neocartilage grafts can be performed in a single-stage surgery and potentially without the technical demand of suturing a periosteal flap into surrounding cartilage.
- The repair tissue from neocartilage allografting maintains type-II collagen and is not fibrocartilaginous.

**TABLE 4**

GROSS EVALUATION RESULTS OF INDIVIDUAL FIBRIN GLUE ONLY-TREATED DEFECTS

Defect	Smoothness	Color	Integration	Filling	Overall Grade
Medial femoral condyle lesion					
1	Intermediate	Opaque	Partial	Partial	Abnormal
2	Intermediate	Translucent	Partial	Partial	Severely abnormal
3	Smooth	Opaque	Partial	Partial	Nearly normal
4	Intermediate	Translucent	None	No filling	No repair
Trochlear lesion					
1	Smooth	Translucent	Partial	No filling	Severely abnormal
2	Intermediate	Opaque	Partial	Complete	Abnormal
3	Intermediate	Opaque	Partial	Partial	Severely abnormal
4	Intermediate	Translucent	Partial	Partial	Severely abnormal



**Figure 4.** Histologic integration of the neocartilage graft. Hematoxylin-eosin staining demonstrated excellent graft integration into the surrounding cartilage laterally and basally to subchondral bone, which is free of evidence of a reactive inflammatory response.

Compared with other emerging autologous cell therapies for cartilage repair, the neocartilage technology uses implants of juvenile differentiated chondrocytes with substantial biosynthetic activities.

### CONCLUSION

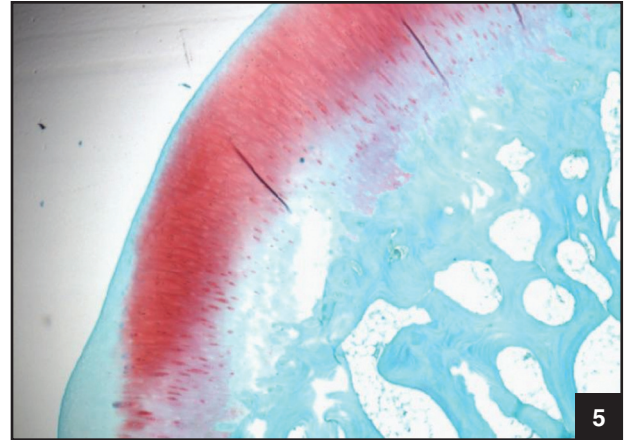
The results of this study show the use of fibrin glue can provide reasonable success of graft fixation within a well-shouldered full-thickness cartilage defect. Given more defined weight-bearing restrictions and passive range of motion limitations, fibrin glue may become a confident choice for the fixation of neocartilage grafts in full-thickness defects of human joints. We consider these results to be promising regarding the future use of neocartilage grafts to address human chondral lesions.

### ACKNOWLEDGMENT


The authors thank Drs Jeff Oswald and Marge Piel for their veterinary care of the animal subjects; Dr Vamsi Singaraju, Ms Sarah Gitelis, and Mr David Karwo for their contributions in preparing the histologic samples; and Dr H.D. Adkisson for his valuable comments on parts of the manuscript.

### REFERENCES

1. Adkisson HD, Gillis MP, Davis EC, Manley W, Hruska KA. In vitro generation of scaffold independent neocartilage. *Clin Orthop*. 2001;(391 suppl):S280-S294.
2. Aklin B, Brehm W, Mainil-Varlet P. Periosteal flap loosening rate in a caprine chondral defect model. *Osteoarthritis Cartilage*. 2003;11(suppl A):107.
3. Bentley G, Biant LC, Carrington RW, et al. A prospective, randomised comparison of autologous chondrocyte im-



**Figure 5.** Safranin O staining of neocartilage construct. The proteoglycan content was well appreciated within the implant, but a loss of proteoglycan can be noted at the basal interface between the graft and subchondral bone.



**Figure 6.** Picrosirius red staining of the neocartilage construct with fibrin glue-treated defect. An intact articular surface is appreciated but lacks normal birefringence (dashed line oval), representing a change in collagen orientation and the neocartilage graft. An island of normal birefringence is noted within the sample (solid line oval).

- plantation versus mosaicplasty for osteochondral defects in the knee. *J Bone Joint Surg Br*. 2003;85:223-230.
4. Bentley G, Smith AU, Mukerjee R. Isolated epiphyseal chondrocyte allografts into joint surfaces. An experimental study in rabbits. *Ann Rheum Dis*. 1978;37:449-458.
5. Brehm W, Aklin B, Yamashita T, et al. Repair of superficial osteochondral defects with an autologous scaffold-free cartilage construct in a caprine model: Implantation method and short-term results. *Osteoarthritis Cartilage*.



- 2006;14:1214-1226.
6. Breinan HA, Martin SD, Hsu HP, Spector M. Healing of canine articular cartilage defects treated with microfracture, a type-II collagen matrix, or cultured autologous chondrocytes. *J Orthop Res.* 2000;18:781-789.
  7. Butnariu-Ephrat M, Robinson D, Mendes DG, Halperin N, Nevo Z. Resurfacing of goat articular cartilage by chondrocytes derived from bone marrow. *Clin Orthop.* 1996;(330):234-243.
  8. Chesterman PJ, Smith AU. Homotransplantation of articular cartilage and isolated chondrocytes. An experimental study in rabbits. *J Bone Joint Surg Br.* 1968;50:184-197.
  9. Crosseal fibrin sealant (human) [package insert]. Ramat Gan, Israel: OMRIX Biopharmaceuticals, Ltd.; 2004.
  10. Driesang IM, Hunziker EB. Delamination rates of tissue flaps used in articular cartilage repair. *J Orthop Res.* 2000;18:909-911.
  11. Elves MW. A study of the transplantation antigens on chondrocytes from articular cartilage. *J Bone Joint Surg Br.* 1974;56:178-185.
  12. Elves MW, Zervas J. An investigation into the immunogenicity of various components of osteoarticular grafts. *Br J Exp Pathol.* 1974;55:344-351.
  13. Frenkel SR, Toolan B, Menche D, Pitman MI, Pachence JM. Chondrocyte transplantation using a collagen bilayer matrix for cartilage repair. *J Bone Joint Surg Br.* 1997;79:831-836.
  14. Gibson T. Cartilage and bone transplantation. *Transplant Proc.* 1969;1:246-250.
  15. Gilligly SD. Treatment of large full-thickness chondral defects of the knee with autologous chondrocyte implantation. *Arthroscopy.* 2003;19(suppl 1):147-153.
  16. Goldberg VM, Stevenson S. Natural history of autografts and allografts. *Clin Orthop.* 1987;(225):7-16.
  17. Gooding CR, Bartlett W, Bentley G, et al. A prospective, randomised study comparing two techniques of autologous chondrocyte implantation for osteochondral defects in the knee: Periosteum covered versus type I/III collagen covered. *Knee.* 2006;13:203-210.
  18. Henderson I, Tuy B, Oakes B. Reoperation after autologous chondrocyte implantation. Indications and findings. *J Bone Joint Surg Br.* 2004;86:205-211.
  19. Horas U, Pelinkovic D, Herr G, Aigner T, Schnettler R. Autologous chondrocyte implantation and osteochondral cylinder transplantation in cartilage repair of the knee joint. A prospective, comparative trial. *J Bone Joint Surg Am.* 2003;85:185-192.
  20. Institute of Laboratory Animal Resources, Commission on Life Sciences, National Research Council. (1996). *Guide for the Care and Use of Laboratory Animals.* Washington, DC: National Academy Press.
  21. Jackson DW, Halbrecht J, Proctor C, Van Sickle D, Simon TM. Assessment of donor cell and matrix survival in fresh articular cartilage allografts in a goat model. *J Orthop Res.* 1996;14:255-264.
  22. Jackson DW, Lalor PA, Aberman HM, Simon TM. Spontaneous repair of full-thickness defects of articular cartilage in a goat model. A preliminary study. *J Bone Joint Surg Am.* 2001;83:53-64.
  23. Jackson DW, Simon TM. Tissue engineering principles in orthopaedic surgery. *Clin Orthop.* 1999;(367 suppl):S31-S45.
  24. Kreuz PC, Steinwachs M, Erggelet C, et al. Classification of graft hypertrophy after autologous chondrocyte implantation of full-thickness chondral defects in the knee. *Osteoarthritis Cartilage.* 2007;15:1339-1347.
  25. Lane JG, Massie JB, Ball ST, et al. Follow-up of osteochondral plug transfers in a goat model: A 6-month study. *Am J Sports Med.* 2004;32:1440-1450.
  26. Lane JG, Tontz WL Jr, Ball ST, et al. A morphologic, biochemical, and biomechanical assessment of short-term effects of osteochondral autograft plug transfer in an animal model. *Arthroscopy.* 2001;17:856-863.
  27. Lu Y, Adkisson HD, Bogdanske J, et al. In vivo transplantation of neonatal ovine neocartilage allografts: Determining the effectiveness of tissue transglutaminase. *J Knee Surg.* 2005;18:31-42.
  28. Micheli LJ, Browne JE, Erggelet C, et al. Autologous chondrocyte implantation of the knee: Multicenter experience and minimum 3-year follow-up. *Clin J Sport Med.* 2001;11:223-228.
  29. Murphy JM, Fink DJ, Hunziker EB, Barry FP. Stem cell therapy in a caprine model of osteoarthritis. *Arthritis Rheum.* 2003;48:3464-3474.
  30. Nehrer S, Breinan HA, Ramappa A, et al. Chondrocyte-seeded collagen matrices implanted in a chondral defect in a canine model. *Biomaterials.* 1998;19:2313-2328.
  31. Newton C, Goodwin C, Helgersson S, Spaethe R. Human growth factors in the fibrinogen complex component of fibrin sealant products. Paper presented at: 7th World Biomaterials Congress; May 17-21, 2004; Sydney, Australia.
  32. O'Driscoll SW, Comisso CN, Fitzsimmons JS. Type II collagen quantification in experimental chondrogenesis. *Osteoarthritis Cartilage.* 1995;3:197-203.
  33. O'Driscoll SW, Salter RB. The induction of neochondrogenesis in free intra-articular periosteal autografts under the influence of continuous passive motion. An experimental investigation in the rabbit. *J Bone Joint Surg Am.* 1984;66:1248-1257.
  34. Peterson L, Minas T, Brittberg M, et al. Two- to 9-year outcome after autologous chondrocyte transplantation of the knee. *Clin Orthop.* 2000;(374):212-234.
  35. Scheraga HA. The thrombin-fibrinogen interaction. *Biophys Chem.* 2004;112:117-130.
  36. Stevenson S. The immune response to osteochondral allografts in dogs. *J Bone Joint Surg Am.* 1987;69:573-582.
  37. Tisseel fibrin sealant [package insert]. Deerfield, IL: Baxter Healthcare; 2002.
  38. Vasara AI, Hyttinen MM, Lammi MJ, et al. Subchondral bone reaction associated with chondral defect and attempted cartilage repair in goats. *Calcif Tissue Int.* 2004;74:107-114.
  39. Vasseur PB, Rodrigo JJ, Stevenson S, Clark G, Sharkey N. Replacement of the anterior cruciate ligament with a bone-ligament-bone anterior cruciate ligament allograft in dogs. *Clin Orthop.* 1987;(219):268-277.
  40. Williams JM, Ongchi DR, Thonar EJ. Repair of articular cartilage injury following intra-articular chymopapain-induced matrix proteoglycan loss. *J Orthop Res.* 1993;11:705-716.
  41. Wood JJ, Malek MA, Frassica FJ, et al. Autologous cultured chondrocytes: Adverse events reported to the United States Food and Drug Administration. *J Bone Joint Surg Am.* 2006;88:503-507.
  42. Wozniak G. Fibrin sealants in supporting surgical techniques: The importance of individual components. *Cardiovasc Surg.* 2003;11(suppl 1):17-21.