

Chapter 21

Articular Cartilage Injury and Adult OCD: Treatment Options and Decision Making

Nicole A. Friel, Sarvottam Bajaj, and Brian J. Cole

INTRODUCTION

Osteochondritis dissecans (OCD) is a pathologic process in which the subchondral bone and the overlying articular cartilage detach from the underlying bony surface.^{10,40,55} The disease results in subchondral bone loss and destabilization of the overlying articular cartilage, leading to separation and increased susceptibility to stress and shear.⁴³ Fragmentation of both cartilage and bone leads to early degenerative changes and loss of function in the affected compartment. The true cause is unknown but is likely related to repetitive microtrauma, an acute traumatic incident, ischemia, an ossification abnormality, or endocrine or genetic predisposition.^{2,39,53}

The prevalence of OCD is estimated at 15 to 30 cases per 100,000, most frequently occurring in the knee, with medial femoral condyle involvement in 80% of cases, lateral femoral condyle in 15%, and patellofemoral in 5%.^{27,36} The lateral aspect of the medial femoral condyle is the classic site of the OCD lesion. In addition to the knee, OCD has the propensity of occurring in the elbow, wrist, and ankle.^{2,10,55}

Osteochondritis dissecans is divided into juvenile (JOCD) and adult (AOCD) forms.⁹ The distinction between JOCD (open growth plates) and AOCD (closed growth plates) may be important in treatment and prognosis. JOCD often resolves with nonoperative management and has a much better prognosis compared with adult OCD, which, once symptomatic, can follow a progressive, unremitting course.

Nonoperative treatments for symptomatic AOCD are rarely an option because of the inherent poor regenerative capacity of articular cartilage. Thus, cases of AOCD usually require surgical intervention, such as loose body removal, drilling, internal fixation, marrow stimulation, autologous chondrocyte implantation, or osteochondral autograft/allograft transplantation, to replace the damaged cartilage. In advanced cases, joint replacement may be the only feasible solution.

PRESENTATION

A patient with an OCD lesion complains primarily of pain and swelling of the affected joint, which can be triggered by physical activity. In the presence of a loose body, mechanical symptoms such as clicking, popping, and locking may accompany the primary complaints.

On physical examination, patients present with tenderness overlying the OCD region. Patients often present with an antalgic gait. If the OCD lesion is present in the classic location, the lateral aspect of the medial femoral condyle, the patient will ambulate with the affected leg in relative external rotation (Wilson sign) to decrease contact of the lesion with the medial tibial eminence. Joint effusion, decreased

range of motion, and quadriceps atrophy are also variably present, depending on the severity and duration of the lesion.^{20,42}

Patellar OCD most often presents with patellofemoral pain, followed by swelling. Feelings of a loose body, locking, or giving way, or episodes of patellar subluxation may also be noted. On examination, patients have retropatellar crepitus or pain and effusion.

IMAGING

Unfortunately, none of the physical findings observed during the examination can be used specifically to diagnose OCD; hence, confirmatory x-ray, magnetic resonance imaging (MRI), or computed tomography (CT) scans are required. Plain x-ray films should include standard anteroposterior, flexion weight-bearing anteroposterior (tunnel view), lateral, and Merchant views (Fig. 21-1). Flexion weight-bearing anteroposterior in addition to standard anteroposterior allows better visualization of lesions along the posterolateral aspect of the medial femoral condyle.²⁶ Radiographic images of patients with adult OCD show a lesion that typically appears as an area of osteosclerotic bone, with a high-intensity line between defect and epiphysis.

MRI is the mainstay in the diagnosis of OCD lesions and is the most informative imaging modality in the preoperative workup of OCD. Specifically, the quality of bone edema, subchondral separation, and cartilage condition are evaluated before treatment.¹ MRI can reliably indicate lesion size, location, and depth, providing insight into a patient's knee condition (Fig. 21-2). MRI images are assessed according to the criteria presented below; meeting one of the four criteria offers up to 97% sensitivity and 100% specificity in predicting lesion stability.^{15,16,20,43}

- Thin, ill-defined or well-demarcated line of high signal intensity, measuring 5 mm or more in length at the interface between the OCD lesion and underlying subchondral bone
- Discrete rounded area of homogeneous high signal intensity, 5 mm or more in diameter beneath the lesion
- Focal defect with an articular surface of the lesion with a width of 5 mm or more
- High signal intensity line traversing the articular cartilage and subchondral bone plate into the lesion

Furthermore, OCD lesions can be classified by MRI findings according to whether the lesion is attached, partially attached, or completely detached from the parent bone^{37,43,49} (Table 21-1).

Other imaging modalities such as CT scans are also used, as they can be greatly beneficial in revealing the exact location and extent of the lesion.

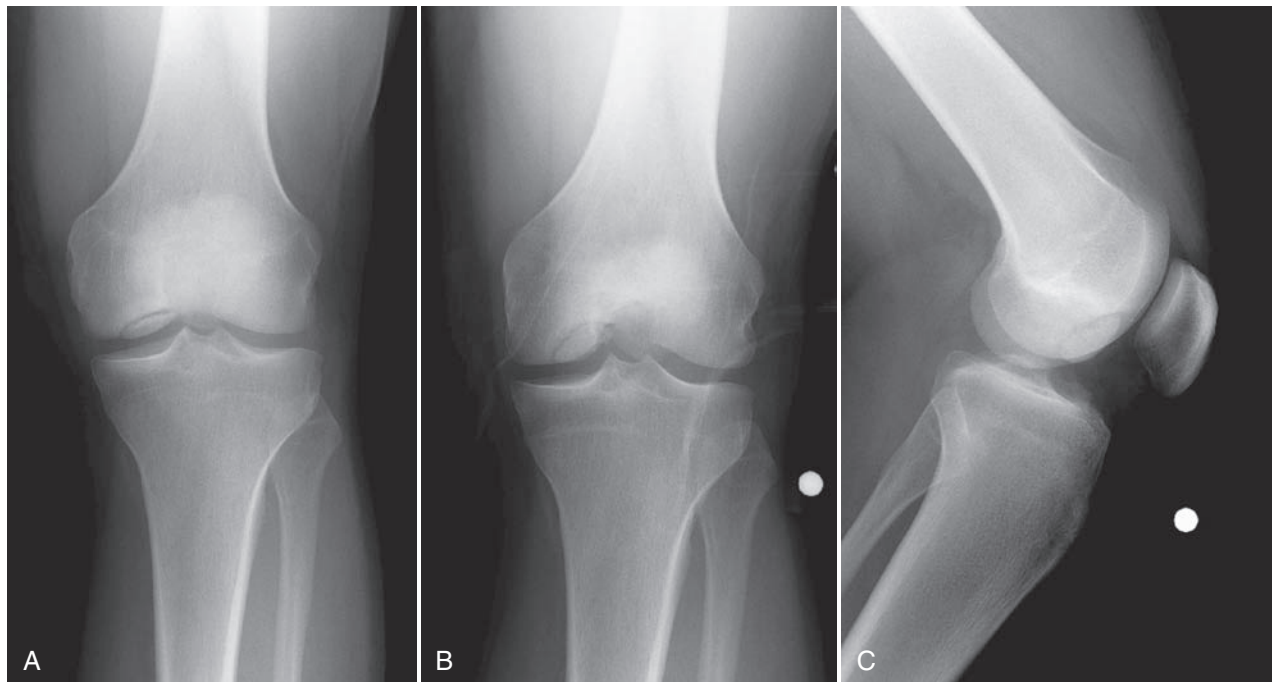


Figure 21-1. Radiograph of an osteochondritis dissecans (OCD) lesion in the classic location of the lateral aspect of the medial femoral condyle. **A**, Standard anteroposterior. **B**, Flexion weight-bearing anteroposterior. **C**, Lateral.

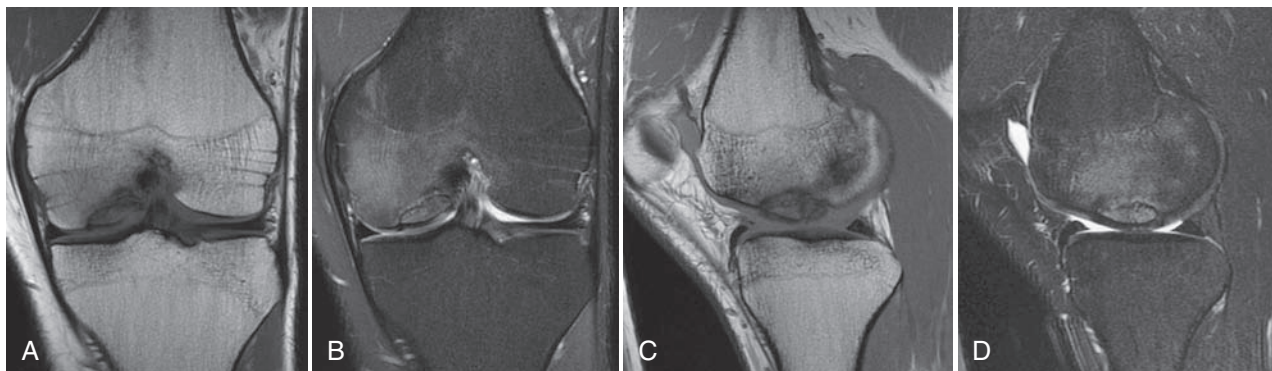


Figure 21-2. Magnetic resonance imaging (MRI) of an osteochondritis dissecans (OCD) lesion at the lateral aspect of the medial femoral condyle. Anteroposterior T1-weighted (**A**) and T2-weighted (**B**) views. Sagittal T1-weighted (**C**) and T2-weighted (**D**) views.

Table 21-1 MRI Staging for Evaluation of Osteochondral Fracture^{27,33,38}

Stage	MRI Findings
0	Normal
I	Signal changes consistent with articular cartilage injury, without disruption, and with normal subchondral bone
II	High-grade signal intensity; breach of the articular cartilage with a stable subchondral fragment
III	Partial chondral detachment with a thin high-signal rim (on T2-weighted images) behind the osteochondral fragment, representing synovial fluid
IV	Loose body in the center of the osteochondral fragment or free in the joint space

ETIOLOGY, NATURAL HISTORY, AND PROGNOSIS

The definitive cause of OCD has yet to be established. A number of factors may contribute, such as repetitive micro-trauma, acute stress and injury, restricted blood supply, endocrine abnormalities, and genetic predisposition.^{2,39,53} Physical trauma is thought to be one of the major contributory factors in the development of OCD. Repetitive trauma to the joint leads to redundant healing and fibrosis, interrupting the blood supply to subchondral bone and possibly leading to avascular necrosis.¹³ In adults, high-impact sports such as soccer, basketball, football, and weightlifting may put a participant at higher risk of developing OCD. Endocrine abnormalities affecting calcium and phosphorous homeostasis or

anomalies of bone formation can compromise the blood supply to subchondral bone and progress to avascular necrosis. Recent reports have suggested a genetic predisposition to OCD.³⁹

Most adult OCD cases arise from established but untreated or asymptomatic juvenile OCD. However, many patients with adult OCD present with a history of knee pain that began when they had open physes. These cases probably represent juvenile OCD that did not heal and evolved to adult OCD. An exception to this progression is juvenile OCD that heals spontaneously; however, such lesions usually are not present in the classic location (lateral aspect of the medial femoral condyle).^{13,55} Adult OCD may also arise de novo.^{9,21}

The natural history of untreated OCD is poorly defined. Neither the literature nor our experience allows us to definitively determine whether untreated OCD has a higher likelihood of progressing to symptomatic degenerative joint disease (DJD) in the future. Linden performed a long-term retrospective follow-up study on patients with OCD of the femoral condyles with an average follow-up of 33 years after initial diagnosis.³⁵ The author concluded that OCD occurring prior to closure of the physes (JOCD) does not lead to additional complications later in life, but patients who manifest OCD after closure of the physes (AOCD) develop osteoarthritis 10 years earlier than the normal population. In contrast, Twyman and associates evaluated 22 knees with juvenile OCD and found that 50% had some radiographic signs of osteoarthritis at an average follow-up of 34 years.⁵⁶ The likelihood of development of osteoarthritis was also found to be proportional to the size of the area involved. The authors believe that lateral femoral condyle OCD has a poorer prognosis, but not all of these cases will become symptomatic over time despite radiographic changes.

NONSURGICAL TREATMENT

The ideal goal of conservative treatment is to attain lesion healing, which occurs more often before physal closure.

Stable OCD lesions in young patients have a favorable prognosis and are treated initially with nonoperative treatment. Nonoperative treatment options include modified activity with decreased weight bearing, anti-inflammatory medications, and management of patient symptoms. Traditional nonoperative treatment consists of an initial phase of knee immobilization with partial weight bearing to prevent repeated microtrauma lesions. Once the patient is pain free, weight bearing as tolerated is permitted and a rehabilitation program emphasizing knee range of motion and low-impact strengthening exercises ensues. The goal is to promote healing in the subchondral bone and prevent chondral separation. X-rays are usually taken 3 months after the start of nonsurgical therapy to assess the status of the lesion and the condition of the subchondral bone. If the lesion reveals adequate healing, patients are allowed to gradually return to activities; if no change is observed, x-ray assessment is repeated in 3 months.

SURGICAL TREATMENT

Surgical options are considered more often than not for adult OCD, as articular cartilage presents with an inherent poor ability to repair itself. Surgical options include loose body removal, drilling of the subchondral bone, internal fixation of the fragment, microfracture, osteochondral autografting and allografting, and autologous chondrocyte implantation.^{9,19,21,43} The overall goal of such intervention is to enhance the healing potential of the subchondral bone, fix the unstable fragment, and replace damaged bone and cartilage with implantable tissue.

The type and extent of surgery necessary for OCD depend on the patient's age, characteristics of the lesion (quality of articular cartilage, size of associated subchondral bone, and shape, thickness, and location of the lesion), diagnostic information provided by MRI and arthroscopy, and preference of the operating surgeon. The author's preferred algorithm for treatment of OCD lesions is shown in Figure 21-3.

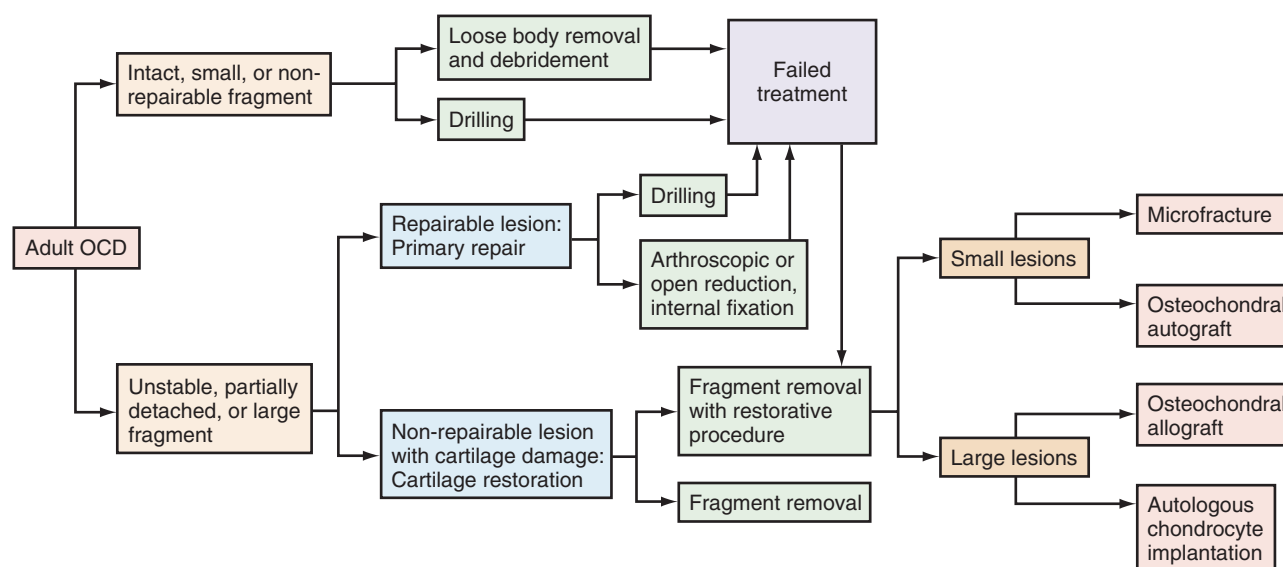


Figure 21-3. Algorithm for surgical treatment of adult osteochondritis dissecans (OCD).

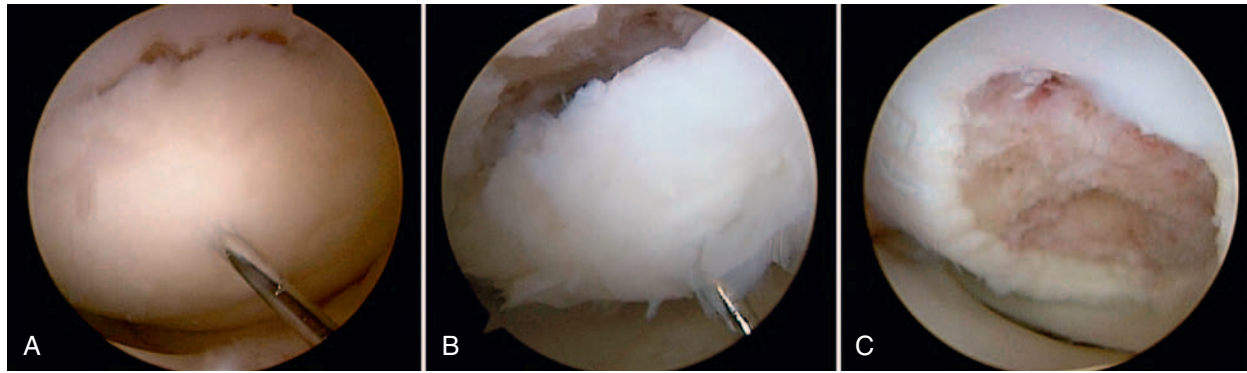


Figure 21-4. Unstable osteochondritis dissecans (OCD) fragment. **A**, OCD lesion palpable at arthroscopy. **B**, Palpation reveals unstable lesion. **C**, Subchondral bone following removal of the OCD lesion.

Table 21-2 Guhl's Classification¹⁸

Stage	Arthroscopic Findings
I	Normal
II	Fragmentation in situ
III	Partial detachment
IV	Complete detachment, loose body present

Positioning, Examination under Anesthesia, and Diagnostic Arthroscopy

All patients are placed supine, with the leg supported by a standard thigh holder and the knee flexed at 90 degrees. The affected extremity is prepared and draped to the proximal thigh to ensure easy access to the knee. Examination under anesthesia assesses range of motion and ligamentous integrity. Lesions on the surfaces of the femoral condyle can usually be accessed using an arthroscopic approach. Standard portals are used and accessory portals are added when needed to improve visibility. More challenging locations, such as the patella and tibial plateau, may require an arthrotomy for better visualization and treatment.

A complete diagnostic arthroscopic evaluation of the structures in each compartment is performed. When the lesions are identified, a probe is used to determine the stability of the fragment (Fig. 21-4). Guhl's intraoperative classification is defined by cartilage integrity and fragment stability²⁵ (Table 21-2).

Loose Body Removal

In a small number of cases, when the fragment is comminuted, avascular, deformed, or otherwise irreparable, fragment removal is an isolated treatment option.³ In cases involving chronic symptomatic lesions, fibrous tissue may impede anatomic reduction and adequate healing. In addition, the fragment may be associated with only small amounts of subchondral bone with limited ability to heal.

Although OCD lesions should be reduced, stabilized, bone grafted, or restored when possible, patients with small or non-weight-bearing lesions may have good outcomes with isolated loose body removal. Ewing and Voto showed 72% satisfactory results in patients treated with fragment excision with or without drilling or abrasion.¹⁹ A recent study showed

successful outcomes in 8 of 9 patients treated with loose body removal alone for small (<2 cm²) AOCD lesions.⁵⁰ These results, however, are controversial and may pertain only to short-term outcomes. Anderson and Pagnani excised OCD fragments in 11 patients with JOCD and 9 patients with AOCD. At an average of 9 years postoperatively, 5 failures and 6 poor outcomes were reported, and equally disappointing outcomes were seen with JOCD and AOCD.⁴ Similarly, Wright and coworkers had 65% fair or poor results at an average 8.9 years postoperatively in 17 patients treated for fragment excision, and suggested the use of aggressive cartilage preservation techniques and avoidance of fragment excision.⁵⁸

REPARATIVE PROCEDURES

The goal of reparative procedures is to restore the integrity of the native subchondral interface and preserve the overlying articular cartilage.⁴²

Drilling

As mentioned previously, disruption of the blood supply to the subchondral bone is thought to be an important factor in the development of OCD.⁵ Thus, treatment incorporates creation of vascular channels to the affected region. Arthroscopic drilling can be used to generate such channels and is usually performed in young patients.¹

This technique is performed using an antegrade or a retrograde approach. Antegrade drilling is performed from the joint space, through the articular cartilage, and into the subchondral bone. Lesions of the medial femoral condyle can be drilled through an anterolateral or anteromedial portal, and lesions of the lateral femoral condyle are usually accessible through the anterolateral portal. If the lesion is not accessible via standard portals, accessory portals are created to obtain an orthogonal drilling angle.⁵ Multiple holes are drilled using a K-wire, making certain to uniformly cover the lesion. Return of blood and fat droplets from the drilled region is used to confirm the depth of the penetration.

Antegrade drilling has the undesirable consequence of violating the articular cartilage surface and therefore causing fill with fibrocartilage. Retrograde drilling, although more difficult, avoids damage to the articular cartilage. The drill enters behind the lesion and penetrates the bony fragment without violating the cartilage or entering the joint. C-arm

visualization or the use of an anterior cruciate ligament (ACL) guide is necessary to avoid joint penetration or dislodgement of the OCD fragment.³²

Overall, outcomes of OCD drilling are generally favorable, and patient age is the best prognostic factor. Younger patients who have undergone this procedure demonstrate higher levels of radiographic healing and favorable relief of symptoms.^{5,8,18,31} Louisiana and associates compared outcomes of JOCD versus AOCD, reporting radiographic healing in 71% of JOCD cases, and only 25% in adult OCD cases.³⁸

It is our opinion that drilling should be utilized when the defect is stable to palpation despite MRI evidence of fluid behind the fragment, indicating biologic instability. When possible, drilling is performed through the intercondylar notch (i.e., adjacent to the posterior cruciate ligament [PCL] femoral origin for OCD of the medial femoral condyle [MFC]) or along the lateral nonarticulating border of the distal femur using a 0.45-mm K-wire. When no gross ballotable instability is noted, we often place one or two bioabsorbable compression screws that are buried deep to the level of the subchondral plate (BioCompression Screw, Arthrex, Inc., Naples, Fla). With any evidence of instability, we make every effort to “hinge” the lesion open to expose the base, which is often covered in fibrovascular scar tissue.

Arthroscopic or Open Reduction and Internal Fixation

Adult OCD lesions that have become detached from the subchondral bone may present with articular cartilage flaps or loose bodies that require fixation.⁴³ Fixation is advised for symptomatic unstable lesions, provided that the lesion has sufficient subchondral bone to provide support for the fixation system. A cartilage flap, sometimes referred to as a hinged lesion, can be fixed using pins and screws. Unstable “trap door” lesions, which are partially elevated off the subchondral bone, require bed fixation, which can be achieved using microfracture awls to restore/improve blood supply, followed by fixation.⁴⁷

Internal fixation can be achieved using a variety of fixation devices, as well as bone pegs and osteochondral grafts.^{11,22} Internal fixation devices include cannulated screws, metal pins/K-wires, and bioabsorbable pins. The method of fixation is based largely on surgeon preference.

Constant pitch (AO) and variable pitch (Herbert, Accutrak) cannulated screws allow for compression across the lesion. AO screws, available in varying sizes, must be placed

below the articular surface to avoid damage to the opposing articular surface. Variable pitch Herbert (partially threaded) and Accutrak (fully threaded) screws have a headless design that allows excellent compression of the fragment into the defect bed. Some surgeons bury the head of these screws, so as to allow early range of motion and prevent subsequent damage to the opposing tibial surface. However, it is the author's preference to utilize variable pitch metal screws and remove them at 8 weeks postoperatively to assess for healing and to avoid the consequences of fragment collapse, which can lead to prominent hardware. Bioabsorbable screws have been recommended by some to avoid removal, but questions remain as to the degree of compression they provide and the fact that they remain in situ for a prolonged time before enzymatic breakdown occurs.²⁸

Before screw placement, unstable lesions are opened to expose the sclerotic bed. If necessary, lesions on the lateral aspect of the medial femoral condyle may require superficial release of PCL fibers to expose the lateral margin of the lesion.²² Cartilage at the lesion site is hinged open, the undersurface is débrided and curetted, and microfracture awls are used to stimulate the subchondral bone. To place a screw, a guide wire is drilled through the fragment into the femoral condyle. The guide wire is then overdrilled and the screw is placed, compressing the fragment into the bed (Figs. 21-5 and 21-6). Another option is retrograde fixation, which most often is used for OCD lesions of the patella. Screws are placed from behind the lesion through the subchondral bone and into the bony portion of the fragment. Accurate screw placement is crucial for the success of this procedure and often involves the use of intraoperative fluoroscopy. Following any OCD procedure with internal fixation, the knee should be ranged to ensure that the screw head does not abrade the opposing surface.

K-wires and metal pins are advantageous because of their ease of insertion and availability in the operating room. However, K-wire use is limited because K-wires do not provide compression, may break or bend, and can migrate from the osteochondral fragment.

Bioabsorbable pins, both smooth and barbed, offer adequate fixation when a smaller device is used without the need for removal. Pins are placed by an anterograde method, and the small-head or headless pin can be impacted beneath the surface. Bioabsorbable pins have the disadvantages of implant fracture and foreign body reaction, resulting in aseptic synovitis. In addition, they provide minimal compression across the defect junction.

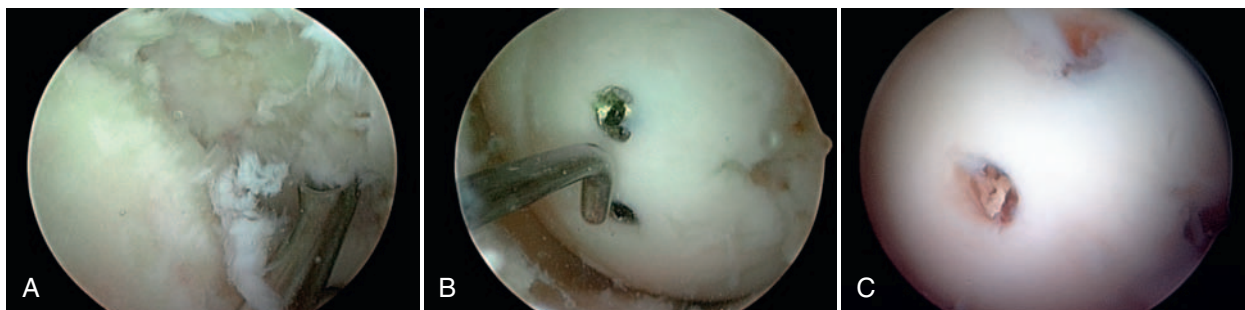


Figure 21-5. Arthroscopic reduction, internal fixation of the osteochondritis dissecans (OCD) fragment. **A**, Unstable fragment with curettage of the underlying subchondral bone. **B**, Fragment fixation with two metallic compression screws. **C**, Hardware removal at second-look arthroscopy 8 weeks postoperatively.

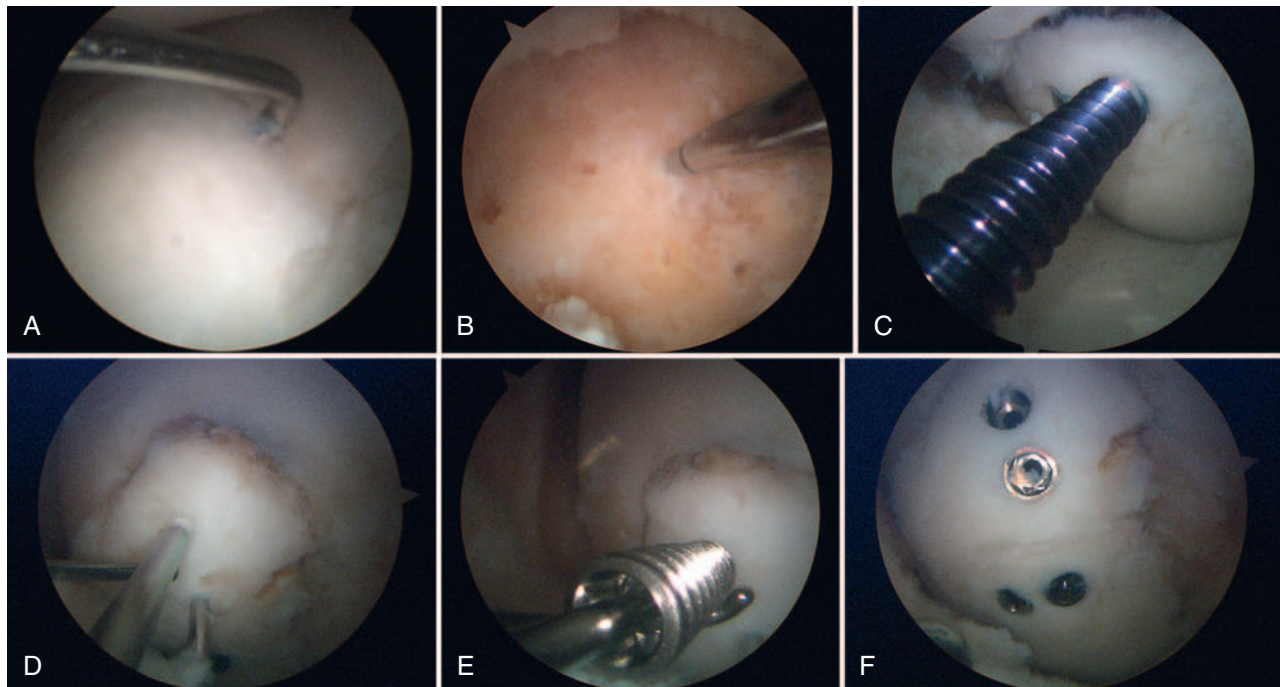


Figure 21-6. **A**, Unstable osteochondritis dissecans (OCD) fragment palpable at arthroscopy. **B**, Débridement and microfracture of the subchondral bone. **C**, Screw placement for fixation. **D**, Evaluation of reduced fragment. **E**, Placement of additional screws to provide further compression and rotational stability. **F**, Final fixation of two large fragments, each with two screws.

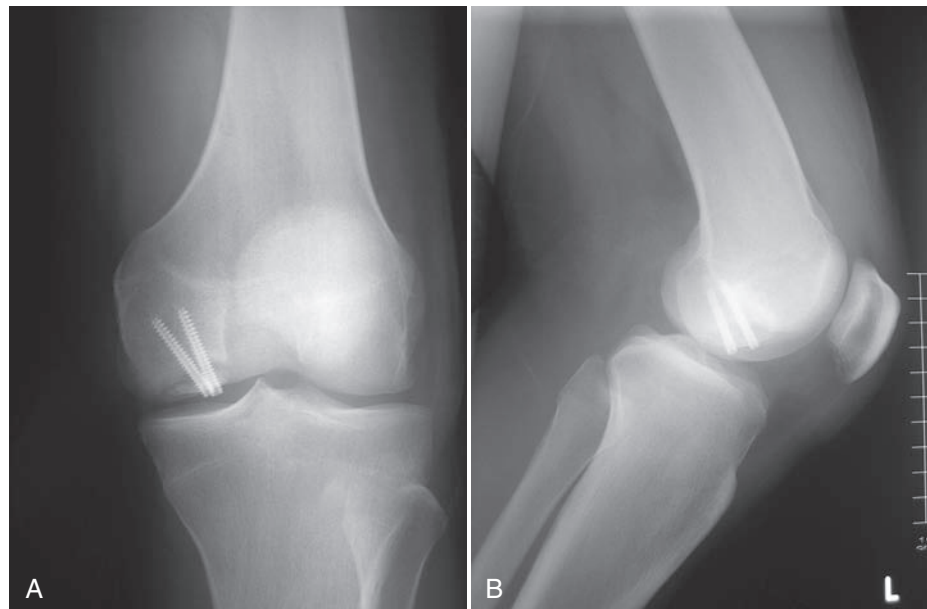


Figure 21-7. Anteroposterior (**A**) and lateral (**B**) views of an osteochondritis dissecans (OCD) lesion after screw fixation. Note that the screws are placed in the center of the lesion and are recessed below the cartilage surface.

In general, unless the lesion is very small, at least two fixation points are utilized to ensure compression and rotational stability. Screws are tightened until the fragment is compressed, but overtightening should be avoided to prevent fracture of the osteochondral fragment. All devices with a prominent head should be recessed beneath the cartilage surface to avoid further injury to the juxtaposing cartilage (Fig. 21-7). As has been mentioned, nonabsorbable screws

often require a second procedure for hardware removal; this affords the opportunity for a second look at the lesion site to verify healing.⁴³

Large, displaced fragments should be augmented with bone grafting. After the base of the lesion has been examined, and débridement and penetration of the lesion bed have been performed with microfracture awls, the fragment still may not sit congruently within the defect site. Cancellous autograft

can be harvested from Gerdy's tubercle on the ipsilateral limb. The bone graft is impacted into the defect site, and reduction of the fragment is reassessed until adequate reduction is achieved. Alternatively, small dowels of bone can be harvested arthroscopically using small-diameter instrumentation from the osteochondral autograft transfer systems. Once adequate reduction is achieved, the fragment is held in place with provisional K-wires until appropriate final fixation is achieved, as described earlier. Osteochondral plugs help to provide fixation and bone grafting across the lesion.

Postoperatively, all patients who have undergone arthroscopic or open reduction and internal fixation may heel-touch weight-bear and, when available, may utilize continuous passive motion machines for 4 to 6 hours per day.

Favorable outcomes have been reported after internal fixation of OCD fragments using absorbable and nonabsorbable screws. A study of Herbert compression screw fixation yielded 13 of 15 normal knees based on International Knee Documentation Committee (IKDC) clinical scoring, including 6 of 8 in skeletally mature patients.⁴¹ Kouzelis and colleagues treated patients with grade III and IV osteochondral lesions using reverse drilling and Herbert screw fixation and reported 90% normal or nearly normal results using IKDC scoring.³² Magnussen reported healing in 92% of patients undergoing open reduction and internal fixation (ORIF) of grade IV OCD lesions, including healing in all seven skeletally mature patients.⁴⁰ Similarly, Pascual Garrido and coworkers reported satisfaction in 13 of 15 adult OCD cases treated with arthroscopic reduction internal fixation.⁵⁰

Similar outcome scores have been reported with use of bioabsorbable screw, nail, and pin fixation. Nagamatsu and associates used fixation with bioabsorbable poly-L-lactide (PLLA) pins and showed 100% union and a clinical score of good (4/8) or excellent (4/8) in all patients.⁴⁸ Good and excellent clinical results were also achieved in all 8 patients undergoing fixation with PLLA nails for OCD.¹⁷ Weckstrom and colleagues compared bioabsorbable nails and pins in 30 patients with AOCD and showed significantly better fixation with nails (73% good to excellent) versus pins (35% good to excellent), suggesting that the barbs and the head of the nail allow for increased compression and rigid fixation.⁵⁷

Summary of Author's Preferred Treatment Method

The method of fixation is based largely on the surgeon's preference because no specific treatment has produced far

superior outcomes. We prefer two to three partially threaded cannulated screws with a second-look arthroscopy to remove the hardware and verify defect healing at 6 to 8 weeks. Bioabsorbable screws are also an option, especially when only one screw is needed for adequate stabilization of a macroscopically stable lesion, as is often seen with the early diagnosis and treatment of JOCD.

RESTORATIVE PROCEDURES

Restorative procedures attempt to replace damaged articular cartilage with hyaline or hyaline-like tissue.³⁴ These techniques should be considered as the next option if the patient has failed reparative treatments and presents with recurrent joint effusion, pain, and reduced range of motion. Multiple restorative techniques can be used for the treatment of OCD; however, the treatment algorithm should start with the least invasive options and progress to the more invasive options.

Marrow Stimulation (Microfracture)

Microfracture involves production of tiny fractures in the subchondral bone, allowing an influx of pluripotent stem cells from the marrow into the defect site and forming a superclot. The presence of pluripotent cells allows differentiation and results in the production of fibrocartilage.⁵⁴ Microfracture is indicated in patients with a small, localized cartilage defect, typically measuring less than 4 cm² (Fig. 21-8). Postoperatively, rehabilitation requires 6 weeks of non-weight bearing with use of continuous passive motion (CPM) for 6 hours a day.

Gudas and colleagues randomized patients with posttraumatic, symptomatic full-thickness cartilage lesions (56%) and OCD lesions (44%) to treatment with microfracture or osteochondral autograft transplantation (OAT). Clinical outcomes were significantly worse for the microfracture group, and the authors noted that whether treated with microfracture or OAT, patients with OCD had worse outcomes than those with full-thickness cartilage defects.²⁴ Another similarly conducted study by Knutsen and coworkers randomized femoral condyle (28% with OCD lesions) cartilage defects to treatment with microfracture or autologous chondrocyte implantation. Both groups demonstrated satisfactory results in 77% of patients at 5 years, with younger patients having better results in both groups. Overall, microfracture should be considered as a first-line treatment, especially in the setting of fragment removal with shallow defects

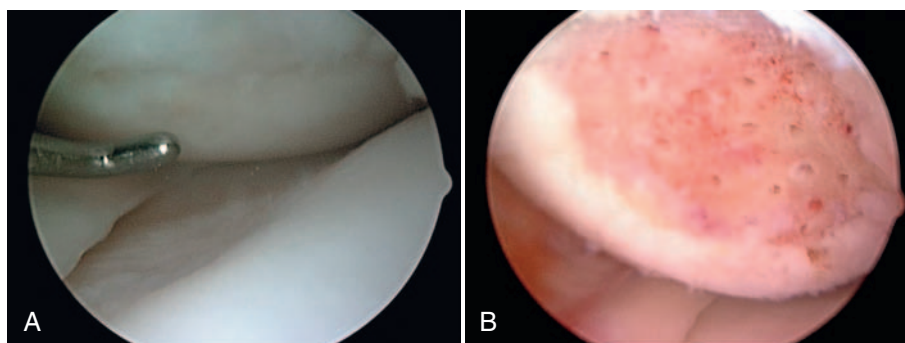


Figure 21-8. A, Osteochondritis dissecans (OCD) lesion of the femoral condyle. B, Treatment with microfracture.

that are relatively small. Whether fragment removal and microfracture fares **≡** than fragment removal alone is not known, and we know little about which OCD lesions are optimal for initial microfracture treatment.³⁰

Osteochondral Autograft Transplantation

In situations where the underlying subchondral bone integrity cannot support microfracture, osteochondral autograft transplantation (OAT) can be considered. The OAT procedure involves transplantation of osteochondral tissue from a low-weight-bearing region, such as the area just above the intercondylar notch or the lateral edge of the trochlea, with insertion of the plug into the defect.⁵² A single autograft plug is preferred for defects smaller than 1 cm²; however, some authors perform mosaicplasty with multiple smaller plugs for larger defects.

Good clinical results have been reported with osteochondral autografts. Miniaci and associates have reported normal postoperative knee scores at 18 months for all 20 OCD patients (11 immature and 9 mature) treated with OAT used as a biologic splint placed through the unstable fragment into the defect bed. In addition, radiographic evidence obtained 6 months postoperatively demonstrated adequate healing.⁴⁶ Outerbridge used osteochondral plugs taken from the ipsilateral lateral patella to treat patients with large osteochondral defects. The authors noted that all patients had increased function, and 81% returned to a high level of function. However, use of OAT is limited to small lesions because of limited supplies and donor site morbidity.

Autologous Chondrocyte Implantation

With limited supplies and donor site morbidity associated with the OAT procedure, treatment for larger lesions requires a different technique. Autologous chondrocyte implantation (ACI) is ideal for large, isolated osteochondral defects

measuring up to 10 cm². This two-step procedure involves an initially healthy chondrocyte biopsy, performed arthroscopically with tissue extracted from the non-weight-bearing intercondylar notch region. Extracted cells are expanded in vitro over 4 to 6 weeks and then are reimplanted at the lesion site. At the time of implantation, defect preparation involves débridement of the calcified cartilage base and creation of vertical walls of healthy cartilage. A patch, periosteal, or synthetic collagen membrane is attached to the perimeter using absorbable sutures. The edges are sealed using fibrin glue, and in vitro cultured cells are injected beneath the patch^{14,45} (Fig. 21-9). As with microfracture, 6 weeks of non-weight bearing postoperatively and CPM are indicated for both OAT and ACI.

Peterson and colleagues evaluated 58 patients (60% JOCD and 40% AOCD) who underwent an ACI procedure. At 2- to 10-year follow-up, the authors reported the presence of repair tissue at the lesion site with good to excellent clinical outcomes in 91% of patients.⁵¹ As noted previously, Knutsen and coworkers reported 77% satisfactory results in patients with femoral condyle lesions treated with ACI.³⁰ In a large population of patients undergoing ACI, including 24% with OCD lesions, Bentley and associates reported 88% good to excellent outcomes based on clinical assessment.⁷ Krishnan and colleagues performed ACI using a collagen membrane to treat 37 OCD patients (27 JOCD and 9 AOCD).³³ Among patients with juvenile-onset OCD, 91% good to excellent outcomes were achieved in patients treated before skeletal maturity compared with 77% in those treated after skeletal maturity, suggesting that early treatment is optimal. Furthermore, adult-onset OCD patients had 44% good to excellent outcomes, and better clinical outcomes were seen in those with smaller (<6 cm²) lesions.

Defects deeper than 8 to 10 mm can still be treated with ACI, but concomitant or staged bone grafting is recommended. Prior to bone grafting, drilling through the bed following débridement allows appropriate blood flow into the defect, ensuring subsequent bone graft incorporation. When

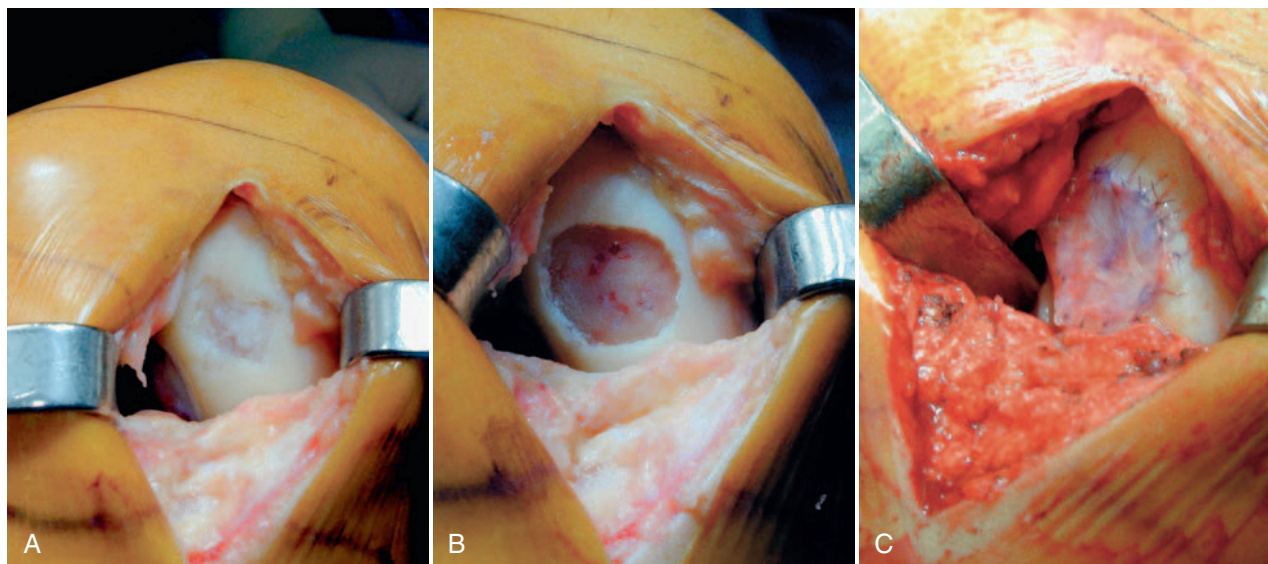


Figure 21-9. A, Lesion at the lateral aspect of the medial femoral condyle. B, Lesion prepared for autologous chondrocyte implantation (ACI). C, Completed ACI.

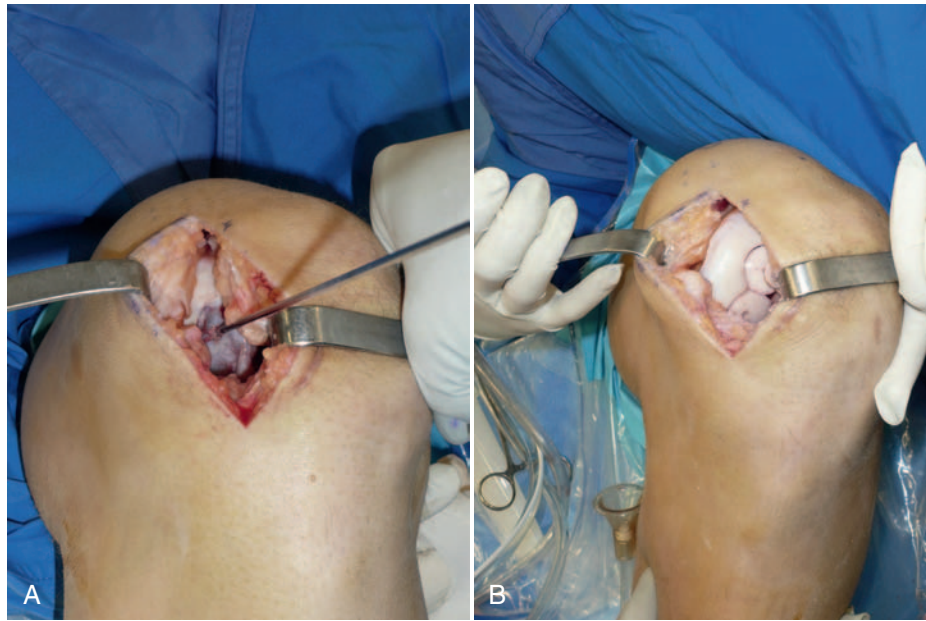


Figure 21-10. **A**, Large osteochondritis dissecans (OCD) lesion of the femoral condyle. **B**, Treatment with two osteochondral allograft plugs.

bone grafting is performed as a primary procedure in an effort to stage definitive treatment with ACI, most surgeons wait a minimum of 6 months to allow bone graft incorporation. Alternatively, a bilayer collagen membrane (periosteal “sandwich” technique) can be employed without the need to stage the ACI.^{6,12} A layer of periosteum or collagen membrane is used to seal the bone graft, and it is fixed with 6-0 Vicryl suture. A second layer is placed on top of the first and is similarly sewn; this is followed by injection of cultured cells between the two layers. Limited experience with this technique has been documented. Bartlett and associates reported 3 excellent results, 1 good, and 1 fair in 5 patients treated using ACI with a bilayer collagen membrane with bone graft.⁶

Osteochondral Allograft

Large OCD lesions may also be treated with osteochondral allograft (OA) transplantation.²³ The OA graft provides the ability to resurface larger and deeper defects with mature hyaline cartilage and addresses the underlying subchondral bone deficiency, which is a hallmark of OCD. The donor tissue is generally fashioned in a cylindrical plug matching the diameter of the initial lesion (Fig. 21-10). To ensure proper fixation, bioabsorbable compression screws or helical variable pitch titanium screws can be used. Postoperative rehabilitation is similar to that utilized following OAT or ACI.

It has been reported that fresh OA graft transplantation provides good to excellent clinical outcomes with long-term follow-up. Garrett and coworkers presented a series of AOCD lesions of the femoral condyle, reporting 94% clinical success at a mean follow-up of 3 years.²¹ McCulloch and associates, in 25 patients with full-thickness defects including 6 OCD lesions, presented an 84% success rate.⁴⁴ In a large study of 66 OCD lesions in 64 patients, treatment with a fresh OA yielded good to excellent results in 72% of patients. Overall, treatment of OCD with an OA graft can result in subjective

improvement in 75% to 85% of patients, as supported by long-term follow-up.²⁹

CONCLUSIONS

Adult OCD of the knee is a challenging problem that results in poor outcomes without surgical intervention once patients present with symptoms. Timely diagnosis can prevent compromise of the articular cartilage and can maximize the successful outcome of restorative procedures. Several surgical treatments have been used to treat OCD lesions. Reestablishment of the joint surface by improving blood supply via drilling or internal fixation is the primary goal of osteochondral fragment preservation. When the symptomatic fragment is not suitable for preservation, cartilage restoration techniques should be considered as an option. The overall goal for the treatment of adult OCD lesions is to relieve pain, restore function, and prevent development of secondary osteoarthritis.

KEY REFERENCES

- Adachi N, Deie M, Nakamae A, et al: Functional and radiographic outcome of stable juvenile osteochondritis dissecans of the knee treated with retroarticular drilling without bone grafting. *Arthroscopy* 25:145–152, 2009.
- Alford JW, Cole BJ: Cartilage restoration, part 2: techniques, outcomes, and future directions. *Am J Sports Med* 33:443–460, 2005.
- Bartlett W, Gooding CR, Carrington RW, et al: Autologous chondrocyte implantation at the knee using a bilayer collagen membrane with bone graft: a preliminary report. *J Bone Joint Surg Br* 87:330–332, 2005.
- Day JB, Gillogly SD: Autologous chondrocyte implantation in the knee. In Cole BJ, Sekiya JK, editors: *Surgical techniques of the shoulder, elbow, and knee in sports medicine*, Philadelphia, 2008, Saunders Elsevier, pp 559–566.
- Gomoll AH, Flik KR, Hayden JK, et al: Internal fixation of unstable Cahill Type-2C osteochondritis dissecans lesions of the knee in adolescent patients. *Orthopedics* 30:487–490, 2007.
- Gudas R, Stankevicius E, Monastyreckiene E, et al: Osteochondral autologous transplantation versus microfracture for the treatment of articular cartilage defects in the knee joint in athletes. *Knee Surg Sports Traumatol Arthrosc* 14:834–842, 2006.

- Kang RW, Gomoll AH, Cole BJ: Osteochondral allografting in the knee. In Cole BJ, Sekiya JK, editors: *Surgical techniques of the shoulder, elbow, and knee in sports medicine*, Philadelphia, 2008, Saunders Elsevier, pp 549–557.
- Kouzelis A, Plessas S, Papadopoulos AX, et al: Herbert screw fixation and reverse guided drillings, for treatment of types III and IV osteochondritis dissecans. *Knee Surg Sports Traumatol Arthrosc* 14:70–75, 2006.
- Lewis PB, McCarty LP 3rd, Kang RW, et al: Basic science and treatment options for articular cartilage injuries. *J Orthop Sports Phys Ther* 36:717–727, 2006.
- McCarty LP III: Primary repair of osteochondritis dissecans in the knee. In Cole BJ, Sekiya JK, editors: *Surgical techniques of the shoulder, elbow, and knee in sports medicine*, Philadelphia, 2008, Saunders Elsevier, pp 517–526.
- McCulloch PC, Kang RW, Sobhy MH, et al: Prospective evaluation of prolonged fresh osteochondral allograft transplantation of the femoral condyle: minimum 2-year follow-up. *Am J Sports Med* 35:411–420, 2007.
- Pascual-Garrido C, Friel NA, Kirk SS, et al: Midterm results of surgical treatment for adult osteochondritis dissecans of the knee. *Am J Sports Med* 37(Suppl 1):125S–130S, 2009.
- Peterson L, Minas T, Brittberg M, et al: Treatment of osteochondritis dissecans of the knee with autologous chondrocyte transplantation: results at two to ten years. *J Bone Joint Surg Am* 85(Suppl 2):17–24, 2003.
- Rabalais RD, Swan KG Jr, McCarty E: Osteochondral autograft for cartilage lesions of the knee. In Cole BJ, Sekiya J, editors: *Surgical techniques of the shoulder, elbow, and knee in sports medicine*, Philadelphia, 2008, Saunders Elsevier, pp 539–548.
- Steadman JR, Rodkey WG, Briggs KK: Microfracture technique in the knee. In Cole BJ, Sekiya JK, editors: *Surgical techniques of the shoulder, elbow, and knee in sports medicine*, Philadelphia, 2008, Saunders Elsevier, pp 509–515.

Full references for this chapter can be found on www.expertconsult.com.

REFERENCES

- Adachi N, Deie M, Nakamae A, et al: Functional and radiographic outcome of stable juvenile osteochondritis dissecans of the knee treated with retroarticular drilling without bone grafting. *Arthroscopy* 25:145–152, 2009.
- Aichroth P: Osteochondritis dissecans of the knee: a clinical survey. *J Bone Joint Surg Br* 53:440–447, 1971.
- Alford JW, Cole BJ: Cartilage restoration, part 2: techniques, outcomes, and future directions. *Am J Sports Med* 33:443–460, 2005.
- Anderson AF, Pagnani MJ: Osteochondritis dissecans of the femoral condyles: long-term results of excision of the fragment. *Am J Sports Med* 25:830–834, 1997.
- Anderson AF, Richards DB, Pagnani MJ, et al: Antegrade drilling for osteochondritis dissecans of the knee. *Arthroscopy* 13:319–324, 1997.
- Bartlett W, Gooding CR, Carrington RW, et al: Autologous chondrocyte implantation at the knee using a bilayer collagen membrane with bone graft: a preliminary report. *J Bone Joint Surg Br* 87:330–332, 2005.
- Bentley G, Biant LC, Carrington RW, et al: A prospective, randomised comparison of autologous chondrocyte implantation versus mosaicplasty for osteochondral defects in the knee. *J Bone Joint Surg Br* 85:223–230, 2003.
- Bradley J, Dandy DJ: Results of drilling osteochondritis dissecans before skeletal maturity. *J Bone Joint Surg Br* 71:642–644, 1989.
- Cahill BR: Osteochondritis dissecans of the knee: treatment of juvenile and adult forms. *J Am Acad Orthop Surg* 3:237–247, 1995.
- Cahill BR, Phillips MR, Navarro R: The results of conservative management of juvenile osteochondritis dissecans using joint scintigraphy: a prospective study. *Am J Sports Med* 17:601–605, 1989; discussion 605–606.
- Cain EL, Clancy WG: Treatment algorithm for osteochondral injuries of the knee. *Clin Sports Med* 20:321–342, 2001.
- Cole BJ, Lee SJ: Complex knee reconstruction: articular cartilage treatment options. *Arthroscopy* 19(Suppl 1):1–10, 2003.
- Crawford EJ, Emery RJ, Aichroth PM: Stable osteochondritis dissecans—does the lesion unite? *J Bone Joint Surg Br* 72:320, 1990.
- Day JB, Gillogly SD: Autologous chondrocyte implantation in the knee. In Cole BJ, Sekiya JK, editors: *Surgical techniques of the shoulder, elbow, and knee in sports medicine*, Philadelphia, 2008, Saunders Elsevier, pp 559–566.
- De Smet AA, Fisher DR, Graf BK, et al: Osteochondritis dissecans of the knee: value of MR imaging in determining lesion stability and the presence of articular cartilage defects. *AJR Am J Roentgenol* 155:549–553, 1990.
- De Smet AA, Ilahi OA, Graf BK: Untreated osteochondritis dissecans of the femoral condyles: prediction of patient outcome using radiographic and MR findings. *Skeletal Radiol* 26:463–467, 1997.
- Dines JS, Fealy S, Potter HG, et al: Outcomes of osteochondral lesions of the knee repaired with a bioabsorbable device. *Arthroscopy* 24:62–68, 2008.
- Donaldson LD, Wojtyls EM: Extraarticular drilling for stable osteochondritis dissecans in the skeletally immature knee. *J Pediatr Orthop* 28:831–835, 2008.
- Ewing JW, Voto SJ: Arthroscopic surgical management of osteochondritis dissecans of the knee. *Arthroscopy* 4:37–40, 1988.
- Flynn JM, Kocher MS, Ganley TJ: Osteochondritis dissecans of the knee. *J Pediatr Orthop* 24:434–443, 2004.
- Garrett JC: Fresh osteochondral allografts for treatment of articular defects in osteochondritis dissecans of the lateral femoral condyle in adults. *Clin Orthop Relat Res* 303:33–37, 1994.
- Gomoll AH, Flik KR, Hayden JK, et al: Internal fixation of unstable Cahill Type-2C osteochondritis dissecans lesions of the knee in adolescent patients. *Orthopedics* 30:487–490, 2007.
- Gross AE: Repair of cartilage defects in the knee. *J Knee Surg* 15:167–169, 2002.
- Gudas R, Stankevicius E, Monastyreckiene E, et al: Osteochondral autologous transplantation versus microfracture for the treatment of articular cartilage defects in the knee joint in athletes. *Knee Surg Sports Traumatol Arthrosc* 14:834–842, 2006.
- Guhl JF: Arthroscopic treatment of osteochondritis dissecans. *Clin Orthop Relat Res* 167:65–74, 1982.
- Harding WG, 3rd: Diagnosis of osteochondritis dissecans of the femoral condyles: the value of the lateral x-ray view. *Clin Orthop Relat Res* 123:25–26, 1977.
- Hughston JC, Hergenroeder PT, Courtenay BG: Osteochondritis dissecans of the femoral condyles. *J Bone Joint Surg Am* 66:1340–1348, 1984.
- Jani MM, Parker RD: Internal fixation devices for the treatment of unstable osteochondritis dissecans and chondral lesions. *Oper Tech Sports Med* 12:170–175, 2004.
- Kang RW, Gomoll AH, Cole BJ: Osteochondral allografting in the knee. In Cole BJ, Sekiya JK, editors: *Surgical techniques of the shoulder, elbow, and knee in sports medicine*, Philadelphia, 2008, Saunders Elsevier, pp 549–557.
- Knutsen G, Drogset JO, Engebretsen L, et al: A randomized trial comparing autologous chondrocyte implantation with microfracture: findings at five years. *J Bone Joint Surg Am* 89:2105–2112, 2007.
- Kocher MS, Micheli LJ, Yaniv M, et al: Functional and radiographic outcome of juvenile osteochondritis dissecans of the knee treated with transarticular arthroscopic drilling. *Am J Sports Med* 29:562–566, 2001.
- Kouzelis A, Plessas S, Papadopoulos AX, et al: Herbert screw fixation and reverse guided drillings, for treatment of types III and IV osteochondritis dissecans. *Knee Surg Sports Traumatol Arthrosc* 14:70–75, 2006.
- Krishnan SP, Skinner JA, Carrington RW, et al: Collagen-covered autologous chondrocyte implantation for osteochondritis dissecans of the knee: two- to seven-year results. *J Bone Joint Surg Br* 88:203–205, 2006.
- Lewis PB, McCarty LP, 3rd, Kang RW, et al: Basic science and treatment options for articular cartilage injuries. *J Orthop Sports Phys Ther* 36:717–727, 2006.
- Linden B: Osteochondritis dissecans of the femoral condyles: a long-term follow-up study. *J Bone Joint Surg Am* 59:769–776, 1977.
- Linden B: The incidence of osteochondritis dissecans in the condyles of the femur. *Acta Orthop Scand* 47:664–667, 1976.
- Loredo R, Sanders TG: Imaging of osteochondral injuries. *Clin Sports Med* 20:249–278, 2001.
- Louisia S, Beaufile P, Katabi M, et al: Transchondral drilling for osteochondritis dissecans of the medial condyle of the knee. *Knee Surg Sports Traumatol Arthrosc* 11:33–39, 2003.
- Mackie T, Wilkins RM: Case report: osteochondritis dissecans in twins: treatment with fresh osteochondral grafts. *Clin Orthop Relat Res* 468:893–897, 2010.
- Magnussen RA, Carey JL, Spindler KP: Does operative fixation of an osteochondritis dissecans loose body result in healing and long-term maintenance of knee function? *Am J Sports Med* 37:754–759, 2009.
- Makino A, Muscolo DL, Puigdevall M, et al: Arthroscopic fixation of osteochondritis dissecans of the knee: clinical, magnetic resonance imaging, and arthroscopic follow-up. *Am J Sports Med* 33:1499–1504, 2005.
- Mandelbaum BR, Browne JE, Fu F, et al: Articular cartilage lesions of the knee. *Am J Sports Med* 26:853–861, 1998.
- McCarty LP, III: Primary repair of osteochondritis dissecans in the knee. In Cole BJ, Sekiya JK, editors: *Surgical techniques of the shoulder, elbow, and knee in sports medicine*, Philadelphia, 2008, Saunders Elsevier, pp 517–526.
- McCulloch PC, Kang RW, Sobhy MH, et al: Prospective evaluation of prolonged fresh osteochondral allograft transplantation of the femoral condyle: minimum 2-year follow-up. *Am J Sports Med* 35:411–420, 2007.
- Minas T, Peterson L: Advanced techniques in autologous chondrocyte transplantation. *Clin Sports Med* 18:13–44, v–vi, 1999.
- Miniaci A, Tytherleigh-Strong G: Fixation of unstable osteochondritis dissecans lesions of the knee using arthroscopic autogenous osteochondral grafting (mosaicplasty). *Arthroscopy* 23:845–851, 2007.
- Morelli M, Poitras P, Grimes V, et al: Comparison of the stability of various internal fixators used in the treatment of osteochondritis dissecans—a mechanical model. *J Orthop Res* 25:495–500, 2007.
- Nakagawa T, Kurosawa H, Ikeda H, et al: Internal fixation for osteochondritis dissecans of the knee. *Knee Surg Sports Traumatol Arthrosc* 13:317–322, 2005.
- Nelson DW, DiPaola J, Colville M, et al: Osteochondritis dissecans of the talus and knee: prospective comparison of MR and arthroscopic classifications. *J Comput Assist Tomogr* 14:804–808, 1990.
- Pascual-Garrido C, Friel NA, Kirk SS, et al: Midterm results of surgical treatment for adult osteochondritis dissecans of the knee. *Am J Sports Med* 37(Suppl 1):125S–130S, 2009.
- Peterson L, Minas T, Brittberg M, et al: Treatment of osteochondritis dissecans of the knee with autologous chondrocyte transplantation: results at two to ten years. *J Bone Joint Surg Am* 85(Suppl 2):17–24, 2003.

52. Rabalais RD, Swan KG, Jr, McCarty E: Osteochondral autograft for cartilage lesions of the knee. In Cole BJ, Sekiya JK, editors: *Surgical techniques of the shoulder, elbow, and knee in sports medicine*, Philadelphia, 2008, Saunders Elsevier, pp 539–548.
53. Schenck RC, Jr, Goodnight JM: Osteochondritis dissecans. *J Bone Joint Surg Am* 78:439–456, 1996.
54. Steadman JR, Rodkey WG, Briggs KK: Microfracture technique in the knee. In Cole BJ, Sekiya JK, editors: *Surgical techniques of the shoulder, elbow, and knee in sports medicine*, Philadelphia, 2008, Saunders Elsevier, pp 509–515.
55. Steinhagen J, Bruns J, Deuretzbacher G, et al: Treatment of osteochondritis dissecans of the femoral condyle with autologous bone grafts and matrix-supported autologous chondrocytes. *Int Orthop* 34:819–825, 2010.
56. Twyman RS, Desai K, Aichroth PM: Osteochondritis dissecans of the knee: a long-term study. *J Bone Joint Surg Br* 73:461–464, 1991.
57. Weckstrom M, Parviainen M, Kiuru MJ, et al: Comparison of bioabsorbable pins and nails in the fixation of adult osteochondritis dissecans fragments of the knee: an outcome of 30 knees. *Am J Sports Med* 35:1467–1476, 2007.
58. Wright RW, McLean M, Matava MJ, et al: Osteochondritis dissecans of the knee: long-term results of excision of the fragment. *Clin Orthop Relat Res* 424:239–243, 2004.

AUTHOR QUERY FORM

Dear Author

During the preparation of your manuscript for publication, the questions listed below have arisen. Please attend to these matters and return this form with your proof.

Many thanks for your assistance.

Query References	Query	Remarks
1	AU: Please clarify what this means.	