

FRESH OSTEOCHONDRAL ALLOGRAFT TRANSPLANTATION FOR ARTICULAR CARTILAGE DEFECTS

JEFF A. FOX, MD, KEVIN B. FREEDMAN, MD, MSCE, STEPHEN J. LEE, BA,
and BRIAN J. COLE, MD, MBA

Fresh osteochondral allografts represent an effective solution for treatment of isolated cartilage defects. The key to successful allograft transplantation is cell viability, with current methods of storage up to 42 days while maintaining acceptable levels of cell viability. Ongoing research and investigations into ways of extending storage time will result in greater availability of osteochondral allografts and pave the road for use of this technique in other joints (ie, shoulder, elbow, wrist, and talus). This article describes the indications, preoperative planning, operative technique, and postoperative care for this procedure.

KEY WORDS: fresh osteochondral allograft, chondrocyte viability, articular cartilage
Copyright 2002, Elsevier Science (USA). All rights reserved.

Fresh osteochondral allografts were first used in 1908 by Lexer¹ to restore the articular surface. He reported a 50% success rate, with good function of the allograft after incorporation.² In the 1940s and 1950s, it was thought that allografts could represent a biological alternative to total joint arthroplasty in young patients with limited articular cartilage damage.³ In the 1970s, several investigators reported moderate success with massive frozen and cryopreserved osteochondral allografts used for limb salvage after resection of bone tumors.^{4,5} Due to increased graft availability, fresh osteochondral allografts are being used more frequently to treat isolated articular cartilage and osteoarticular defects.

GRAFT SELECTION

Chondrocyte viability is the principle determinate for osteochondral allograft selection, as frozen grafts have demonstrated decreased cell viability, deterioration in the form of fissuring or fibrosis, and progressive breakdown.⁶ The definition of a *fresh graft* varies from those that are immediately implanted to those that are implanted at up to 42 days, depending upon the preservation methodology. Chondrocytes survive without a significant immune response, because they are believed to be immunologically privileged.^{7,8} The tissue must be retrieved, handled, and processed in strict accordance with the criteria of the

American Association of Tissue Banks.⁹ The risk of disease transmission with allograft tissue is extremely low due to current screening techniques; however, the risk cannot be completely eliminated.¹⁰⁻¹² The risk of human immunodeficiency virus (HIV) transmission from bone allografts has been estimated to be 1 in 1,667,600 when all screening criteria are met.¹³

INDICATIONS

Typically, osteochondral allografts are indicated in patients who have larger, deeper, and more extensive chondral or osteochondral lesions. Patient age is a relative consideration. Skeletal maturity (ie, growth plate closure) is required; the upper age limit is typically around 50 to 55 years, most commonly due to the presence of frank osteoarthritis, which is more appropriately treated with arthroplasty. Pain and symptoms should correlate with the location of the cartilage lesion. Optimal outcomes are achieved when a single articular defect of greater than 2 cm² (ie, femoral condyle, trochlea, patella) in 1 compartment is replaced, the ligaments are competent, menisci are present, and no angular deformities exist.¹⁴⁻¹⁶

For many articular cartilage lesions, both osteochondral allografts and autologous chondrocyte implantations are viable options. In making this difficult decision, we currently use several clinical parameters. In older, lower demand patients with large, relatively deep lesions (ie, deeper than 6 to 8 mm of subchondral bone loss), we prefer osteochondral allografts. As experience is increasing, bipolar allograft reconstruction may prove to be a viable option in select patients. Alternatively, in younger, higher demand patients with medium to large size lesions involving minimal bone loss, we typically recommend autologous chondrocyte implantation.

Contraindications include inflammatory arthropathy, uncorrected ligamentous instability, uncorrected mal-

From the Central States Orthopedic Specialists, Tulsa, OK, and Department of Orthopedic Surgery, Rush-Presbyterian-St. Luke's Medical Center, Chicago IL.

Address reprint requests to Brian J. Cole, MD, MBA, Medical Director, Rush Cartilage Restoration Center, Associate Professor, Department of Orthopedic Surgery and Anatomy (Conjoint), Rush-Presbyterian-St. Luke's Medical Center, 1725 W Harrison St, Suite 1063, Chicago IL, 60612.

Copyright 2002, Elsevier Science (USA). All rights reserved.

1060-1872/02/1003-0010\$35.00/0

doi:10.1053/otsm.2002.35866

alignment, diffuse arthrosis within the knee joint, diffuse avascular necrosis, and uncorrected meniscus deficiency.

PREOPERATIVE PLANNING

All associated knee pathology must be thoroughly evaluated and addressed. Ligamentous instability, malalignment, or meniscal deficiencies are not absolute contraindications to performing an osteochondral allograft. However, this pathology must be addressed prior to implantation or at the time of surgery. Realignment procedures are performed when even a few degrees of malalignment toward the involved compartment exist compared to the contralateral limb. Radiographs, including a 45° flexion posterior to anterior weight bearing radiograph and mechanical axis views, should be obtained to assess the degree of arthritic change and alignment. Preoperative radiographs are also used to match the size of the recipient with the donor. Precise matching of the geometry of the donor and recipient articular surface is necessary to ensure long-term survival. The authors measure the bony width of the tibial plateau on the anteroposterior radiograph taken 1 cm below the articular surface, after correcting for magnification, in addition to measuring the femoral condyle width and defect size. Specific details regarding the defect location, size, depth, degree of containment, and associated pathology are typically obtained at the arthroscopy that commonly leads to the indication for osteochondral allograft transplantation.

OPERATIVE TECHNIQUE

Setup

The patient is positioned supine on the table with a tourniquet around the thigh. The leg is draped free.

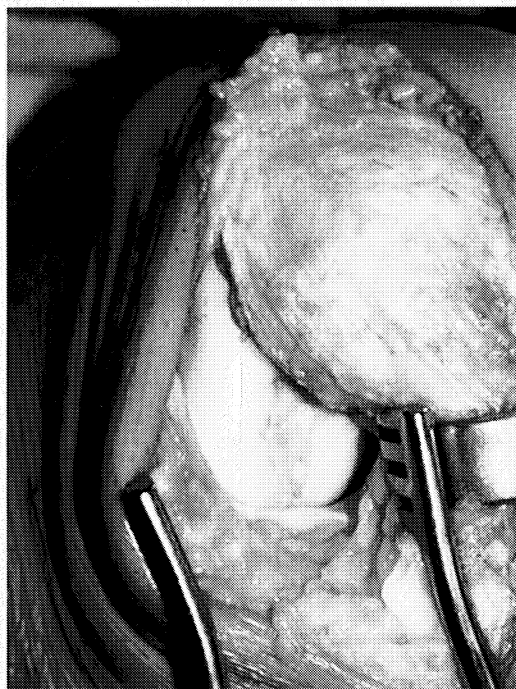


Fig 1. Example of a femoral condyle articular cartilage lesion having failed microfracture technique in a 38-year-old male.

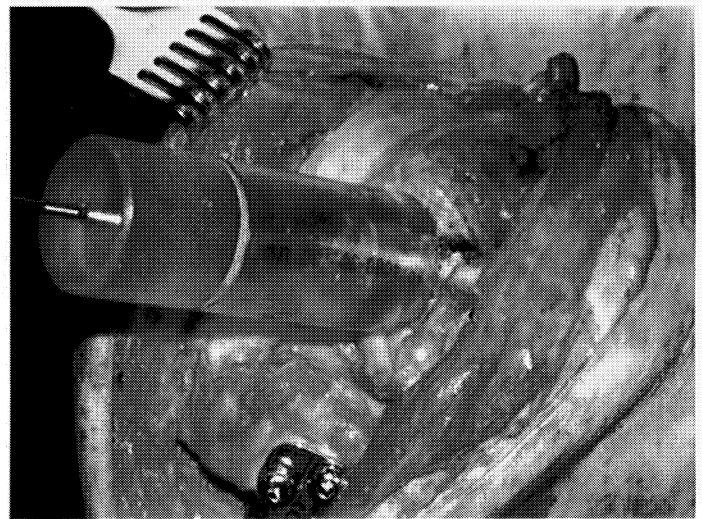


Fig 2. Graft size is determined using a series of cannulated sizing cylinders placed over a centering guide pin drilled within the center of the defect.

Preparing the Cartilage Lesion

Diagnostic arthroscopy is usually unnecessary, since this was usually performed as part of the preoperative planning. If questions remain regarding coexisting pathology, a diagnostic arthroscopy is performed to determine the definitive management of the patient's pathology. Exposure of the lesion can be performed with a standard midline knee arthrotomy. However, in many cases, a medial or lateral peripatellar miniarthrotomy can be used to expose the lesion. The lesion is assessed to determine the graft shape that will best fit the defect (Fig 1). Whenever possible, an instrumentation system (Arthrex, Inc, Naples, FL) is used to create and harvest a circular graft. Because of the close tolerance between the donor plug and recipient socket that results from this technique, one can press fit the graft, eliminating the need for supplemental internal fixation. If the lesion is not amenable to a circular graft, a shell graft can be fashioned freehand, typically in a trapezoidal configuration that matches a hand-prepared defect bed using a motorized burr and oscillating saw with cold irrigation. Freehand sizing of a graft is more time-consuming and often requires fixation, as the fit is less precise.

The diameter of the defect is matched to the sizing cylinder (15, 18, 20, 25, 30, or 35 mm) that best incorporates the majority of the defect. Holding the sizing cylinder centered and perpendicular to the defect, a guide pin is drilled in the center of the lesion to a depth of 2 to 3 cm (Fig 2). While irrigating with normal saline, the cannulated counter bore is drilled over the pin to create a cylindrical defect to a depth of 8 to 10 mm (Fig 3). Bone depth is intentionally minimized, as the subchondral bone is known to be the most immunologic component of the composite graft. A sterile marking pen is used to mark the 12 o'clock position of the lesion to appropriately orient the donor plug, and the depth of the recipient lesion is measured in 4 quadrants to determine the exact depth of the final cut of the donor plug (Fig 4).

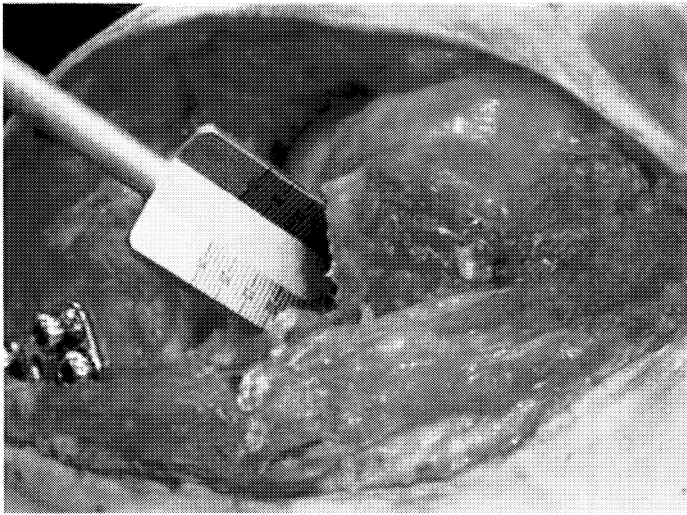


Fig 3. Under cold irrigation, a counter bore reamer is used to prepare the recipient defect socket.

Allograft Preparation

If an entire hemicondyle is made available, it is first sectioned to create a flat surface perpendicular to the proposed harvest site (Fig 5). The allograft is secured in the allograft workstation with 4 set screws (Fig 6). The bushing is secured such that the donor site matches the location and angle of the recipient site, as viewed from the side of the workstation using the sizing cylinder for orientation (Fig 7). While matching the location of the defect on the donor condyle is preferred, defects smaller than 2 cm² are easily matched from most regions of the hemicondyle. The 12 o'clock position of the donor graft is marked. While irrigating with normal saline, the donor graft is then drilled through its entire depth with a harvester, and the graft is extracted (Fig 8). A ruler is used to measure and mark the graft to match the graft depth to the 4 quadrants measured previously at the recipient site. Holding forceps are used to secure the allograft while it is irrigated and cut using an oscillating saw (Fig 9). To facilitate insertion, the

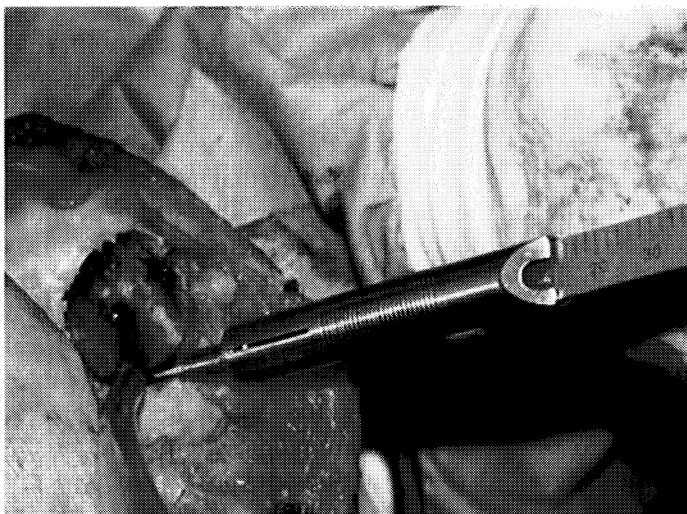


Fig 4. The depth of the recipient lesion is measured in 4 quadrants with measurements transferred to the graft prior to final preparation.



Fig 5. The hemicondyle is cut perpendicular to the proposed graft harvest site to allow it to sit anatomically within the holding jig.

edge of the allograft is slightly beveled with a rongeur (Fig 10). Prior to insertion, the graft is pulsatile lavaged to remove blood and bone marrow elements to reduce the chance of disease transmission and graft immunogenicity.¹⁷

Graft Implantation

A calibrated dilator is inserted in the recipient socket to dilate the socket an additional 0.5 mm. The graft is press fit into the socket by hand after carefully aligning the 4 quadrants to the recipient site (Fig 11). Recent studies have demonstrated chondrocyte death in response to mechanical compression.¹⁸ Thus, if the graft requires impaction to fully seat it, an oversized tamp may be used with gentle tapping with a mallet. Additional fixation is typically unnecessary. However, if the graft is particularly large, fixation can be achieved with bioabsorbable pins or metal screws. While bioabsorbable devices avoid the need for a second surgery for removal, they currently lack the ability to compress the graft. When necessary, we prefer a head-




Fig 6. The condyle is secured in the jig.




Fig 7. The orientation of the bushing is adjusted and then secured, while visualizing the sizing cylinder relative to the graft from the side of the jig.

less screw (Acumed, Beaverton, OR), which provides excellent compression but may need to be removed at a later date if not properly recessed.

The wound is closed in the usual fashion, and the patient is placed in a hinged knee immobilizer with a cold therapy unit applied over a thin sterile dressing. Typically, patients are discharged the day of surgery unless other procedures are performed simultaneously, such as osteotomy, ligament reconstruction, or allograft meniscus transplantation.

POSTOPERATIVE CARE

Restricted weight bearing is recommended for at least 8 weeks to protect the cartilage surface and to minimize the chance for subchondral collapse during the creeping substitution phase of graft healing. Because these grafts are equivalent to a "shell allograft" with minimum bone thickness, the risk of graft collapse is relatively low. Continuous




Fig 8. The cylindrical coring reamer is used to harvest the donor graft, while using irrigation solution to minimize thermal necrosis of the graft.

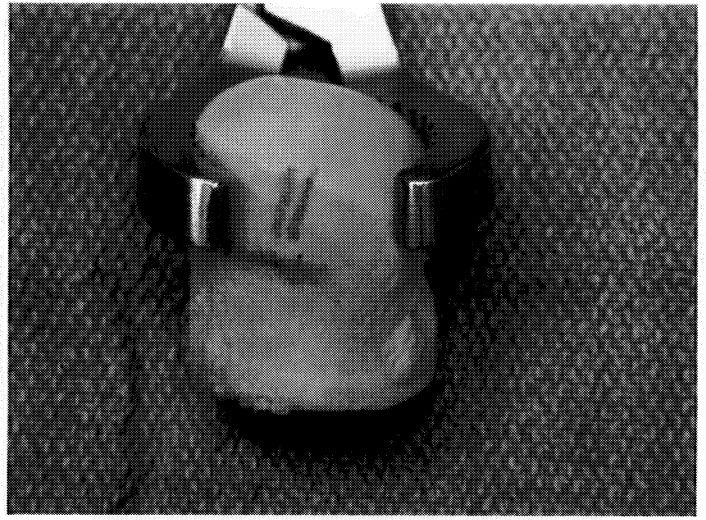


Fig 9. A serrated holding forceps secures the graft with markings in place transferred from the recipient site to indicate the proper depth to cut the graft.

passive motion is used for 6 to 8 hours per day at 1 cycle per minute, starting at 45° and advancing to 90° as tolerated for the first 4 to 6 weeks. Return to normal activities of daily living and light sport activity is considered at 4 to 6 months. In general, high-impact sports are not recommended after osteochondral allografting for large articular cartilage lesions due to the theoretical risk of graft collapse and potential deterioration in the long-term survival of the graft.^{19,20}

RESULTS

Between May 1999 and May 2002, the senior author (B.J.C.) performed osteochondral allograft reconstruction in 18 patients (average age, 38 years; range, 32-42 years). The average follow-up period is 15.3 months (range, 2-32 months). Eleven patients had concomitant procedures, including 3 with meniscus transplants and 4 with osteotomies. Using the Rush Cartilage Restoration Center rating



Fig 10. A pituitary rongeur is used to slightly bevel the edges of the graft to facilitate placement within the recipient bed.

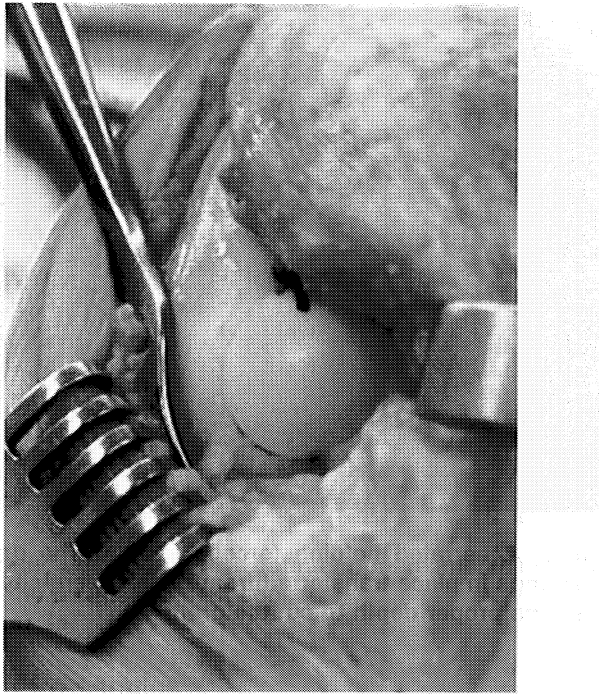


Fig 11. The allograft is implanted by hand after proper orientation is obtained to best match the convexity of the femoral condyle.

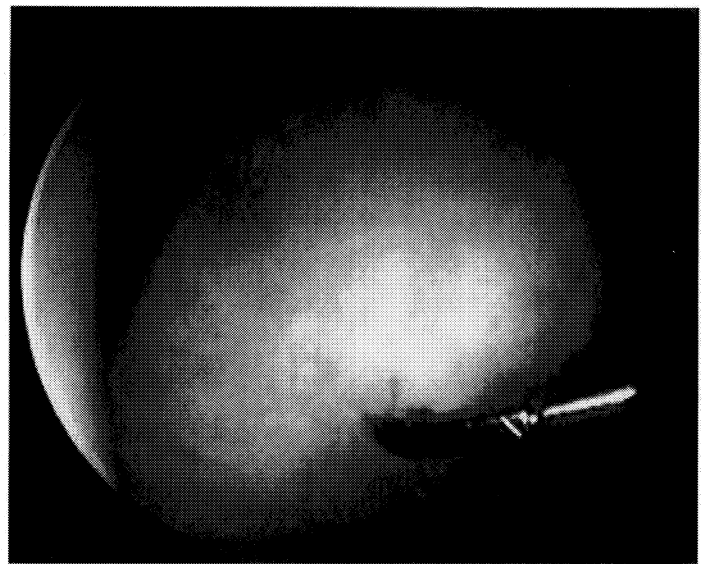


Fig 12. Arthroscopic view of a dislodged and degenerated osteochondral allograft from the left knee of an 18-year-old male with bilateral osteochondritis dissecans of the medial femoral condyles. The patient was initially treated with a unilateral opening wedge osteotomy on the right knee at the time of osteochondral grafting and isolated osteochondral grafting of the left knee without osteotomy. The left knee osteochondral graft failed early, presumably related to bio-mechanical overload.

system, there were 11 excellent, 3 good, 3 fair, and 1 poor results.

Other studies have looked at long-term survivorship to determine the durability of osteochondral allografts. Ghavazi et al²¹ demonstrated 95% survival at 5 years, 71% at 10 years, and 66% at 20 years. McDermott et al¹⁴ found a 75% success rate at 5 years; at 10 years the success rate

was 64%, and at 14 years it fell to 63%. Beaver et al¹⁶ reviewed 92 knees with posttraumatic osteochondral defects treated with fresh osteochondral allografts. At 5 years, there was a 75% success rate. At 10 years, there was a 64% success rate that fell to 63% at 14 years.

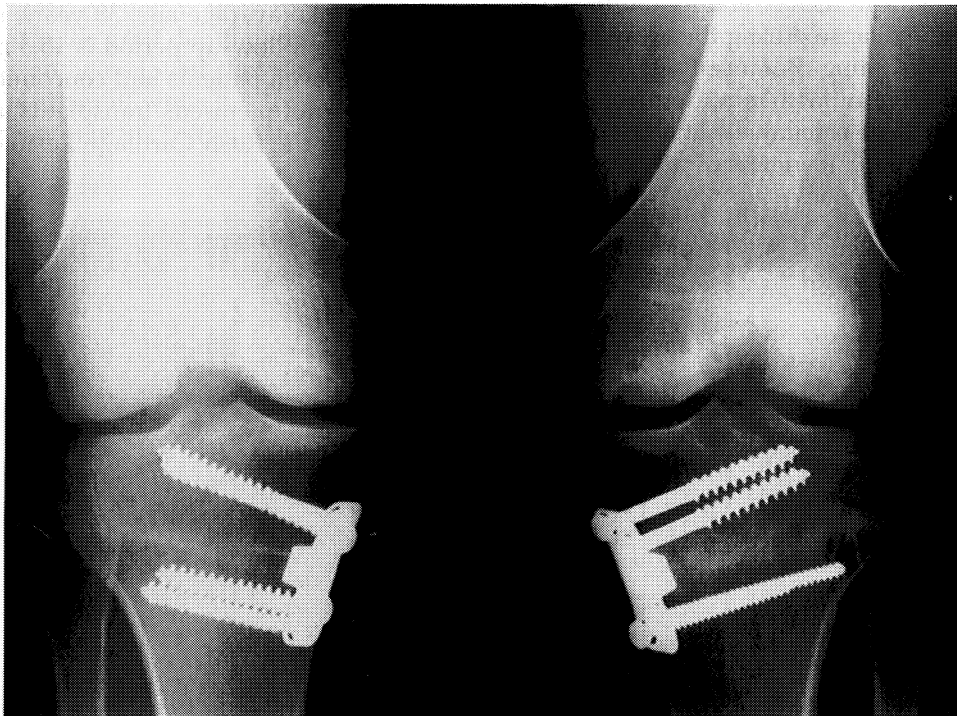


Fig 13. One-year radiograph following revision allograft surgery and osteotomy of the left knee and 2-year radiograph of the right knee following osteotomy and osteochondral grafting of the same patient in Figure 12, demonstrating bilateral healed opening wedge osteotomies and well-incorporated osteochondral allografts of the medial femoral condyles.

COMPLICATIONS

Potential complications include infections, arthrofibrosis, and graft failure. Graft failure occurs both early and late and is often due to biologic and biomechanical considerations (Figs 12 and 13). Early failures include the failure of graft incorporation or early graft collapse/fragmentation. Late failures can be due to graft collapse/fragmentation and progressive joint space narrowing.

DISCUSSION

Fresh osteoarticular allografts represent a viable solution to treat articular cartilage disease. Relatively large defects can be treated with a single-stage procedure. At present, the knee is the most commonly treated joint in a patient group that is typically relatively young with isolated articular or osteoarticular cartilage disease. With appropriate indications and increased graft availability, this treatment option can be readily extended to other joints, including the shoulder, elbow, wrist, and talus. The key to successful allograft transplantation is cell viability. Kwan et al²² has demonstrated preservation of the histological, biomechanical, and chemical characteristics of articular cartilage for up to 28 days. Significant cell viability (ie, more than 65% to 80%) was also demonstrated by Cole et al²³ in a model evaluating 28-day specimens of canine fresh articular cartilage cultured with similar methodology used by tissue banks. After implantation, several studies have shown that the chondrocytes do survive. Czitrom et al²⁴ were the first to demonstrate the viability of articular cartilage in transplanted osteochondral allografts in humans. They demonstrated 69% to 99% cell viability and proteoglycan production in the biopsies of a small number of allografts 12 to 72 months after surgery. Correcting even minor degrees of malalignment when the mechanical axis falls through the affected compartment is currently recommended to improve patient outcomes.^{15,25}

CONCLUSION

The use of fresh osteochondral allografts for isolated articular cartilage lesions is an effective means of treating cartilage lesions. Excellent results can be obtained when the patient has normal or corrected malalignment, a stable knee, and a unipolar lesion. The risk for disease transmission from the allograft is low, but present. Ongoing investigations are exploring ways to extend the time that allografts can be stored and still maintain a high percentage of chondrocyte viability. Improved preservation techniques will make osteochondral allografts more readily available in the future. Osteochondral allograft transplantation provides an excellent option for single-stage treatment of chondral and osteochondral lesions with good long-term results.

REFERENCES

1. Lexer E: Substitution of whole or half Joints from freshly amputated extremities by free plastic operation. *Surg Gynecol Obstet* 6:601-607, 1908
2. Lexer E: Joint transplantations and arthroplasty. *Surg Gynecol Obstet* 40:782-809, 1925
3. Fitzpatrick PL, Morgan DA: Fresh osteochondral allografts: A 6-10-year review. *Aust N Z J Surg* 68:573-579, 1998
4. Volkov M: Allotransplantation of joints. *J Bone Joint Surg Br* 52:49-53, 1970
5. Parrish FF: Allograft replacement of all or part of the end of a long bone following excision of a tumor. *J Bone Joint Surg Am* 55:1-22, 1973
6. Garrett JC: Osteochondral allografts. *Instr Course Lect* 42:355-358, 1993
7. Langer F, Gross AE, Greaves MF: The auto-immunogenicity of articular cartilage. *Clin Exp Immunol* 12:31-37, 1972
8. Langer FC: The immunogenicity of fresh and frozen allogenic bone. *J Bone Joint Surg Am* 57A:216-220, 1975
9. Standards for Tissue Banking. McLean, VA, American Association of Tissue Banks, 1993
10. Newman AP: Articular cartilage repair. *Am J Sports Med* 26:309-324, 1998
11. Buck BE, Malinin TI, Brown MD: Bone transplantation and human immunodeficiency virus. An estimate of risk of acquired immunodeficiency syndrome (AIDS). *Clin Orthop* 240:129-136, 1989
12. Asselmeier MA, Caspari RB, Bottenfield S: A review of allograft processing and sterilization techniques and their role in transmission of the human immunodeficiency virus. *Am J Sports Med* 21:170-175, 1993
13. Buck BE, Resnick L, Shah SM, et al: Human immunodeficiency virus cultured from bone. Implications for transplantation. *Clin Orthop* 251:249-253, 1990
14. McDermott AG, Langer F, Pritzker KP, et al: Fresh small-fragment osteochondral allografts. Long-term follow-up study on first 100 cases. *Clin Orthop* 197:96-102, 1985
15. Oakeshott RD, Farine I, Pritzker KP, et al: A clinical and histologic analysis of failed fresh osteochondral allografts. *Clin Orthop* 233:283-294, 1988
16. Beaver RJ, Mahomed M, Backstein D, et al: Fresh osteochondral allografts for post-traumatic defects in the knee. A survivorship analysis. *J Bone Joint Surg Br* 74:105-110, 1992
17. Chu CR, Convery FR, Akeson WH, et al: Articular cartilage transplantation. Clinical results in the knee. *Clin Orthop* 360:159-168, 1999
18. Loening AM, James IE, Levenston ME, et al: Injurious mechanical compression of bovine articular cartilage induces chondrocyte apoptosis. *Arch Biochem Biophys* 381:205-212, 2000
19. Garrett JC: Fresh osteochondral allografts for treatment of articular defects in osteochondritis dissecans of the lateral femoral condyle in adults. *Clin Orthop* 303:33-37, 1994
20. Gross A: Use of fresh osteochondral allografts to replace traumatic joint defects, in Czitrom A, Gross A (eds): *Allografts in Orthopedics Practice*. Philadelphia, PA, Williams and Wilkins, 1992, pp 67-82
21. Ghazavi MT, Pritzker KP, Davis AM, et al: Fresh osteochondral allografts for post-traumatic osteochondral defects of the knee. *J Bone Joint Surg Br* 79:1008-1013, 1997
22. Kwan MK, Wayne JS, Woo SL, et al: Histological and biomechanical assessment of articular cartilage from stored osteochondral shell allografts. *J Orthop Res* 7:637-644, 1989
23. Cole BJ, Vird iAS, Markel M, et al: Cold preservation of osteochondral material for transplantation. Fourth Annual International Cartilage Repair Symposium, Toronto, Canada, June 15-18, 2002
24. Czitrom AA, Keating S, Gross AE: The viability of articular cartilage in fresh osteochondral allografts after clinical transplantation. *J Bone Joint Surg Am* 72:574-581, 1990
25. Aubin PP, Cheah HK, Davis AM, et al: Long-term follow-up of fresh femoral osteochondral allografts for posttraumatic knee defects. *Clin Orthop* 391:S318-S327, 2001 (suppl)