

Patient and graft selection important for meniscal allograft transplant success

Two-year follow-up shows best results for those with lateral meniscectomy and high pain scores.

by Susan M. Rapp

ORTHOPEDICS TODAY STAFF WRITER

Patients who suffer from pain or instability following partial or total meniscectomy can expect improved knee function following allograft meniscal transplantation, according to a recent study.

Meniscal allograft transplantation is indicated to restore a more even or natural distribution of stresses across the tibiofemoral (TF) joint following meniscectomy, according to **Brian J. Cole, MD, MBA**, of Chicago, the study's lead author.

But even a segmental meniscectomy can be problematic, particularly if it affects or disrupts the hoop stresses in the TF joint, Cole said. Such an occurrence may indicate that over time this increased TF contact force may lead to progressive degeneration.

In patients who undergo total meniscectomy, "These stresses go up exponentially in the central aspect of the tibia and the femur and the natural history then becomes somewhat unpredictable," Cole said in a presentation at ORTHOPEDICS TODAY New York 2006, A Comprehensive CME Course.

He reported results of a prospective evaluation of implanted meniscal allografts via a mini-arthrotomy with a minimum 2-year follow-up. The authors published their findings in the *American Journal of Sports Medicine* in 2006.

Indications: Pain, instability

Not all patients who undergo meniscectomy – segmental or total – are candidates for the allograft procedure. Patients who present with pain and instability may meet the indications, Cole said.

However, a few key principles must be followed in every transplantation case. By consistently adhering to them, the meniscal transplant procedure stands the best chance of being a successful intervention, he said.

Those principles include the following:

- Correct all comorbidities.
- Correct malalignment to neutral or slightly beyond.
- Perform ligament reconstruction as needed.
- Repair/restore cartilage defects that are Outerbridge grade III or IV (ICRS grade III) of the TF joint.

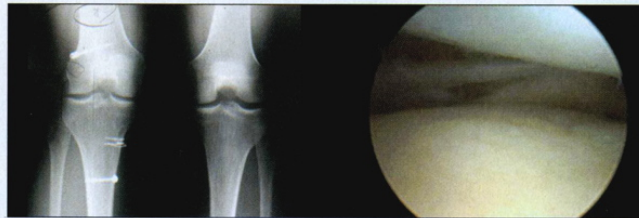Performing these corrective procedures can be staged or performed

concomitantly with the transplantation, Cole said.

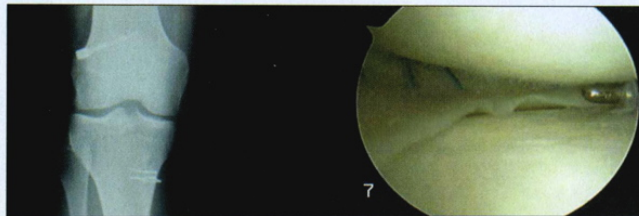
Contraindications for meniscal allograft implantation include uncorrected malalignment, ligament insufficiency, chondral injury, a flattened femoral con-

strate if these patients do have malalignment, and we will have a low threshold to correct this malalignment," he said.

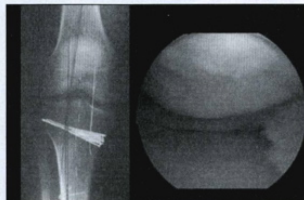
But when it comes to assessing who is best suited for meniscal transplantation, arthroscopic assessment of the knee remains the gold-standard evaluation tool. It can help rule out patients not suitable for the procedure who were not identified through the physical exam or



An index arthroscopy of a 23-year-old female volleyball player showed a lateral meniscectomized state with minimal chondral damage. Images: Cole BJ



Her second-look arthroscopy after transplantation demonstrated peripheral incorporation at 12 months.



Long leg alignment films are frequently obtained to assess for varus or valgus deformity that is routinely corrected at the time of meniscus allograft transplantation when the weightbearing axis falls within the middle or beyond the affected compartment.

dyle or tibial plateau, and TF subluxations.

Treatment highlights

Cole favors thoroughly evaluating potential allograft patients using radiographs. "The 45° posterior to anterior flexion, weight-bearing view is critically important," he said. He cautioned against using radiographic views that may "hide" joint space narrowing, such as those taken with the knee in full extension.

Cole is also a big proponent of getting long leg alignment films. They "demon-

strate if these patients do have malalignment, and we will have a low threshold to correct this malalignment," he said.

radiographs, such as ones with bipolar disease.

When it comes to graft sizing, size matters, Cole said. For nearly 200 meniscal transplants, he has successfully used the sizing technique described by M.E. Pollard.

He urged surgeons performing these transplantations to make sure that they understand how their tissue bank measures its grafts, and to factor in any anatomical magnification seen on the radiographs.

To avoid a sizing mistake, he recommended putting a 100-mm marker in the field of the radiograph when making the anterior-posterior X-ray and then mea-

asuring that mark on the actual X-ray. If it measures 110 mm, for example, that means the radiographic magnification is 10%, so any measurements made on the radiograph to size the graft needed should be reduced by 10%.

Cole developed his graft implantation technique, which has been published, with Jack Farr, MD. "It's fairly intuitive on the lateral side, that you can maintain the anatomy of the anterior-posterior horns by keeping some type of bone bridge," Cole said.

He also studied the technique of maintaining a bone bridge on the medial side and determined that it established the medial forces to an intact state.

Published results

Cole's study included results with 38 of the first 210 allograft meniscus transplants through the 2-year-follow-up. Two allografts failed during that time, leaving 36 patients (21 men, 15 women) for evaluation.

"Virtually every outcome score we looked at showed a statistically significant improvement," Cole said. They used the Visual Analog Scale (VAS) pain score, among other assessment tools. Postoperative VAS score improvement vs. preop assessment was statistically significant, except for workers' compensation patients. Based on their International Knee Documentation Committee scores, investigators deemed 90% of patients to have normal or nearly normal knees, according to the abstract.

Results proved best in patients who previously had a lateral meniscectomy and had high pain scores, he said.

Satisfaction scores showed 86% of patients were completely satisfied with their procedure and "94% said they would have this surgery again," Cole said. Patients who undergo the allograft transplantation in conjunction with another procedure also seem to do well, he said.

For more information:

Cole BJ. Allograft meniscus transplantation. Presented at ORTHOPEDICS TODAY NY 2006, A Comprehensive CME Course. Nov. 11-12, 2006. New York.

Cole BJ, Dennis MG, Lee S, et al. Prospective evaluation of allograft meniscus transplantation: Minimum 2-year follow-up. *Am J Sports Med*, 2006; 34(6):902-910.

Lee SJ, Adalén KJ, Malaviya, Cole BJ, et al. Tibiofemoral contact mechanics following serial medial meniscectomies in the human cadaveric knee. *Am J Sports Med*, 34(8): 13349-1344, 2006.

Brian J. Cole, MD, MBA, director of the Rush Cartilage Restoration Center, Rush University Medical Center, 1725 W. Harrison Street, #1063, Chicago, IL 60612. 312-432-2300, bcole@rushortho.com. He has indicated he receives grant research funding from and is a consultant to Genzyme.