

Medial Patellofemoral Ligament Reconstruction

A Novel Approach

Ammar Anbari, MD
Brian J. Cole, MD, MBA

ABSTRACT: Recurrent patellar instability is common, and multiple procedures have been described for its treatment. Medial patellofemoral ligament reconstruction can be successful in patients who have an incompetent medial patellofemoral ligament or who have failed medial patellofemoral ligament repair and present with recurrent patellar instability. This article describes a novel approach to medial patellofemoral ligament reconstruction using a folded hamstring al-

lograft with a new knotless suture anchor and bio-interference screw fixation. The principal advantage of this construct is the ability to definitively fix the medial patellofemoral ligament soft-tissue graft on the femur and provisionally fix the graft to the patella while assessing for reasonable medial patellofemoral ligament isometry throughout the arc of knee motion.

[*J Knee Surg.* 2008;21:241-245.]

INTRODUCTION

Recently, medial patellofemoral ligament reconstruction has gained popularity as a treatment modality for recurrent patellar instability.²⁻⁶ Patients who have failed surgical interventions including lateral release, medial patellofemoral ligament reefing, and distal realignment may be good candidates for medial patellofemoral ligament reconstruction.

The anatomy and biomechanics of the medial patellofemoral ligament have been well described. Anatomically, the medial patellofemoral ligament extends between the superomedial pole of the patella to the anterior aspect of the medial epicondyle in layer 2 of the medial soft-tissue structures.⁸ The patellar insertion is wider than the femoral origin. The vertical distance from the superior pole of the patella to the top of the medial patellofemoral ligament averages about 6.1 mm.⁸ The inferior edge of the medial patellofemoral ligament is located near the midpoint of

the patella. On the femoral side, the medial patellofemoral ligament inserts on the entire height of the medial epicondyle. Biomechanically, the medial patellofemoral ligament is considered the primary passive restraint to patellar lateral displacement, with a mean tensile strength of 208 N.¹

This article presents a novel, minimally invasive approach to reconstruct the medial patellofemoral ligament anatomically, a bio-interference screw to achieve fixation in the femur, and a knotless suture anchor to achieve fixation in the patella.

SURGICAL TECHNIQUE

After induction of anesthesia, patients are placed supine on the operating room table and prepared and draped in the usual fashion. Arthroscopy may be performed before reconstruction to address any intra-articular pathology. For example, concomitant articular cartilage lesions are debrided and occasionally microfracture is performed. If additional treatment of larger chondral defects is anticipated in the future, a biopsy for autologous chondrocyte implantation may also be performed.

If the lateral patellar tilt is noted, an arthroscopic lateral release may be performed. Abnormal patellar track-

The authors are from the Department of Orthopedics and Anatomy and Cell Biology, Rush University Medical Center, Chicago, Ill.

Correspondence: Brian J. Cole, MD, MBA, Department of Orthopedics and Anatomy and Cell Biology, Rush University Medical Center, 1725 W Harrison, Ste 1063, Chicago, IL 60612.

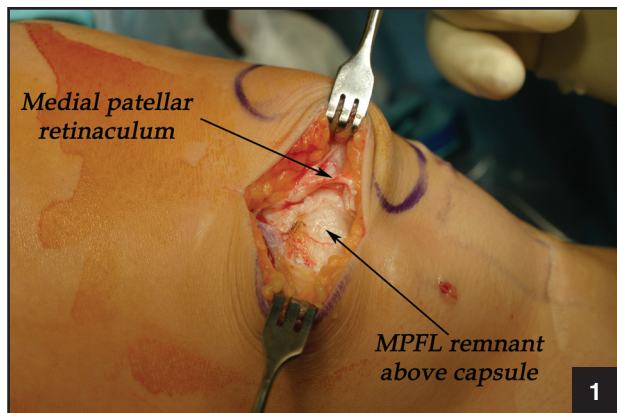


Figure 1. Intraoperative photograph showing the medial patellar retinaculum opened to expose the layer above the capsule containing the remnant of the medial patellofemoral ligament (MPFL).

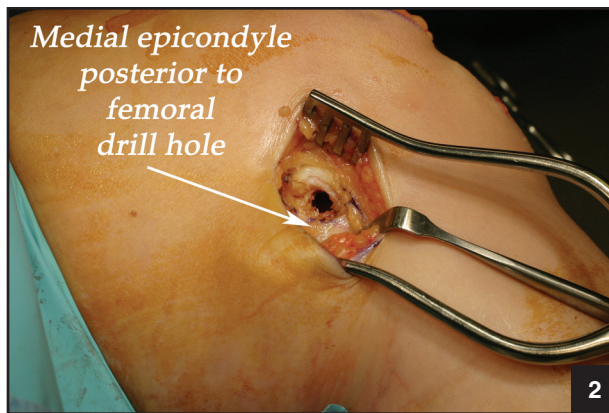


Figure 2. Intraoperative photograph showing the location of the femoral tunnel drill hole.

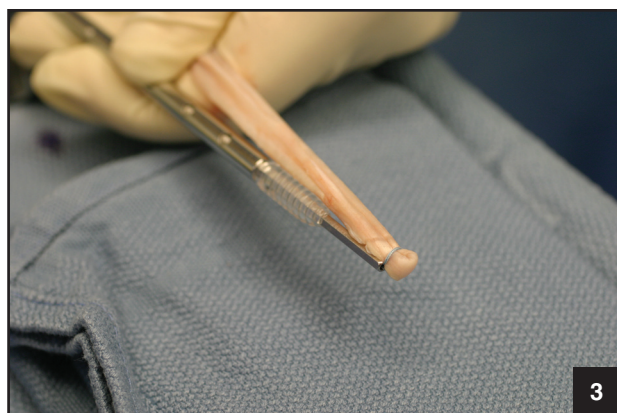


Figure 3. Photograph showing the hamstring allograft folded in half with the Fiberwire suture loop wrapped around the end of the tendon.

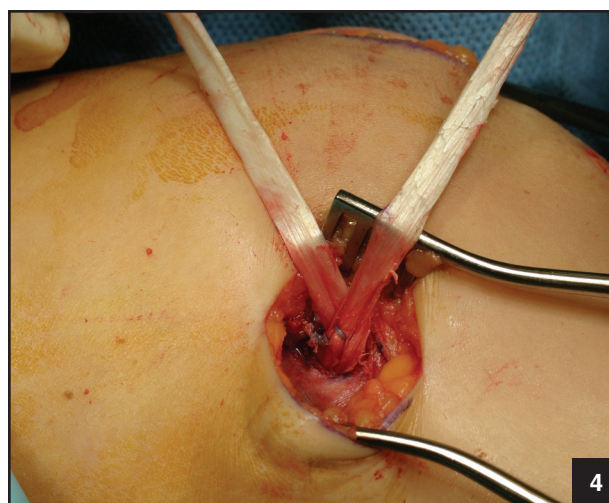


Figure 4. Intraoperative photograph showing the allograft being secured in the femoral tunnel.

ing, tight lateral retinaculum, patellar tilt, and increased lateral patellar laxity are some of the physical examination signs that have to be evaluated prior to making this decision. At the conclusion of the arthroscopic procedure, the pump pressure is reduced, the geniculate vessels are verified as coagulated, fluid is evacuated, and the portal sites are closed appropriately.

Medial patellofemoral ligament reconstruction is performed using two 3-cm incisions. The first is placed approximately 1 cm medial to the medial border of the patella beginning at the level of the proximal pole and extending distally to the equator of the patella. The second incision is centered over the medial epicondyle. The skin is infiltrated with local anesthesia with epinephrine, and both skin incisions are made with dissection down to the level of the medial retinaculum.

Blunt dissection is used to expose the superficial medial retinaculum adjoining the inferior border of the vastus medialis obliquus. The retinaculum is opened carefully,

and with meticulous blunt dissection, the layer containing the medial patellofemoral ligament is exposed above the capsule (Figure 1). In some cases, remnants of the ligament may still be intact, and a hemostat can be used to place traction on it to determine the attachment on the femur. The femoral attachment is identified on the medial epicondyle just proximal to the femoral insertion of the medial collateral ligament.

The femoral tunnel is secured with a Bio-Tenodesis screw (Arthrex Inc, Naples, Fla) as follows. A 2.4-mm guide pin is drilled into the center of the intended femoral tunnel to a depth of 3 cm. A 7-mm cannulated reamer is used to ream the tunnel to the same depth. Then, both the reamer and the guide pin are removed, and soft-tissue remnants surrounding the tunnel hole are cleared using electrocautery or a scalpel (Figure 2).

On the back table, a semitendinosus allograft is thawed and doubled over itself. If given the choice, we use the thickest and longest allograft available. This provides us

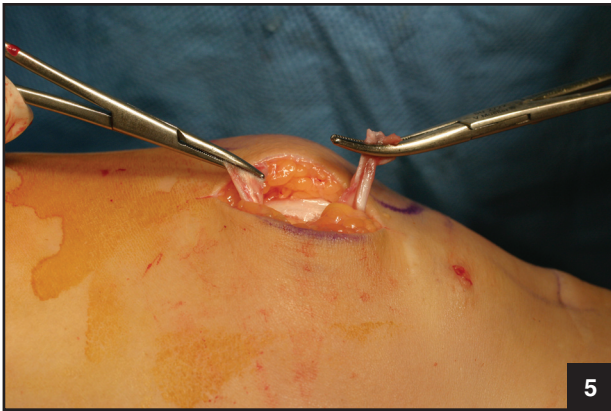

Figure 5. Intraoperative photograph showing the 2 allograft limbs being retrieved through the patellar incision.

with the most secure fixation and ample length to simplify graft tensioning. A 7×23-mm Bio-Tenodesis screw is placed on the appropriate driver, and a suture passing wire is inserted through the cannulated handle. A #2 Fiberwire (Arthrex Inc) suture is folded in half and its free ends are placed through the loop of the passing wire and pulled into the driver. The suture loop is used to capture the folded end of the hamstring allograft approximately 5 mm from the end of the graft (Figure 3).

The driver is used to advance the allograft and driver tip into the femoral tunnel, and the Bio-Tenodesis screw is advanced until it is flush with the bone. Then the driver is removed. Using a small free needle, the 2 suture limbs are passed through the 2 limbs of the allograft in a figure-8 fashion and secured to the femoral insertion to reinforce the fixation (Figure 4). A curved hemostat is placed through the patellar incision, tunneled under the skin between the retinaculum and medial patellofemoral ligament remnant, and used to retrieve the 2 allograft limbs (Figure 5).

The medial proximal half of the patella is exposed, and a curette or motorized burr is used to remove the soft tissue and superficial cortical layer to create a bleeding bone bed measuring approximately 20 mm in length. Two 3.5-mm Peek or Bio-PushLock anchors (Arthrex Inc) are used for soft-tissue fixation to the patella. A PushLock drill is used to make two 15-mm deep holes in the proximal and distal aspects of the medial patellofemoral ligament footprint along the decorticated border of the patella (Figure 6).

The patella is reduced to neutral with the knee flexed to 30°, and a pen is used to mark an approximate point on each allograft limb held taut to their estimated insertion points on the patella. A #2 Fiberwire is folded over, and both free ends are placed through the anchor eyelet. The loop end of the suture is passed around the respective limb of the allograft at the approximate marked

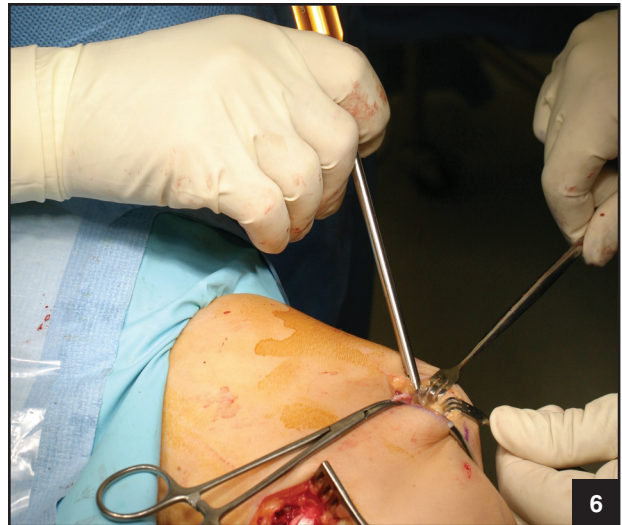

Figure 6. Intraoperative photograph showing the PushLock drill holes being placed in the patella.

location. The same process is repeated for the second anchor.

The anchor eyelet tips are approximated to the pre-drilled holes. Each allograft limb is tensioned through the loop, and the loop is tightened or “noosed” around the allograft as the anchor driver tip is partially introduced into the pilot hole such that the anchor itself abuts the cortical surface (Figure 7). The objective is to seat the anchor eyelet and suture loop-allograft construct to provisionally stabilize the soft-tissue graft allowing assessment for proper allograft tension prior to achieving final fixation by impacting the anchor against the eyelet. One of the advantages of the PushLock device is that the anchor eyelet tip can be pushed all the way into the 15-mm drill hole and taken out without compromising the anchor security and still achieving an accurate assessment of graft tension.

If a superomedial portal is used for the arthroscopic portion of the procedure, patellar tracking can be evaluated by placing the arthroscope through that portal. Patellar stability and graft tension are tested at different degrees of knee flexion. After being deemed acceptable, the anchor is impacted against the eyelet for final fixation. The free ends of each suture then are sutured through their allograft limb and tied to reinforce the repair. The excess allograft tissue is trimmed flush with the patella. This places the allograft limbs directly against the patellar cortical bone.

Both incisions are irrigated and closed in layers. If a tourniquet is used, it generally is deflated prior to closure to achieve adequate hemostasis. Sterile dressings are applied, and the knee is placed in a hinged brace locked in extension.

Postoperatively, patients are allowed full weight bearing with the leg locked in extension. The brace is locked

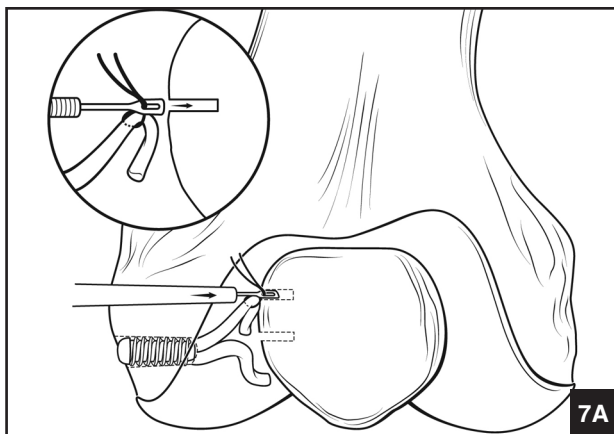


Figure 7. Diagram (A) and intraoperative photograph (B) showing the allograft limbs provisionally fixed to the patella using the PushLock anchor eyelets.

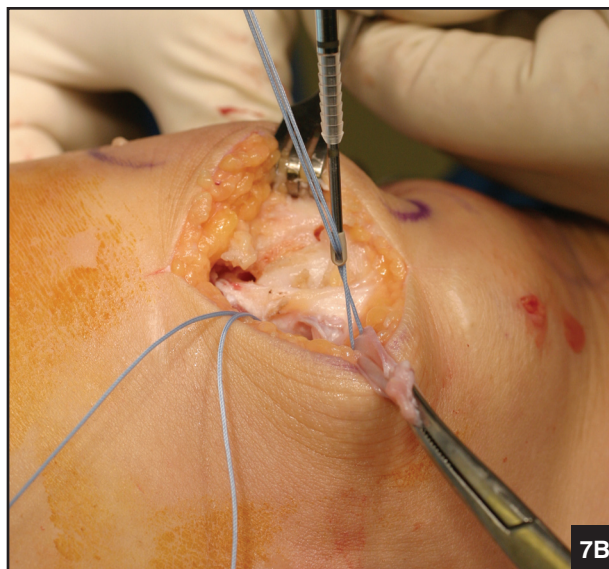for ambulation and is removed at night. The brace also is removed to start active and passive range of motion exercises, gentle isometric quadriceps strengthening, and stationary bicycling. The brace is unlocked when quadriceps strength is regained. At 6 weeks postoperatively, patients should achieve full range of motion and be able to perform straight-leg raises without difficulty. At that point, the brace is discarded and closed chain quadriceps exercises are started. At 12 weeks, patients are allowed to start jogging. Return to sports is delayed for approximately 4 months.

DISCUSSION

The medial patellofemoral ligament is the major restraint to lateral dislocation of the patella. Multiple procedures have been proposed to treat patellar instability including lateral release, medial imbrication, medial patellofemoral ligament repair, and a number of distal realignment procedures. Reconstruction of the medial patellofemoral ligament can be used as a successful primary procedure or as a salvage procedure.

Deie et al² studied the outcomes of 6 pediatric knees with recurrent patellar instability treated with medial patellofemoral ligament reconstruction by transferring the semitendinosus to the patella. They noted no recurrence of patellar instability with normalization of the congruence angle, tilt angle, and lateral shift ratio in all of their patients. Drez et al³ used autogenous hamstring or fascia lata for reconstruction or repair in 15 patients with recurrent patellar instability. Mean follow-up was 31.5 months, with 93% good to excellent results documented. Mean Kujala score was 88 of 100.

In another study, Ellera Gomes et al⁴ reported long-term results of medial patellofemoral ligament reconstruction in 16 knees treated for recurrent patellar instability.



The authors used a free semitendinosus graft, and follow-up was >5 years. Overall, 94% of patient outcomes were rated good or excellent according to the Crosby-Insall criteria. Fifteen knees showed a negative apprehension test at follow-up. Eighty-eight percent of the patients were satisfied with their surgery.

In our technique, we use small cosmetic incisions and tunnel the graft in between the 2 incisions. We use fixation methods biomechanically shown to have excellent pullout strength.⁷ We have found this method to be successful in our patients, and it allows intraoperative assessment of graft tension with provisional fixation. However, it is important to keep in mind that although our early data show successful clinical results, no prospective clinical data are available yet.

REFERENCES

1. Amis AA, Firer P, Mountney J, Senavongse W, Thomas NP. Anatomy and biomechanics of the medial patellofemoral ligament [published correction appears in *Knee*. 2004;11:73]. *Knee*. 2003;10:215-220.
2. Deie M, Ochi M, Sumen Y, Yasumoto M, Kobayashi K, Kimura H. Reconstruction of the medial patellofemoral ligament for the treatment of habitual or recurrent dislocation of the patella in children. *J Bone Joint Surg Br*. 2003;85:887-890.
3. Drez D Jr, Edwards TB, Williams CS. Results of medial patellofemoral ligament reconstruction in the treatment of patellar dislocation. *Arthroscopy*. 2001;17:298-306.
4. Ellera Gomes JL, Stigler Marczyk LR, Cesar de Cesar P, Jungblut CF. Medial patellofemoral ligament reconstruction with semitendinosus autograft for chronic patellar instability: A follow-up study. *Arthroscopy*. 2004;20:147-151.
5. Nomura E, Inoue M. Hybrid medial patellofemoral ligament reconstruction using the semitendinosus tendon for

- recurrent patellar dislocation: Minimum 3 years' follow-up. *Arthroscopy*. 2006;22:787-793.
6. Noyes FR, Albright JC. Reconstruction of the medial patellofemoral ligament with autologous quadriceps tendon. *Arthroscopy*. 2006;22:904.e1-e7.
 7. Richards DP, Burkhart SS. A biomechanical analysis of two biceps tenodesis fixation techniques. *Arthroscopy*. 2005;21:861-866.
 8. Steensen RN, Dopirak RM, McDonald WG III. The anatomy and isometry of the medial patellofemoral ligament: Implications for reconstruction. *Am J Sports Med*. 2004;32:1509-1513.