

## MENISCAL INJURIES

The meniscus is an important structure maintaining homeostasis within the knee joint by assisting in load transmission, stabilization, lubrication, nutrition, and proprioception. Meniscal tears represent about 50% of all knee injuries that ultimately require surgery. The male to female ratio is 2.5:17 with the peak incidence in males occurring between age 31 and 40 and the peak incidence in females occurring between age 11 and 20. The incidence is 61 per 100,000 people. In general isolated medial meniscus tears are more frequent than lateral meniscus tears. Degenerative tears are found in 60% of cadaver knees more than 65 years old.

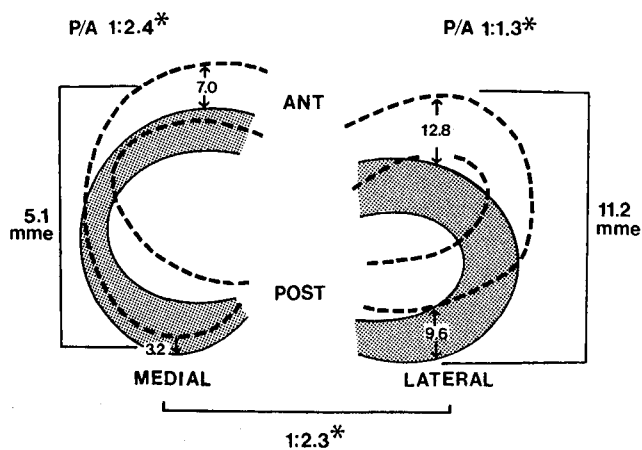
Two patterns of meniscal injury are seen: traumatic and degenerative. Degenerative tears are typically complex and not amenable to repair. Traumatic tears are often associated with ACL injuries and are usually amenable to repair. The incidence of meniscal tears rises significantly with the chronicity of the ACL tear, ranging from 65% in acute injuries to 90% in chronic injuries. The lateral meniscus is more frequently torn in the acute ACL injury due to rotary forces. The medial meniscus is more frequently torn in chronic ACL-deficiency (3:1) due to repeated episodes of instability and its relative lack of mobility.

### Basic Science

#### Biomechanics

##### Meniscal motion

Using three-dimensional MRI, meniscal motion has been shown as the knee is moved from 0 to 120 degrees (Fig. 35-25). The medial meniscus has an overall excursion of 5.1 mm compared with 11.2 mm for the lateral meniscus. Both posterior horns are less mobile relative to their respective



**Figure 35-25** Diagram of mean meniscal excursion (in millimeters) along the tibial plateau, ANT, anterior; POST, posterior; mme, mean meniscal excursion; P/A, ratio of posterior to anterior meniscal translation during flexion; \*,  $p < 0.05$  by Student *t*-test analysis. Reproduced with permission from Thompson WO, Thaete FL, Fu FH, Dye SF. Tibial meniscal dynamics using three-dimensional reconstruction of magnetic resonance images. *Am J Sports Med.* 1991; 19:214.

anterior horns, and the medial meniscus is less mobile than the lateral meniscus due to its greater soft tissue and bony constraints.

##### Load transmission

The development of "hoop stress" within the meniscus depends on intact anterior and posterior attachments. Hoop stress also relies on the conversion of axial load into tensile strain through intact longitudinally oriented collagen fibers. Loads normally transmitted to articular cartilage are partially borne by the menisci transmitting 50% of the knee load in extension and 85% with flexion during weight-bearing. The posterior horns carry more load than the anterior horns. About 50% of this load is borne by the medial meniscus, and 70% is borne by the lateral meniscus.

The paucity of radial fibers make menisci susceptible to splits in the longitudinal and horizontal direction. As the size of the meniscus decreases, the contact stress borne by the articular cartilage increases. Total meniscectomy decreases tibia-femoral contact area by 50% and increases peak loads nearly fourfold. One study showed that total meniscectomy decreased contact area by 75% and increased peak contact stress by 235%. Others have shown that a partial meniscectomy of 15 to 34% increases peak loads by more than 350%. Results after partial excision of the lateral meniscus are less favorable than partial excision of the medial meniscus.

##### Joint stability and congruity

The concave menisci increase the congruity and conformity of the tibio-femoral joint. The medial meniscus is a secondary AP stabilizer only in the ACL-deficient knee. Their viscoelasticity provides a shock-absorbing capacity in intact knees that is about 20% greater than knees that have undergone complete meniscectomy.

##### Joint lubrication and nutrition

Microcanals within the meniscus transport fluid for joint nutrition and lubrication. Following meniscectomy, there is a 20% increase in the coefficient of friction.

##### Joint proprioception

Mechanoreceptors provide a feedback mechanism for sensing joint position.

### PEARL

**Because the posterior horn of the medial meniscus is the least mobile, it is more susceptible to shear stress in the anterior cruciate ligament (ACL)-deficient knee leading to a high incidence of tears with repeated episodes of instability.**

### Meniscal Healing

Injuries that extend into the peripheral vasculature (red-red tear) heal similar to other vascularized connective tissue. Tears in the border zone (red-white) have good potential for healing. Tears in the avascular zone (white-white) have poor

healing potential without supplemental techniques. The perimeniscal capillary plexus provides substrate (fibrin clot), vessels, and cells for this healing response. A synovial pannus forms from the synovial fringe over the area of injury, providing vessel anastomoses with the perimeniscal capillary plexus. By 10 weeks, fibrovascular scar has formed that is modulated to normal appearing fibrocartilage of indeterminate strength over the next several months. Red-white and possibly some white-white tears can have their healing enhanced by techniques that extend vascularity such as vascular access channels, synovial abrasion, and fibrin clot.

#### *Vascular access channels*

Creating access of peripheral vessels to avascular regions by a channel (i.e., trephination) allows the avascular portion of the menisci to heal through proliferation of fibrous scar. Some authors are wary of this technique; it requires disruption of some of the circumferential fibers.

#### *Synovial abrasion*

Parameniscal abrasion with a meniscal rasp of tibial and femoral surface synovial fringe encourages vascular extension to avascular regions via formation of vascular synovial pannus.

#### *Exogenous fibrin clot*

A clot precipitated on a sterile glass surface and placed within the defect within the vascular zone can promote healing. It provides a scaffold of adhesive, chemotactic (i.e., platelet derived growth factor), and mitogenic factors for cellular migration, proliferation, and matrix production that eventually (6 months) modulates into fibrocartilage.

## Anatomy

### *Embryology*

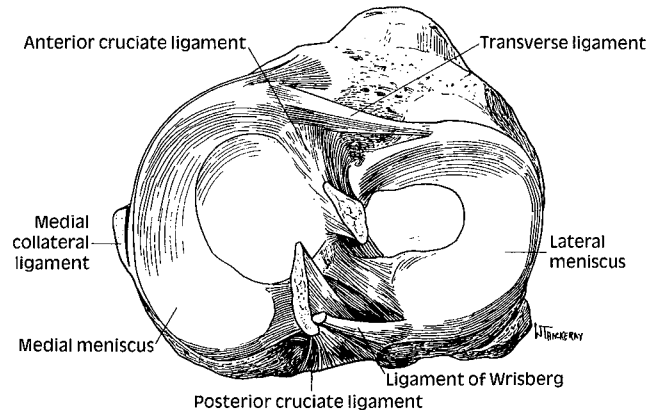
The menisci appear as distinct structures between the 8th and 10th week of gestation. They arise as a condensation of the intermediate mesenchyme and form attachments to the surrounding joint capsule and cruciates.

### *Histology*

The meniscus is composed of fibrocartilage and extracellular matrix (ECM). Chondrocytes and fibroblasts are responsible for synthesis and maintenance of the ECM. The ECM is primarily composed of an interlacing network of type I collagen (55–65% of dry weight) and minor amounts of types II, III, V, and VI collagen. The collagen is arranged in a circumferential orientation with an intermingling of radially oriented fibers acting as ties. The radial fibers help convert compressive forces into tensile forces ("hoop stress"). Within this network of collagen are small amounts of elastin, proteoglycans, and glycoproteins helping to resist compressive forces.

### *Functional anatomy*

The menisci are semilunar cartilages that act as anatomical extensions of the tibial plateau, effectively increasing the congruity with the femoral condyles (Fig. 35–26). They are triangular in cross section, being thicker peripherally where they



**Figure 35–26** Drawing of tibial plateau showing the shape and attachments of the lateral and medial menisci in relationship to the cruciate ligaments. Reproduced with permission from Nicholas JA, Hershman EB. *The Lower Extremity and Spine in Sports Medicine*. St. Louis, MO: CU Mosby; 1995: 687.

attach to the joint capsule and tibia through the coronary ligaments. Anteriorly, they are interconnected by the transverse intermeniscal ligament. They are firmly attached at their horns anteriorly and posteriorly.

#### *Medial Meniscus*

The medial meniscus is semicircular covering about 64% of the area of the medial tibial plateau. It is broader posteriorly than anteriorly. The anterior and posterior horns attach anterior to the ACL and PCL tibial insertion sites within the intercondylar fossa, respectively. Peripherally, the medial meniscus is firmly attached to the joint capsule and to the deep MCL.

#### *Lateral Meniscus*

The lateral meniscus is circular, covering approximately 84% of the area of the lateral tibial plateau. It has a uniform width throughout. The horns attach in close proximity to one another. The anterior horn inserts adjacent to the anterior half of the ACL. The posterior horn inserts slightly more medial at the posterior border of the ACL, in front of the posterior horn of the medial meniscus. Peripherally, it is loosely attached to the capsule, except at the popliteal hiatus. At the hiatus, it is only attached to an aponeurotic extension from the popliteus and portions of the arcuate and meniscofemoral ligaments.

## *Vascular Supply*

During the transition from prenatal to postnatal development, the vascular supply recedes to the outer region of the meniscus. Peripherally, it is supplied by branches of the lateral, medial, and middle geniculate arteries, forming a perimeniscal capillary plexus. The peripheral 10 to 30% of the meniscus in the adult is vascular. The remaining portions receive nutrition via diffusion enhanced by joint loading. Energy production is principally through anaerobic glycolysis. Three zones exist based on decreasing vascular supply from the periphery to the center: red-red, red-white, and white-white, with decreasing capacity to heal after injury.

### *Innervation*

The peripheral two thirds of the meniscus is innervated by myelinated and unmyelinated nerve fibers supplied by the posterior tibial, obturator, femoral, and peroneal nerves. Primarily concentrated in the anterior and posterior horns, mechanoreceptors (Ruffini, Golgi, and Pacini) and free nerve endings have proprioceptive and nociceptive functions.

## **Examination**

### *History*

Commonly associated with a twisting injury to the knee. Patients often complain of pain localized to the joint line. Typically, the location is posterior to the collateral ligaments. Older patients may present with an insidious onset of pain. Hyperflexion (e.g., squatting) may exacerbate the pain. Swelling may be present. Peripheral acute tears may present with an insidious onset of a hemarthrosis. Chronic tears that become dislodged or that are associated with arthritis may cause effusions. Mechanical locking, catching or giving way from a displaced fragment may also occur.

### *Physical Examination*

#### *Observation*

Observe for antalgic gait, effusion, decreased active or passive ROM, and thigh atrophy from feedback inhibition to the quadriceps due to pain.

#### *Palpation*

Palpate for effusion (50% of patients), joint line tenderness (77–86% of patients), extensor mechanism pathology, and for associated ligament insufficiency. Collateral ligament tenderness is commonly present at the joint line, but will extend proximal or distal over the course of the ligament.

#### *Range of motion*

Mechanical blocking may cause a decrease in active or passive motion.

#### *Special Tests*

##### **McMurray's Test**

This test is performed on the supine patient beginning with the knee flexed to 90 degrees, axially loaded and slowly extended with IR and ER forces applied to the tibia. The addition of a varus or valgus stress can help delineate medial meniscus or lateral meniscus tears, respectively. A positive test is a palpable click along the joint line often associated with pain.

##### **Apley's Test**

Perform this test on the prone patient with the knees flexed to 90 degrees and axially loaded through the heels with IR and ER. A positive test is pain relieved with distraction. Pain not occurring during compression but occurring with distraction may indicate collateral ligament injury.

##### **Steinmann Test**

Performing a brisk tibial rotation of the flexed knee elicits pain.

### **Squat Test**

In this test, asking the patient to squat repetitively or to "duck walk" elicits symptoms or inability to perform in the presence of meniscal tears.

### **PEARL**

**Clinical examination accuracy is about 82% for medial meniscus tears and 76% accurate for lateral meniscus tears.**

## **Aids to Diagnosis**

### *Radiographs*

Complete radiographic evaluation is discussed in Anterior Knee Pain and Patellofemoral disorders. In general, an AP, lateral, axial and 45 degree PA flexion weight-bearing radiograph should be obtained. Specifically, a history of prior meniscectomy may lead to early degenerative changes including those described by Fairbank (1948, squaring of the femoral condyles, marginal ridging, and joint space narrowing) and peaked eminences and notch osteophytes thought to be related to chronic ACL-deficiency with repeated episodes of instability.

### *Magnetic Resonance Imaging*

Accuracy in MRI has improved significantly over the last few years and is slightly greater for medial meniscus (93–98%) than lateral meniscus tears (90–96%). Signal grading comprises: grade I; intrameniscal ovoid or globular signal; grade II; linear signal not reaching the articular surface and, grade III; intrameniscal signal communicating with the articular surface. Only a grade III signal coincides with tears with an accuracy of up to 90%. Grades I and II probably represent mucinous degeneration and are present in asymptomatic patients past age 30 who do not have evidence of meniscal tears. Following meniscal repair, an abnormal signal may persist for as long as 3 to 6 years postoperatively.

Sagittal images offer the most information concerning the meniscus. Normally, the meniscus has a uniform, low signal on T1- and T2-weighted images. A torn meniscus imbibes fluid and is seen well on T2-weighted images. Common pitfalls exist when reading the MRI. The transverse intermeniscal ligament can mimic a tear of the anterior horn of the lateral meniscus. The superior recess above the posterior horn of the medial meniscus can mimic a partial-thickness tear of the medial meniscus. The popliteal tendon sheath and meniscofemoral ligament can be misinterpreted as a tear of the posterior horn of the lateral meniscus.

### *Arthrography*

Double contrast arthrography has an accuracy of at least 83 to 93%. This invasive test is used mostly in areas where the MRI is not available and to evaluate the results of meniscal repair.

### *Classification*

#### *Location*

Based on vascularity, tears are located in the peripheral vascular zone (red-red), middle zone (red-white), and central

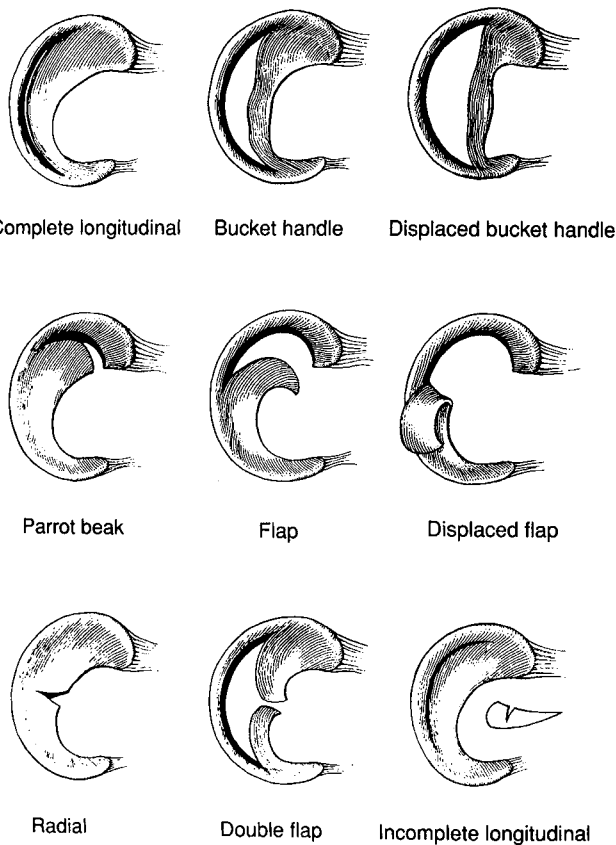
avascular zone (white-white). Other geographic classifications exist to describe the radial and circumferential extent of the tear. One method divides the medial meniscus into three radial zones (A, B, and C) from the posterior third to the anterior third, and the lateral meniscus into three radial zones (D, E, and F) from the anterior third to the posterior third. These are subclassified into four circumferential zones (0, 1, 2, and 3) from the meniscal synovial junction (0), outer third (1), central third (2), and inner third (3). Zones 0 to 1 correspond to the red-red zone, zones 1 to 2 correspond to the red-white zone, and zones 2 to 3 correspond to the white-white zone.

### Orientation and Appearance

Figure 35-27 describes various tears. In general, it is best to document the length, location, and tear pattern. Tears can be vertical, longitudinal oblique or flap, degenerative or complex, radial, and horizontal cleavage. They can be acute or chronic. The ability to displace the tear by greater than 3 mm with an arthroscopic probe is used to determine stability.

### Specific Conditions, Treatment, and Outcome

Total meniscectomy, once the standard of care, leads to the development of arthritis. Attempts to preserve the meniscus are now the rule rather than the exception. When a meniscus



**Figure 35-27** Gross anatomy of the most common meniscus tears. Reproduced with permission from Tria AJ, Klein KS. *An illustrated Guide to the Knee*. New York, NY: Churchill Livingstone; 1992: 100.

tear is not amenable to repair, partial meniscectomy is the preferred treatment.

### Nonoperative Treatment

Nonsurgical treatment for meniscal tears may be suitable for asymptomatic tears, older patients who are willing to change their lifestyle, and those at high risk for surgery. All patients should be initially managed with rest, ice compression, elevation, and NSAIDs. Rehabilitation emphasizing painless, full ROM and strengthening is performed.

Meniscal tears found at the time of arthroscopy that do not require repair may be stimulated to heal faster by performing parameniscal abrasion. This includes:

1. partial-thickness splits
2. full-thickness vertical or oblique tears less than 5 mm in length, if stable
3. short radial or minor inner-rim tears
4. degenerative tears in osteoarthritis without mechanical symptoms
5. stable tears with inability to displace the central portion by greater than 3 mm.

It has recently been suggested that tears of the lateral meniscus posterior to the popliteal hiatus need only parameniscal abrasion and do not require excision or repair. Additionally, some authors report longitudinal tears of less than 1.5 cm can also be left alone, if deemed stable at arthroscopy.

### Operative Treatment

Surgical intervention is recommended for those patients with a history of persistent pain, catching or locking, and a physical examination consistent with a meniscal tear. More than 90% of athletes with symptomatic meniscal tears are unable to return to sports at the same level unless treated. Operative treatment includes (1) total meniscectomy, (2) partial meniscectomy, (3) meniscal repair, and (4) meniscal transplantation.

#### Total Meniscectomy

Early literature on the short-term followup following total meniscectomy showed a high incidence of good results. Long-term followup, however, at intervals of 10 to 22 years, demonstrated significant increases in the incidence and severity of degenerative arthritis following total meniscectomy. In 1948, Fairbank was the first to suggest that degenerative changes after meniscectomy resulted from increased joint reactive forces. Given our present understanding of the biomechanical importance of the meniscus, procedures that preserve the meniscus have significant long-term advantages.

#### Partial Meniscectomy

Partial meniscectomy will significantly increase forces across the articular cartilage, and maximizing meniscal preservation

should minimize the incidence and severity of degenerative change over time. Removal of only the torn or unstable portion (flaps, complex tears, degenerative and central/radial tears) with subsequent contouring of the remaining meniscus is recommended. Use of an arthroscopic basket forceps and motorized shaver are helpful to accomplish these goals.

### PEARL

**Irreparable bucket-handle tears should be reduced, detached posteriorly, partially detached anteriorly, and avulsed from the residual attachment.**

#### *Meniscal Repair*

Our present understanding of meniscal vasculature and healing potential has resulted in an increased popularity of meniscal repair. It is important to evaluate the meniscus for the location, extent, and stability of the tear. Using the modified Gillquist approach, one can view the posterior horn of the medial meniscus by passing the 30- and 70-degree arthroscope between the medial femor condyle and PCL. The site is prepared using a meniscal rasp or motorized shaver. At present, the most common criteria for meniscal repair include the following.

#### **Criteria for repair**

##### *Location*

This is possibly the most important factor. Peripheral tears (10–30%) with good vascular access (red-red and red-white) are optimal. If bleeding is not evident, it has been suggested that tears within 3 mm of the periphery are presumed vascular, and tears greater than 5 mm from the periphery are presumed avascular. Tears 3 to 5 mm from the periphery have variable vascularity and results may be improved by the use of vascular extension techniques.

##### *Stability*

Stable tears include partial-thickness (< 50% of height of meniscus) and full-thickness oblique or vertical tears less than 10 mm in length with inability to displace the central portion with a probe greater than 3 mm. Unstable tears should be resected or repaired.

##### *Length*

Stable tears less than 10 to 15 mm in length can be left alone or treated with parameniscal abrasion. Radial tears less than 5 mm in length can also be left alone. Longer tears (> 4 cm) may have lower healing rates, especially when isolated repair is performed

### PEARL

**Combining length and stability factors yields the recommendation that stable tears greater than 10 to 15 mm in length or tears that are any length and unstable (displaced by > 3 mm) to probing are amenable to partial meniscectomy or repair.**

#### *Tear pattern*

Peripheral, vertical, longitudinal tears represent the ideal situation for repair. Chronic bucket-handle tears often have radial components, making them less amenable to repair. Complex bucket-handle tears, flap tears, degenerative, complex, and radial tears often perform poorly with repair and are more often amenable to excision. Horizontal cleavage tears are not repairable, and the unstable leaf should be excised, leaving up to 3 mm of the leaf.

#### *Patient age*

Age by itself does not affect the ability of the meniscus to heal. Although some recommend that a patient under the age of 50 should be considered a candidate for repair if the tear is repairable, probably any tear amenable to repair should be considered for repair.

#### *Chronicity*

Both acute and chronic tears can be repaired, but acute tears less than 8 weeks old have better healing potential, probably because they are less likely to be complex or degenerative.

#### *Ligament stability*

Anterior cruciate ligament deficiency must also be corrected simultaneously to prevent instability and retearing. Because of relatively poor results following removal of the lateral meniscus versus the medial meniscus, some authors maintain that aggressive salvage of the lateral meniscus regardless of the status of the ACL is warranted. Repairable meniscus tears in ACL-stable knees are less common and often associated with complex or degenerative tears. On the other hand, repairable tears are usually part of a complex that includes a torn ACL. Compared with the ACL-deficient knee, the PCL-deficient knee has a lower incidence of associated meniscal pathology.

### PEARL

**The ideal candidate for repair is the young patient with an acute longitudinal tear in the periphery of the meniscus that is 1 to 2 cm in length that is repaired in conjunction with an ACL reconstruction.**

#### **Technical aspects of meniscus repair**

##### *Suture placement*

Anatomic coaptation of the edges is the desired result. Most authors recommend a separate suture every 3 to 5 mm of tear and that the entrance site be 2 to 3 mm from the tear margin to prevent cutting out. Only polydioxanone sutures (PDS) (Ethicon, Inc.; Somerville, NJ) and nonabsorbable sutures retain significant strength beyond 6 weeks. The choice of suture material is technique dependent. If support is desired beyond 6 weeks of healing, then nonabsorbable sutures should be used. Arthroscopically, one can use either the ipsilateral or contralateral portal for suture placement, as long as the neurovascular structures are protected. Ideally, sutures

should be placed perpendicular to the tear surface. Vertical mattress sutures have the highest tearing stress, as such a suture catches more circumferential fibers within the loop. It is best to have the two suture ends near one another and then diverge for optimal strength and coaptation. If it is not possible to place a vertical mattress, a horizontal mattress is considered second best. With a horizontal mattress, sutures may need to be placed on the tibial and femoral surface for maximal coaptation. Horizontal sutures require a minimum meniscal bridge between the two suture arms of 2 to 4 mm.

On the lateral side, sutures are passed with the knee in the figure-four position with 70 to 90 degrees of knee flexion. On the medial side, the knee is placed in 10 to 30 degrees of flexion for optimal visualization and to avoid capturing the posteromedial capsular recess.

#### *Incisions*

Depending on the technique utilized, a longitudinal incision centered at the joint line may be required to facilitate repair or to tie sutures against the capsule. Repairs performed arthroscopically will not require a capsulotomy, and only subcutaneous dissection is required. For the medial meniscus, a posteromedial incision is utilized. The pes tendons, saphenous nerve and its intrapatellar branch are retracted posteriorly. An oblique capsular incision is made as needed, just posterior to the trailing edge at the MCL.

For the lateral meniscus, a posterolateral incision is used in line with the posterior border of the fibular head with the knee flexed to 90 degrees. The posterior border of the ITB is incised and retracted posteriorly with the biceps femoris to protect the peroneal nerve. At times, the lateral head of the gastrocnemius must also be retracted posteriorly. An oblique capsular incision is made as needed parallel to the posterior border of the popliteus tendon.

#### *Open meniscal repair*

This technique provides limited access to the meniscus and is most indicated for peripheral posterior third tears. It is performed through lateral- or medial-based longitudinal incisions as described above, often using a double-armed suture and vertical mattress for anatomic repair.

#### *Inside-out arthroscopic repair*

Long, flexible Keith needles are passed through a curved, single- or double-barrel cannula placed through the arthroscopic

portal (Fig. 35-28, left). A single-barrel cannula allows vertically oriented suture placement, but a double barrel cannula may be quicker. Nonabsorbable No. 2-0 or absorbable No. 2-0 PDS sutures are used and placed from posterior to anterior as a vertical or horizontal mattress. Outer mini-incisions are made (as described above) to prevent entrapment of subcutaneous nerve branches as the sutures are tied over the capsule.

#### *Outside-in arthroscopic repair*

An 18-gauge spinal needle is placed as a cannula to pass a No. 0 PDS suture through the tear from the outside-in (Fig. 35-28). The sutures are retrieved from within the knee through the arthroscopic portal and a large "mulberry" knot is tied outside of the knee and subsequently drawn back into the knee. Separate 1- to 2-cm incisions or a single, long incision can be made to tie adjacent sutures to one another against the capsule without capturing subcutaneous nerves.

#### *All-inside arthroscopic repair*

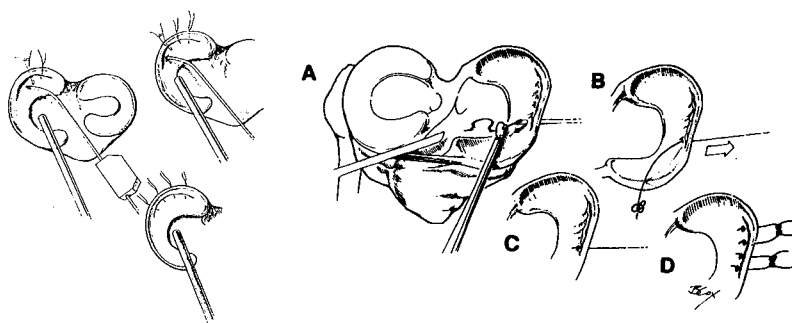
A special cannulated suture hook is used to perforate both sides of the tear. Sutures are passed through the lumen of the hook, and a knot pusher is used to secure them into place. No additional incisions are required.

#### *Enhancement of meniscal healing*

As described above, promotion of neovascularization can be accomplished by perimeniscal abrasion, placement of exogenous fibrin clot, and creating vascular access channels. Most commonly, perimeniscal abrasion is used. Although fibrin clot is believed to occur spontaneously during ACL reconstruction or with peripheral tears, it is especially useful during the repair of isolated tears extending into the white-red zones. Fibrin clot is prepared by stirring 50 to 75 ml of the patient's venous blood with a glass rod, rinsing the clot through a sponge, and arthroscopically suturing it into the defect. Vascular access channels can be prepared with an 18-gauge spinal needle.

#### *Allograft meniscal transplantation*

The rationale of meniscal transplantation is to prevent degenerative changes in the postmeniscectomy patient. Young patients who have undergone even partial meniscectomy, especially of the lateral meniscus, are undoubtedly at significant risk for developing arthritis. At present, the most



**Figure 35-28** Two of the most common meniscal repair techniques. Left: the inside-out technique. Reproduced with permission from Fu FH, Harner CD, Vince KG. *Knee Surgery*. Philadelphia, PA: Williams and Wilkins; 1994: 623. Right: the outside-in technique. (A) Sutures are placed from outside-in through a spinal needle. (B) Knot is tied. (C) Suture is pulled back. (D) Sutures are tied together outside the capsule. Reproduced with permission from Hanks GA, Kalenak A. Alternative arthroscopy techniques for meniscal repair: a review. *Orthop Rev*. 1990; 19:29.

accepted indications for meniscal transplantation are patients less than age 45 with pain and discomfort associated with early osteoarthritis (less than grade IV) of the involved compartment without ACL-deficiency or significant malalignment. Contraindications include age greater than 60 or patients with bony architectural changes, prior infection, significant malalignment, or instability. Meniscal allografts are considered "immunologically privileged," and clinical rejection has not been a problem. Several graft preservation techniques are available including fresh, fresh freezing, cryopreservation, and freeze drying. Secondary sterilization with radiation of less than 2.5 MRad minimizes mechanical degradation while sterilizing all but the most virulent bacterial and viral pathogens. Techniques include arthrotomy, arthroscopy, or combined approaches and are beyond the scope of this discussion. Long-term followup is limited with success rates ranging between 60 and 100% at 8 to 48 months.

### *Meniscal Cyst*

Meniscal cysts more commonly involve the lateral meniscus than the medial meniscus (3 to 10:1). They have an incidence of less than 1 to 22% and are associated with meniscal tears in 18 to 100% of cases. They usually involve a horizontal cleavage tear of the peripheral, middle third of the lateral meniscus. The peak incidence is in males in the second or third decade. Patients complain of a dull ache along the joint line and have a tender, rubbery mass that may change size with flexion. Magnetic resonance imaging is helpful to confirm the diagnosis. Meniscal cysts usually contain a gelatinous fluid. Treatment of symptomatic cysts with a meniscal tear includes partial meniscectomy with arthroscopic cyst decompression. When no tear is identified, en bloc resection may be required.

### *Discoid Meniscus*

The incidence of discoid meniscus involving the lateral meniscus is about 0.4 to 7% and 0 to 0.3% for the medial meniscus. Less than 10% are bilateral. These lesions have been classified by Watanabe as (1) complete, (2) incomplete, and (3) Wrisberg-ligament type (absent posterior coronary ligament) with normal shape and excessive hypermobility. Only the first two types have been found in the medial meniscus. Radiographically, the first two types may demonstrate a widened joint space, squaring of the condyle, cupping of the tibial plateau, and a hypoplastic tibial spine that are all found on the lateral side. Magnetic resonance imaging is helpful to confirm the diagnosis. Complete and incomplete types are disc-shaped, and if found incidentally are left alone. When torn and symptomatic, saucerization (central partial meniscectomy) is performed to trim the meniscus back to a stable 6 to 8-mm rim.

The Wrisberg-ligament type commonly presents as the "snapping knee syndrome" in children or adolescents who complain of lateral joint line pain. An audible clunk with terminal extension may occur because the posterior horn is tethered by only the ligament of Wrisberg (not the tibial plateau), and thus, is excessively mobile. No radiographic changes occur. A symptomatic Wrisberg-ligament type should be treated by repair of its hypermobile posterior horn.

### *Rehabilitation*

Rehabilitation protocols following meniscal repair have evolved as our understanding of meniscal biomechanics and healing has improved. During the first 8 weeks, weight bearing as tolerated in a hinged knee brace locked in extension and unlocked only for therapeutic exercise is performed. Motion begins in the initial phase, but flexion beyond 90 degrees is avoided for 6 months. After 8 weeks, patients are weaned from crutch and brace use, and greater emphasis is placed on strengthening and proprioception. Terminal, knee extension exercises and open-chain, kinetic exercises are avoided for the first 3 months. Sport-specific training or work hardening begins at about 6 months, taking an average of about 9 months to return to full activities. Variations of this protocol are in use with greater acceptance of accelerated rehabilitation protocols. Meniscal repair in conjunction with ACL reconstruction follows a protocol similar to the ACL rehabilitation guidelines.

### *Results*

Results of partial meniscectomy are better than total meniscectomy in the short-term. In the degenerative, ACL-deficient knee, results of partial meniscectomy are satisfactory if mechanical meniscal symptoms are the presenting complaint.

Overall healing rates range from 78 to 95%. Isolated meniscal repair in the ACL-deficient knee has a failure rate of 40 to 50%. More recent reports show even higher healing rates, and this is believed to be related to more appropriate patient selection and improved techniques. Meniscal repair in conjunction with ACL reconstruction has a healing rate in excess of 90 to 95%. This has been related to the postoperative hemarthrosis and to the knee stability conferred by the reconstruction.

### *Complications*

The overall complication rate is around 2.5%. The most common complication following meniscal repair is a failure to heal or a retear occurring in as many as 50% of those with unstable knees and as little as 0 to 5% in stable knees. Not all failures, however, are symptomatic. Repeat surgery rates for partial meniscectomy and repair are each about 25%. Neurovascular injury most commonly involving the infrapatellar branch and the saphenous nerve ranges from 2 to 28%, most of which resolve before 4 months. Stiffness occurs in 6 to 12%, with loss of extension being more common than loss of flexion, especially with medial meniscus repair or concomitant ACL reconstruction. Other complications include arthrofibrosis, infection, thrombophlebitis, and RSD.

### *Future Directions*

Future trends include improved repair techniques and the use of synthetic meniscus implants. New meniscal repair techniques include the use of a bioresorbable implant for easier all-inside meniscal repair, but long-term results are lacking. Recently, the use of a bovine collagen meniscus implant fabricated as a meniscal replacement has been reported in animal models. The template is slowly resorbed as it induces and supports the ingrowth of host cells and matrix. Clinical studies are in preliminary stages.

## SELECTED BIBLIOGRAPHY

## General References

- FU FH, HARNER CD, VINCE KG. *Knee Surgery*. Baltimore, MD: Williams and Wilkins; 1994.
- MERCHANT AC, MERCER RL, JACOBSEN RJ, COOL CR. Roentgenographic analysis of patellofemoral congruence. *J Bone Jt Surg*. 1974;56A:1391-1396.
- MILLER MD, COOPER DE, WARNER JP. *Review of Sports Medicine and Arthroscopy*. New York, NY: WB Saunders; 1995.
- OUTERBRIDGE RE. The etiology of chondromalacia patellae. *J Bone Jt Surg*. 1961;43B:752-757.
- ROSENBERG TD, PAULOS LE, PARKER RD, COWARD DB, SCOTT SM. The forty-five degree posteroanterior flexion weight-bearing radiograph of the knee. *J Bone Jt Surg*. 1988;70A:1479-1983.
- WIBERG G. Roentgenographic and anatomic studies on the femorapatellar joint. *Acta Orthop Scand*. 1941;12:319-410.
- NOYES FR, BUTLER DL, GROOD ES et al. Biomechanical analysis of human ligament grafts used in knee-ligament repairs and reconstruction. *J Bone Jt Surg*. 1984;66A:344-352.
- NOYES FR, MATTHEWS DS, MOOAR LA, GROOD ES. The symptomatic ACL deficient knee. II. The results of rehabilitation, activity modification and counseling on functional disability. *J Bone Jt Surg*. 1983;65A:163-174.
- O'DONOGHUE DH. An analysis of end results of surgical treatment of major injuries to the ligaments of the knee. *J Bone Jt Surg*. 1955;37A:1-12.
- WOJTYK EM. *The ACL Deficient Knee*. Am Acad Orthop Surg Monograph Series. Rosemont, IL; 1994.
- WOO SLY, ADAMS DJ. The tensile properties of human ACL and ACL graft tissues. In: Dale D et al, eds. *Knee Ligaments. Structure, Function, Injury and Repair*. New York: Raven Press; 1990.

Anterior Knee Pain  
and Patellofemoral Disorders

- DREZ D, DELEE JC. Patellofemoral joint surgery. *Op Tech Sports Med*. 1994;2:238-334.
- FU FH, MADAY MG. Arthroscopic lateral release and the lateral patellar compression syndrome. *Orthop Clin North Am*. 1992;23:601-612.
- FULKERSON JP. Patellofemoral pain disorders: evaluation and management. *J Am Acad Orthop Surg*. 1994;2:124-132.
- FULKERSON JP, HUNGERFORD DS. *Disorders of the Patellofemoral Joint*, 2<sup>nd</sup> ed. Baltimore, MD: Williams and Wilkins; 1990.
- POST WR. Surgical decision making in patellofemoral pain and instability. *Oper Tech Sports Med*. 1994;4:273-284.

## Anterior Cruciate Ligament Injuries

- BALDERSTON RA. Surgery of the anterior cruciate ligament. *Op Tech Orthop*. 1996;6:125-180.
- DREZ D, DELEE JC. Anterior cruciate ligament injuries. *Op Tech Sports Med*. 1993;1:1-83.
- FU FH. The anterior cruciate ligament. *Clin Sports Med*. 1993;12:625-852.
- HARNER CD. Failed anterior cruciate ligament surgery. *Clin Orthop Rel Res*. 1996;325:1-139.
- LARSON RL, TAILLON M. Anterior cruciate ligament insufficiency: principles of treatment. *J Am Acad Orthop Surg*. 1994;2:26-35.

## Posterior Cruciate Ligament Injuries

- COVEY DC, SAPEGA AA. Injuries of the posterior cruciate ligament. *J Bone Jt Surg*. 1993;75A:1376-1386.
- SEEBACHER J, INGLIS A, MARSHALL J, WARREN RF. The structure of the posterolateral aspect of the knee. *J Bone Jt Surg*. 1982;64A:536-541.
- VELTRI DM, WARREN RF. Isolated and combined posterior cruciate ligament injuries. *J Am Acad Orthop Surg*. 1993;1:67-75.

## Meniscus

- BELZER JP, CANNON WD. Meniscus tears: treatment in the stable and unstable knee. *J Am Acad Orthop Surg*. 1993;1:41-47.
- CANNON WD, DEHAVEN KE. Meniscus repair. *Sports Med Arthroscop Rev*. 1993;1:103-176.
- DEHAVEN KE. Decision-making factors in the treatment of meniscus lesions. *Clin Orthop Rel Res*. 1990;252:49-54.
- DREZ D, DELEE JC. Meniscal surgery. *Op Tech Sports Med*. 1994;2:152-235.
- FAIRBANK TJ. Knee joint changes after meniscectomy. *J Bone Jt Surg*. 1948;30B:664-670.
- SHERMAN OH. Meniscal repair. *Clin in Sports Med*. 1996;15:445-630.

## SAMPLE QUESTIONS

- Patellar tilt is best evaluated radiographically using the:
  - Merchant's view
  - Laurin's view
  - sunrise view
  - 45-degree PA view
  - lateral view
- A 25-year-old female presents with a history of anterior bilateral knee pain made worse during negotiation of steps. Upon evaluation, it is determined that she has lateral retinacular tightness and a normal Q angle. The best initial management of this problem is:
  - physical therapy with quadriceps strengthening using open-chain exercises from 0 to 45 degrees