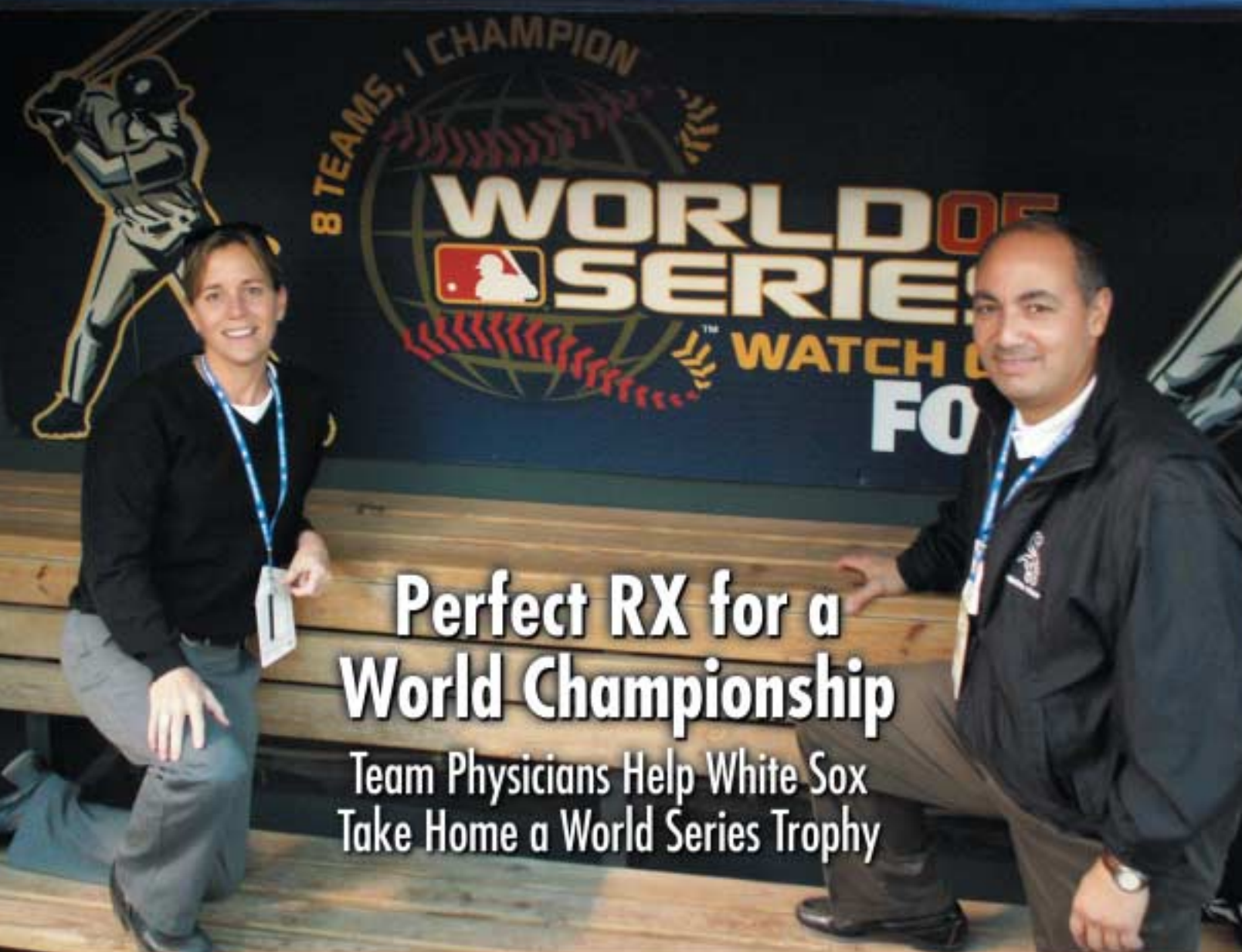

Orthopaedics EXCELLENCE

A publication from Midwest Orthopaedics at Rush (MOR)
VOLUME 2 • ISSUE 3 www.rushortho.com

Midwest
Orthopaedics at
Rush Makes the
Grade...and the Cover!
— See page 6



Perfect RX for a World Championship

Team Physicians Help White Sox
Take Home a World Series Trophy

Preserving Motion: Total Disc Replacement May Provide Alternatives to Fusion Surgery

Minimally Invasive Fracture Surgery: An Overview



ATI



Athletic & Therapeutic Institute

Experience for Yourself Why Physicians are Choosing ATI:

- *One-to-One Physical Therapy*

- *Innovative and Research-Based Work Conditioning/Hardening Program (F.I.R.S.T.™)*

- *Legally Defensible Functional Capacity Assessments (FCAs)*

- *Personalized Sports Performance Enhancement Programs*

- *Unparalleled Sports Medicine Program*



ATI

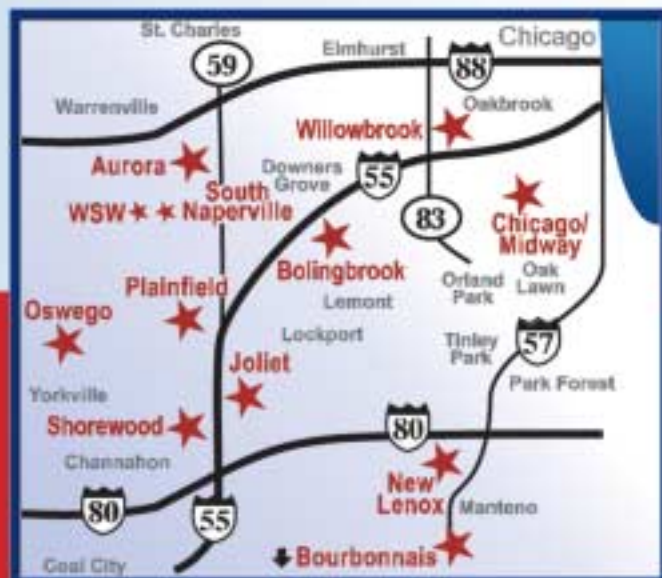Athletic & Therapeutic Institute

Standing out in RehabilitATIOn.



ATI's promise and reputation for unsurpassed **one-to-one** care earns the trust of many physicians as the right choice for their patients.

www.ATIPT.com



Visit www.ATIPT.com for additional location information

Orthopaedic EXcellence

Volume 2 • Issue 3



In this issue

**Midwest Orthopaedics at Rush
Makes the Grade...and the Cover!**
Staff Physicians Win Repeat Honors as 'Top Doctors'6

Lateral Epicondylitis: Causes and Treatments
Patience Is a Prime Factor
in Recovery from Tennis Elbow
By Gregory P. Nicholson, MD8

Keeping Up with the Lawmakers
Understanding the 2005 Amendments to the Illinois
Workers' Compensation Act
By Eugene F. Keefe, JD10

Preserving Motion
Total Disc Replacement May
Provide Alternatives to Fusion Surgery
By Frank M. Phillips, MD12

Perfect RX for a World Championship
Team Physicians Help White Sox
Take Home a World Series Trophy
By Dennis Viellieu18

Shoulder Rehabilitation after Surgery
Early Physical Therapy Allows
Optimal Outcomes for the Patient
By Kimberly A. Kollwelter, PT, DPT, MSPT, CIMT, STC, CSCS20

Minimally Invasive Fracture Surgery
An Overview
By Walter W. Virkus, MD24

At the Cutting Edge
The New Field of Cartilage Transplantation Brings Fresh
Options for Repairing Damaged Shoulders
By Brian J. Cole, MD, MBA, and Andreas H. Gomoll, MD26

Be Wary During Winter
Local Health Talk
By Trish Palmer, MD28

Directory38

Orthopaedic Excellence is published by QuestCorp Media Group, Inc., 885 E. Collins Blvd., Ste. 102, Richardson, TX 75081. Phone (972) 447-0910 or (888) 860-2442, fax (972) 447-0911, www.qcmedia.com. QuestCorp specializes in creating and publishing corporate magazines for businesses. **Inquiries:** Victor Horne, vhorne@qcmedia.com. **Editorial comments:** Brandi Hatley, bhatley@qcmedia.com. Please call or fax for a new subscription, change of address, or single copy. Single copies: \$5.95. This publication may not be reproduced in part or in whole without the express written permission of QuestCorp Media Group, Inc. QC Creative is a full-service graphic design firm, www.qccreative.com. **Creative services inquiries:** Todd Hagler, thagler@qcmedia.com.

President's Letter



Let me first wish everyone all the best for 2006 and beyond. I hope 2005 was as fun and exciting for you and your organizations as it was for me and Midwest Orthopaedics at Rush (MOR). My personal involvement in the White Sox World Series Championship was an absolute blast, something I'll always remember. We were also excited about the improvement in the Rush Orthopaedic Department's *U.S. News and World Report* ranking from tenth in the country in 2004 to eighth in 2005. We believe our close collaboration with Rush University Medical Center, Rush University, and the Department of Orthopaedics at Rush will enable us to keep providing the best possible care to your patients as we advance our standing among the nation's best orthopaedic programs.

MOR continued to expand in 2005 with the addition of Rush physicians Steve Gitelis, MD, and Walt Virkus, MD. Drs. Gitelis and Virkus will enhance our clinical capabilities in orthopaedic oncology, in which they both have a nationally recognized practice, and orthopaedic trauma, which Dr. Virkus practices. This broadening of our service should benefit your patients and organizations. We also strengthened our primary care sports medicine program by bringing on board Trish Palmer, MD, from the University of Utah, and bolstered our spine section with the skills of Kern Singh, MD. Dr. Singh joined us in September 2005 after completing a spine surgery fellowship at Emory University. All four of these physicians will increase and improve our ability to provide care to your patients as conveniently and efficiently as possible.

In 2006, we will expand our foot and ankle section with the addition of Johnny Lin, MD. Dr. Lin is completing his foot and ankle fellowship at the University of Tennessee's Campbell Clinic and will join our practice in September. We are also planning to add a joint replacement physician at Rush and a primary care sports medicine physician at our Central DuPage Hospital (CDH) office. We think these new staff members will help us provide more timely care for your patients. Having the right physicians in MOR is the most important responsibility our group undertakes. Each addition to our practice involves much scrutiny and deliberation. Growing the organization is not our goal. Rather, we want to bring in physicians who will best serve your needs and those of your patients. In some areas, we continue to struggle with meeting the demand for our services and providing care in an appropriate, patient-friendly timeframe. The addition of the new physicians mentioned here should help us address this issue.

In August 2005, we opened a new office in CDH's new Ambulatory Services Pavilion. We look forward to expanding our presence at this location and in the western suburbs. We also enlarged our administrative offices in Westchester to accommodate current and future growth. This summer, we plan to open a new clinic next to the Westchester administrative site. We are also evaluating a dedicated orthopaedic outpatient clinic on the Rush campus that would allow us to consolidate our existing fragmented Rush Professional Office Building and downtown facilities. We plan to open in 2009 as we move ahead with this project. We look forward to continuing our sports medicine/team medical services programs with the Chicago White Sox, Chicago Bulls, Chicago Rush, Chicago Bandits, Chicago Blaze, and Chicago Steel. We hope to expand these programs in 2006 by adding the Chicago Force, a new women's professional football team, as well as by implementing an outreach program focused on providing athletic training, injury prevention, and safety programs and services to sports clubs across the Chicago area.

We would like to hear from each and every one of you regarding your experiences — good and bad — with our organization. Please feel free to contact me or our CEO, Dennis Viellieu, at 708-236-2611 if we can help you with anything.

God bless and have a great year.

Charles A. Bush-Joseph, MD
Managing Member, Midwest Orthopaedics at Rush
cbj@rushortho.com

Orthopaedic Excellence

A publication from
Midwest Orthopaedics at Rush
www.rushortho.com

Central DuPage Hospital
25 North Winfield Road
Winfield, IL 60190
Toll free: (877) MD-BONES
Phone: (630) 682-5653
Fax: (630) 682-8946

Chicago – South Loop/River City
800 South Wells, Suite M30
Chicago, IL 60607
Toll free: (877) MD-BONES
Phone: (312) 431-3400
Fax: (312) 427-6116

Oak Park Hospital
Medical Office Building
610 South Maple Avenue, Suite 1400
Oak Park, IL 60304
Toll free: (877) MD-BONES
Phone: (312) 243-4244
Fax: (312) 942-1517

RUSH University Medical Center
1725 West Harrison Street, Suite 1063
Chicago, IL 60612
Toll free: (877) MD-BONES
Phone: (312) 243-4244
Fax: (312) 942-1517



Physician Listing

Howard An, MD

Spine, Back, and Neck

Gunnar Andersson, MD

Spine, Back, and Neck

Bernard Bach Jr., MD

Sports Medicine

Richard Berger, MD

Joint Reconstruction

Charles Bush-Joseph, MD

Sports Medicine

Mark Cohen, MD

Hand, Wrist, and Elbow

Brian Cole, MD

Sports Medicine, Cartilage
Restoration

Craig Della Valle, MD

Joint Reconstruction

John Fernandez, MD

Hand, Wrist, and Elbow

April Fetzer, DO

Physical Medicine/Pain
Management

Joseph Fillmore, MD

Physical Medicine/Pain
Management

Jorge Galante, MD

Joint Reconstruction

Steven Gitelis, MD

Orthopaedic Oncology/Joint
Reconstruction

Edward Goldberg, MD

Spine, Back, and Neck

George Holmes Jr., MD

Foot and Ankle

Joshua Jacobs, MD

Joint Reconstruction

Simon Lee, MD

Foot and Ankle

Gregory Nicholson, MD

Sports Medicine and Shoulder

Trish Palmer, MD

Sports Medicine and Women's
Sports Medicine

Wayne Paprosky, MD

Joint Reconstruction

Frank Phillips, MD

Spine, Back, and Neck

Anthony Romeo, MD

Sports Medicine, Elbow,
and Shoulder

Aaron Rosenberg, MD

Joint Reconstruction

Mitchell Sheinkop, MD

Joint Reconstruction

Kern Singh, MD

Spine, Back, and Neck

Scott Sporer, MD

Joint Reconstruction

Nikhil Verma, MD

Sports Medicine and Shoulder

Walter Virkus, MD

Orthopaedic Oncology/Trauma

Kathleen Weber, MD

Sports Medicine and Women's
Sports Medicine

YeJia Zhang, MD

Physical Medicine/Pain
Management

Chairman's Letter



The Department of Orthopaedic Surgery at Rush University Medical Center had a banner year in 2005, one marked in particular by the opening and success of the Spine and Back Center. The new center further enhances clinical collaboration across orthopaedics, neurosurgery, and psychiatry clinicians and specialties, resulting in better, more comprehensive care for patients. We are looking forward to this program's continued success and expansion.

We are also very happy to note that our orthopaedic program improved in national ranking from tenth to eighth in *U.S. News and World Report's* "Best Hospitals" issue. As we move ahead, we will continue to work hard and focus on innovation to maintain our place among the top institutions in the United States.

On the individual front, some of our foremost physicians have once again been recognized and named to leadership positions at the national level. Bernie Bach, MD, Director of Sports Medicine at Rush, has been named President of the Herodicus Sports Medicine Society and President-Elect of the American Orthopaedic Society for Sports Medicine, the world's most renowned sports medicine organization. In 2005, Bernie was also named to the endowed Claude Lambert-Susan Thompson Chair in Orthopaedics.

Honors also went to Josh Jacobs, MD, who was elected President of the Orthopaedic Research Society, a very prominent, prestigious national post in orthopaedics. Dr. Jacobs chairs the American Association of Orthopaedic Surgeons' Council on Research and is a member of the National Institutes of Health Advisory Council on Musculoskeletal Research, as well.

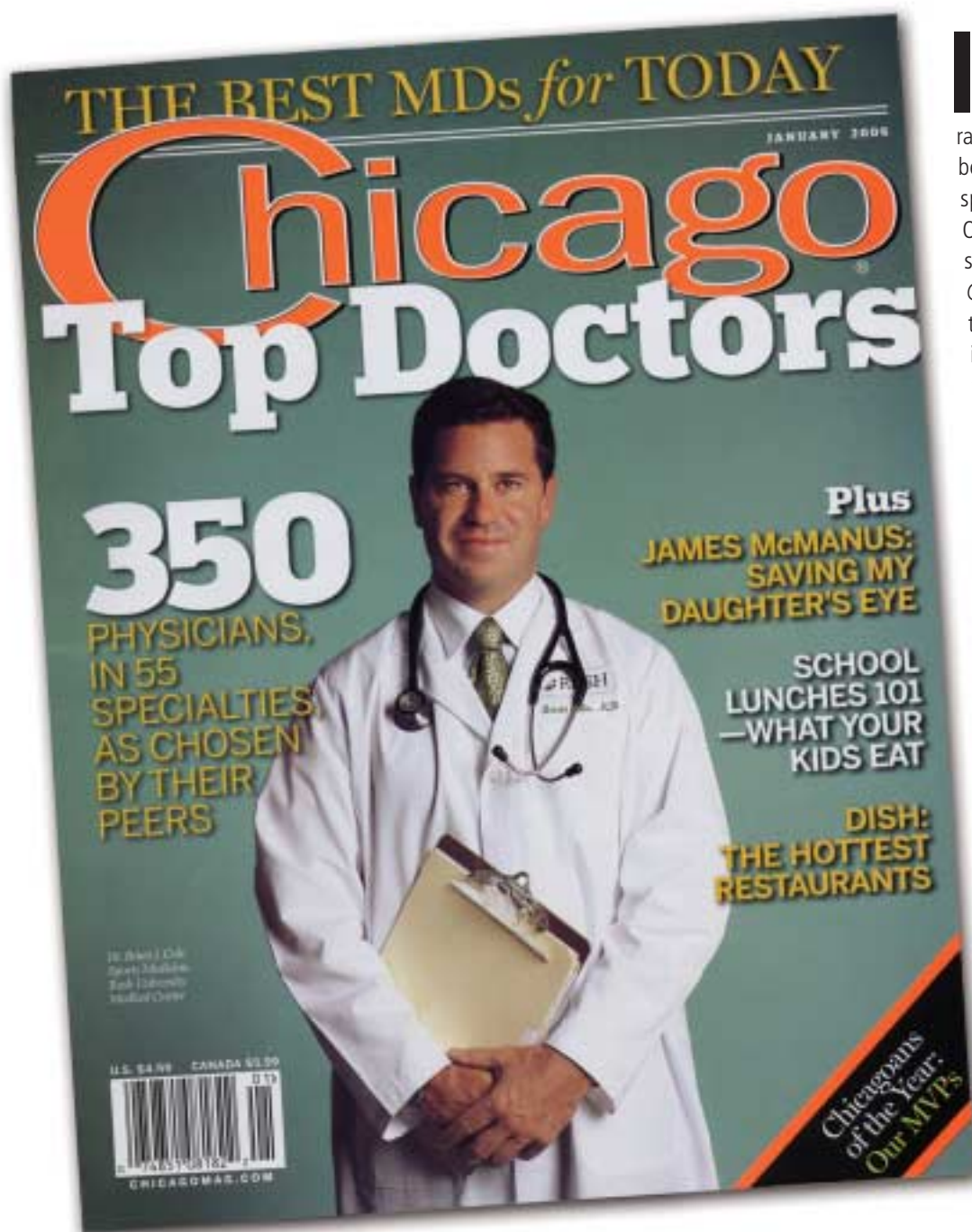
In other news, the department is developing a single destination facility for delivering outpatient orthopaedic care at Rush through Rush University Medical Center and Midwest Orthopaedics at Rush. A new facility of this type on Rush's campus can become a national orthopaedic destination for patients, students, and clinicians. This collaboration could also improve the quality of our research, the delivery of our care, and the integration of our services across multiple specialties. It is a dream we hope to realize.

Best regards,

Gunnar Andersson, MD, PhD
Department of Orthopaedic Surgery
Rush University Medical Center

Midwest Orthopaedics at Rush Makes the Grade...and the Cover!

Staff Physicians Win Repeat Honors as 'Top Doctors'



Imagine walking into your local grocery or convenience store and discovering your own face staring back at you from the magazine rack. How would you feel? Surprised? Flabbergasted? Embarrassed? Brian J. Cole, MD, a sports medicine physician with Midwest Orthopaedics at Rush (MOR), describes just such an experience as “a bit unnerving.” *Chicago Magazine* honored Dr. Cole as one of the area’s “Top Doctors” in its January 2006 issue and put him on the front cover. Once the initial shock passed, Dr. Cole found much to appreciate in the recognition. “It was a great honor being selected and put on the cover, not to mention a lot of fun,” he says.

Chicago Magazine also profiled Dr. Cole in the inside pages. The story focused on his groundbreaking research and work in cartilage transplantation and in shoulder, elbow, and knee arthroscopy. The article also noted his roles as head team physician for the Chicago Bulls and team physician for the Chicago White Sox.

Three other MOR physicians joined Dr. Cole in being honored as “Top Doctors.” The first is Bernard R. Bach Jr., MD. Dr. Bach directs the Rush sports medicine program. He is also President of the Herodicus Sports Medicine Society, President-Elect of the American Orthopaedic Society for Sports Medicine, and recipient of the Claude Lambert–Susan Thompson Endowed Chair in Orthopaedics. Dr. Bach has been selected as a “Top Doctor” five consecutive times.

Another honoree was Mark S. Cohen, MD, a hand-and-elbow surgeon who received “Top Doctor” recognition for the fourth consecutive time since joining the practice. Dr. Cohen has directed the Hand and Elbow Section at Rush since 1993. He also serves as Director of Education in Rush’s Department of Orthopaedics. Dr. Cohen has won several research and teaching awards, written 60 scientific papers, and given more than 160 national and international speeches on hand, wrist, and elbow conditions.

Also acknowledged was Jorge O. Galante, MD. Dr. Galante is a founding member of MOR and a worldwide pioneer in joint replacement. For more than four decades, he has earned worldwide recognition, including many national and international awards for his research and clinical contributions in the field of total hip and total knee replacement. Dr. Galante has also been selected as a “Top Doctor” multiple times.

In some respects, Chicago Magazine’s choosing MOR physicians for its 2006 “Top Doctors” list came as no surprise. MOR member and long-time Chairman of the Department of Orthopaedics at Rush, Gunnar Andersson, MD, PhD, points out that MOR is an academically affiliated practice whose physicians subspecialize in specific orthopaedic areas. According to Dr. Andersson, this relationship gives them a certain renown in their field. In addition, MOR physicians are heavily involved with Rush University Medical Center’s fellowship programs in three of the subspecialties, which promote name recognition as well. “These are some of the main reasons for the practice’s success in the “Top Doctor” rankings,” he says.

Midwest Orthopaedics at Rush is a 30-physician, highly subspecialized orthopaedic group practice. *U.S. News & World Report* has ranked the orthopaedic program at Rush as eighth in the nation and first in Illinois. MOR physicians are board certified and fellowship trained in their subspecialties, hold academic appointments at Rush Medical College, are on the medical staff at Rush University Medical Center, and are active in research. The physicians also provide services at Central DuPage and Oak Park Hospitals. ●

For more information about MOR and its physicians, please visit www.rushortho.com or call 877-MD-BONES.

A Sporting Chance

Brian J. Cole, MD, MBA, Sports Medicine, Rush University Medical Center

As director of the Cartilage Restoration Center at Rush, Brian J. Cole, MD, MBA, uses cutting-edge orthopaedic, rehabilitative, and transplant techniques to treat shoulder, elbow, and knee injuries, while also serving as one of the team physicians for the Bulls and the White Sox and as orthopaedic consultant to the Rush, the local arena-football franchise. He lives in Lincoln Park with his wife, Emily, an assistant state’s attorney, and their three children. “My family loves going to the games,” says Cole, 43. “My kids don’t know what it’s like to sit in a regular seat. They have no idea how good they have it.”

Q. Do you have any tips for the average weekend athlete?

A. I think cross-training is important, rather than just focusing on one exercise, like running. Don’t give up running, but find some alternatives, like swimming or ellipticals. Nutrition is clearly important, but people overlook it.

Q. If you do suffer a sports injury, when should you see a doctor?

A. If there is a joint involved and significant pain that does not go away quickly; if there is swelling, stiffness, or any numbness or tingling — those are things that need to be evaluated. You should see someone — it could be your primary-care physician — who can assess whether this is something that needs immediate attention or something that can be watched to the point of resolution.

Q. What is the impact of age on a person’s ability to participate in athletic activities?

A. A component that often gets overlooked is the emotional aspect of what happens as we age. I’m going through it myself. I think about it every single day: what would it mean if I couldn’t run, if I couldn’t lift weights, if I couldn’t be active with my kids? You would be amazed at the psychological impact that something as simple as knee pain can have on an individual. So there is nothing better than when a patient comes in for a follow-up and says, “You changed my life, because I no longer have pain.”

Q. What is different about treating a professional athlete?

A. The first thing is, you always need to look at these people as patients, as individuals with physical problems. But you are trying to safely return them to play and you are trying to move very quickly. So we do things that we obviously wouldn’t do to the general population to try and encourage rapid healing and rehabilitation.

Q. Last March, after Eddy Curry, the Bulls’ young center, experienced potentially life-threatening heart problems, the team sat him down through the end of the season and the playoffs before finally trading him to the New York Knicks. John Paxson, the team’s general manager, was criticized for how he handled the situation. Was that criticism justified?

A. We wanted to do the right thing for Eddy Curry as a human being. John Paxson never let the goal of “we have to win a game” usurp letting all the physicians involved make what they felt was the right medical decision. He did for Eddy what he would have done for his own son. ●

REPRINTED WITH PERMISSION FROM CHICAGO MAGAZINE

Lateral Epicondylitis: Causes and Treatments

Patience Is a Prime Factor in Recovery from Tennis Elbow

By Gregory P. Nicholson, MD

Lateral epicondylitis (tennis elbow) was first described over a hundred years ago. The condition is most prevalent in the fourth and fifth decade of life and is usually the result of overuse. The name actually is inappropriate, because the condition is not an inflammation of the tendon, but a tendinosis (a degenerative condition) of the tendon origin of the common extensor tendons of the forearm, primarily the extensor carpi radialis brevis (ECRB).

Studies have shown that the pathology involves microtears of the tendon with noninflammatory granulation-type tissue replacing the tendon substance. This small area is the origin of the pain. It is truly a “princess and the pea” phenomenon, with the area of tendon pathology being quite small. A similar process can be seen in “jumper’s knee” of the patella tendon and in Achilles’ tendon degeneration.

The diagnosis can be straightforward. A history of lateral elbow pain with an overuse occupation or recreational activity is typical. The vast majority of patients are actually not involved in repetitive activities, though. Typical patients are between 30 and 55 years of age and are

certainly active. The activity is sporadic in intensity, however, and this unevenness may be a contributing factor. Thus, it is not necessary to be involved in repetitive work or sports to be afflicted with the symptoms of lateral epicondylitis.

Diagnosing the Problem

Physical examination will reveal tenderness over the tendon origin at the lateral epicondyle. This pain will be accentuated with resisted wrist extension with the elbow flexed. The pain may be worsened when resisted wrist extension is performed with the elbow positioned in extension.

Resisted long finger extension can help to delineate radial tunnel syndrome symptoms, which are localized more distal to the lateral epicondyle on the forearm. The differential diagnosis can include intraarticular elbow pathology (such as a plica, synovitis, or radiocapitellar joint pathology), radial tunnel syndrome, and cervical disease.

Conservative Treatments First

Most patients will respond to conservative treatment for lateral epicondylitis. Gentle stretching with the elbow extended and the wrist palmar flexed to place the extensor tendons on stretch and then massage to the tendon origin can provide compliance and pain relief.

Progressive, resistive exercise below the pain level can be specified for the forearm muscles.

Counterforce bracing can help “fool” the tendon origin into seeing less force and allow the tendon to heal. Avoiding lifting with the forearm in pronation can help. Injections are not usually indicated,

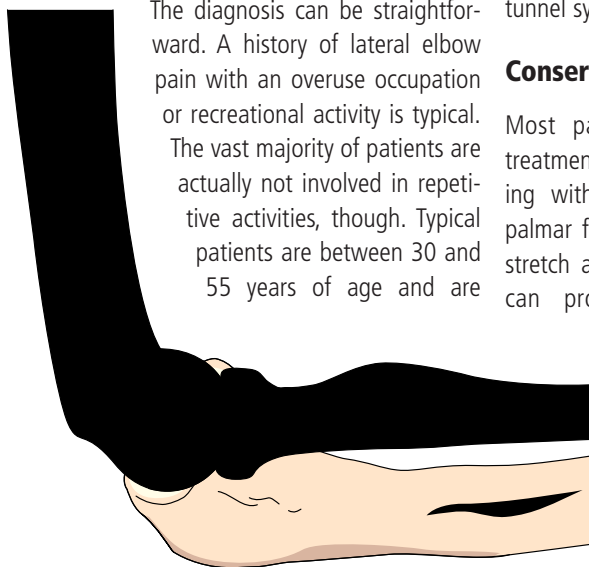
because this condition is degenerative, not inflammatory; however, early in the recovery process a one-time steroid injection can relieve pain and facilitate rehabilitation. Repeated steroid injections are not advised. This condition is stubborn, and the patient should be informed of the variability in symptom intensity over time. It can take six to nine months for symptoms to resolve.

Because of the variability in etiology and time course of resolution of symptoms, many differing types of treatments have been attempted. These other nonsurgical treatments have included extracorporeal shock treatment, botulinum toxin (botox) injections, office percutaneous tenotomy, blood injections, and multiple corticosteroid injections.

If conservative measures fail and the patient remains symptomatic after six months of treatment, then surgical intervention is considered. Remember, however, that the presentation and time course can vary considerably among patients. Most patients will respond to time, activity modification, and some form of therapy as discussed above. When surgery is considered, the surgical treatment should address the underlying pathology, namely the degenerative area in the tendon origin of the ECRB tendon.

Surgical Options

There are many described operations for lateral epicondylitis; however, simple excision in an elliptical fashion of the affected degenerative tendon area (a surprisingly small area) in the origin of the ECRB with repair of the longitudinal tendon excision has shown consistent results with regard to excellent pain relief and strength return. Patients are usually immobilized for one week, and then range-of-motion exercises are initiated.



Lateral view of the elbow joint showing relative positions of skeletal structures (humerus, radius, and ulna)

Strengthening exercises are begun at four weeks postoperatively; and usually at around four months out, the patient can return to work and resume sports and activity with unlimited upper extremity movement. The physicians at Midwest Orthopaedics at Rush do not advocate lateral epicondylectomy or complete release of the tendon origin. These types of procedures have the potential to violate the lateral ligament complex.

Arthroscopic approaches to lateral epicondylar tendon pathology have shown the ability to access the abnormal tendon region. Intraarticular pathology can be identified and addressed with this approach. Thus, if there is a suspicion of concomitant intraarticular pathology, the arthroscopic approach can be utilized.

The arthroscopic approach has also emphasized the fact that the ECRB tendon origin is proximal to the midportion of the radiocapitellar joint. This location has implications for both the open and arthroscopic approaches. Surgical dissection or excision below the "equator" of the radiocapitellar joint can inadvertently injure the lateral ligament complex, which can lead to a postoperative complication of lateral rotatory instability of the elbow. This complication can cause significant disability and should be avoided.

Reasons for surgical treatment failure can include a concomitant radial tunnel syndrome, intraarticular pathology, and damage to the lateral ligamentous structures of the elbow, as discussed above. Activity modifications and use of the counterforce brace may still be needed in a percentage of patients as they return to work and sport activity. The average time to return to full-duty work and sports varies with the intensity of the activity, but three to five months is not uncommon.

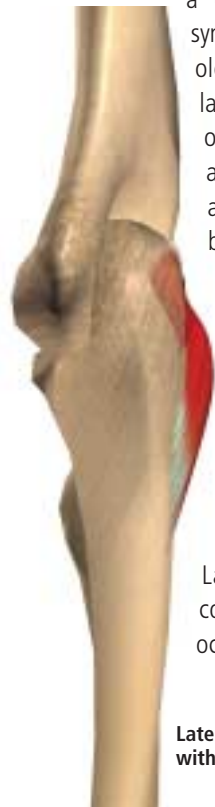Lateral epicondylitis is a common elbow condition occurring in the fourth to sixth

decades of life. It can have a variable and stubborn time course. The vast majority will respond to proper activity modifications, therapy, and patience. Surgical treatment, if indicated, should address the underlying tendon pathology. ●



Gregory P. Nicholson, MD, a medical graduate from Indiana University School of Medicine, completed his internship and residency at University Hospital of Cleveland and served a

fellowship in shoulder surgery at the New York Orthopaedic Hospital at Columbia-Presbyterian Medical Center in New York City. Dr. Nicholson is Board Certified by the American Board of Orthopaedic Surgery and a Fellow of the American Academy of Orthopaedic Surgeons. He specializes in shoulder and elbow surgery, utilizing state-of-the-art arthroscopic and open surgical techniques to treat sports-related, traumatic, arthritic, and occupational conditions.



Lateral view of the anconeus muscle with bony attachments.

MERGE eFILM

Accelerating Productivity

FUSION PACS™

FUSION PACS is comprised of integrated software application modules which build the foundation for a comprehensive, successful PACS solution.

FUSION OrthoView™

In conjunction with FUSION PACS, FUSION OrthoView provides a complete pre-operative planning and templating system for knee, hip and shoulder surgery.

Partnering with

Midwest Orthopaedics at Rush

to Accelerate Productivity

www.merge-efilm.com

Keeping Up with the Lawmakers

Understanding the 2005 Amendments to the Illinois Workers' Compensation Act

By Eugene F. Keefe, JD, Keefe & Associates, Chicago, IL

On July 20, 2005, the governor of Illinois signed HB2137 (Public Act 94-0277), a bill that made significant changes to the state's Workers' Compensation Act. Some of the more important changes included those focusing on a medical fee schedule, utilization review, balance billing, delayed payment penalties, and past due interest rates. Here are some of the highlights of note for caregivers and medical billers.

Medical Fee Schedule

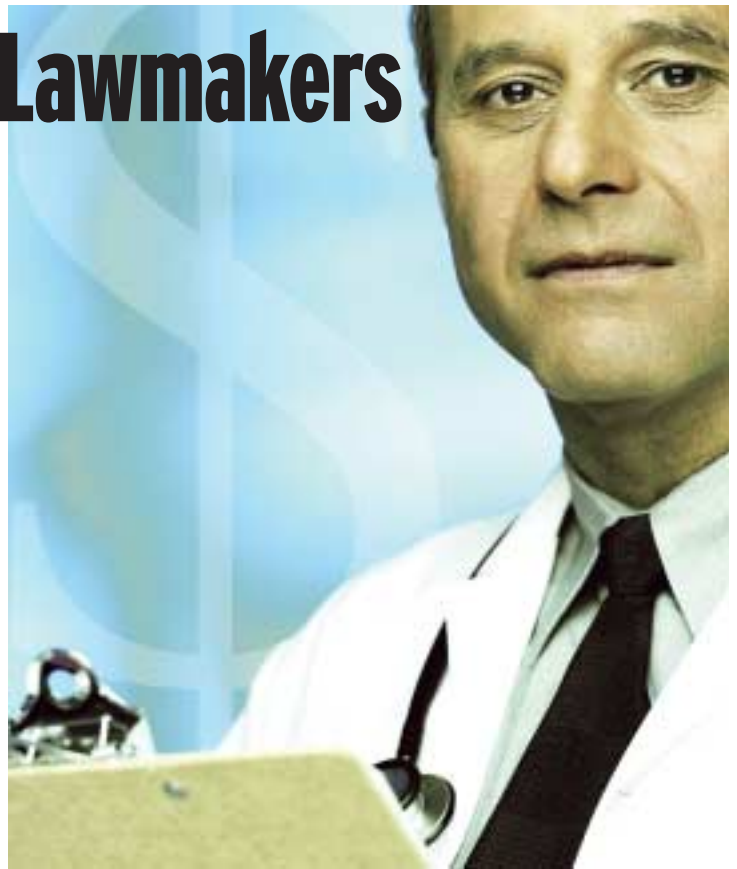
February 1, 2006, the Illinois medical community implemented a new global medical fee schedule that applies to all work-injury-related treatment. The schedule applies to all medical caregivers providing such treatment. Many observers feel the new schedule may speed up the determination of whether a claim is compensable. We feel insurance carriers/third-party administrators (TPAs) may want to quickly determine compensability so as to move work injury cases into the fee schedule and not cause medical providers to send medical bills at much higher "sticker price" rates. Prior to implementation of the medical fee schedule, insurance carriers/TPAs had no incentive to make such a determination — they were getting hit with high workers' compensation bills whether they accepted the claim or not. We were told the increased speed in determining compensability was one impact of implementation of medical fee schedules in other states, particularly Michigan and Wisconsin — once they brought in the fee schedule, adjusters were told to make a clear determination on compensability as

rapidly as possible. If that happens, the change will mark an improvement for the medical community and the insurance industry.

Speeding compensability determinations will help both insurance carriers/TPAs and the medical community as it should provide more certainty of costs for the carriers and rapid payment for the medical providers. We also feel quicker compensability determinations will lessen the need for litigation and attorney involvement on both sides, resulting in lower overall claim costs. Finally, we were aware of a number of physicians and other caregivers who would many times choose to make a questionable claim a work-related claim because they could charge effectively unlimited medical fees versus the discounts provided by group health providers, if a claim was found by the doctor not to be related to work. A medical fee schedule should slow or stop this practice because there will be discounts for both work-related treatment and nonwork-related care.

Under the new fee schedule requirements, Keefe & Associates strongly urges all medical providers to start doing three things for each claim:

- Get the name, phone number, and fax number of the workers' compensation (WC) bill payer as soon as possible; follow up to see if the claim has been accepted as compensable.



Speeding compensability determinations will help both insurance carriers/TPAs and the medical community as it should provide more certainty of costs for the carriers and rapid payment for the medical providers.

- Fax reasonable medical documentation about the treatment plan and care provided, along with recommendations regarding lost time and/or work restrictions, with each billing.
- Always, always get group health care insurance information as a backup in case all or some of the medical bills are disputed at any time.

All parties are waiting for the databases necessary to input the fee schedule into bill payer systems. The medical fee schedule directs payment of 90% of the 80th percentile of fees as the Illinois standard for WC medical billing. When the databases are released, all bill payers in the WC defense industry will hustle to get this information into their computers and pay discounted bills.

Miscellaneous concerns include whether doctors and hospitals will take WC patients at these rates. We understand the medical fee cuts are not as severe as most group health plans sought. There is also no intention to implement the medical fee schedule by using a multiplier of Medicare reimbursement, as other states have done.

If you dislike the fee schedule, avoid it!!! The new law allows doctors and medical caregivers to

contract directly with employers or insurance carriers/TPAs for any service at any rate. There is no provision requiring injured workers to go to a specific provider, however. We are advising all occupational health providers to set up agreements directly with employers and carriers. If you already have such an agreement or a preferred provider organization in place, have the document amended to state that the provisions fall outside of the fee schedule.

Utilization Review

Utilization review (UR) can now be used in Illinois WC claims to dispute reasonableness and necessity of medical treatment and lost time. This concept is new to Illinois and will be further developed in the years to come. In addition to optimizing medical treatment, UR might be used to demonstrate that a claimant should be back at modified or full work. Many states have implemented UR with great success and to the satisfaction of the medical community and employers alike.

Balance Billing

What happened to balance billing? The practice, which involves taking partial payment from the carrier while continuing to bill the employee, is now illegal — sort of. The unusual aspect is that while it is clearly against the “law,” there is no penalty. We understand some providers will still do it. Potential methods do exist to stop balance billing, however. We suggest you contact counsel if you plan to continue the practice.

Medical billers and medical caregivers still have a problem that the new amendments do not address. Medical providers and insurance carriers/TPAs are not actually parties to WC claims. So what do they do if they disagree about the medical fee schedule? The legislation created no formal or informal procedure to resolve medical bill payment disputes. In response, we have recommended that the Illinois Workers’ Compensation Commission consider creating a bill dispute panel similar to one that exists in Wisconsin.

Another action that is clearly proscribed but has no penalty attached is that of medical providers seeking to collect from WC patients while WC issues are under dispute. The idea behind the proscription is to slow down overzealous collection actions that can affect an injured worker’s credit rating during bona fide litigation. No one knows if

this concept will change collection agency practices. Veteran observers feel many agencies, never known for adhering closely to the law, may simply ignore this one.

Under the balance billing amendment, work-related medical treatment bills are now due within 60 days on undisputed compensable bills. The sole requirement is that medical bills must be accompanied with “substantially all data.” There is no definition of “substantially all data,” but we assume it means CPT and ICD9 codes and dates of service.

Delayed Payment Penalty

Starting February 1, 2006, injured workers in litigation may be entitled to a \$30-per-day penalty for unreasonable delay or nonpayment of medical and temporary total disability benefits. Claims that are not litigated may not be subject to this “late fee.” Most doctors and other caregivers continue to wonder why the patient gets a bonus when they are not being paid in a similar fashion. You can take that up with your lobbyists. There seems to be no defined reason for this provision other than to penalize Illinois business and “reward” litigious claimants.

Past Due Interest Rate Changes

Doctors, hospitals, and other medical caregivers will be able to charge 1% per month as interest on unpaid medical bills with appropriate documentation. Due to the double whammy of the new interest charges and the \$30-per-day penalty, you should assume medical billers will immediately receive rejected claims if they lack CPT and ICD9 codes and dates of service, along with a form letter outlining the missing information. Such letters may reduce exposure to delayed payment penalties.

Illinois Medical Fee Schedule Advisory Board

As a final note, a Medical Fee Advisory Board has been appointed and has already met and voted on implementation of the schedule. By the time this is published the Illinois fee schedule should already be in place. A searchable, downloadable schedule will be posted on the Workers’ Compensation Commission’s Web site. Further information may be found on the web at <http://www.state.il.us/agency/iic/WCMFAB.pdf>. ●



Eugene F. Keefe received his Bachelor's degree from Loyola University of Chicago and graduated from John Marshall Law School. He is a member of the Chicago Bar Association, Illinois Workers' Compensation Lawyers Association, and Workers' Compensation Claims Association. Keefe is the editor for Workers' Compensation Law Update as well as the co-author of "The Road to Understanding Workers' Compensation", Journal of Workers' Compensation, Vol. 4, No. 2, Winter, 1995, Standard Press, Boston, MA.

RUSH OUTPATIENT PHYSICAL THERAPY

RUSH Outpatient Physical Therapy provides customized, state-of-the-art care and easy access to the full range of specialty services available at RUSH University Medical Center. And we're proud to be affiliated with the Chicago area's #1 orthopedics program.

We offer:

- One of the few comprehensive balance assessment and treatment programs in Chicago
- A women's physical health specialist
- Education and gait training for amputees
- Pre- and post-surgical rehabilitation
- Rehabilitation for orthopedic and sports injuries
- Spine (back and neck) care
- Treatments for pelvic floor disorders
- A convenient location in the RUSH Professional Building

We accept most insurance plans, including Medicare.

RUSH Outpatient Physical Therapy
1725 W. Harrison, Suite 1006
(312) 563-2454

RUSH UNIVERSITY MEDICAL CENTER

Preserving Motion

Total Disc Replacement May Provide Alternatives to Fusion Surgery

By Frank M. Phillips, MD

Spinal motion-preserving technology in general, and total disc replacement (TDR) in particular, has captured the imagination of the spinal community. In the lumbar spine, this technology has been touted as an alternative to fusion surgery for the treatment of axial low back pain.^{1,2} Cervical disc replacement has a shorter clinical history than lumbar disc replacement and to date has been used following anterior discectomy for the treatment of radiculopathy or myelopathy. Some cervical TDR implants are “shrunk down” versions of their lumbar predecessors, whereas others have unique design characteristics. When considering cervical disc replacement, it is important to understand the specific kinematics, anatomy, disease processes, and treatment outcomes pertaining to the cervical spine.

Issues relating to cervical disc replacement are quite different from those in lumbar disc replacement surgery. Lumbar disc replacement has been considered for the treatment of degenerative disc disease, a condition for which treatment success with fusion has been quite limited.^{1,2} In contrast, fusion following an anterior cervical discectomy has been quite successful. Lumbar disc replacement surgery involves a specific decision to proceed with TDR surgery. In the cervical spine, the decision to proceed with anterior decompressive surgery for radiculopathy or myelopathy is made independent of the choice of reconstruction. Once decompression is accomplished, the surgeon may then decide to proceed with TDR, or placement of a structural interbody device with or without supplementary plate fixation.

Clinical trials (ongoing and planned) for cervical disc arthroplasty include patients having decompression for the treatment of cervical spondylosis giving rise to radiculopathy or myelopathy. The high success rate and long-term track record of

anterior cervical decompression and fusion (ACDF) in the treatment of these conditions, raises the question as to the need for the development of alternate procedures. Proponents of artificial disc technology claim that although cervical arthrodesis is often clinically successful in the short term, fusion results in increased biomechanical stresses at adjacent segments that may hasten degeneration at these levels.^{3,4,5,6} Alternatively,

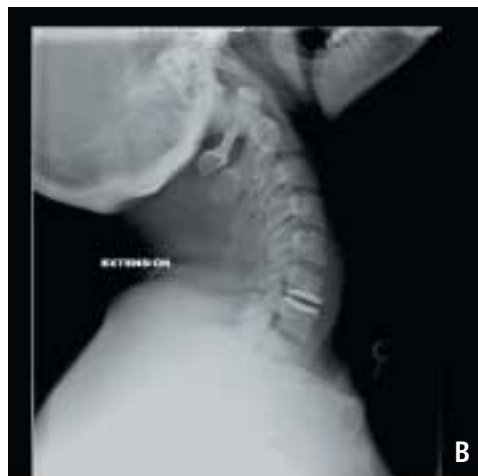
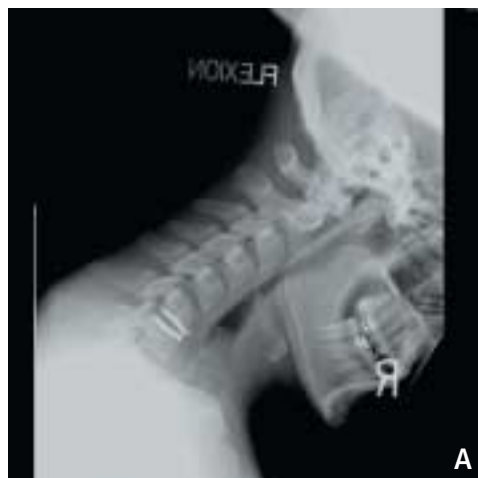
Figure 1: Flexion (A) and extension (B) lateral radiograph obtained six months after insertion of a Bryan TDR at C6-7

artificial disc replacement maintains motion at the operated level, thereby maintaining adjacent level kinematics and reducing the rate of adjacent level degeneration when compared with fusion. The fate of segments adjacent to a fusion has indeed become the rationale for the development of TDR and merits further discussion.

Degeneration Adjacent to Fusion Biomechanical Data

Biomechanical studies have shown that cervical fusion alters adjacent level kinematics^{3,4} whereas TDR leads to a normalization of load transfer and kinematics at adjacent levels when compared with fusion. DiAngelo, et al., have shown that after anterior cervical fusion, the loss of motion at the index level is compensated for by an increase in motion at adjacent segments.³ In contrast, use of an artificial disc replacement did not alter motion at either the instrumented or adjacent levels. Eck, et al., found a 73% and 45% increase in intradiscal pressure at levels cephalad and caudad to a simulated fusion, respectively.⁵ In contrast, after TDR (Bryan, Medtronic Sophamor Danek, Memphis, TN), Wigfield and colleagues recorded stress profiles in the adjacent level intervertebral discs that were similar to those seen in nontreated, intact specimens.⁶ In the adjacent level annulus, the artificial disc led to reduced stresses when compared with spines with a simulated fusion.

Clinical Data

Cervical spondylosis is thought to be an inevitable consequence of aging. After the age of 40 years, almost 60% of the population has radiographic evidence of cervical spine degeneration and by the age of 65 years, 95% of men and 70% of women have at least one degenerative change on roentgenograms.^{7,8,9} The rates of adjacent level degeneration after cervical fusion must, therefore, be compared with this natural history data.

Baba, et al., reported that at an average of eight years after ACDF, 25% of patients developed new onset spinal stenosis adjacent to the previously fused segments.¹⁰ Gore and Sepic observed new spondylosis in 25% of 121 patients and progression of pre-existing spondylosis in another 25% of patients who had undergone prior ACDFs with a mean follow-up of five years.¹¹ They noted no correlation between these new radiographic findings and the development of clinical symptoms. In a follow-up study of 50 patients, Gore and Sepic

described that 14% of patients underwent additional surgery for adjacent level disease after ACDF.¹² It remains challenging to determine whether the reports of degeneration adjacent to cervical fusion reflect only the consequence of altered biomechanics resulting from the fusion, or represent to some degree the natural tendency towards degeneration of the cervical spine with aging, particularly in the group of individuals who have had clinical symptoms and signs leading to surgery. Hillibrand, et al., reported on the long-term follow-up of 409 patients who had anterior cervical decompression and fusion procedures.¹³ They reported that 14% of patients had additional neck surgery over a 21-year period with an average annual incidence of development of adjacent level disease of 3%. The authors noted that anterior cervical fusion performed at more than one level had a significantly lower rate of development of adjacent level disease than those fusions performed at a single level. This outcome seems counterintuitive, as one might have predicted that the longer fusion constructs would result in greater adjacent-level stresses than single-level fusion. Hillibrand, however, noted "the results of this study suggest that adjacent segment degeneration was a common problem, but may reflect the natural history of the underlying cervical spondylosis."¹⁴ In conclusion, review of the literature suggests that although biomechanical studies have proven the deleterious effects of cervical fusion on adjacent level kinematics, the clinical relevance is not clearly established.

Other rationales for the use of cervical TDR relate to the complications or morbidity associated with ACDF. Anterior cervical arthrodesis heals gradually, and it does not always heal. In many cases, surgeons impose limitations on patient activities in an effort to enhance fusion. Such limits may slow the patient's ability to return to normal employment and lifestyle. After disc replacement, patients will likely be able to resume unlimited activities more rapidly. In a small percentage of ACDFs, pseudarthrosis develops that may compromise the ultimate clinical results, leading to a revision surgery.^{15,16} This complication obviously would be eliminated by TDR. In addition, TDR would eliminate the risks and morbidities associated with bone graft procurement for arthrodesis. Before embracing TDR technology, however, it is necessary to ensure that a new set of more significant complications and morbidities are not created by this intervention (**Table 1**).

Table 1. Cervical Disc Replacement: Criteria for Adoption

- Reduce the incidence of adjacent level degeneration compared with fusion
- Equivalent or improved effectiveness in terms of lasting relief of presenting signs and symptoms compared with ACDF
- Long-term durability (wear of bearing surfaces, osseous-integration, subsidence)
- Ease of implantation
- Complication rate that is no higher than that of ACDF, until additional outcome benefits are proven that might outweigh any added risks
- Acceptable cost

Table 2. Cervical Disc Replacement Design Considerations

- Articulation kinematics**
 - One-piece vs. two-piece articulation
 - Constrained vs. unconstrained
 - Fixed vs. mobile axis of rotation
- Materials**
 - CoCr
 - Stainless Steel
 - Titanium
 - Polyethylene
 - Polycarbonate/urethane
- Articulation**
 - Metal-on-polymer
 - Metal-on-metal
- Footplate geometry and dimensions**
- Attachment to bone**
 - Interference fit
 - Porous surface coatings
 - Anchors to vertebral body (screws, fins, spikes)

Disc Design

Implant design characteristics are important for functioning and longevity of TDR. The articulating surfaces must be able to tolerate anticipated load without fatigue or failure, while minimizing friction, and should have superior wear characteristics with minimal debris generation. In addition, the implants must remain permanently affixed to the adjacent vertebral bodies (**Table 2**).

Implant Kinematics

Although the stated goal of all cervical prosthesis designs is to restore, or maintain, normal cervical disc motion after discectomy, the kinematics and biomechanics of cervical TDRs have not been widely reported. Cervical range of motion involves complex coupled motions that may be difficult to reproduce artificially. Puttlitz, et al., have reported recently that in a cadaveric model, a ball-and-socket design disc prosthesis (Prodisc C, Synthes, Paoli, PA) produced normal physiologic motion and maintained coupled motion patterns.¹⁷ The importance of restoring physiologic motion in a degenerating motion segment that is naturally tending towards decreased range of motion is

unclear, as are the consequences. In addition, the increased motion after TDR may allow for ongoing nerve irritation unless the neural elements are adequately decompressed. It is therefore imperative to decompress the neural elements directly during TDR surgery and probably desirable that the prosthesis provides foraminal distraction

to effect, and maintain, decompression of the nerve roots.

Most TDR articulations have either single-gliding or double-gliding interfaces. The geometry of articulations in current double-gliding designs of cervical TDR includes ball-and-socket and saddle designs that permit rotation and in some instances translation. In order to protect the facet joints from abnormal stresses, the implant should have an axis of rotation (AOR) that mimics that seen in the normal spine. In certain implant designs the AOR remains fixed, whereas in others it is dynamic.

Implants may be constrained or relatively unconstrained, in which case they are reliant on surrounding soft tissues to provide restraint to extremes of range of motion. With unconstrained implants, appropriate soft tissue tensioning is important for stability. Retention of the posterior longitudinal ligament has been shown to enhance stability after discectomy when placing a cervical prosthesis.¹⁸ Generally, unconstrained devices allow translation and diminish stress concentration at specific points on the articulating surfaces. The lack of constraint may, however, subject the facet joints to greater shear and torsional loads.^{19,20} These unconstrained devices have a mobile AOR, so that they may be more forgiving of small errors in implant placement. More constrained devices achieve greater stability; however, they create greater stresses at the implant–bone interfaces. Constrained devices generally have a fixed AOR and in theory minimize shear at the facet joint.¹⁹ Devices with a fixed AOR may be less forgiving, however, and require precise anatomic placement so that the TDR AOR mimics the natural posterior AOR of the motion segment.

Implant Materials

Metal composition of the prosthesis is an important design consideration. Cobalt chrome (CoCr) alloys have been used extensively as bearing

Table 3: Cervical Disc Prostheses

					
	Bryan	Prestige, Prestige LP	ProDisc-C	PCM	CerviCore
Footprint					
Footprints available	Diameter mm 14 15 16 17 18	Width depth mm 12* x 12 12* x 14 12* x 16 12* x 18	Width depth mm 15 x 12 15 x 14 17 x 14 17 x 16 19 x 16 19 x 18	Width depth mm 15 x 12 17 x 12 20 x 17	Width depth mm 12x12 12x14 14x16 16x18
Height	11 mm 10.3 mm compressed	6 mm 7 mm 8 mm	5 mm 6 mm 7 mm	6.3 mm 8.0 mm	5-10 mm
Articulation	Stainless steel- polyethylene- ethylene	Chrome cobalt; metal- on-metal	Chrome cobalt; metal-on- polyethylene	Chrome cobalt; metal- on-polyethylene	Chrome cobalt; metal- on-metal

* Estimated width.

surfaces in joint arthroplasty because of their excellent wear characteristics. Stainless steel alloys have long been used as orthopaedic implants; however, they have not been widely used for arthroplasty because of inferior mechanical properties. Titanium alloys have generally not been widely used for articulating components because of their poor wear characteristics. In the cervical spine, where MRI imaging may be required after TDR, titanium, with its improved MRI imaging compatibility, offers distinct advantages. Surface treatment of titanium, such as coating with nitride or diamond-like carbon, may improve hardness and wear characteristics.^{21,22}

In the appendicular skeleton, generation of wear debris is the primary source of artificial joint implant degradation; and the subsequent tissue and systemic reaction to the debris is an important factor in limiting longevity of the prosthesis. Debris has been associated with osteolysis, implant loosening, and prosthesis failure.^{23,24} These complications are influenced by not only the number, but also the size and shape of the wear particles.²⁵ Debris may be generated by wear, fretting, or fragmentation. Polyethylene-on-metal provides a low friction articulation, but generates polyethylene wear debris. Polyethylene wear is an established cause of failure of hip and knee arthroplasty. Cross-linking with gamma irradiation has been used to improve wear properties of ultra-high molecular weight polyethylene, but

this process can also affect the mechanical properties.^{26,27} Metal-on-metal articulation has gained popularity because of dramatically lower wear rates compared with polyethylene-on-metal articulations. Although with metal-on-metal articulations the wear debris generated is markedly less volumetrically, there are greater numbers of debris particles that are smaller than particles generated by polyethylene-on-metal articulations. Enthusiasm for metal-on-metal articulating surfaces must be tempered by reports of systemic metal deposition after hip arthroplasty, although no adverse clinical effects have been attributed to the deposition of heavy metal.^{28,29,30} It is uncertain whether dissemination of metallic debris after hip arthroplasty is analogous to an arthroplasty in the relatively avascular, nonsynovial, cervical disc space. In addition, metal-on-metal prostheses provide less shock absorption than metal-on-polyethylene articulations. To date, acceptable rates of wear (typically to 10 million test cycles) have been claimed by the manufacturers of all cervical devices in their U.S. Food and Drug Administration (FDA) Investigational Device Exemption (IDE) submissions. Manufacturers have also reported that wear particles generated have been nontoxic in rabbit studies.

Fixation to Bone

Long-term implant fixation depends on bone ingrowth into the surface of the prosthesis.

Ingrowth depends on initial stability of the implant, pore size, and pore geometry. The initial stability with a TDR depends on soft tissue tensioning, implant surface geometry (corrugated or serrated), and dimensions, as well as any anchoring of the implant to the host bone using, for example, stabilizing fins or screws. Surface coatings to improve bony ingrowth include titanium wire mesh, plasma-sprayed titanium, porous CoCr, and bioactive materials, such as hydroxyapatite and calcium phosphate. Although not well characterized in cervical implants, good bony ingrowth into the surface of lumbar disc implants has been demonstrated in nonhuman primates.¹⁹

The potential for implant subsidence remains a concern with total disc implants. This phenomenon has been described after lumbar TDR.³¹ Subsidence could lead to implant loosening and altered implant kinematics affecting TDR function and wear characteristics. It also leads to increased stresses on the facet joints. Maintaining the harder subchondral bone during discectomy, and placing a large enough implant footplate that is anchored on the peripheral apophysial ring and the harder lateral uncovertebral bone, may reduce the risk of subsidence.³² With aging and development of osteoporosis, the impaired ability of the cancellous bone of the vertebral body to support the vertebral endplates may, however, place an implant at risk for late subsidence and failure.

Clinical Trials

There are cervical disc replacement designs by a number of companies undergoing FDA IDE studies in the United States. These include the Prestige and Bryan discs (Medtronic Sofamor Danek, Memphis, TN), ProDisc Cervical (Synthes, Paoli, PA), and the PCM (Cervitech, Roundhill, NJ). At the time of this writing, the CerviCore (Stryker, Rutherford, NJ) is awaiting approval for an IDE study (**Table 3**).

Prestige

The Prestige ST prosthesis, currently in U.S. IDE study, is a two-piece prosthesis constructed of stainless steel, employing a ball-in-groove articulation. This design permits motion in flexion, extension, lateral bending, and axial rotation about the center of rotation of the ball component of the upper base plate. The ball-socket design allows for anterior-posterior translation of the center of rotation. The endplates are roughened by grit blasting to promote bony ingrowth

and are attached to the adjacent vertebral bodies with a locking screw.

Traynelis has reported the results of wear testing (presumably obtained from the implant manufacturer).³³ After 10 million cycles in flexion and extension and 5 million cycles of a coupled axial rotation and lateral bending, 0.37 to 0.42 mm³/million cycles of material were lost. This result compares favorably with the 5 mm³/million cycles of debris generated by CoCr total hip prosthesis. No information as to the size of particles generated was published.

The design of the Prestige ST has been modified (Prestige STLP) to include rails to secure the prosthesis to the adjacent vertebral body endplates, which eliminates the anterior profile of the prosthesis that originally had been placed for screw attachment.

Robertson and Metcalf reported the four-year results in 14 of 17 patients who had a Prestige I prosthesis implanted for "end-stage" disease, in patients who "often had a history of multiple previous fusions."³⁴ Radiographic analysis confirmed maintained motion at the operated segment. In 2002, Robertson reported on patients with single-level cervical radiculopathy or myelopathy who were decompressed and randomized to receive uninstrumented arthrodesis or the Prestige II disc device (precursor to Prestige ST).³⁵ Twenty-seven patients were randomized to each arm. At two years, the arthroplasty groups had retained motion across the operated level and had improved pain and physical function scores when compared with the arthrodesis group. Porchet and Metcalf (2004), reported on what appears to be the same cohort (55 patients) showing clinical improvement in both the ACDF and the arthroplasty groups with radiographic results showing that the Prestige II disc maintained motion at the treated level.³⁶

Bryan Disc


The Bryan disc is a single-piece, metal-on-polymer prosthesis comprised of a polycarbonate/polyurethane core between two porous-coated endplate shells, encapsulated by a polymer sheath. The instantaneous axis of rotation is variable and not limited by the geometry of articulating surfaces normally characteristic of two-piece disc designs. The polyurethane sheath is intended to contain debris and prevent soft tissue ingrowth. The endplates are porous-coated titanium alloy. At the

time of this writing, over 4,000 Bryan prostheses have been implanted worldwide, and a U.S. IDE is in process (**Figure 1**).

Anderson, et al., have reported the results of wear testing for the Bryan Disc.³⁷ After 10 million cycles, the mean height loss was 0.75%. Particles generated had a mean diameter of 3.89 microns. Particle shape varied from those generated after hip and knee arthroplasty testing. After 40 million cycles, endplate-to-endplate

contact was observed. The change in prosthetic height was 0.02mm per million cycles. The authors stated that they believed that 100,000 to 400,000 stimulator cycles represent one year of clinical use. The in vivo inflammatory response of the device was studied in a caprine model at the C4-5 level. No inflammatory response was observed one-year postimplantation.

Goffin, Komusteh, et al., reported similar motion after implantation of Bryan discs at C5-6 as



www.scheckandsiress.com

Scheck & Siress

We help our patients achieve the art of movement through precision and technology

For more than five decades, our highly skilled practitioners at Scheck & Siress have been providing orthotic, prosthetic and pedorthic services to patients throughout the greater Chicago area. The most advanced technology ensures that our patients are comfortable, have the highest quality device available and achieve the greatest degree of mobility possible.

Our certified and licensed practitioners are an integral part of our patients' health-care team. Personal care, follow-up and education are the standard of care at Scheck & Siress.

We are affiliated with many Chicago area hospitals and have 10 locations in the area. Wherever you need care, we're there.

SCHECK & SIRESS
Advanced Orthotics & Prosthetics

ARLINGTON HEIGHTS 617 East Golf Road, Suite 108 847.437.3929	CHICAGO - Rush Pres. St. Lakes 1725 W. Harrison, Suite 829 312.942.2011	NAPEVILLE 1551 Bond Street, Suite 111 630.637.4638
BANNOCKBURN 2101 Waukegan Road, Suite 104 847.444.0690	CHICAGO - UIC 1740 W. Taylor St., Room C100, MC889 312.996.6450	OAKBROOK TERRACE 15376 Summit Ave., Ct. E 630.424.0392
CHICAGO - Lincoln Park 2531 N. Clark St., Suite 200 773.472.3663	HICKORY HILLS 8641 W. 95th Street 708.599.8336	OAK PARK 401 Harrison Street 708.383.2257
SCHERERVILLE, INDIANA 6629 W. Lincoln Hwy (Rt. 30), Suite 1 219.864.9501		

Contact the office in your area

compared with normal volunteers.³⁸ Goffin, Casey, and coauthors reported on 60 patients who underwent single level anterior discectomy and placement of a Bryan disc prosthesis.³⁹ At 12 months they reported success rates of 85% to 90%. Two patients had possible device migration. Range of motion was preserved and no device has been revised or explanted. Duggal and colleagues recently reported on 26 patients treated with the Bryan disc for degenerative cervical radiculopathy or myelopathy.⁴⁰ A significant improvement in Neck Disability Index and a trend towards improved SF-36 scores was noted at 24 months. Motion was preserved at the treated spinal segment (mean 7.8 degrees.) Pickett, et al., reported on 14 patients who received the Bryan disc prosthesis and were followed from six to 24 months.⁴¹ Motion at the index level was similar preoperatively and at final follow-up. The treated level, however, became and remained more kyphotic after insertion of the Bryan prosthesis.

Goffin and associates reported heterotopic ossification (HO) around the Bryan disc with some impact on clinical results.⁴² Development of HO

may be the result of the extensive bone removal (milling) required for implantation of this particular prosthesis. Heller, et al.,⁴¹ have recommended routine use of nonsteroidal antiinflammatory medication in the perioperative period to reduce the risk of HO, and this practice is required in the U.S. IDE study with this prosthesis.

Prodisc-C

The Prodisc-C is constructed of two chromium-cobalt endplates with sagittal fins for fixation into the adjacent vertebral body and a fixed polyethylene core. The joint consists of a concave cephalad component that rides on an ultra high molecular weight polyethylene (UHMWPE) insert fixed to the caudad component. This articulation provides coupled motion without independent translation resulting in a fixed center of rotation in the vertebral body below the disc space. The surfaces of the prosthesis in contact with the vertebrae have a plasma-spray titanium layer to promote bony ingrowth.

Porous-Coated Motion (PCM)

The PCM is a polyethylene-on-metal design with a large radius UHMWPE bearing surface attached

to the caudal endplate, allowing for translational motion. The cobalt-chromium endplates are coated with titanium with electrochemically coated calcium phosphate in a 1:1 ratio. The surface encourages osseous integration. The PCM endplates are shaped to maximize support in the dense lateral bone in proximity to the uncovertebral joints.

Pimenta in Brazil implanted 81 PCM discs in 52 patients who had degenerative disc disease and radiculopathy or myelopathy.⁴⁴ Surgery took approximately 50 minutes per level and estimated blood loss was 50cc per level implanted. Significant improvement in pain-intensity, disability, and analgesic use was noticed at one-year follow-up. Complications included a single prosthesis that displaced 4mm anteriorly and one case of mild HO.

CerviCore

The CerviCore prosthesis is a metal-on-metal (chrome-cobalt) design with a saddle shaped articulation. The designers of this device assert that the articulation allows for maintaining the axis of vertebral rotation in the caudal vertebral



Yep. It's that easy.

Scan it. Save it. Find it in seconds
...from anywhere.

SRS Software
Document Management for Healthcare
800.288.8369 | info@srssoft.com | www.srssoft.com

body during flexion-extension, while simultaneously maintaining the AOR in the cephalad-vertebral body during lateral bending, mimicking the normal disc AOR. The designers also claim that the articulation mimics the function of the uncovertebral articulation and promotes vertebral foraminal widening during coupled rotation and bending. These claims await verification. The base plates feature a titanium spray and three spikes. After placement of the device, bone screws are inserted through anterior flanges into the vertebral bodies. To date there are no reports of clinical implantation of this prosthesis.

Conclusion

Cervical disc replacement is an exciting technology that preserves motion at the instrumented level(s) and will potentially improve load transfer to the adjacent levels when compared with fusion. Clinical reports of success of cervical TDR are encouraging, but are also quite preliminary. The consequences of failure of a cervical TDR implant in close proximity to the spinal cord, the esophagus, and the trachea must be considered. In addition, reconstructive strategies after device failure are likely to be complex. As the U.S. IDE studies are completed, a clearer role for the place of cervical TDR in the spine surgeon's armamentarium should emerge. Most implant designs in trial are quite similar, and alternative design concepts will probably be developed in the future. ●



Frank M. Phillips, MD, a board-certified orthopedic surgeon, specializes in minimally invasive spinal fusion and decompression and total disc replacement surgery. He received his medical degree from the University of Witwatersrand, Johannesburg, South Africa. Dr. Phillips completed his orthopaedic residency at The University of Chicago Medical Center and served a spine fellowship at Case Western Reserve University School of Medicine. He is the principal investigator on the FDA study of cervical disc replacement surgery and has published and lectured extensively on spinal topics.

References

- Guy RD, McAfee PC, Hochschul SH, et al. Prospective randomized study of the Charité artificial disc: data from two investigational centers. *Spine J* 2004;4 (suppl 6):252-9.
- Zigler JE. Lumbar spine arthroplasty using the ProDisc II. *Spine J* 2004;4(suppl 6):260-7.
- DiAngelo DJ, Roberston JT, Metcalf NH, et al. Biomechanical testing of an artificial cervical joint and an anterior cervical plate. *J Spinal Disord Tech* 2003;16:314-23.
- Maiman DJ, Kumaresan S, Yoganandan N, et al. Biomechanical effect of anterior cervical spine fusion on adjacent segments. *Biomed Mater Eng* 1999;9:27-38.
- Eck JC, Humphreys SC, Lim TH, et al. Biomechanical study on the effect of cervical spine fusion on adjacent-level intradiscal pressure and segmental motion. *Spine* 2002; 27:2431-4.
- Wigfield CC, Skrzypiec D, Jackowski A, et al. Internal stress distribution in cervical intervertebral discs: the influence of an artificial cervical joint and simulated anterior interbody fusion. *J Spinal Disord Tech* 2003;16:44-9.
- Lehto JJ, Tertti MO, Komu ME, et al. Age-related MRI changes at 0.1 T in cervical discs in asymptomatic subjects. *Neuroradiology* 1994;36:49-53.
- Boden SD, McCowin PR, Davis DO, et al. Abnormal magnetic-resonance scans of the cervical spine in asymptomatic subjects: a prospective investigation. *J Bone Joint Surg Am* 1990;72:1178-84.
- Gore DR, Sepic SB, Gardner GM. Neck pain: a long-term follow-up of 205 patients. *Spine* 1987;12:1-5.
- Baba H, Furusawa N, Imura S, et al. Late radiographic findings after anterior cervical fusion for spondylotic myeloradiculopathy. *Spine* 1993;18:2167-73.
- Gore DR, Sepic SB. Anterior cervical fusion for degenerated or protruded discs: a review of one hundred forty-six patients. *Spine* 1984;9:667-71.
- Gore DR, Sepic SB. Anterior discectomy and fusion for painful cervical disc disease: a report of 50 patients with an average follow-up of 21 years. *Spine* 1998;23:2047-51.
- Hillibrand AS, Carlson GD, Palumbo MA, et al. Radiculopathy and myelopathy at segments adjacent to the site of a previous anterior cervical arthrodesis. *J Bone Joint Surg Am* 1999; 81:519-28.
- Hillibrand AS, Robbins M. Adjacent segment degeneration and adjacent segment disease: the consequences of spinal fusion. *Spine J* 2004;4(suppl):190-4.
- Tribus CB, Corteen DP, Zdeblick TA. The efficacy of anterior cervical plating in the management of symptomatic pseudoarthrosis of the cervical spine. *Spine* 1999; 24:860-4.
- Phillips FM, Carlson G, Emery SE, et al. Anterior cervical pseudoarthrosis: natural history and treatment. *Spine* 1997; 22:1585-9.
- Puttlitz CM, Rousseau MA, Xu Z, et al. Intervertebral disc replacement maintains cervical spine kinetics. *Spine* 2004;29:2809-14.
- McAfee PC, Cunningham B, Dmitriev A, et al. Cervical disc replacement porous coated motion prosthesis: a comparative biomechanical analysis showing the key role of the posterior longitudinal ligament. *Spine* 2003; 28(suppl):176-85.
- Cunningham BW, Dmitriev AE, Hu N, et al. General principles of total disc replacement arthroplasty: seventeen cases in a nonhuman primate model. *Spine* 2003; 28(suppl):118-24.
- Dooris AP, Goel VK, Grosland NM, et al. Load-sharing between anterior and posterior elements in a lumbar motion segment implanted with an artificial disc. *Spine* 2001; 26:E122-9.
- Hendry JA, Pilliar RM. The fretting corrosion resistance of PVD surfacemodified orthopedic implant alloys. *J Biomed Mater Res* 2001;58:156-66.
- Komu R, Maloney WJ, Kelly MA, et al. Osteoblast adhesion to orthopaedic implant alloys: effects of cell adhesion molecules and diamond-like carbon coating. *J Orthop Res* 1996;14: 871-7.
- Howie DW, Haynes DR, Rogers SD, et al. The response to particulate debris. *Orthop Clin North Am* 1993; 24:571-81.
- JJ Jacobs, Shanbhag A, Glant T, et al. Wear debris in total joint replacement. *J Am Acad Orthop Surg* 1994; 2:212-20.
- Catelas I, Campbell PA, Dorey F, et al. Semi-quantitative analysis of cytokines in MM THR tissues and their relationship to metal particles. *Biomaterials* 2003;24:4785-97.
- Shen FW, McKellop H. Surface-gradient cross-linked polyethylene acetabular cups: oxidation resistance and wear against smooth and rough femoral balls. *Clin Orthop* 2005;430:80-8.
- Bradford L, Baker D, Ries MD, et al. Fatigue crack propagation resistance of highly crosslinked polyethylene. *Clin Orthop* 2004;429:68-72.
- Wagner M, Wagner H. Medium-term results of a modern metal-on-metal system in total hip replacement. *Clin Orthop* 2000;379:123-31.
- Brodner W, Bitzan P, Meisinger V, et al. Serum cobalt levels after metal-on-metal total hip arthroplasty. *J Bone Joint Surg Am* 2003;85:2168-73.
- Urban RM, Jacobs JJ, Tomlinson MJ, et al. Dissemination of wear particles to the liver, spleen, and abdominal lymph nodes of patients with hip or knee replacement. *J Bone Joint Surg Am* 2000;82:457-76.
- van Ooij A, Oner FC, Verbout AJ. Complications of artificial disc replacement: a report of 27 patients with the SB Charite disc. *J Spinal Disord Tech* 2003;16:369-83.
- Link HD, McAfee PC, Pimenta L. Choosing a cervical disc replacement. *Spine J* 2004;4(suppl 6):294-302.
- Traynelis VC. The Prestige cervical disc replacement. *Spine J* 2004;4(suppl): 310-4.
- Robertson JT, Metcalf NH. Long-term outcome after implantation of the Prestige I disc in an end-stage indication: 4-year results from a pilot study. *Neurosurg Focus* 2004;17:E10.
- Robertson J, Porchet F, Brotchi J et al. A multicenter trial of an artificial cervical joint for primary disc surgery. Society for Spinal Arthroplasty. Montpellier, France, May 2002.
- Porchet F, Metcalf NH. Clinical outcomes with the Prestige II cervical disc: preliminary results from a prospective randomized clinical trial. *Neurosurg Focus* 2004;17:E6.
- Anderson PA, Sasso RC, Rouleau JP, et al. The Bryan Cervical Disc: wear properties and early clinical results. *Spine J* 2004;4(suppl 6):303-9.
- Goffin J, Komistek R, Malfouz H, et al. In vivo kinematics of normal, degenerative, fused and disk-replaced cervical spines. AAOS Annual Meeting, New Orleans, February 2003.
- Goffin J, Casey A, Kehr P, et al. Preliminary clinical experience with the Bryan Cervical Disc Prosthesis. *Neurosurgery* 2002;51:840-5.
- Duggal N, Pickett GE, Mitsis DK, et al. Early clinical and biomechanical results following cervical arthroplast. *Neurosurg Focus* 2004;17:E9.
- Pickett GE, Mitsis DK, Sekhon LH, et al. Effects of a cervical disc prosthesis on segmental and cervical spine alignment. *Neurosurg Focus* 2004;17:E5.
- Goffin J, Van Calenberg F, van Loon J, et al. Intermediate follow-up after treatment of degenerative disc disease with the Bryan Cervical Disc Prosthesis: single-level and bi-level. *Spine* 2003;28:2673-8.
- Heller JG, Park AE, Tortolani PJ, et al. CT scan assessment of anterior paravertebral bone formation after total cervical disc replacement: temporal relationships and effects OF NSAID. 19th Annual Meeting of the Cervical Spine Research Society, Barcelona, Spain, 2003.
- Pimenta L, McAfee PC, Cappuccino A, et al. Clinical experience with the new artificial cervical PCM (Cervitech) disc. *Spine J* 2004;4(suppl 6): 315-21.

Perfect RX for a World Championship

Team Physicians Help White Sox Take Home a World Series Trophy

By Dennis Viellieu

It was one Cinderella story after another. The Boston Red Sox did it in 2004, winning the World Series and breaking the Curse of the Bambino that had dogged them since 1918. Then the Chicago White Sox took it all in 2005, winning their first World Series since 1917 and forever putting to rest the embarrassment and shame of the Black Sox scandal of 1919.

One of the keys to success for the 2005 World Champion White Sox was certainly the low incidence of injury, especially among the pitching staff. The White Sox pitchers — some of Major League Baseball's best — stayed healthy, which was vital to the team's incredible 11-1 run through the playoffs.

"Professional baseball teams tread a fine line between success and failure. A few additional effective innings by a pitcher or a position player staying healthy for a couple of extra games can make a huge difference," says Dr. Chuck Bush-Joseph, Lead Team Physician. "We definitely saw that with the White Sox this year as some key players worked through injuries and made important contributions at critical times." Like any other team, the White Sox have had their share of nagging injuries. Sox legend Frank Thomas' foot problems have sidelined him for most of the last two seasons. Dustin Hermanson and Joe Crede have struggled with bad backs, and Jermaine Dye even had to deal with an infected spider bite on a road trip. The White Sox medical team faces these kinds of challenges every day.

Prevention and Quick Response

The primary job of the White Sox medical staff is twofold: first and foremost, prevent injuries that keep players off the field, and second, provide effective treatment when injuries occur and return athletes to action as quickly as possible. Enter the White Sox medical team and its winning prescription.

Longtime Head Trainer Herm Schneider and his assistant Brian Ball head up the White Sox medical staff. Brian and Herm got topnotch

help in 2005 from Midwest Orthopaedics at Rush (MOR), which fields a team of physicians led by Chuck Bush-Joseph, MD, and Kathy Weber, MD. Dr. Weber handles internal and sports medicine issues, while Dr. Bush-Joseph deals with orthopaedic concerns.

With her training in sports medicine, internal medicine, and exercise physiology, Dr. Weber was uniquely qualified to address orthopaedic injuries and medical conditions, such as heat illness, head injuries, allergies, viral infections, high blood pressure, and diabetes. Her comprehensive approach also helped Sox players cope with postseason stress and anxiety. She even treated a player with a champagne allergy, an inopportune complication that arose during the otherwise joyous celebrations.

Joining Dr. Weber to provide internal medicine and medical coverage through spring training and the regular season were MOR physician Trish Palmer, MD, as well as Scott Palmer, MD; Dragan Djordjevic, MD; Joseph Hennessy, MD; and Syed Shah, MD, physicians who practice privately and are affiliated with Rush University Medical Center.

Additional doctors working with Dr. Bush-Joseph to address musculoskeletal issues included fellow MOR staff members Bernard Bach Jr., MD; Gregory Nicholson, MD; Brian J. Cole, MD, MBA; Anthony Romeo, MD; Nikhil Verma, MD; and Mark Cohen, MD.



Left to right: Kathy Weber, MD, and Chuck Bush-Joseph, MD, pictured with the Chicago White Sox's World Series trophy

Experience All Around

This year marked MOR's second season working with the Chicago White Sox. Herm Schneider chose the practice because he needed the most comprehensive medical service available. "I wanted our players, staff, and front office personnel to have the best medical expertise," says Schneider. "In addition, I wanted the team to have access to a full-service academic medical facility like Rush University Medical Center, which is just minutes away from our home field."

The 2005 season was Schneider's third as a trainer for a World Championship team (he worked as assistant trainer with the champion Yankees in 1977 and 1978), and he clearly had demanding expectations for his physician partners. MOR did not disappoint him, and neither did the team. "This season was special because it was my first championship as Head Athletic Trainer, because I've been with the team so long, and because 1917 was the last time this organization won a title," says Schneider.

Herm has been Head Trainer for the White Sox since 1979, so he understands the importance of patience and consistently good medical attention. Over the past three seasons, the White Sox have placed fewer players on the disabled list than any other major league team.

Teamwork, Teamwork, Teamwork

Whenever injuries occurred, MOR physicians were right there to make accurate, rapid diagnoses and to initiate effective immediate care, which helps reduce an injured player's time away from the game. The key to providing this excellent service is the same approach players use to win: teamwork.

"Herm has my cell number, and I have his. It takes a constant flow of communication to keep players healthy," says Dr. Bush-Joseph. "Our close working relationship with the White Sox training staff enabled us to diagnose and treat injuries quickly, minimizing player downtime. That was especially critical in August, when Herm and I really had to stay on top of every injury."

Apart from being on the field for every home game during the season, and every home and away game during the playoffs and World Series, the MOR physician team was also involved with player conditioning and training throughout the year.



Left to right: White Sox Assistant Trainer Brian Ball; White Sox Head Trainer Herm Schneider; MOR member and White Sox Lead Team Physician Charles A. Bush-Joseph, MD; former MOR sports medicine fellow and current Minnesota Twins Team Physician, Pearce McCarty, MD

The team physicians handled a broad range of responsibilities: diagnosing and treating problems on the field; caring for visiting team players, coaches, and umpires; providing follow-up and continued care in the office; doing phone consultations; facilitating emergency care; managing team care on the road; and coordinating all medical personnel involved in ensuring the overall health of the players, their families, and the White Sox staff.

The 2005 Championship Run and Beyond

During the 2005 playoff season, Dr. Bush-Joseph and Dr. Weber were "on call" to travel at a moment's notice. They were with the team for every pitch of every inning of every postseason game. Fortunately, the only major injury came during a victory party when one of the coaches cut his foot on a broken champagne bottle. "I sewed it up right then and there," said Dr. Bush-Joseph. "The patient was already sufficiently anesthetized."

One of the things Dr. Bush-Joseph will always remember was how the team traveled in style, especially in Houston. "Everywhere we went, we had a police motorcycle escort shutting off traffic in front and behind us. This must be how it feels to travel with the President of the United States."

As the only female physician traveling with the White Sox, Dr. Weber inadvertently created an unexpected challenge for the medical team. After

the games clinching the division and league championships, the White Sox wanted to leave immediately for the next playoff location to maximize their preparation time. Since a champagne "bath" accompanied each championship win, everyone needed a shower before getting on the plane. For the males, it presented no problem since the celebrations took place in the men's locker room. Unfortunately, none of these facilities offered a separate shower for women. Between the party's end and takeoff, the medical team constructed a makeshift shower so Dr. Weber could clean up before the trip. "My colleagues and the players were great. They actually got to be very handy at building these temporary showers quickly. We never missed a flight," says a thankful Dr. Weber.

The coming season looks bright for the White Sox and for MOR. "Next year will be our third with the White Sox," says Dr. Weber. "We can use the solid foundation we've built thus far to further develop a model system of comprehensive medical care for individual athletes and the team." MOR physicians and their internal medicine colleagues will cover the entire 2006 Spring Training Schedule in Tucson and provide full coverage for all the home games next season. MOR physicians will also conduct medical evaluations of potential draftees and free agents, which will help the White Sox player development staff make the best personnel decisions for future success. ●

Shoulder Rehabilitation after Surgery

Early Physical Therapy Allows Optimal Outcomes for the Patient

By Kimberly A. Kollwetter, PT, DPT, MSPT, CIMT, STC, CSCS

Shoulder dysfunction is common in today's society. Many individuals, both young and old, experience injuries that require shoulder surgery to help alleviate subjective pain and/or improve function. The most common shoulder surgeries include rotator cuff repairs, subacromial decompressions, SLAP (superior labrum, anterior/posterior) repairs, and Bankart lesion repairs. Following surgery, an immediate physical therapy program is crucial to decrease pain, increase motion, and educate the patient in proper exercises — including how to perform activities of daily living (ADL) without compromising the repaired tissue.

It Hurts to Wait

Typical practice suggests that many surgeons do not refer their patients to physical therapy until one to six weeks postoperatively.^{1,2,3} Most surgeons simply instruct their patients to begin exercising independently during this time period. However, compliance to acute postoperative exercise programs is typically considered low due to increased subjective pain levels. In addition, patients tend to perform these exercises incorrectly or with compensatory movement patterns. Patients are simply not skilled at the exercises or the rehabilitation techniques; and often for years previously, they have utilized compensatory movement patterns, which led to their surgical condition. An immediate physical therapy program following surgery can increase compliance and ensure the patient is completing the exercises without compensation. Following surgery, the most common step is immobilization through the use of a sling. The majority of surgeons keep the shoulder immobilized for a period of three to six weeks.^{2,3,4,5,6,7} Immobilization time varies depending on the quality of tissue repaired, the quality of bone tissue, the magnitude of the tear, the security of the repair, and the surgeon's discretion.^{2,3,6} Immobilization of the repaired tissue is an important step for the healing process, which allows for the repaired tissue to scar down; however, passive range of motion (PROM) exercises performed by a skilled physical therapist may begin day one post-

operatively without putting stress on the involved tissue. It is also important to begin moving the joints down the kinetic change in a controlled manner to decrease stiffness and swelling in the distal joints.

The Benefits of Early Rehabilitation

It has been my clinical experience that patients who are seen by a physical therapist at day one postoperatively have increased range of motion (ROM) and decreased overall pain during their rehabilitation programs. It is much easier to attain full physiological ROM and normal mobility within the glenohumeral joint capsule with early rehabilitation. By waiting the standard one to six weeks postoperatively to begin physical therapy, patients typically begin to have significant restrictions in their capsule, regardless of procedure (acromioplasty, rotator cuff repair, SLAP repair, et cetera). Attaining full ROM after a few weeks of immobilization is much more difficult for the therapist to achieve. Because of these factors, the physical therapist often has to be more aggressive to stretch out the capsule properly, which results in increased pain for the patient. Anecdotally, patients with day one physical therapy report getting off their pain medication earlier than patients who began rehabilitation at a later date. This phenomenon has been shown in the literature as well. Kim et al.⁴ found that individuals who began physical therapy on day one postoperatively displayed increased ROM early on and a faster return to functional activity compared with a group that began formal therapy three weeks postoperatively. Kim et al.⁴ also found that individuals who began therapy immediately had decreased pain. It is important to note that the participants in the accelerated therapy group of this study did not have an increased incidence of reinjury.

Day One of Rehabilitation

Patients presenting to physical therapy postoperatively on day one receive a dressing change and instruction in ADLs. Instruction in ADLs includes donning and doffing the sling in a manner that

does not stress the involved tissue. The first session also involves education on a home exercise program (HEP) and demonstrating to the patient the safe and proper way to don and doff articles of clothing. A common HEP given on day one includes Codman's exercises, gripping exercises, scapular retraction and depression exercises, and active elbow flexion/extension exercises, unless the biceps is an involved structure (biceps tenodesis or some SLAP repairs). Frequently, patients perform Codman's exercises incorrectly and turn this PROM exercise into an active range of motion (AROM) exercise. This simple example illustrates the importance of physical therapist instruction and education regarding the proper rehabilitation technique. Kibler⁸ found that open chain Codman's exercises only create 9% of a maximal voluntary contraction to the rotator cuff if performed correctly. Manual PROM performed by the therapist is also started on day one. Kibler⁸ found PROM exercises that support the upper extremity and emphasize humeral head depression only create 5% of a maximal voluntary contraction. The therapist will perform PROM within the desired range, depending on the type of surgery and the quality of the tissues involved.

Communication Is Key

Communication is the key to understanding almost any issue. In this example, the physical therapist will know only the type of surgery and quality of the tissues involved with adequate communication from the surgeon — typically with a referring script or with a phone conversation. With this information, the therapist will be able to progress the patient early on without putting inappropriate stress on the involved tissue. Interdisciplinary communication between the physician and physical therapist is extremely important to ensure the most optimal outcome for the patient, both postoperatively and nonoperatively. Since many patients do not understand the details and method of the operation performed, the physical therapist is frequently asked questions regarding his or her specific surgery because of the

increased amount of contact time during the patient's rehabilitation sessions. With adequate communication between the physician and the physical therapist, the therapist can educate the patient on what activities are appropriate and can be completed without putting stress on the procedure. In addition, the patient can be given more information regarding the best care for his or her shoulder while at home and moving forward.

PROM to ROM

Following postoperative day one, the physical therapist progresses PROM exercises, while continuing to protect the involved tissues. PROM includes both physiological motion and joint mobilizations. When physiological motion is performed, it is important to glide the humeral head manually to

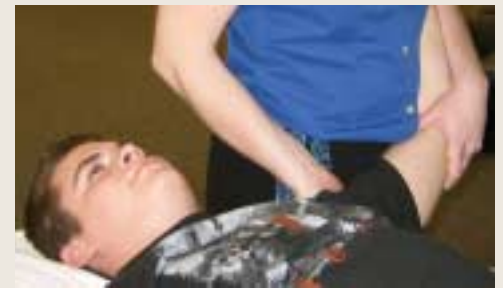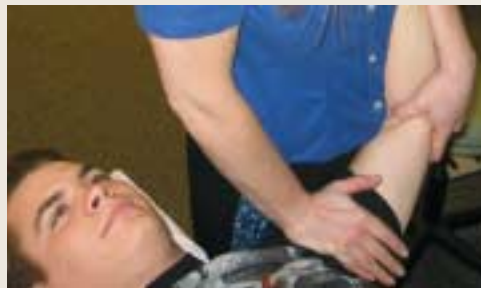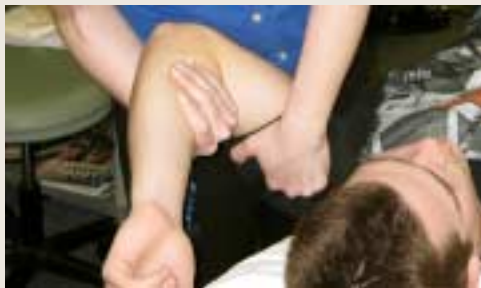structures in the surgical procedure. Due to posture and holding the arm in a protective position postoperatively, the posterior and inferior capsules are the most common to be restricted. Performing joint mobilizations early in the rehabilitation phase (day one) can prevent excessive scarring and restricted ROM following surgery. There are specific techniques to target the posterior (Figure 2) and inferior capsule (Figure 3).

Eye on Biomechanics

Besides the glenohumeral joint, other joints within the shoulder girdle complex may need attention for optimal biomechanics to occur. Physical therapists will assess the mobility of the sternoclavicular joint, acromioclavicular joint, and scapulothoracic joint. The scapula contributes

trapezius is the most common muscle affected by overactivation.¹¹ Scapular mobilizations and scapular control exercises can begin immediately postoperatively without placing stress on the involved tissues. Scapular control exercises, including scapular depression and retraction, do not require glenohumeral movement.¹¹

By beginning physical therapy on postoperative day one, the therapist can begin to address any deficits in the biomechanics of the entire shoulder girdle, as well as educate the patient in the proper exercises to correct the deficits without placing inappropriate stress on the involved tissues. Beginning this process early will help ensure normal mobility of the sternoclavicular, acromioclavicular, and scapulothoracic joints



Left to right: Figure 1, Figure 2, Figure 3 — It has been my clinical experience that patients who are seen by a physical therapist at day one postoperatively have increased range of motion and decreased overall pain during their rehabilitation programs.

maintain the proper biomechanics within the joint. An example is manually gliding the head of the humerus inferiorly when passively taking the arm into elevation (Figure 1). If the therapist does not manually glide the humeral head inferiorly with elevation, the humeral head will glide superiorly and impinge the subacromial tissues. The subacromial tissues affected would include the supraspinatus tendon and subacromial bursa.⁹

Joint mobilizations are performed day one postoperatively, as well. Joint mobilizations continue to be a part of the treatment protocol provided by a physical therapist until full ROM is attained. Grade I and II mobilizations are performed to increase nutrition and lubrication to the joint surfaces, as well as decrease pain through the Gate Control Theory of Pain. Grade I and II mobilizations start at the beginning arthrokinematic ROM and only go to the midpoint of arthrokinematic motion. Grade III and IV mobilizations are performed to increase joint extensibility by breaking adhesions or stretching out the capsule.¹⁰ Grade III and IV mobilizations are not performed early on in the rehabilitation process if the labrum or capsule were involved

approximately 60 degrees of the total 180 degrees of shoulder elevation. The glenohumeral joint contributes the other approximate 120 degrees.⁹ The scapula frequently displays decreased ROM, which is commonly the result of postural deficiencies over time. With a compromised posture, the scapulae often sit protracted and caudally rotated. If motion is limited, and the full 60 degrees of cranial rotation is not available at the scapulothoracic joint, the glenohumeral joint will try to make up for this hypomobility by becoming hypermobile. A caudally rotated scapula will also increase the stress on the subacromial tissues with elevation. Once the scapula has its proper mobility, it can perform its proper contribution to function within the shoulder complex. The scapula's function is to provide a stable base for the humeral head, as well as provide a kinematic link between the upper extremity and the axial system.⁷ Scapular dyskinesia is frequently associated with shoulder injuries, even if the scapula has full ROM passively. It is often caused by inhibition or overactivation of the scapular muscles. Serratus anterior and the lower trapezius are common muscles affected by inhibition. The upper

by the time the glenohumeral joint is allowed full ROM. Normalizing mobility of the entire shoulder girdle will not only decrease stress on the involved structures in the short term, but also decrease the chance of re-injury in the long term. Another reason to start postoperative shoulder patients in physical therapy on day one is to allow for a smooth and appropriate transition from PROM to active-assisted ROM (AAROM) and finally to active and resisted ROM. The physical therapist will provide expert instruction and mentorship to ensure that the patient is completing all activities while maintaining optimal quality of motion and concurrently improving the quantity of motion. Patients frequently demonstrate compensatory patterns and increased subjective pain levels, which increase the stress on the surrounding structures. Physical therapists are very aware of these compensation patterns and can reinforce proper movement patterns until they become habit.

Changing Opinions

Physicians' opinions of postsurgical shoulder rehabilitation programs vary widely. Most

surgeons agree on beginning a few exercises within the first few weeks after surgery. Based on the literature⁴ and on my own clinical experience, beginning formal physical therapy at day one postoperatively has been shown to be beneficial. Superior communication between the surgeon and the therapist and early mobilization are the keys to increased mobility, decreased pain, and an earlier return to function while protecting and allowing the involved structures to heal. The patient is provided with more education and a smoother transition throughout the various stages of his or her shoulder rehabilitation in this scenario. The end result is a patient who displays more function with less subjective pain, who is more educated with less frustration, and who is, in short, happier.

Patients who are happier with their outcome and their rehabilitation make our careers very rewarding. Anecdotally, I think we can all agree on that. The benefits of early postoperative rehabilitation on shoulder patients extend not only to the patients that we serve, but also is a rewarding improvement to our respective professions. ●



Kimberly A. Kollwelter, PT, DPT, MSPT, CIMT, STC, CSCS, is the Director at ATI Physical Therapy in Joliet, IL. She completed her Master's Degree in Physical Therapy from the University of Wisconsin-LaCrosse. She went on to complete her post-professional Doctorate of Physical Therapy Degree from the University of St. Augustine. Kimberly is also certified in sports physical therapy, strength and conditioning, and manual therapy. Kimberly teaches continuing education courses nationally on the shoulder and the knee.

Editor's Note: Kimberly A. Kollwelter is not affiliated with Midwest Orthopaedics at Rush (MOR). Treatment recommendations presented in this article are solely the professional opinion of the author. MOR physicians direct postoperative physical therapy in accordance with each patient's individual medical case specifics.

References

- 1 Stokes DA, Savoie FH, Field LD, Ramsey JR. Arthroscopic repair of anterior glenohumeral instability and rotator interval lesions. *Orthop Clin North Am.* 2003;34:529-538.
- 2 Hewitt M, Getelman MH, Snyder SJ. Arthroscopic management of multidirectional instability: pancapsular plication. *Orthop Clin North Am.* 2003;34:549-557.
- 3 Millstein ES, Snyder SJ. Arthroscopic evaluation and management of rotator cuff tears. *Orthop Clin North Am.* 2003;34:507-520.
- 4 Kim SH, Ha KI, Jung MW, Lim MS, Kim YM, Park JH. Accelerated rehabilitation after arthroscopic Bankart repair for selected cases: a prospective randomized clinical study. *Arthroscopy.* 2003;19(7):722-731.
- 5 Bacilla P, Field LD, Savoie FH. Arthroscopic Bankart repair in a high demand patient population. *Arthroscopy.* 1997;13(1):51-60.
- 6 Abrams JS. Arthroscopic repair of posterior instability and reverse humeral glenohumeral ligament avulsion lesions. *Orthop Clin North Am.* 2003;34:475-483.
- 7 Rubin BD, Kibler WB. Fundamental principles of shoulder rehabilitation: conservative to postoperative management. *Arthroscopy.* 2002;18(9):29-39.
- 8 Kibler WB. Rehabilitation of rotator cuff tendinopathy. *Clin Sports Med.* 2003;22(4):837-847.
- 9 Levangie PK and Norkin CC. *The shoulder complex.* In: Levangie PK, Norkin CC, eds. *Joint Structure and Function: A Comprehensive Analysis.* 3rd ed. Philadelphia, Pa: F.A. Davis Company; 2001:196-225.
- 10 Beissner KL. Mobilization techniques. In: Tomberlin JP, Saunders HD, eds. *Evaluation, Treatment, and Prevention of Musculoskeletal Disorders, Volume 2 Extremities.* Chaska, Minn: The Saunders Group; 1994:323-360.
- 11 Kibler WB, McMullen J, Uhl TL. Shoulder rehabilitation strategies, guidelines, and practice. *Orthop Clin North Am.* 2001;32(3):527-538.

Rush SurgiCenter LP



Multispecialty Outpatient Surgery Center
Located in the Rush University Medical Center campus

Named as one of the
"Who's Who in Ambulatory Surgery"
Featured in the December 2005 edition of
Today's Surgicenter magazine

Licensed by the State of Illinois and accredited by the Joint
Commission of Healthcare Organizations




"Running a practice isn't getting any easier."



Like many doctors, Ellen is facing increased costs, rising insurance rates and more complex government regulations. That's why Harris has specialists with over 20 years experience dealing with the unique issues faced by doctors and their practices. We can help with customized lending to buy into a practice or start your own, streamline the management of your finances and identify financial risks so you are better prepared for the future.

For details, contact
Susan Luperini
at (630) 920-7033
or visit www.theharris.com

Investment Management

Tailored Banking and Lending Solutions

Financial Planning

Trust and Estate Services

Philanthropic Advice

Helping individuals and families accumulate, protect and grow their wealth for more than 100 years.

Harris Private Bank is a trade name used by various financial service providers in the Harris Financial Corp. Banking products and services offered by Harris Private Bank are provided by Harris N.A., The Harris Bank N.A., and its affiliates. Member FDIC. Financial planning and investment advisory services are provided by Sullivan, Bourne, Spens & Baynes, Inc., an SEC-registered investment advisor. Family Office Services are provided by Harris mFCPO, Inc. Investment Advisory Services are provided by Harris mFCPO Investment Advisory Services LLC, an SEC-registered investment advisor, and a wholly-owned subsidiary of Harris mFCPO, Inc. Not all products and services are available in every state and/or location. Figures are used in ad. Quotations and content based on actual experience.



When it comes to comprehensive hip, knee or shoulder replacements, Rush Oak Park Hospital is a recognized leader. Teams of skilled experts offer an individualized approach to joint replacement. From one-on-one consultations with the attending physicians and surgeons to a specially tailored recovery plan, our goal is to help patients rapidly return to their active lifestyles.

Joint Replacement Made Better

In addition, Rush Oak Park offers patients access to the benefits and resources of Rush University Medical Center and Marianjoy Rehabilitation Hospital.

MEDICINE MADE BETTER

For more information about our monthly joint replacement seminars, or to make an appointment, call 708-660-INFO (4636), or visit rohp.org.

RUSH
OAK PARK HOSPITAL

SPONSORED BY THE WHEATON FRANCISCAN SISTERS

Gallagher

Healthcare Insurance Services, Inc.

The leading provider of malpractice insurance to Orthopaedic Surgeons in Illinois

Unmatched client advocacy

Healthcare niche expertise

Strong market relationships

Financial strength & industry leadership

Comprehensive client service

Client focused culture—The Gallagher Way

Specialized products and innovation

Insurance and Risk Management Solutions for the Healthcare Industry

The Gallagher Centre • Suite 1850 • Two Pierce Place • Itasca, IL 60143
630.285.3942 • www.ajg.com/healthcare

Accelerated
rehabilitation centers
Physical Therapy • Sports Medicine

Accelerated Rehabilitation Centers is the premier provider of rehabilitation services. We specialize in rehabilitation for sports injuries, back and neck pain, work injuries and hand therapy.

East Loop 12 S. Michigan Ave., 3rd FL. 312-980-4775	Loop 67 W. Jackson Blvd. 312-386-1100	North Loop 221 N. LaSalle St. 312-855-9206	West Loop 850 W. Jackson Blvd. 312-491-0934		
South Loop 1509 S. Michigan Ave. 312-431-0434	Streeterville 150 E. Huron, #901 312-640-1112	River North 401 W. Ontario, #100 312-943-6700	Old Town 1527 N. Wells 312-642-8114	Lincoln Park 2400 N. Sheffield 773-281-7991	Lakeview 3229 N. Broadway 773-871-4538
Logan Square 2731 N. Milwaukee 773-394-0796	Hyde Park 5230 S. Blackstone 773-256-1475	Chatham 8658 S. Cottage Grove, #400 773-723-1270	Midway 4412 S. Pulaski Rd. 773-847-3123	Beverly 2304 W. 95th St. 773-233-9570	Morton Grove 6759 Dempster St. 847-470-9995
Skokie 9300 Weber Park Pl., Rm. 225 847-779-6100	Evanston 1629 Chicago Ave. 847-475-1630	Kenilworth 554-B Green Bay Rd. 847-256-3500	Northbrook (East) 1535 Lake Cook Rd., #500 847-509-8850	Northbrook (West) 640 Anthony Trail Rd. 847-486-1886	Highland Park 799 Central Ave., #210 847-433-5502
Northwest Side-Chicago 8337 W. Lawrence Ave. 708-583-9500	Mount Prospect 2364 S. Elmhurst Rd. 847-718-9201	Barrington 111 Lions Dr., #212 847-381-0372	Elgin 583 N. McLean Blvd. 847-808-4749	Oak Park 1145 Westgate, #120 708-763-0564	Oak Brook Terrace 17W721 Roosevelt Rd. 630-705-0060
Downers Grove 1625 Ogden Ave. 630-724-0977	Bolingbrook 520 E. Boughton Rd. 630-783-2438	Naperville 1012 W. 95th St. 630-428-1503	Hazel Crest 3330 W. 177th St., 2nd Fl. 708-249-8346	Olympia Fields 2655 W. Lincoln Hwy., #102 708-481-2323	Bourbonnais 215 N. Convent St., #6 815-928-8357
Plainfield 24014 W. Renwick Rd. 815-577-2488	Joliet 2430 Plainfield Rd. 815-439-2121	Mokena 19841 Wolf Rd. 708-479-0320	Dyer, IN 425 US Rte. 30 219-864-0290	Highland, IN 9501-B Indianapolis Blvd. 219-923-4832	Merrillville, IN 3240 E. 84th Pl. 219-791-0494

For more information on Accelerated's 90 rehabilitation centers, contact us at:

1-877-97REHAB or info@acceleratedrehab.com

Minimally Invasive Fracture Surgery

An Overview

By Walter W. Virkus, MD

Minimally invasive surgery is becoming more popular with patients because of smaller incisions and possibly shorter recovery times. While many orthopaedic fracture surgeries have been performed with minimally invasive techniques for years, the possibilities are expanding to additional types of fractures. In addition to smaller incisions and shorter recovery periods, minimally invasive fracture surgery actually may allow the fracture to heal faster than with more invasive surgical options.

Fracture Healing

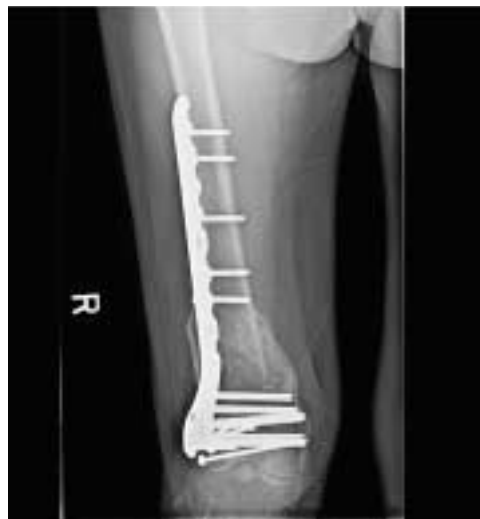Fractures heal by one of two methods, called primary and secondary fracture healing. The method of healing is determined by how closely and tightly the fracture is held together. When the bone ends are only loosely held together, as in cast treatment, the bones heal by secondary, or indirect, fracture healing. In this form of healing, a blood clot or hematoma forms around the fracture. Factors released by the injured bone lead to the formation of fibrocartilage callus in this hematoma. The fibrocartilage is then converted to woven or immature bone, which is slowly remodeled into mature haversian bone over many months.

This process results in a ball of new bone surrounding and joining the fractured ends of the bone. This type of healing also occurs in operative fracture care when partial stability is obtained. If there is excessive motion between the fracture fragments, the fibrocartilage will not be converted to bone and nonunion will result.

Primary, or direct, bone healing occurs when the fractured ends are perfectly aligned and held tightly in place, called rigid stability. It can only

occur with surgery. In primary healing, osteoclasts (bone resorbing cells) bore tunnels through the bone and across the fracture site. In these tunnels new mature bone is grown. The bone strength is restored by direct knitting of one bone to the other. If the bones are not held tightly, or if they are held tightly but are not perfectly aligned end-to-end, nonunion can result. Both types of healing require the fractured bone to have a good blood supply, which it receives from the surrounding muscle. If too much muscle is torn off the bone during the open reduction and plating, nonunion can occur.

In operative fracture care, the type of stability and resultant desired healing depends on the type of fracture and its location. Rigid stability and primary fracture healing can only be obtained with an open reduction and internal fixation, usually with plates and screws. Only rarely is it possible with minimally invasive techniques. Relative stability and secondary fracture healing are achieved



Healed distal femur fracture

able with a wide variety of surgical techniques, many of them minimally invasive. In fact, one reason minimally invasive fracture surgery is beneficial to patients is that the nutrient-rich hematoma that forms at the time of the fracture is not washed away, as it is in open fracture surgery, which likely speeds the time to callus formation and, eventually, to healing.

Minimally Invasive Techniques

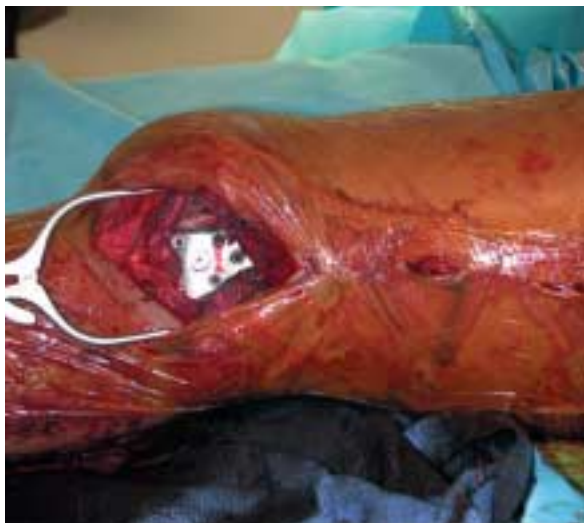Minimally invasive fracture surgery can be divided into two types. The first is intramedullary nailing or rodding. This type of surgery has been utilized for 40 years. This technique is mostly used in fractures of the tibia, femur, and humerus when the fracture is in the middle of the bone. A hole is made at one end of the bone and a reamer is used to clean out the bone marrow in the middle of the bone. Then the rod or nail is inserted down the middle of the bone. Locking screws are placed through the nail at each end to prevent the bone from collapsing or twisting.

A more recent minimally invasive technique for fractures involves using plates and screws inserted through small incisions. The terms percutaneous plating or submuscular plating are sometimes used to describe this technique. In percutaneous plating, the fractured bone is straightened by any of a variety of techniques, using x-ray to determine when the bone is aligned closely. The fracture does not need to be realigned perfectly in this technique. Then a small incision is made on one side of the fracture. A tunnel is created between the bone and the overlying muscle or skin. The plate is bent to match the surface of the normal, nonbroken bone. The plate is placed into the tunnel and across the fracture. Then screws are placed through the plate into the bone on both sides of the fracture through very small skin incisions, using x-ray guidance.

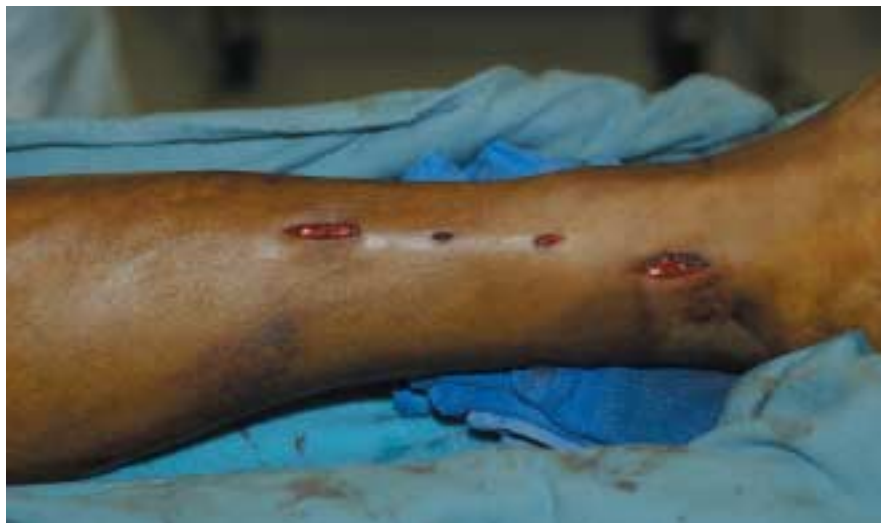Although the fracture is not held as tightly as when the fracture is aligned through a large incision and direct vision, the hematoma that forms the callus is not washed away, which allows the healing to occur more rapidly. In addition, since less muscle is pulled off the bone with this technique, the bone receives a larger blood supply, which also assists in healing.

Only Sometimes the Answer

So why not perform minimally invasive fracture surgery all the time? Well, it is not possible in all



Minimal incision through which the larger plate is inserted across the fracture



fractures. Most fractures that extend into a joint and split the cartilage need to be realigned perfectly to minimize the risk of posttraumatic arthritis. In most cases, perfect alignment can only be obtained by looking at the fragments and the joint surface directly through an open incision. In addition, some areas, like the forearm, have a lot of arteries and nerves very close to the fracture area. In these circumstances, the risk of minimally invasive surgery is too high because these important structures cannot be seen on x-ray, and therefore cannot be protected.

Lastly, minimally invasive fracture surgery is much more difficult and takes longer than traditional

open surgery. It takes a lot of experience to be able to get the fracture aligned when you can see only the ends of the bones on x-ray instead of looking at them directly. Placing the plate and putting in the screws using x-ray guidance is also very difficult and takes some practice.

Despite the longer surgical times, there are many benefits to minimally invasive fracture surgery. Although the smaller incisions are nice, they are probably the smallest benefit from the medical point of view. The real benefits are the minimal muscle injury and the preservation of the fracture hematoma and blood supply to the bone.

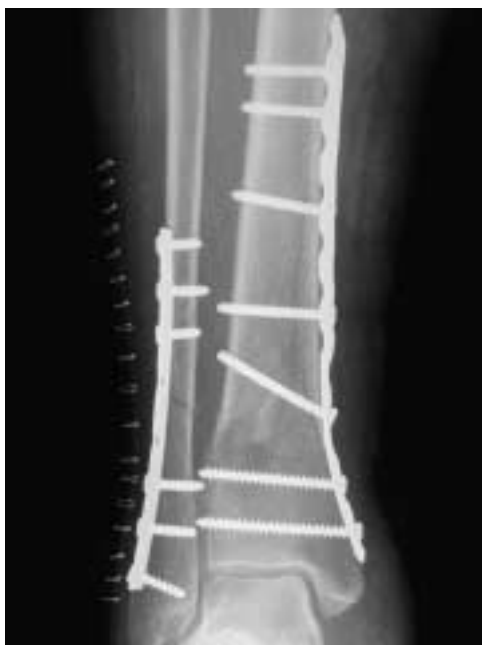As mentioned, preserving the hematoma and blood supply seems to increase the speed of bone healing, sometimes dramatically, which is certainly a benefit to any patient. Additionally, smaller incisions usually mean much less damage to the muscles around the fracture. Less damage allows for faster rehabilitation and helps minimize joint stiffness, allowing the patient to return more quickly to the activities of daily life.

Pluses and Minuses

There are many benefits to minimally invasive fracture surgery. While not possible in all fracture cases, newer techniques and implants are available to increase the number of fractures that can be treated with these methods. Minimally invasive surgery is more difficult and takes longer than traditional surgery, and the surgeon's experience can play a large role in a successful outcome. ●



Walter Virkus, MD, is an orthopaedic surgeon with a unique combination of training in both orthopaedic trauma and orthopaedic oncology. After receiving his doctorate from the University of Medicine and Dentistry of New Jersey and completing his internship at Mount Sinai Medical Center in New York City, New York, Dr. Virkus went on to complete his orthopaedic residency at the University of Maryland. He received his training in orthopaedic trauma through fellowships at the Shock Trauma Center in Baltimore, Maryland, and the Hospital for Special Surgery in New York City, New York. He completed a fellowship in orthopaedic oncology at the University of Florida in Gainesville. Dr. Virkus is currently an Assistant Professor of Orthopaedic Surgery at Rush Medical College, Assistant Attending Physician of Orthopaedic Surgery at Rush University Medical Center, and a member of the medical team for the Rush Center for Limb Preservation. The majority of his practice, which focuses on orthopaedic trauma and oncology, is at Rush University Medical Center. Dr. Virkus is also the Senior Attending Orthopaedic Surgeon on the staff of Cook County Hospital in Chicago, Illinois, one of the busiest Level 1 trauma centers in the nation, where he also treats cancer patients. Dr. Virkus has special interests in extremity and pelvic fractures as well as reconstruction, nonunions, complex limb reconstruction, minimally invasive fracture surgery, and bone-transplant surgery. His research interests include fracture fixation, bone-graft substitutes, and limb-reconstruction methods. Dr. Virkus has authored numerous articles and chapters on both trauma and oncology. He is on the faculty of AO North America and is a Fellow of the American Academy of Orthopaedic Surgeons.



Postoperative distal tibia fracture

At the Cutting Edge

The New Field of Cartilage Transplantation Brings Fresh Options for Repairing Damaged Shoulders

By Brian J. Cole, MD, MBA, and
Andreas H. Gomoll, MD

Damage to the articular cartilage (the cartilage that covers the surface of the bone) is a relatively rare cause of shoulder pain compared with other causes, such as impingement or tears of the rotator cuff. While there are excellent therapeutic options for impingement and tears, however, treatment for cartilage injuries, especially in young and active patients, has become available only recently.

Types of Shoulder Damage

Cartilage damage in the shoulder is divided into several categories — acute versus chronic and localized versus diffuse. The best-known and most common type of cartilage damage is the chronic, diffuse type that results from osteoarthritis, also known as degenerative arthritis. Treatment for osteoarthritis in the shoulder, similar to that in other joints, includes anti-inflammatory medications, physical therapy, injections, and ultimately a joint replacement. In shoulder replacements, the damaged cartilage is removed and replaced with a metal-and-plastic prosthesis, similar to hip and knee replacements. Although shoulder replacement provides good pain relief, functional gains are less predictable; in addition, like all mechanical parts, artificial shoulders wear out over time and might require subsequent surgery. For these reasons, surgeons have traditionally attempted to avoid joint replacements in younger patients.

In addition, cartilage damage in younger patients is often not caused by arthritis, but is a result of traumatic injuries, such as a shoulder dislocation during which cartilage is chipped, or less frequently because of problems with the blood supply, where a piece of bone with the attached cartilage dies off and becomes detached. This type of damage is often localized and more acute in nature. It often presents as a deep pain that worsens with

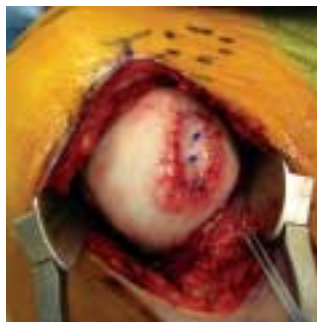

Figure 1: Smaller cartilage defect treated with autologous chondrocyte implantation

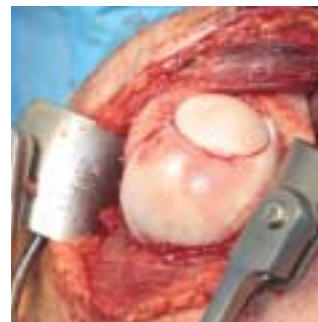
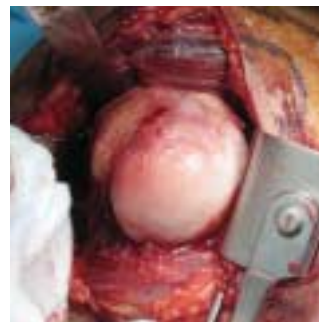
Figure 2: (left) Photograph of a large defect of the humeral head; (right) photograph of a fresh osteochondral allograft used to replace the damaged cartilage

increased activities. Sometimes patients experience popping or clicking, and report limited motion or weakness. To diagnose these injuries, surgeons often initially obtain x-rays, possibly followed by magnetic resonance imaging (MRI) or a computed tomography (CT) scan. Guided by the patient's symptoms and physical and radiographic findings, the physician will often attempt conservative treatment at first.

Treating Conservatively

Conservative treatment with physical therapy, anti-inflammatory medications, and steroid injections largely provides symptomatic relief, without true healing of the damaged cartilage. The patient's symptoms will often decrease dramatically even with conservative measures, however, and surgery is avoidable. If all conservative measures are exhausted and the symptoms continue to exist, surgical intervention is considered. Traditional surgical options include arthroscopy for joint debridement, essentially a cleaning of the joint while viewing through a small camera to remove scar tissue and loose pieces of cartilage. This procedure can improve symptoms dramatically, but often provides only temporary relief, since it still does not correct the underlying cartilage damage.

Enter Cartilage Transplants

Because certain lifelong restrictions, such as limited carrying or lifting, have to be accepted by the patient with a shoulder replacement, and because

other replacements may become necessary over time, surgeons and patients alike have been looking for alternatives to joint replacement and for something more effective than simply cleaning the joint out arthroscopically. The new field of cartilage restoration promises to provide a biological answer to this problem and avoid the implantation of a metal and plastic prosthesis. Originally developed and applied for the treatment of cartilage damage in the knee joint, cartilage transplantation now is applied increasingly to other joints, such as the shoulder, hip, and ankle. Within the field of cartilage transplantation, three distinct technologies aim to restore articular cartilage — autologous chondrocyte, osteochondral autograft, and osteochondral allograft transplantation.

Autologous Chondrocyte Transplantation (ACI)

This technique involves the arthroscopic harvesting of a small piece of cartilage from the patient's knee, which is then used to grow new cartilage in the lab. Once the cartilage cells have multiplied sufficiently over the course of several weeks, the patient returns for implantation of the cells. This second procedure involves open surgery, as opposed to the arthroscopic method used for the cell harvest. The physician excises the damaged cartilage, covering the resultant hole with a flap of periosteum. This periosteum, a thin tissue similar to a skin that covers all bones, is harvested from the patient's shinbone through a small inci-

sion during the same procedure. Once the flap is in place with multiple small stitches to the surrounding cartilage, the now-covered hole is filled with the cartilage cells that were grown in the lab. The cells then start to produce cartilage tissue that closely resembles the original articular cartilage (Figure 1).

Osteochondral Autograft Transplantation

In this procedure, healthy cartilage from the patient's knee takes the place of the damaged cartilage in the shoulder. The surgeon removes a round area of damaged cartilage, together with a cylinder of underlying bone, with a punch-like device. The surgeon then obtains a piece of cartilage and bone of similar dimensions from an area of the knee joint where there is extra cartilage. The physician makes use of the cylinder of healthy bone and cartilage to fill-in the defect in the shoulder. The hole in the knee fills in with scar tissue over time.

Osteochondral Allograft Transplantation

Similar to the above-described autograft transplantation, allograft transplantation utilizes cylinders of healthy bone and cartilage to replace damaged cartilage. The difference lies in the source of the tissue. While the term 'autograft' implies that the patient's own tissue is used, 'allograft' means tissue from somebody else. Similarly to heart and kidney transplants, bone and cartilage is obtained from tissue donors. Unlike these organ transplants, however, cartilage and bone transplants do not require immune suppression, and there is no organ rejection. Prior to transplantation, the tissue undergoes extensive testing for diseases and infections, but a minimal risk remains. The main advantage of allograft over autograft transplantation is the ability to treat large areas of cartilage and bone damage (Figure 2) and the avoidance of surgery on the patient's own knee, which decreases pain and speeds up recovery after the operation.

The physicians at Midwest Orthopaedics at Rush routinely perform all three types of transplants as guided by patient symptoms, radiographic findings, and patient preference.

Future Directions

Research is ongoing on several fronts to improve cartilage transplantation. New technologies are emerging that will allow surgeons to perform

autologous chondrocyte transplantation arthroscopically through keyhole surgery, rather than through an open incision. While this technology is already in use in Europe, it has not received U.S. Food and Drug Administration (FDA) approval yet for use in the United States. Other research is underway to make allograft transplantation safer using even better tests to rule out disease transmission. Additional research involves allowing for a better supply of donated grafts by improving the time that these grafts can

safely remain in storage prior to implantation (now, grafts have to go from the donor to the patient within a few days).

We are actively involved in improving patient outcomes by performing basic science research in the area of cartilage transplantation, as well as outcomes research, through which we are continually evaluating and improving our surgical technique in this evolving field at the cutting edge of orthopaedic surgery. ●



Brian J. Cole, MD, MBA, is an Associate Professor in the Department of Orthopaedics as well as the Department of Anatomy and Cell Biology at Rush University Medical Center in Chicago, Illinois. He received his medical degree and MBA from the University of Chicago in 1990. He completed his residency at the Hospital for Special Surgery in New York in 1996 and his sports medicine fellowship at the University of Pittsburgh in 1997. Dr. Cole is the Section Head of the Rush Cartilage Restoration Center as well as the Head Team Physician for the Chicago Bulls, a Co-Team Physician for the Chicago White Sox, and an orthopaedic

surgeon for the Chicago Rush Arena Football team.



Andreas H. Gomoll, MD, joined the Midwest Orthopaedics at Rush Sports Medicine Fellowship program after completing the Harvard Combined Orthopaedic Residency Program at Massachusetts General Hospital in Boston. A native of Germany, Dr. Gomoll graduated from Ludwig-Maximilians-Universitaet Medical School in Munich and attended Oxford University on a visiting student scholarship. He specializes in sports medicine, and his research interests include rotator cuff disorders and bone and cartilage transplantation.



Serving Healthcare Practices Throughout Northern Illinois

Our **Healthcare Services Group** is dedicated to providing healthcare practices with responsive service and expert advice in the following areas:

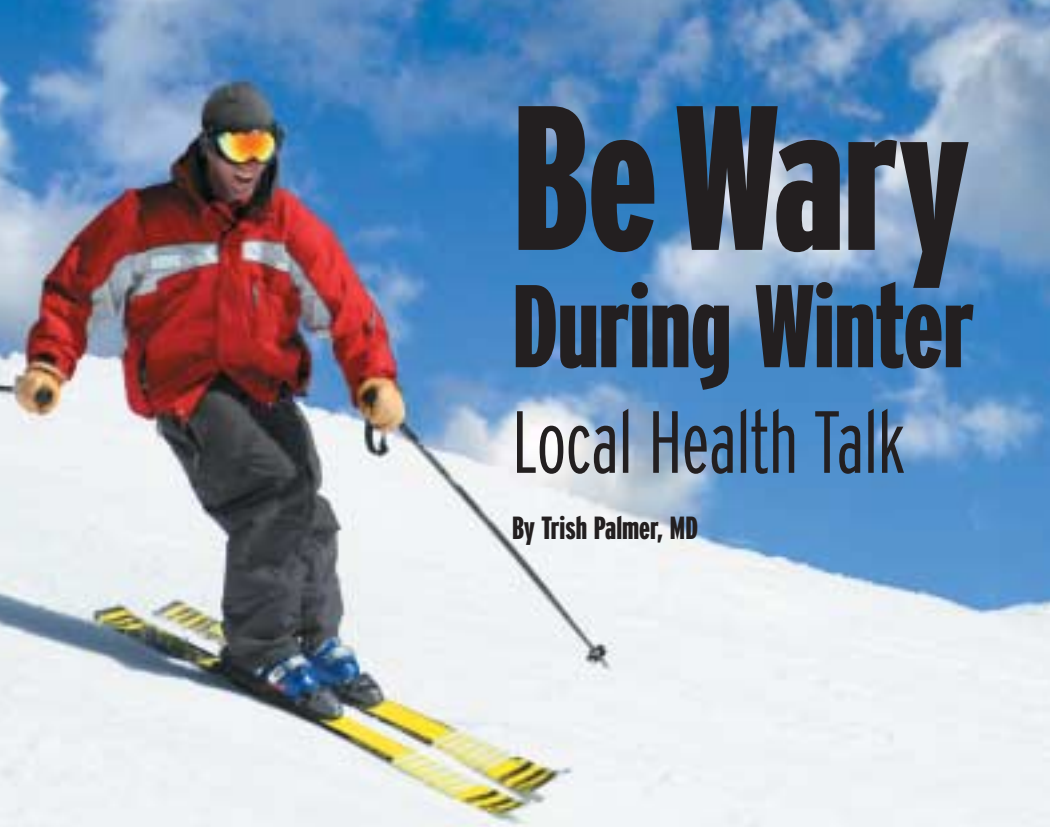- ▲ Audit and Accounting Services
- ▲ Tax Services
- ▲ Operations, Financial and Technology Consulting
- ▲ Investment Banking
- ▲ Business Valuations
- ▲ Investment Management Services
- ▲ Benefits, Retirement, Human Resources and Risk Management Services

To learn more about our services, contact Steve Lutz at 630-545-4550 or email steve.lutz@wolfco-fs.com.



Wolf Financial Group
Better Ways ▲ Better Results

2100 CLEARWATER DRIVE, OAK BROOK, IL 60523 630-545-4500 WWW.WOLFFINANCIALGROUP.COM



Be Wary During Winter Local Health Talk

By Trish Palmer, MD

Are you thinking about preventing winter sports and cold-related injuries? Most cold-related injuries can be prevented with a little planning, some preparation, and the proper equipment.

Beware the Snow Shovel

One of the most common winter-related injuries results from shoveling snow. It is vigorous exercise and a big strain on the back that people don't appreciate. The weight and position are really bad for two parts of your back. A disc could be compressed, resulting in a pinched nerve. Also, the muscles in the lower back are small and easily strained.

Prevent problems with good positioning and exercise.

When you lift 10 pounds close to your body, it exerts 10 pounds of pressure on the back. If you lift that same 10 pounds away from your body, as people often do when shoveling, it is seven times heavier, exerting 70 pounds of pressure on the back.

The best advice is don't do it. Our bodies are not built to shovel snow. Get a snowblower or pay the neighbor kid to do it for you.

If you insist on shoveling yourself, start exercising for some time before you attempt it. You need to get in shape and build up those back muscles.

Winter Sports Prep

That advice holds true for winter sports as well. Exercising in cold weather places extra demands

on the body. If you haven't exercised regularly in months, you are more likely to suffer an injury on the ski slopes or at the ice rink. Pay special attention to muscles particular to your chosen sport.

For downhill skiing, concentrate on strengthening the muscles of the upper leg, the quadriceps, and hamstrings. You want both sets of muscles to be strong or you could expose yourself to injury, like an ACL tear.

A great exercise is the wall sit. Sit against a wall as if you are in a chair. Make sure your upper legs are horizontal and your heels are directly beneath your knees. Try three sets of 30 seconds each. Try to hold the position for a few minutes at a time.

If you're hoping to be the next Nancy Kerrigan or at least stay on your feet while ice skating, work on strength and balance. Proprioception drills are simple exercises to strengthen your ankles and work on balance. Simply stand on one foot with your eyes closed and work up to being able to do this for 1-2 minutes at a time.

In addition to strengthening the quads and hamstrings, condition the calves and the muscles in the front of the leg. Calf raises are the most basic exercises for lower body strength. Be careful of squats and lunges which put a lot of pressure on the front of the knee.

To strengthen ankles, use resistance bands wrapped around the leg of a table and your foot.

Flex feet toward your body. Repeat the exercise, moving your foot in a clockwise fashion, and then move the foot counterclockwise.

Snowboarding is gaining popularity and as a result, doctors are seeing more wrist and arm injuries, especially for beginners. On the upside, people with knee problems may want to transfer to snowboarding because it may be easier on the knees than skiing.

Warm Up

Once the skating pond freezes and the snow falls, the most important part of protecting yourself during winter activities is being prepared. Warm up before you go outdoors for activities to loosen muscles and expand your lungs to handle the cold air.

Exercise and cold-induced asthma can be worse in the winter, so cover your mouth with a scarf to warm the air coming into your lungs. Dress warmly in layered clothing, hats, warm socks, and mittens.

Watch Out

Always be aware of frostbite and hypothermia. On a day with a wind-chill, you can get frostbite much more quickly than you may think. Signs of frostbite include skin changing in color to pink and then white. In addition the body part will feel cold to the touch and become numb. The area tends to feel intensely painful on rewarming. Participate in outdoor activities with a partner and check each other for signs of hypothermia, which include shivering, drowsiness, and lack of coordination.

Hydrate!

Don't forget to drink plenty of water before, during, and after your outdoor fun. Dehydration can also occur in the winter months with strenuous activities. Don't drink alcohol, which can restrict blood vessels and increase your risk for hypothermia. Protect your skin from the sun and wind using a sunscreen or sun block. The sun reflects off the snow and can quickly cause a sunburn, even though you might feel cold.

Head Gear, Etc.

The importance of protective equipment and a proper fit cannot be stressed enough. Ensure that your skis, skates, shoes, and other equipment fit you correctly. Helmets are a must for skiing,

4 Rules of Winter Injury Prevention

Rule #1: Quit while you're ahead

If you feel yourself getting tired, then stop the activity. Fatigue can cause a loss of concentration, and one sloppy movement could result in a major setback.

Rule #2: Stay energized

Remember that your body needs fuel to make all those smooth moves. Pack plenty of water and have a snack during breaks.

Rule #3: Exercise often

Strong and flexible leg muscles allow freedom of movement and reduce the likelihood of injury. Maintaining a light exercise routine will improve athletic performance and overall health.

Rule #4: Know your limits

Buying an expensive ski vacation package does not make you an athlete. Unless you are an experienced skier, shrug off the pressure to outperform your peers.

sledding, and snowboarding. You wouldn't allow your children to bicycle without a helmet, why would you allow them to do other high-velocity sports without protection?

And finally, enjoy yourself but remember to stop before you get fatigued. Most winter-related injuries happen in the afternoon as participants tire out. ●



Trish Palmer, MD, is a sports medicine specialist at Midwest Orthopaedics at Rush, Chicago, Illinois. Dr. Palmer is a team physician for the United States Ski and Snowboard Association, working with alpine and freestyle ski team members. She is also a team physician for U.S. Speedskating. Her patients include members of the current alpine skiing, mogul skiing, aerial skiing, speedskating, bobsled, and skeleton teams. Dr. Palmer was Deputy Venue Medical Officer for Deer Valley for the 2002 Winter Olympics in Salt Lake City.

Reprinted with permission from the Joliet Herald.



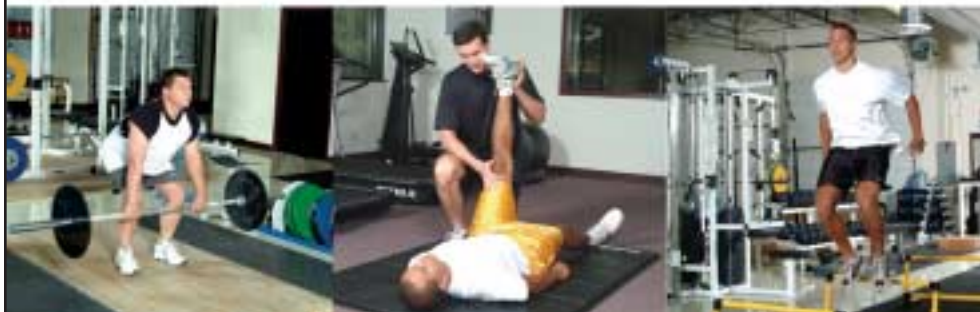At WCS, we take a hands-on exercise-based approach to address your unique deficits and goals. Utilizing the latest research regarding exercise science and rehabilitation, our highly-trained staff will assist you in realizing your goals.

Occupational Rehabilitation
Return to Work Program (Work Conditioning)
Functional Capacity Evaluations
Physical Therapy

Sports Medicine
Sports Performance

708-671-0771
www.wcsrehab.com

ILLINOIS FACILITIES: Buffalo Grove • Hillside • Joliet • Naperville • Orland Park • Palos Heights • South Holland
INDIANA FACILITY: Highland



Physiotherapy Associates



- Physical Therapy
- Occupational Therapy
- Athletic Training
- Industrial Rehab
- Manual Therapy
- FCEs
- Work Conditioning
- Hand Therapy

New Golf Performance Enhancement Program to "Strengthen Your Game" now available locally. Phone 708.358.1612 or visit www.strengthenyourgame.com for more information about this professional evaluation and performance training program for the recreational golfer.

The professionals trust us with their healthcare, and you should too. Conveniently-located throughout the Chicagoland area, we offer adult and pediatric rehabilitation. Call 312.944.7595 to find a facility close to you or visit www.myphysio.com.



Preferred Healthcare Provider of the PGA Tour & Champions Tour



Before you commit to a new CR system be sure to check it out from every angle.

There's a lot of sullyery out there, but only one true powerhouse. Only Fuji has purged out continuous improvements that have led to eight generations of readers and nine generations of imaging plates. The strength of our technological innovations makes our image quality superior and our readers easier to use with streamlined workflow. For instance, we're the only ones to deliver dual-side reading to give you more diagnostic information and less noise. In fact, all Fuji systems have a higher DOE and signal to noise ratio than any other CR system. And only Fuji offers flexible, durable IPs for long-lasting, reliable performance. So step up to Fuji for the best image quality, productivity, support and fitness for every radiographic study. FOR...there really is a difference. Call 1-800-431-2861 today.

 **FUJIFILM**

©Copyright 2006 FUJIFILM Medical Systems (USA), Inc.

www.fujifilm.com

William Blair & Company®

The Salvino Investment Team

Customized Portfolio Management
for Individual Investors

Serving doctors and their unique investment
and retirement planning needs

Phone: 312.364.5360

William Blair & Company

Investment Banking • Asset Management • Equity Research • Institutional & Private Brokerage • Private Capital

William Blair & Company, L.L.C. 322 West Adams Street Chicago, Illinois 60606 800.621.8687 www.williamblair.com

CHICAGO HARTFORD LONDON SAN FRANCISCO TOKYO VALEZ ZURICH

Working Partners with
Midwest Orthopaedics at RUSH

PROMOTIONAL PRODUCTS

More than 17 Years Experience

- ☆ Awards
- ☆ Sales Promotions
- ☆ Apparel

SPECIAL

500 BIC CLIC PENS
WITH YOUR LOGO
\$210 (.42 EACH)

Plus \$12 freight charge
IL Residents add sales tax

708-396-0420

prestomark@aol.com

Visit us on the web

www.prestomarketing.com



Get ACG!

If you want to get it right, then Get ACG!


GetACG.com is your key to Chicagoland's
premiere communications contractor.

Visit our site today, to learn how
your company can benefit from our
experience. Our professional staff
delivers satisfaction.

ACG Connects You to Your Customers!

www.GetACG.com
630-529-1020

MY TEAM!



2006 HOME SCHEDULE

DAY	DATE	OPPONENT	TIME
FRIDAY	FEBRUARY 3	NEW YORK	7:30 P.M.
SUNDAY	FEBRUARY 12	NASHVILLE	2:00 P.M.
SUNDAY	FEBRUARY 26	SAN JOSE	12:00 P.M.
SUNDAY	MARCH 5	DALLAS	11:00 A.M.
FRIDAY	MARCH 10	COLORADO	7:30 P.M.
SUNDAY	MARCH 26	GRAND RAPIDS	2:00 P.M.
SUNDAY	APRIL 23	LAS VEGAS	3:00 P.M.
SATURDAY	MAY 6	UTAH	7:00 P.M.

GET YOUR TICKETS NOW!

CHICAGO RUSH ARENA FOOTBALL
877.RUSH.TIX > CHICAGORUSH.COM > FEEL THE RUSH



**Chicago's Choice for
Physical Therapy**

Services Include:

- ▶ Physical Therapy
- ▶ Occupational/Hand Therapy
- ▶ Sports Performance
- ▶ Athletic Training
- ▶ Women's Health
- ▶ WorkStrategies™ Program –
Work Injury Prevention & Management
- ▶ Aquatic Therapy

Many of us will need physical therapy at some
point in our lives. Whether you are injured
at work, home or in athletic competition,
NovaCare Rehabilitation is your
partner on the road to recovery.



Alsip – South Suburbs
(708) 388-5900

Chicago – Andersonville
(773) 784-9406

Chicago – Bridgeport
(773) 376-1214

Chicago – Greektown
(312) 733-3311

Chicago – Hyde Park
(773) 667-8800

Chicago – Logan Square
(773) 252-4921

Chicago – Loop
(312) 782-2727

Chicago – O'Hare
(773) 693-2121

Chicago – Midway
(773) 788-9347

DePaul University
Ray Meyer Fitness Center
(773) 525-4966

Lake in the Hills
(847) 854-9754

Lake Zurich
(847) 438-1170

Lincolnwood
(847) 568-1244

McHenry
(815) 344-1919

Mt. Prospect
(847) 398-1775

Oak Park
(708) 934-7062



www.novacare.com/chicagoland.htm



Chicago
Office
Technology
Group

Column Office Equipment, Inc.
Distinctive Business Products, Inc.

Our mission is to build strong,
long-lasting business relationships
through innovative document
imaging technology and supported
by an extraordinary dedication
to customer service.

Call Ryan Mossbarger
(630) 771-8503



ESTABLISHED 1940

3101 W 95th St.
Second Floor
Evergreen Park, IL
1-888-ICS-COLL
www.ics-collection.com

ICS is committed to
unparalleled client satisfaction.

Our clients have access to our
industry-leading website,
which allows them to list
accounts, monitor their
accounts, report payments,
request holds/cancels, run
custom reports, and more, all
in real time.



Each of our experienced
employees is charged with
successfully resolving patient
balances without sacrificing
the positive image of
our clients.

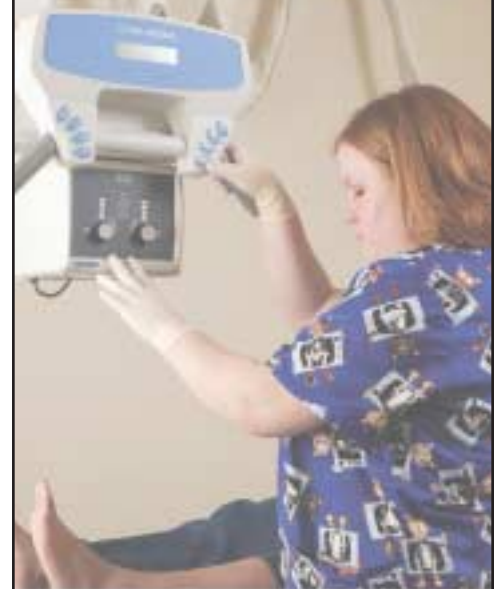

Call us today
for more information.



Proud to be PPMS Certified by the
American Collectors Association, Inc.

everything imaging



SourceOne Healthcare Technologies,
the nation's largest supplier of radiography
equipment and supplies, is a proud partner of
Midwest Orthopedics at RUSH



SourceOne Healthcare Technologies
8000 Van Hook - Morris (IL 62450)
800.433.7377 www.sourceonehealthcare.com

Digital Power
Without Revolutionary Pain

For practices that desire the
very best document workflow
technology with NO upfront
software expense.

- ✓ Digital Dictation
- ✓ Voice Recognition
- ✓ Transcription Platform
- ✓ Document Management Console
- ✓ Digital Signature
- ✓ Communicate Fax/Email
- ✓ Online Repository/EMR
- ✓ Advanced Reporting/Tracking
- ✓ HL7 Integrations
- ✓ Secure
- ✓ HIPAA Compliant
- ✓ No Special Software/Hardware

Ask about a no-obligation trial
1-866-Scribe-2



<http://www.scribe.com>

Has Your Practice Marketing Program Flatlined?

While focusing on providing the best possible care for
your patients, you may have overlooked a critical factor:
the continuous strategic marketing of your practice.

It may be time to call in a specialist...

OMD Healthcare Marketing



Strategic Planning • Target Marketing • Web Site Development
Toll Free: 888-874-6600 • www.omniemarketing.com

www.4ppts.com

MEASURING SUCCESS
ONE PATIENT AT A TIME



Performance Physical Therapy

PPTS emphasizes, superior quality of care, cost containment, treatment outcomes, and convenient locations.



**The Official Rehabilitation
Provider of the Chicago Fire**

SPECIALIZING IN:

- Orthopedic Therapy • Manual Therapy • Sports Rehabilitation
- Athletic Training Outreach Programs • Work Conditioning • Ergonomics
- Work Capacity Evaluations • Sports Performance Training

LOCATIONS

- ◆ Bridgeview
- ◆ Bourbonnais
- ◆ Frankfort
- ◆ South Holland
- ◆ Hobart, IN
- ◆ Merrillville, IN
- ◆ Munster, IN
- ◆ Portage, IN

To schedule your appointment call :
(800) 881 - 3313

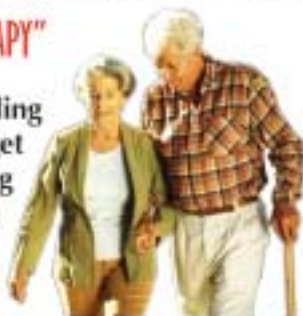GIRLING HEALTH CARE, INC.

HELPS YOU WITH YOUR HOME REHABILITATION NEEDS

LEADING THE CHICAGO AREA IN HOME
REHABILITATION AFTER JOINT REPLACEMENT

INTRODUCING "INTENSIVE THERAPY"

- A Program exclusive to Girling Health Care designed to get you walking and functioning independently faster than traditional home care practices.
- Pre-Operative Physical Therapy visits designed to educate and prepare you and your family for the ultimate rehab experience...



ALL PROVIDED IN YOUR HOME!

Call for information (708) 442-6420

7222 W. Cermak Rd. #210 | North Riverside, IL | 60546
WWW.GIRLING.COM

ATHLETICO

REHABILITATION FITNESS PERFORMANCE

- Sports Medicine • Physical & Occupational Therapy • Personal Training
- Orthopedic Rehabilitation • Work Rehabilitation • Fitness Programs
- Performing Arts Rehabilitation • Massage Therapy • Endurance Program
- Performance Enhancement • Golf Fitness Program • Athletic Training

30 CONVENIENT CHICAGOLAND

locations

CHICAGO

- Bucktown, 1644 N. Milwaukee Ave., 60647 773.252.2300
- Garfield Ridge/Midway, 6255 S. Archer Ave., 60638 773.284.6735
- Gold Coast/Near North, 1031 N. Clark St., 60610 312.951.9790
- Lincoln Park/Lakeview, 1323 W. Diversey Pkwy., 60614 773.549.2520
- Loop, 20 N. Michigan Ave., Ste.103, 60602 312.236.0660
- North Center, 2035 W. Irving Park Rd., 60618 773.528.7502
- Miles/Northwest Chicago, 6000 W. Touhy Ave., Ste.202, 60648 773.774.4291
- River North, East Bank Club, 500 N. Kingsbury, 60610 312.527.5801, ext. 278
- South Loop, 1815 S. Archer Ave., 60616 312.674.9132
- West Loop, 1301 W. Madison St., Ste.104, 60607 312.421.7274

SUBURBS

- Arlington Heights, 88 South Arlington Hts. Rd., 60005 847.506.1767
- Aurora/Naperville, 1137 N. Erie Rd., Ste. 106, 60502 630.236.6698
- Bannockburn, The Bannockburn Club, 2211 Waukegan Rd., 60015 847.267.8800
- Evanston, 909 Davis Street, Ste. 220, 60201 847.733.7906
- Glenview, Carillon Square, 1500 Waukegan Rd., Ste. 250, 60025 847.657.9445
- Grayslake, Country Fair Plaza, 1860 E. Belvidere Rd., 60030 847.548.0360
- LaGrange Park, 407 N. LaGrange Rd., 60526 708.482.9320
- Lake in the Hills, 280 N. Randall Rd., 60156 847.854.8219
- Lemont, 15400 127th St., Ste. C, 60438 630.257.9787
- Lisle, Bulls/Sax Training Academy, 6200 River Bend Dr., 60532 630.324.8243
- Maitland, 4801 Southwick Dr., 5th Floor, 60443 708.263.9785
- Miles/Northwest Chicago, 6000 W. Touhy Ave., Ste. 202, 60648 773.774.4291
- Oak Brook, The Oaks of Oak Brook, 1600 W. 16th St., Ste. T14, 60523 630.572.9700
- Oak Park, Oak Park Athletic Club, 1145 N. Harlem Ave., 60302 708.386.2088
- Palatine, Forest Grove Athletic Club, 1770 N. Hicks Rd., 60174 847.776.0106
- River Grove, 8937 Grand Ave., 60171 708.453.1354
- Schaumburg, 50 West Schaumburg Rd., 60194 847.498.7100
- St. Charles, Sportsplex, 1400 Foundry St., 2nd Floor, 60174 630.752.1200
- Tinley Park, 17837 S. 80th Ave., 60477 708.342.2580
- Wheeling, 481 East Dundee Rd., 60090 847.465.0355
- Willowbrook, Willowbrook Athletic Club, 207 West 63rd St., 60527 630.230.0900



COMPLIMENTARY

Orthopedic or Sports
Injury Evaluation

Sprained, Strained, Twisted?

Our skilled professionals can help.

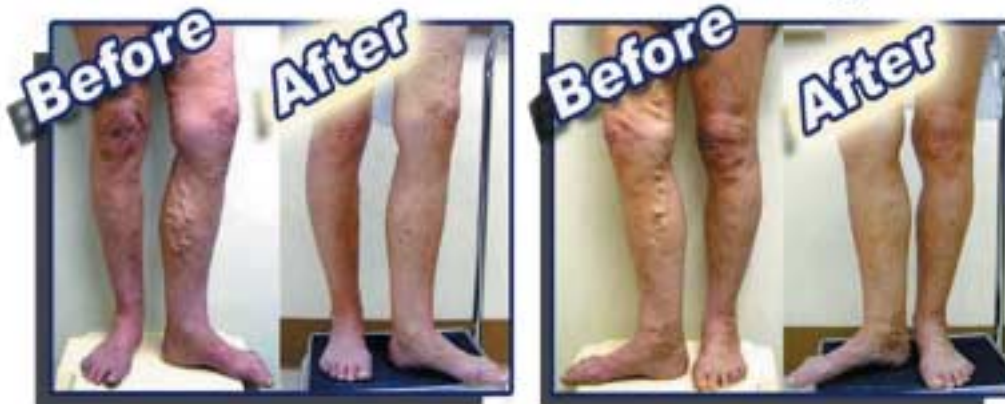1-877-ATHLETICO

www.athletico.com

Chicago Interventional Institute and Vein Clinic

Affiliated Radiologists S.C.

**Remember life before varicose veins?
You can feel that freedom again.**



No-Surgery, No-Scar EVLT



Nilesch Patel, MD



Hector Ferral, MD



Marc Alonzo, MD

Rush University
Professional BLDG., Suite 456
1725 West Harrison Street
Chicago, Illinois 60612
312.563.4238

We offer the most advanced laser technology to make eliminating varicose veins a great experience for you.

EVLT has been clinically proven safe, effective and non-traumatic. Performed right here in our office, the procedure lasts less than an hour. The great results last a lifetime.

Services Offered:

- * EVLT
- * Stab Phelectomy
- * Management of spider veins

To Schedule an appointment please call Megan McAuliffe at 312.563.4238

If Megan does not answer your call, please leave a detailed message with your name and a contact number. Megan will get back to you right away.

The Greatest Experience in Eliminating Varicose Veins



INTEGRITY
physical therapy

CHICAGO LOCATIONS

Lakeview • 3232 N. Lincoln Avenue 773.525.1533
 Loop • 20 S. Clark Street, 11th Floor 312.977.1708
 South Loop • 1131 S. State Street 312.212.1401
 Portage Park • 4862 W. Irving Park Road 773.282.9751

SUBURBAN LOCATIONS

Buffalo Grove • 462 Half Day Road 847.478.8340
 Elgin (a) • 75 Market Street, Suite 7 847.531.5974
 Elgin (b) • 750 Fletcher Drive 847.531.5974
 Hoffman Estates • 5050 Sedge Boulevard 847.645.9568
 Libertyville • 1950 N. Highway 45 847.281.8800
 Naperville • 1804 N. Naper Blvd, Suite 304 630.955.0059
 Northfield • 1847 Oak Street 847.441.7460
 Oak Park • 605 W. Madison 708.763.8597
 Park Ridge • 678 C Northwest Hwy, Suite 13B . . 847.384.9530

Clinically driven by the highest professional standards

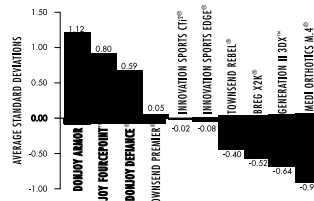
www.integritypt.com



DonJoy®
Not all braces are created equal.



Composite Scores for Six Biomechanical Parameters of Stability and Component Failure*



*Independent test data from the Orthopedic Biomechanics Laboratory at Children's Hospital of San Diego. Download the report at www.djortho.com/rd/ama_report.pdf

Market Leadership means more than offering 'just a knee brace.' Proven by independent sources, DonJoy continues to outperform the competition. Our superior product design, materials selection, and manufacturing processes ensure your patients receive the most dependable, well made, and highest quality functional braces on the market.



For more detailed information, please visit www.djortho.com or call 800.336.6569

© 2004 dj Orthopedics, LLC. All rights reserved. DonJoy, dj Ortho, Defense and Never Stop Getting Better are registered trademarks of dj Orthopedics, LLC. Fourpoint is a trademark of dj Orthopedics, LLC. 3DX is a trademark of Generation II, M-4 is a registered trademark of Medi Orthotics. Premier and Rebel are registered trademarks of Townsend Design. CTI and Edge are registered trademarks of Innovations Sports.

How do you harness ingenuity?



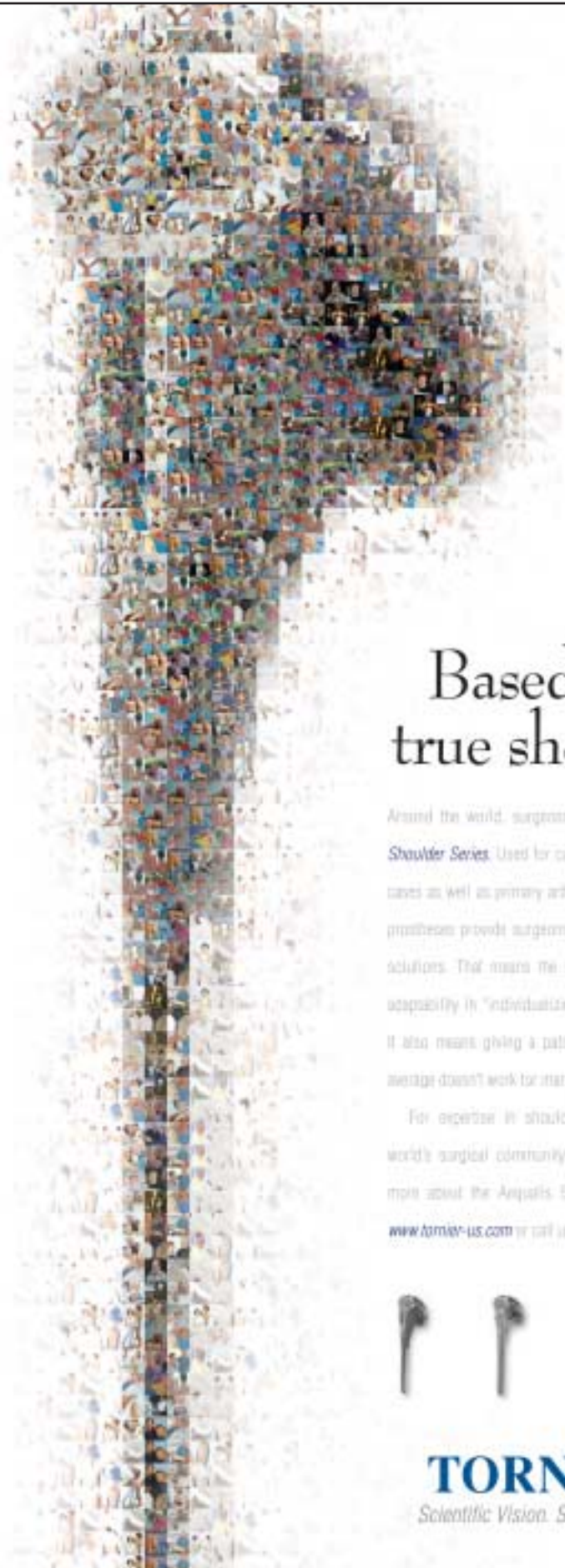Ingenuity. Integrity. Infinite possibilities.

Distributed by:

INNOTEK Medical Products, Inc.

Orthopedics & Neurosurgery

630.953.6301 innotek@innotekmedical.com



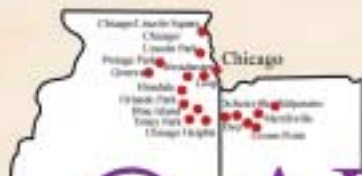Based on a true shoulder.

Around the world, surgeons prefer *Tornier's Aequalis® Shoulder Series*. Used for complex fractures and revision cases as well as primary arthroplasty, Aequalis shoulder prostheses provide surgeons with anatomically accurate solutions. That means the surgeon has unprecedented capability in "individualizing" the shoulder procedure. It also means giving a patient a better fit — because average doesn't work for many.

For expertise in shoulder implant technology the world's surgical community turns to Tornier. To learn more about the Aequalis Shoulder Series visit us at www.tornier-us.com or call us at 888-TORNIER.



TORNIER 
Scientific Vision. Surgical Leadership.



"The Largest Pain Management Group in the Midwest"

Specializing in Spinal Diagnostics & The Treatment of Back Pain, Neck Pain, and Chronic Pain



www.apacgroupe.com

Our Mission

To provide the most advanced, compassionate care to patients in pain.



Top Row, L-R: Faisal M. Rahman, Ph.D.; Najmeddin Beyranvand, M.D.; Ghassan S. Nemri, M.D.; Timothy E. King, M.D.;
2nd Row, L-R: Jonathan A. Seral, M.D.; Joseph Fillmore, M.D.; Mohammad Uddin, M.D.; John Kurbinski, Ph.D.; Shreyasi Dulat, M.D.;
3rd Row, L-R: Oren G. Carstman, M.D.; Reynaldo Parbo, M.D.; Randolph Chang, M.D.; Krishna Parameswar, M.D.; Thomas J. Valente, M.D.;
4th Row, L-R: Kalpana Doshi, M.D.; Janet Moy, M.D.; Angie Zielinski, APRN-BC, MSN, NP; Cynthia Mastbrook, M.D.; Ivailo Dimitov, M.D.;
Bottom Row, L-R: Ann Schilling, APRN-BC, MSN, NP; Susan Funckas, MSN, RN, ANP-BC

Conditions We Treat

Headache

- Cervicogenic Headaches
- Occipital Headaches

Neck Pain

- Herniated Disc
- Spondylosis (Axial Neck Pain)
- Biomechanical (Postural) Pain
- Whiplash

Low Back Pain

- Herniated Disc
- Spinal Stenosis
- Internal Disc Disruption (Annular Tear)
- Spondylosis (Axial Back Pain)
- Facet Mediated Pain
- Compression Fracture
- Scoliosis
- Sacroiliac Joint Pain
- Spondylolysis / Spondylolisthesis
- Failed Back Syndrome
- Biomechanical (Postural) Pain

Thoracic Pain

- Spondylosis (Axial Back Pain)
- Compression Fracture
- Scoliosis
- Herniated Disc

Musculoskeletal Pain

- Radiculopathy (Sciatica)
- Complex Regional Pain Syndrome (RSD)
- Post-Herpetic Neuralgia (Shingles)
- Fibromyalgia
- Sports Injuries
- Joint Pain

Treatments We Offer

Medical Treatment

- IDET
- Epidural Steroid Injections
- Racz Catheter Lysis of Adhesions
- Percutaneous Disc Decompression
- Radiofrequency of Medial Branch Nerves for Facet Joint Pain
- Sacroiliac Joint Injection
- Occipital Nerve Injection
- Stellate Ganglion Injection
- Lumbar Sympathetic Injection
- Discography
- Facet Joint Injection
- Peripheral Nerve Injection
- Trigger Point Injection
- Joint Injection
- Synvisc

Physical & Occupational Therapy

- Spine-Oriented Physical Therapy
- Skilled Manual Therapy
- Aquatic Therapy
- Massage Therapy
- Acupuncture

Surgical Treatment

- Neuromodulation (Spinal Cord Stimulation)
- Implantable Infusion Devices (Morphine Pump)

Medication Management

- Anti-Inflammatory Medications
- Neuropathic Medications
- Opioid Medications

Workers Compensation

- IMEs
- Facilitate Functional Capacity Exams
- Interventional / Medical Management

Psychological

- Behavioral Strategies to Help Manage Pain
- Coping Skills
- Strategies to Improve Sleep
- Biofeedback & Relaxation Training
- Management of Depression

We have over 21 locations and Board Certified Physicians to better serve you in Illinois and Northwest Indiana

Scheduling: Chicago (312) 442-9102, Geneva (630) 443-2068, Western Suburbs (708) 483-7007, South Suburbs (708) 342-7994, Northwest Indiana (219) 756-2722

Directory

Midwest Orthopaedics at Rush thanks the following advertisers for helping make this publication possible.

Accountants

Wolf & Company, LLP.....see page 27

Ambulatory Surgery Centers

Rush SurgiCentersee page 22

Answering Services

The Center, Inc.
1853 Bernice Rd., Lansing, IL 60438
(800) 237-8228 • (708) 730-3324 Fax

Banking

Citibank.....see back cover

Harris Bank.....see page 22

Collection Agencies

Illinois Collection Service, Inc.see page 32

Communications

Applied Communications Groupsee page 31

Financial Planning

William Blair & Company, L.L.C.see page 30

Health Care

Accelerated Rehabilitation Centers.....see page 23

Rush Oak Park Hospital.....see page 23

Health Care Software & Services

Merge eFilmsee page 9

Health Care Technology

Scribe, Inc.....see page 32

Health Insurance Brokers & Consultants

Benefitdecisions, Inc.
125 S. Wacker Dr., Ste. 2075, Chicago, IL 60606
(312) 606-4800 • (312) 606-8108
www.benefitdecisions.com

Home Health Care Agencies

Girling Health Care, Inc.see page 33

Imaging

FUJIFILM Medical Systems USA, Inc.see page 30

Insurance — Medical Malpractice

Gallagher Healthcare
Insurance Services, Inc.....see page 23

Law Firms

McGuireWoods LLP
77 W. Wacker Dr., Ste. 4100, Chicago, IL 60601
(312) 750-6016 • (312) 849-3690 Fax
www.mcguirewoods.com

Marketing Communications

Omnia Marketing & Design.....see page 32

Medical Device Companies

Tornier.....see page 36

Office Equipment

Chicago Office Technology Group
1 E. Wacker Dr., Ste. 1305, Chicago, IL 60601
(630) 771-2600 • (630) 771-2601 Fax
www.cotg.com

Column Office Equipment, Inc.see page 32

Orthopaedic Supplies

DonJoy Orthopaedicssee page 35

Orthotics & Prosthetics

Scheck & Siress.....see page 15

Pain Management

Apac Groupe Centers
for Pain Managementsee page 37

Physical Therapy & Sports Medicine

AthletiCo.....see page 33

ATI.....see inside front cover

Integrity Physical Therapysee page 35

NovaCare Rehabilitationsee page 31

OccuSport Physical Therapysee page 38

Performance Physical Therapysee page 33

Physiotherapy Associates.....see page 30

Rush University Medical Centersee page 11

WCS Physical Work Re-Training.....see page 29

Promotional Products

Presto Marketing, Inc.see page 31

Publishing

Chicago Magazine.....see inside back cover

Radiology

Affiliated Radiologists S.C.see page 34

Radiography Equipment & Supplies

SourceOne Healthcare Technologiessee page 32

Signs

Van Bruggen Signs, Inc.
13401 Southwest Hwy., Orland Park, IL 60462
(708) 448-0826 • (708) 448-9092 Fax
www.vbsign.com

Software

SRS Software.....see page 16

Spine Implants

DePuy Spinesee page 35

Sports

Chicago Rush.....see page 31



**Orthopedic Rehabilitation • Sports Medicine • Hand Therapy • Sport-Specific Training
Golf Fitness • Massage Therapy • Women's Health Services • Industrial Medicine
Work Hardening/Work Conditioning • Injury Prevention Programs for Employers**

2403 Harnish Dr., Ste. 100
Algonquin, IL 60102
Phone: 847.854.6482
Fax: 847.854.6483

9634 S. Pulaski Rd.
Oak Lawn, IL 60453
Phone: 708.423.4800
Fax: 708.423.4843

420 Summit Dr.
Lockport, IL 60441
Phone: 815.834.9901
Fax: 815.834.9904

337 W. 75th Steet
Willowbrook (Darien), IL 60527
Phone: 630.789.0004
Fax: 630.789.0095

2900 Foxfield Rd., Ste. LLA
St. Charles, IL 60174
Phone: 630.587.5788
Fax: 630.587.8570

7225 W. College Dr.
Palos Heights, IL 60463
Phone: 708.361.5355
Fax: 708.361.5399

7166 Caton Farm Rd.
Plainfield, IL 60544
Phone: 815.609.3554
Fax: 815.609.3556

15635 S. 94th Ave.
Orland Park, IL 60462
Phone: 708.460.8588
Fax: 708.460.8788

www.occusport.com



Midwest
Orthopaedics
at RUSH
TEAM PHYSICIANS
Chicago White Sox & Chicago Bulls

CHICAGO MAGAZINE RECOGNIZES MIDWEST ORTHOPAEDICS AT RUSH FOR THEIR ADVANCEMENTS IN SPORTS MEDICINE

Pictured above from left: Nikhil N. Verma, M.D., Trish L. Palmer, M.D., Gregory P. Nicholson, M.D., Brian J. Cole, M.D., M.B.A., Bernard R. Bach, Jr., M.D., Charles A. Bush-Joseph, M.D., Kathleen M. Weber, M.D., Anthony A. Romeo, M.D. Additional Physicians: Howard An, M.D. Gunnar B. Andersson, M.D., Ph.D. Richard A. Berger, M.D. Mark S. Cohen, M.D. Craig J. Della Valle, M.D. John J. Fernandez, M.D. April Fetzer, D.O. Joseph Fillmore, M.D., M.B.A. Jorge O. Galante, M.D. Steven Gitelis, M.D. Edward J. Goldberg, M.D. George B. Holmes, Jr., M.D. Joshua J. Jacobs, M.D. Simon Lee, M.D. Wayne Paprosky, M.D. Frank M. Phillips, M.D. Aaron Rosenberg, M.D. Mitchell Sheinkop, M.D. Kern Singh, M.D. Scott Sporer, M.D. Walter Virkus, M.D. Yejia Zhang, M.D., Ph.D.

Chicago
magazine®



We want you to work hard
at your practice, not at
your credit application.

Find out more about our Physicians' Loan Program. Your medical practice needs your undivided attention; your loan application shouldn't. At Citibank we can help you get a loan or a line of credit to grow your practice or improve cash flow. Citibank is the proud sponsor of MidWest Orthopaedics at RUSH.

For more information please contact:
Regina A. Rogers, Relationship Manager, V.P.
Citibank Commercial Banking, at 630-790-5645.

