

# Arthroscopic Meniscus Transplantation: Bridge in Slot Technique

KEVIN B. FREEDMAN, BRIAN J. COLE, AND JACK FARR

## ARTHROSCOPIC MENISCUS TRANSPLANTATION: BRIDGE IN SLOT TECHNIQUE IN A NUTSHELL

### History:

Previous meniscectomy, ipsilateral joint line pain, activity-related swelling

### Physical Examination:

Joint line pain; evaluate for malalignment or ligament insufficiency

### Imaging:

Standing radiographs, including 45-degree posteroanterior and mechanical axis views; magnetic resonance imaging and bone scan usually unnecessary

### Indications:

Prior meniscectomy, normal alignment, stable knee, intact articular cartilage (less than grade III)

### Contraindications:

Significant articular disease (grade III or IV), inflammatory arthritis, uncorrected comorbidities (malalignment, cartilage defects, ligament insufficiency)

### Preoperative Planning:

Meniscus sizing: anteroposterior (meniscus width) and lateral (meniscus length [ $\times 0.8$  for medial,  $\times 0.7$  for lateral meniscus]) radiographs, corrected for magnification

Meniscus preservation: fresh-frozen or cryopreserved

### Surgical Technique:

Arthroscopic preparation: debride remaining meniscus to 1- to 2-mm rim; limited notchplasty; meniscus repair exposure on medial or lateral side

Exposure: mini-arthrotomy on ipsilateral side of patellar tendon

Slot preparation: in line with anterior and posterior horns; slot created with 4-mm bur; drill guide used for guide pin insertion; ream over guide pin; do not penetrate posterior cortex; box cutter and rasp

Meniscal allograft preparation: debride meniscus to attachment sites; bone bridge 7 mm wide and 1 cm high; remove bone beyond posterior horn; leave bone beyond anterior horn; number 0 PDS vertical mattress traction suture at posterior one-third junction

Meniscus insertion: nitinol pin to pass traction suture through repair incision; meniscus inserted through arthrotomy and reduced

Meniscus fixation: allograft bone screw for fixation of bone bridge in slot; inside-out vertical mattress sutures in meniscus

Closure: standard arthrotomy closure

### Postoperative Management:

Hinged knee brace; range of motion 0 to 90 degrees first 4 weeks, then full motion; partial to full weight bearing over first 4 weeks, then weight bearing as tolerated; return to sports at 4 to 6 months

Contemporary understanding of the natural history and biomechanical consequences of the meniscectomized knee has led to a commitment to preserve the meniscus. However, there is an existing population of patients who have already undergone subtotal meniscectomy, in addition to cases in which meniscal preservation is not possible. In these cases, the knee suffers from the loss of meniscus function, including load sharing, shock absorption, joint stability, joint nutrition, and protection of the articular cartilage. In an effort to restore normal knee anatomy and biomechanics, meniscal allografts are used to replace the native meniscus in select symptomatic individuals. Excellent pain relief and improved function can be achieved with rigid adherence to surgical indications.

### History

Patients typically report a history of one or more previous meniscectomies, performed arthroscopically or open. Usually, there is a near immediate and complete resolution of symptoms following open or arthroscopic meniscectomy. Over time, however, there is an increase in ipsilateral joint line pain, activity-related swelling, and generalized achiness affected by changes in the ambient barometric pressure. Occasionally, there are complaints of giving way and crepitus. A thorough history should elicit the mechanism of injury, associated injuries, and previous treatments, such as ligament reconstruction or management of articular cartilage lesions.

### Physical Examination

Typically, patients experience tenderness along the ipsilateral joint line and may have palpable bony changes along the edges of the femoral or tibial condyle. The location of previous incisions should be noted and may provide evidence of prior meniscectomy. It is essential to evaluate for concomitant pathology that would modify treatment recommendations, such as malalignment or ligament deficiency. Because only minor degrees of arthritic change are considered acceptable in candidates for meniscus transplantation, motion is generally preserved.

### Imaging

Diagnostic imaging should begin with a standard weight-bearing anteroposterior (AP) radiograph of both knees in full extension, a non-weight-bearing 45-degree-flexion lateral view, and an axial view of the patellofemoral joint. Additionally, a 45-degree-flexion weight-bearing posteroanterior radiograph is recommended to help identify subtle joint space narrowing that traditional extension views may fail to identify. Special studies such as a long-cassette mechanical axis view or magnetic resonance imaging should be ordered if there is any degree of clinical malalignment or

suspicion of chondral injury, respectively. Generally, magnetic resonance imaging should be reserved for difficult cases in which the diagnosis remains unknown, especially in the setting of completely normal radiographs. Techniques include two-dimensional fast spin echo and three-dimensional fat suppression with and without intra-articular gadolinium. When questions remain about the source of a patient's symptoms, a three-phase technetium bone scan is potentially useful. Both magnetic resonance imaging and bone scan may demonstrate increased signals in the affected compartment related to stress overload due to the meniscal deficiency.

### Indications and Contraindications

Indications for meniscus transplantation are prior meniscectomy with persistent pain in the involved compartment, intact articular cartilage (less than grade III), normal alignment, and a stable joint. Simultaneous or staged ligament reconstruction or realignment procedures can be performed in patients who otherwise have appropriate indications for the procedure. In addition, patients with recurrent failure of anterior cruciate ligament (ACL) reconstruction who have medial meniscal deficiency may be candidates for combined ACL reconstruction and medial meniscus transplantation to increase knee stability. Contraindications are most commonly significant articular disease (grade III or IV) or radiographic osteoarthritic changes. Localized chondral defects can be treated concomitantly with cartilage restoration techniques. Additional contraindications are inflammatory arthritis, obesity, and previous infection.

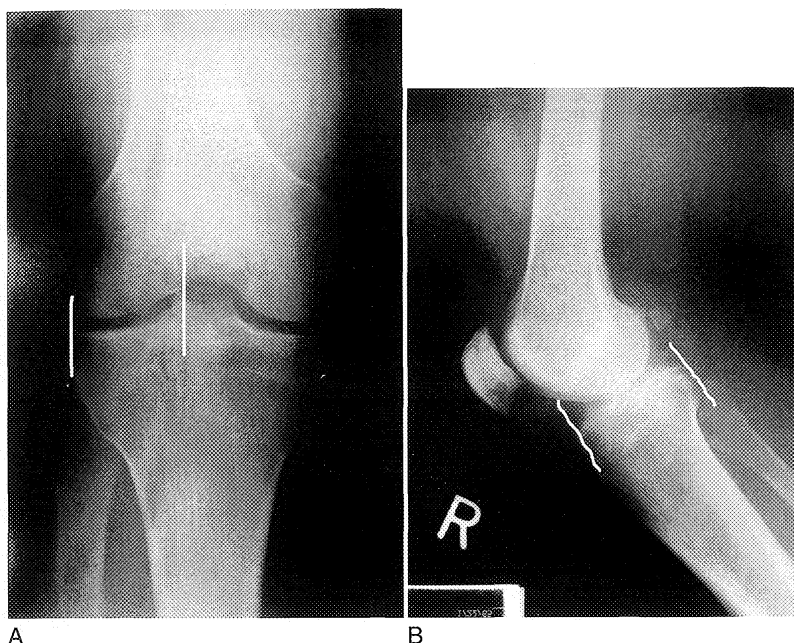
### Preoperative Planning

#### Concomitant Procedures

In cases of significant limb malalignment and ligament insufficiency, these deformities should be corrected either before or concomitant with meniscus transplantation. Technical considerations regarding the simultaneous performance of these procedures are discussed later.

#### Meniscus Sizing

Meniscal allografts are size and compartment specific. Precise preoperative measurements are obtained from AP and lateral radiographs with magnification markers placed on the skin at the level of the joint line. The meniscus width is determined on the AP radiograph (from the edge of the ipsilateral tibial spine to the edge of the tibial plateau), and the meniscus length is determined on the lateral radiograph (AP dimension of the ipsilateral tibial plateau). Following correction for magnification, this number is multiplied by 0.8 for the medial and 0.7 for the lateral meniscus (Fig. 53-1).



**Figure 53-1** Meniscus sizing is performed by first correcting for magnification. *A*, Meniscus width (coronal plane) is calculated on the anteroposterior radiograph by measuring the distance from the peak of the tibial eminence (medial or lateral) to the tibial metaphyseal margin, ignoring marginal osteophytes. *B*, Meniscus length (sagittal plane) is determined on the lateral radiograph. The medial meniscal length is 80%, and the lateral meniscal length is 70%, of the sagittal tibial plateau distance measured at the joint line between a line parallel to the anterior tibia and one tangential to the posterior plateau margin perpendicular to the joint line.

### **Meniscal Graft Processing and Preservation**

Meniscal allografts are harvested using sterile surgical technique within 24 hours of death. Following the harvest, the tissue is preserved by one of four methods: fresh, cryopreservation, fresh-frozen, or lyophilization. Unlike in fresh osteochondral allografts, cell viability in meniscal allografts does not seem to improve the morphologic or biochemical characteristics of the grafts; thus, the most commonly implanted grafts are either fresh-frozen or cryopreserved. The risk of disease transmission is minimized through rigid donor screening, graft culturing, and polymerase chain reaction testing for human immunodeficiency virus (HIV).

### **Surgical Technique**

#### **Positioning**

Depending on surgeon preference, the limb can be placed in a standard leg holder or maintained in the unsupported supine position. The posteromedial or posterolateral corner of the joint must be freely accessible to perform an inside-out meniscus suturing technique.

### **Examination under Anesthesia**

An examination under anesthesia should be performed to confirm full range of motion and the absence of concomitant ligamentous laxity.

### **Diagnostic Arthroscopy**

In most cases, diagnostic arthroscopy has been performed before surgery to confirm meniscal deficiency. However, at the time of surgery, meniscal deficiency and the integrity of the articular surface should be confirmed. In general, if chondral changes greater than grade III are present on the femoral condyle or tibial plateau, meniscus transplantation is not indicated, because the results will be compromised.

### **Specific Surgical Steps**

#### **Arthroscopic Preparation**

The initial steps for medial and lateral meniscus transplantation are similar and are performed in the ipsilateral compartment only. The remaining meniscus is

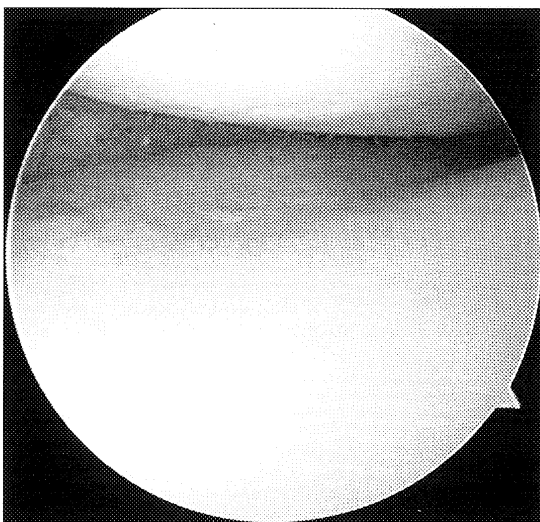
arthroscopically debrided to a 1- to 2-mm peripheral rim until punctate bleeding occurs (Fig. 53-2). The remnant of the anterior and posterior meniscal horns can be maintained to provide a footprint for subsequent allograft placement. In addition, performing a limited notchplasty along the most inferior and posterior aspects of the femoral condyle adjacent to the cruciate ligaments is helpful to visualize the posterior horn and to pass the meniscus into the recipient slot. A standard meniscus repair exposure on the posteromedial or posterolateral joint line is performed and is situated one third above the joint line and two thirds below it to protect the neurovascular structures during an inside-out meniscus repair.

#### Exposure

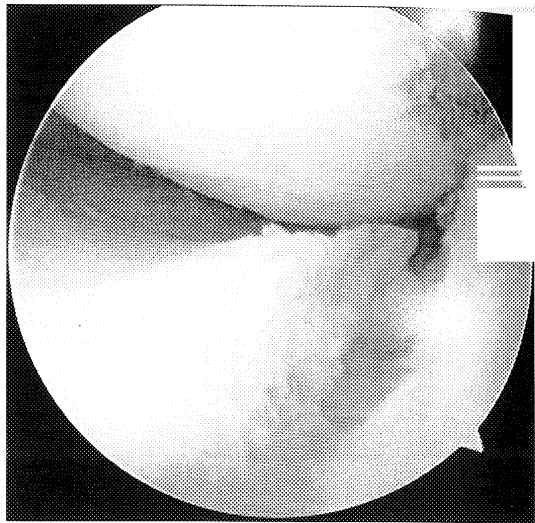
It is necessary to perform a mini-arthrotomy in line with the anterior and posterior horns of the involved meniscus to permit accurate, "in-line" guide placement during slot formation and introduction of the meniscus. Depending on the surgeon's preference, the mini-arthrotomy may be immediately adjacent to the patellar tendon or in a portion of the patellar tendon in line with its fibers.

#### Slot Preparation

A slot is created based on the normal anatomy of the meniscus attachment sites. Using electrocautery, a line is marked to connect the centers of the anterior and posterior horn attachment sites. With this line as a guide, a 4-mm bur is used to create a superficial reference slot equal to the height of the bur and parallel to the sagittal slope of the tibial plateau (Fig. 53-3). A level slot



**Figure 53-2** Arthroscopic view demonstrating the periphery of the host medial meniscus debrided to within 1 to 2 mm of the capsule to promote punctate bleeding.

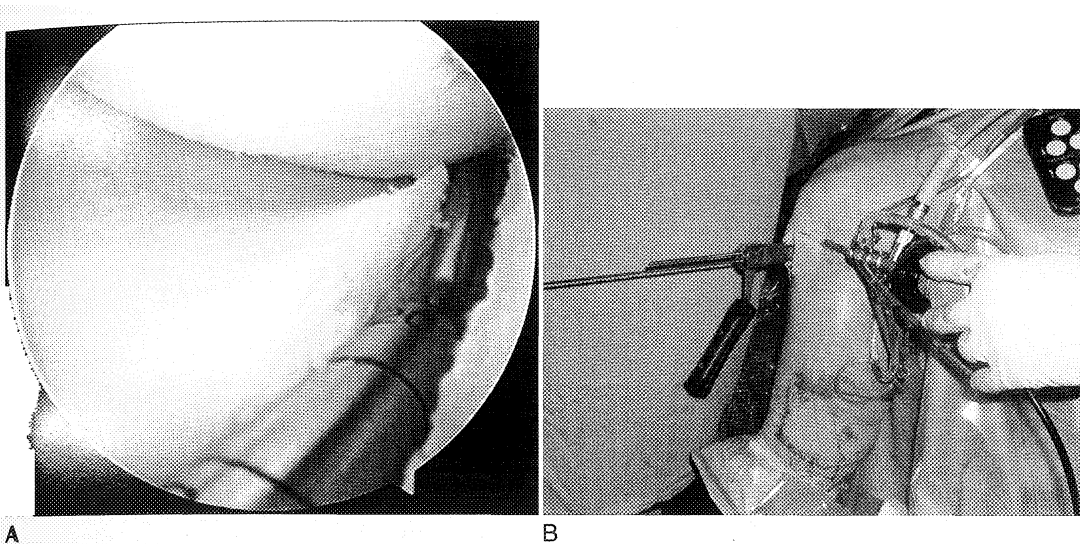


**Figure 53-3** Arthroscopic view of the reference slot created in line with the anterior and posterior horns of the medial meniscus using a 4-mm arthroscopic bur to create a flat subchondral surface. This is facilitated by making a satellite portal through the patellar tendon at the level of the joint line in line with the horn insertion sites.

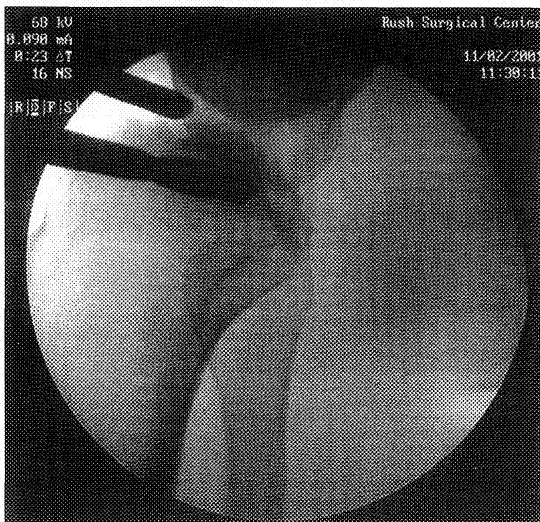
should be confirmed by placing a depth gauge in the reference slot; the depth gauge should also be used to determine the AP length of the tibial plateau. Using a drill guide, an insertion pin is placed under fluoroscopic guidance in a parallel fashion (Fig. 53-4). Care should be taken to ensure that the pin does not overpenetrate the posterior cortex. A reamer is then used to drill over the guide pin with a 7- or 8-mm cannulated drill bit (Fig. 53-5). The posterior cortex of the tibia should be maintained. A 7- or 8-mm box cutter is then used to create a slot 7 or 8 mm wide by 10 mm deep. A 7- or 8-mm rasp is used to smooth the final slot. This ensures that the bone bridge will slide smoothly into the slot (Fig. 53-6).

#### Meniscal Allograft Preparation

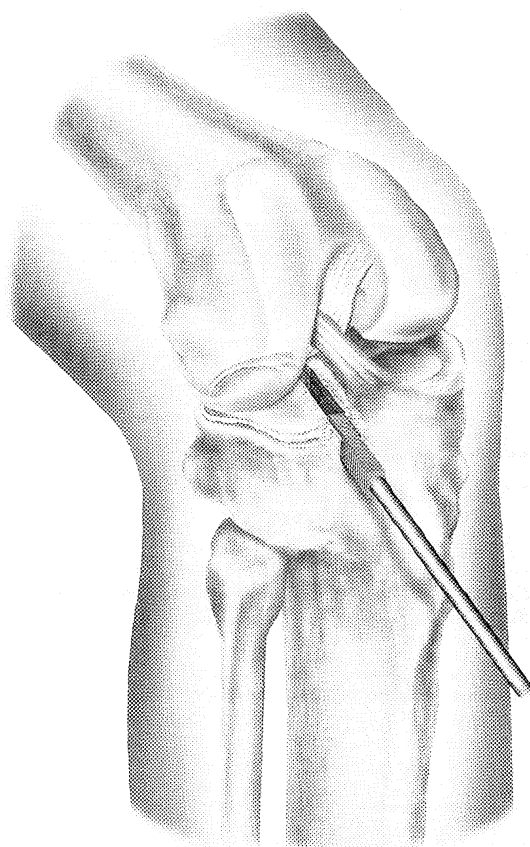This technique creates a slotted meniscus with a 1-mm-undersized bone bridge. The undersized bridge prevents inadvertent bridge fracture during insertion. The attachment sites of the meniscus are identified on the bone block, and the accessory attachments to the meniscus are debrided. Only the true attachment sites should remain, usually 5 to 6 mm wide. The bone bridge is then cut to a width of 7 mm and a height of 1 cm. Any bone that extends beyond the posterior horn attachment should be removed. However, bone extending beyond the anterior horn attachment is left intact, because this provides graft integrity during insertion. A temporary vertical mattress traction suture is placed at the junction of the posterior middle third of the meniscus using a number 0 PDS suture (Fig. 53-7). The anterior horn of the medial meniscus usually extends to the anteriormost extent of the tibial plateau for its attachment. In addition, the



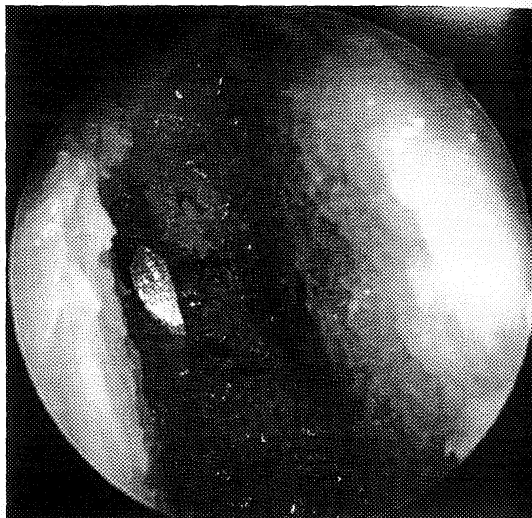
**Figure 53-4** A, The reference arm (depth gauge) is placed through the top hole of the drill guide and rests within the reference slot. B, An insertion pin is placed in a parallel fashion through the inferior hole. To ensure that the pin does not overpenetrate the posterior cortex, it should be placed under fluoroscopic guidance.



**Figure 53-5** Fluoroscopic view of a 7-mm reamer passing over the guide pin, taking care to avoid penetrating the posterior cortex.

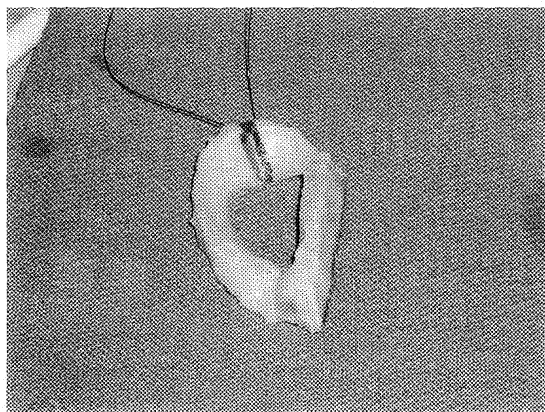


A



B

**Figure 53-6** A, A 7- or 8-mm three-sided rasp is used to create the rectangular recipient slot. B, The recipient slot is uniform in nature from anterior to posterior, as seen arthroscopically. (Courtesy of Regeneration Technologies, Inc., Alachua, FL.)



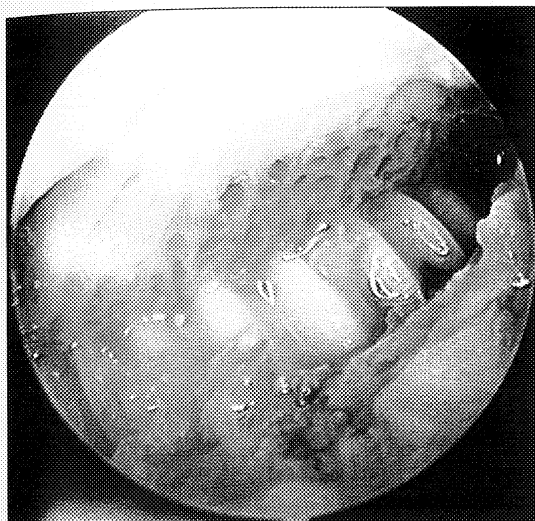
**Figure 53-7** Medial meniscus prepared by creating a rectangular slot 7 mm wide and 1 cm deep, measured at the insertion of the anterior and posterior horns. A traction suture is placed at the junction of the posterior and middle third of the body of the meniscus to facilitate introduction into the knee.

anterior horn attachment can be 7 to 9 mm wide. If the anterior horn width is greater than 7 mm, the attachment should be left intact, and the width of the bone bridge should be increased appropriately in the area underneath the anterior horn only. The remainder of the bone bridge should be trimmed to 7 mm as planned. Before insertion, the most anterior aspect of the recipient slot should be widened to fit the enlarged bone bridge.

#### Meniscus Insertion and Fixation

A single-barrel zone-specific cannula for inside-out suture technique is placed in the contralateral portal and is used to advance a long nitinol suture-passing pin through the knee capsule at the attachment site of the posterior middle third of the meniscus. This should exit the accessory posteromedial or posterolateral incision. The proximal end of the nitinol pin is then withdrawn from the arthrotomy site to facilitate passage of the meniscus into the knee. The traction sutures are passed through the loop of the nitinol pin, and the sutures are withdrawn through the accessory incision.

The meniscus is inserted through the arthrotomy, taking care to align it with the recipient slot while gently pulling on the traction suture. The meniscus should be appropriately reduced. The proper size and position of the meniscus are confirmed by cycling the knee through its range of motion. An allograft cortical bone interference screw is used to achieve final fixation of the bone bridge in the slot (Fig. 53-8). The meniscus is then fixed with standard vertical mattress sutures using an inside-out technique (Fig. 53-9).



**Figure 53-8** A fully threaded interference cortical bone screw is placed adjacent to the meniscus, achieving rigid fixation.



**Figure 53-9** Medial meniscus is reduced and sutured to the periphery using 2-0 nonabsorbable vertically placed mattress sutures.

## Closure

Standard closure of the arthrotomy and accessory incisions is performed.

## Postoperative Management

There is progression from partial to full weight bearing with crutches over the first 4 postoperative weeks. The patient is placed in a hinged knee immobilizer and is allowed immediate motion from 0 to 90 degrees. Flexion with weight bearing is limited beyond 90 degrees for the first 4 weeks to protect the meniscus repair. At 4 weeks, full range of motion is allowed, and gentle strengthening is performed. In-line running is permitted at 12 weeks, and return to full activity is allowed at 4 to 6 months, provided lower extremity strength is at least 80% to 85% that of the nonoperated leg.

## Results

Following meniscal allograft transplantation, good to excellent results are achieved in nearly 85% of cases, and patients demonstrate a measurable decrease in pain and increase in activity level (Table 53-1). The risk of graft failure seems to be greatest with irradiated grafts and in patients with grade III to IV osteoarthritic changes.<sup>6</sup>

**Table 53-1 Clinical Results of Meniscal Allograft Transplantation**

Author (Date)	Follow-up	Outcome
Milachowski et al. (1989) <sup>5</sup>	14 mo mean	19 of 22 (86%) successful
Garrett (1993) <sup>3</sup>	2-7 yr	35 of 43 (81%) successful
Noyes et al. (1995) <sup>6</sup>	30 mo mean (range, 22-58 mo)	56 of 96 (58%) failed
van Arkel and de Boer (1995) <sup>9</sup>	2-5 yr	20 of 23 (87%) successful
Cameron and Saha (1997) <sup>1</sup>	31 mo mean (range, 12-66 mo)	58 of 63 (92%) successful
Goble et al. (1996) <sup>4</sup>	2 yr minimum	17 of 18 (94%) successful
Carter (1999) <sup>2</sup>	48 mo mean	45 of 51 (88%) successful
Rodeo (2001) <sup>8</sup>	2 yr minimum	22 of 33 (67%) successful 14 of 16 (88%) bone fixation 8 of 17 (47%) no bone fixation
Rath et al. (2001) <sup>7</sup>	5.4 yr mean (range, 2-8 yr)	14 of 22 (64%) successful



## Complications

Complications are rare and are similar to those following meniscus repair. These include incomplete healing of the meniscus repair, infection, arthrofibrosis, and neurovascular injury related to the repair technique. Persistent symptoms despite meniscal allograft are most frequently related to improper patient selection. Traumatic tears of the meniscus occur occasionally following meniscus transplantation and can be treated with standard arthroscopic meniscal repair techniques or partial meniscectomy when necessary.

## Technical Considerations for Concomitant Procedures

### High Tibial Osteotomy

Patients with a history of meniscectomy who develop secondary varus or valgus deformity should be treated with concomitant high tibial or distal femoral osteotomy, respectively. If performed as separate procedures, the limb realignment should be done first. When performed simultaneously, the meniscus transplant is completed first. Otherwise, the varus and valgus stress during the transplantation procedure could create excessive stress at the osteotomy site. Extreme caution must be used to avoid creating a fracture through the slot to the osteotomy site.

### Anterior Cruciate Ligament Reconstruction

Any concomitant ligamentous laxity must be addressed at the time of meniscus transplantation. When the surgeon is performing an ACL reconstruction and meniscus transplantation, all the soft tissue portions of the transplant technique should be performed first; then the ACL tibial and femoral tunnels should be reamed before meniscus slot placement. Placing the tibial ACL tunnel as close to the midline as possible decreases the interference between the tunnel and the meniscus slot. In addition, the meniscus bone bridge is trimmed at the

site of the intersection with the ACL tunnel. When using a patellar tendon graft, the bone bridge of the meniscal allograft is temporarily elevated to allow passage of the bone and is then reduced, as the tendon portion occupies a much smaller volume of the tunnel.

### Autologous Chondrocyte Implantation or Osteochondral Allografting

If an isolated chondral defect exists, it should be treated at the time of meniscus transplantation. It is typically easier and safer for the chondral procedure to be performed after all the steps of the meniscus transplant have been completed. This avoids any inadvertent damage to the articular cartilage graft during instrumentation or suture placement.

## References

1. Cameron JC, Saha S: Meniscal allograft transplantation for unicompartmental arthritis of the knee. *Clin Orthop* 337:164-171, 1997.
2. Carter TR: Meniscal allograft transplantation. *Sports Med Arthrosc Rev* 7:51-62, 1999.
3. Garrett JC: Meniscal transplantation: A review of 43 cases with two to seven year follow-up. *Sports Med Arthrosc Rev* 1:164-167, 1993.
4. Goble EM, Kane SM, Wilcox TR, Doucette SA: Meniscal allografts. In McGinty JB, Caspari RB, Jackson RW, Poehling GG (eds): *Operative Arthroscopy*. Philadelphia, Lippincott-Raven, 1996, pp 317-331.
5. Milachowski KA, Weismeir K, Wirth CJ: Homologous meniscus transplantation: Experimental and clinical results. *Int Orthop* 13:1-11, 1989.
6. Noyes FR, Barber-Westin SD: Irradiated meniscus allograft in the human knee: A two to five year follow-up. *Ortho Trans* 19:417, 1995.
7. Rath E, Richmond J, Yassir W, et al: Meniscal allograft transplantation: Two to eight year results. *Am J Sports Med* 29:410-414, 2001.
8. Rodeo SA: Current concepts: Meniscus allografts—where do we stand? *Am J Sports Med* 29:246-261, 2001.
9. van Arkel ERA, de Boer HH: Human meniscal transplantation: Preliminary results at 2- to 5-year follow-up. *J Bone Joint Surg Br* 77:589-595, 1995.