



# Mini-Open Subpectoral Biceps Tenodesis With an All-Suture Anchor

David R. Christian, BS, Michael L. Redondo, BS, MA,  
Gregory L. Cvetanovich, MD, Adam J. Beer, BS, and Brian J. Cole, MD, MBA

The long head of the biceps tendon can be a source of pain in a variety of shoulder pathologies such as including biceps tenosynovitis, type II SLAP tears, partial long head of the biceps tears, and long head of the biceps subluxations or dislocations among others. When nonoperative management has failed and surgical management is indicated, the long head of the biceps can be treated with either tenotomy or tenodesis. Although tenotomy is reliably effective, tenodesis is often preferred as it helps prevent complications such as cramping, fatigue, and supination and elbow flexion weakness. Several biceps tenodesis techniques have been described including suprapectoral vs subpectoral, open vs arthroscopic and a variety of fixation methods have been used including a biotenodesis screw, cortical button, bone bridge, and suture anchor. This article describes the technique for a mini-open, subpectoral on-lay biceps tenodesis using an all-suture anchor double loaded with suture tape. We prefer this method as it provides effective fixation with minimal tendon slippage and minimizes the risk of complication.

Oper Tech Sports Med 26:105-109 © 2018 Published by Elsevier Inc.

**KEYWORDS** biceps tenodesis, subpectoral, suture anchor, mini-open

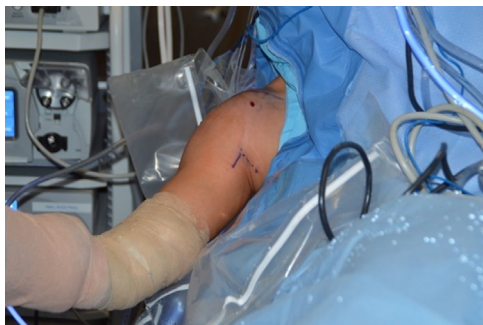## Introduction

Treatment for shoulder pathology involving the long head of the biceps (LHB) can include debridement, tenotomy, arthroscopic biceps tenodesis, or open biceps tenodesis. Surgical treatment of the LHB is indicated for patients who failed nonoperative management for conditions including biceps tenosynovitis, type II SLAP lesions, partial LHB tendon tears, and subluxations or dislocations of the LHB, and can also be considered certain patients with rotator cuff pathology and glenohumeral degenerative joint disease. When the decision is made to surgically release the biceps tendon, the option exists to decide between tenodesis and simple tenotomy. Although tenotomy has been found to reliably relieve pain, tenodesis is typically preferred as it helps avoid Popeye deformity of the biceps muscle, maintains the length-tension relationship,

and preserves elbow flexion and supination strength.<sup>1</sup> Additionally, tenotomy may be associated with poor functional result, cramping, and fatigue in 19%-38% of patients.<sup>2,3</sup> In our practice, tenotomy is generally reserved for patients at elevated risk of infection, those who are unable to comply with the postoperative rehabilitation required of biceps tenodesis, and those in whom cosmetic appearance of a Popeye deformity is not a concern. Biceps tenodesis can be performed with a variety of techniques including proximal vs distal, open vs arthroscopic, and with a variety of methods of fixation including a biotenodesis screw, cortical button, bone bridge, or suture anchor. We prefer a mini-open, distal subpectoral biceps tenodesis technique due to reduced incidence of residual pain and stiffness.<sup>4</sup> This is accompanied by reliable clinical outcomes and low complication rate.<sup>5,6</sup> Here we present the senior author's (B.J.C.) preferred method for biceps tenodesis, which is a mini-open, subpectoral on-lay technique using a double loaded all-suture anchor with broad suture tape to maximize suture-tendon biomechanics and prevent slippage while allowing insertion into a small outer diameter (1.7 mm) drill hole that reduces the risks for postoperative complications.

Department of Orthopaedic Surgery, Rush University Medical Center, Chicago, IL.

Address reprint request: Brian J. Cole, MD, MBA, Department of Orthopaedic Surgery, Rush University Medical Center, 1611 W Harrison St, Suite 300, Chicago, IL 60612. E-mail: [bcole@rushortho.com](mailto:bcole@rushortho.com)



**Figure 1** Patient positioning. Right shoulder prepared for open biceps tenodesis with the patient reclined in the beach chair position. The right arm is abducted 20°-30° and a 3 cm vertical incision is planned (solid marking pen line) superiorly at the border at the junction of the pectoralis major and anterior deltoid. Dotted marking pen line indicates the inferior border of the pectoralis major. (Color version of the figure available online.)

## Patient Positioning and Surgical Preparation

Preoperatively, an interscalene nerve block is administered and the patient is placed under conscious sedation. An examination under anesthesia is performed to assess for passive range of motion and instability. The patient is then placed the beach chair position to prepare for diagnostic arthroscopy (Fig. 1). A posterior portal is first established, 2 cm inferior and 1 cm medial to the posterolateral acromion. Using direct visualization from the posterior portal and guidance with a spinal needle, a standard anterior portal is established through the rotator interval 1 cm lateral to the coracoid.

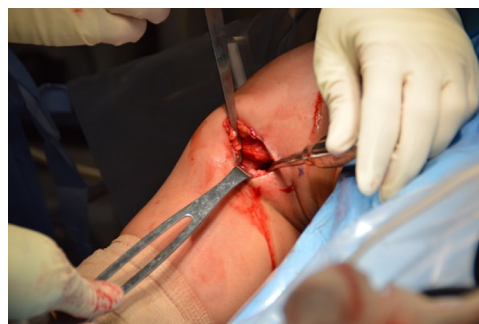## Surgical Technique

Once the posterior and anterior portals are established, a standard diagnostic arthroscopy is performed to evaluate for pathology of the glenoid, humeral head, labrum, rotator cuff, and biceps tendon. After diagnostic arthroscopy while viewing through the posterior portal, the long head of the biceps is incised at its junction with the superior labrum using an arthroscopic basket through the anterior portal. If needed, an arthroscopic shaver (Torpedo; Arthrex, Naples, FL) is used to gently remove any residual biceps tendon from the superior labrum.

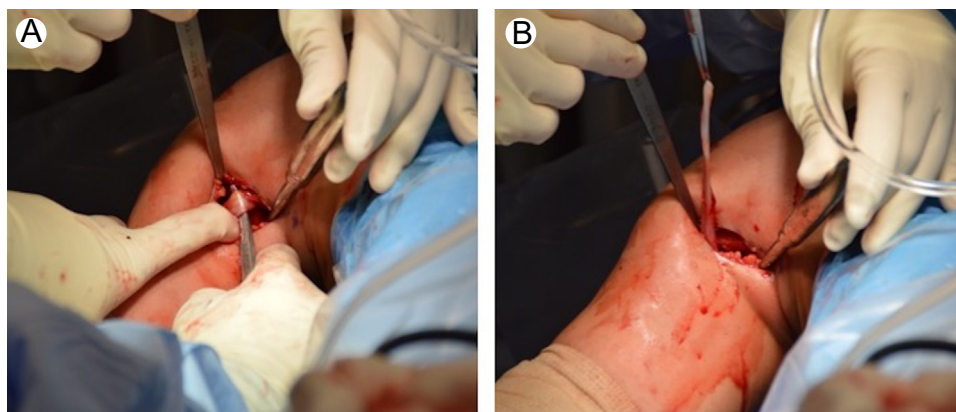
At the completion of shoulder arthroscopy, during which any pathology including the labrum and rotator cuff are addressed, the head of the bed is reclined an additional 20°. The arm is then slightly externally rotated and abducted. The inferior border of the pectoralis major is palpated and a 3-cm vertical incision is made from this inferior border headed distally just lateral to the axillary crease (Fig. 1). Blunt finger dissection or with a Metzenbaum scissors is used for the subcutaneous tissue and to enter the fascia just inferior to the pectoralis major and lateral to the short head of the biceps. Blunt dissection is used to develop the subpectoral plane in the direction of the humerus and the

LHB tendon is palpated in the bicipital groove adjacent to the pectoralis major tendon edge. A small pointed Hohmann retractor is then placed under the pectoralis major lateral to the biceps tendon entering just lateral to the pectoralis major tendon insertion. A Chandler retractor is gently placed against the medial aspect of the humerus, staying adjacent to the bone avoiding the neurovascular structures lying medially, particularly the musculocutaneous nerve (Fig. 2). An Army-Navy retractor can be used superiorly or inferiorly as needed for visualization. The LHB tendon that was previously released during the arthroscopic portion of the procedure can be retrieved either using a finger or curved hemostat (Fig. 3).

After retrieving the long head of the biceps, electrocautery is used to decorticate a 1.5 cm × 1.5 cm area in the subpectoral region at the distal aspect of the bicipital groove. At the desired site for fixation, an osteotome and a mallet are used to gently “fish-scale” the humeral cortex to enhance healing of the tenodesis and to help prevent guide migration (Fig. 4A). A straight drill guide is then placed at the desired location of the biceps tenodesis at the superior part of the prepared region of the distal biceps groove. Using the drill guide, a unicortical 1.7 mm hole is drilled (Fig. 4B). The position of the drill guide is maintained and a double loaded all-suture soft anchor (Biceps FiberTak Anchor; Arthrex, Inc, Naples, FL) is then gently impacted into the drill hole (Fig. 5). The sutures are gently tensioned to ensure anchor fixation. Each suture is passed through the LHB tendon with running, reinforced sutures over a 2 cm zone of the biceps tendon in a location that normalizes the tendon tension and typically about 1 cm proximal to the musculotendinous junction (Fig. 5). The opposite ends of both sutures that were not passed through the tendon are then pulled tightly to reduce the biceps tendon to the bone. The sutures are tied using the unpassed ends as posts to firmly fixate the biceps tendon to the prepared humeral surface. The remaining proximal tendon and excess suture are excised and the skin incision is closed with Monocryl suture and Dermabond (Ethicon, Somerville, NJ) (Fig. 6).



**Figure 2** Soft tissue dissection. Right shoulder vertical incision with a pointed Hohmann retractor placed laterally under the deltoid, a Chandler retractor medially, and an Army-Navy retractor inferiorly to enhance visibility. The subcutaneous tissue and fascia is dissected to view the long head of the biceps tendon. (Color version of the figure available online.)



**Figure 3** Long head of the biceps retrieval. (A) With a Chandler retractor medially and a Hohmann retractor laterally, an index finger is used to locate the long head of the biceps tendon on the anterior aspect of the humerus and a curved hemostat is used for retrieval. (B) Fully retrieved long head of the biceps tendon ready for tenodesis. (Color version of the figure available online.)

## Postoperative Management and Rehabilitation

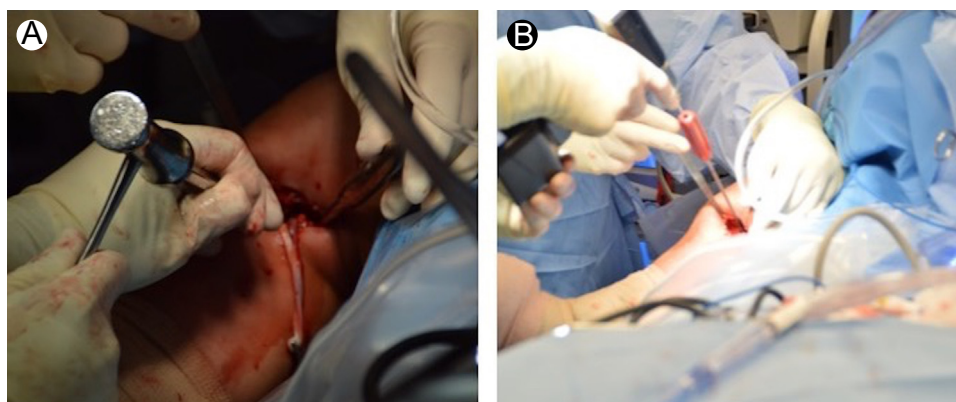
For the first 2 weeks following surgery, patients are instructed to wear an upper extremity immobilizer at all times except during instructed exercises and when tending to hygiene needs. When possible, patients should ice their shoulder either with ice packs or an icing machine for 20 minutes every 2 hours up until their first postoperative visit, which occurs 8-10 days after surgery. Beginning the first postoperative day, patients can begin wrist and hand range of motion and shoulder pendulum exercises two to three times per day. Patients are instructed not to perform any active elbow flexion or supination exercises against resistance for six weeks after surgery.

Patients may begin formal physical therapy two weeks after surgery, following their first postoperative visit. For the first four weeks after surgery, patients are instructed to only allow passive range of motion of their upper extremity. After 4 weeks, patients can advance to isometric exercises of the rotator cuff and deltoid as tolerated. Exercises involving the

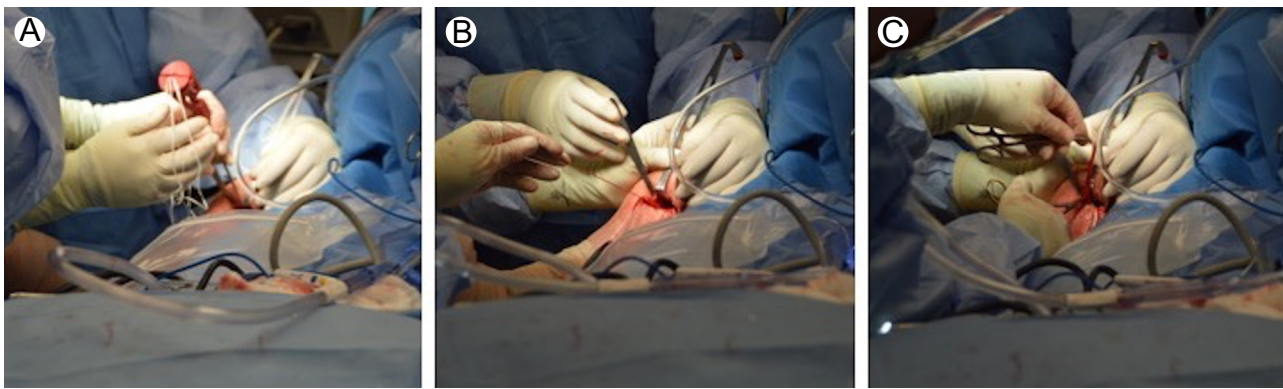biceps are avoided until 6 weeks postoperatively when isometric exercises are initiated. Exercises are slowly advanced to include exercise bands and dumbbells as tolerated. Beginning at 8 weeks, strength training is advanced to include eccentric, resisted exercises as tolerated. By 12 weeks, patients are advised to return to their full sport and activity as tolerated.

## Discussion

Biceps tenotomy and tenodesis are both surgical options for shoulder pathology involving the LHB. The senior author (B.J. C.) prefers to perform mini-open subpectoral biceps tenodesis, particularly in active patients, since tenotomy is associated with high incidence of cosmetic deformity (Popeye deformity), biceps cramping, and loss of elbow flexion and supination strength.<sup>2,3,7,8</sup> Although patients must go through a more prolonged rehabilitation protocol to avoid failure of the biceps fixation, tenodesis helps to prevent the complications seen with tenotomy by re-establishing the length-tension



**Figure 4** Humerus preparation. (A) A mallet and osteotome are used to gently “fish scale” the desired fixation site on the proximal humerus. (B) A straight spear is directed at the distal aspect of the bicipital groove and used as a guide for drilling of a 1.7 mm unicortical hole. (Color version of the figure available online.)



**Figure 5** All-suture anchor placement and tendon preparation. (A) Using the straight spear as a guide to maintain the position of the drill hole, the double loaded all-suture anchor is inserted. (B) Gentle traction is applied to the sutures to ensure fixation. (C) A running, reinforced suture is placed with the same side of both sutures in the long head of the biceps tendon over a 2 cm span that is 1 cm proximal to the musculotendinous junction. The opposite sides of the sutures are then pulled taught and tied to fixate the tendon on the anterior humerus. (Color version of the figure available online.)

relationship of the biceps. The subpectoral approach has been reported to result in the lowest risk of persistent postoperative pain and stiffness, and may help prevent over-tensioning of the muscle which significantly decreases the maximum load to failure.<sup>9</sup>

Arthroscopic and open tenodesis techniques using interference screws, suture anchors, or cortical buttons have all been shown to provide successful functional outcomes with no significant difference observed between the different techniques.<sup>5,6,10,11</sup> Cadaveric biomechanical studies have reported that interference screws provide superior fixation strength compared to knotless suture anchors.<sup>12</sup> More recently, however, the fixation strength of all-suture anchors has been found to be equivalent to interference screw strengths when using either subpectoral and suprapectoral approaches, making them an exciting option for use in biceps tenodesis.<sup>13,14</sup>

The all-suture anchor allows for a smaller diameter drill hole, which reduces bone loss and the associated significant complications. Minimizing drilling of the proximal humerus is an important consideration as proximal humerus fractures following biceps tenodesis with interference screw fixation have been reported.<sup>15,16</sup> Moreover, a biomechanical study

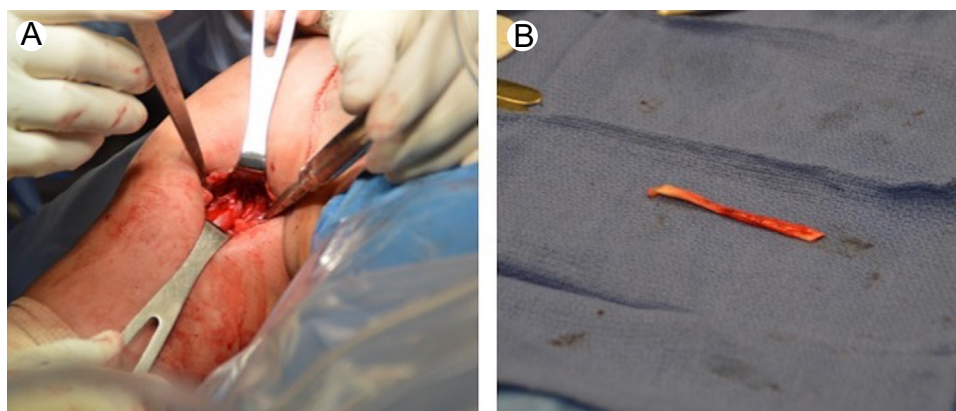
showed that biceps tenodesis with interference screw fixation significantly reduced maximum torque and rotation to failure, which may place overhead throwers at increased risk.<sup>17</sup> Additionally, the all-suture anchor requires only unicortical drilling which protects possible axillary nerve injury which is of greater risk with bicortical drilling.<sup>18</sup> Finally, the use of suture tape reduces the reported complication of tendon-suture slippage typically seen with small diameter sutures.<sup>19,20</sup>

## Conclusion

This report describes the senior author's (B.J.C.) preferred technique for mini-open all-suture anchor subpectoral biceps tenodesis. This technique is preferred as it provides an effective fixation technique with reliable clinical outcomes and minimal complication risk.

## Statement of Conflict of Interest

David Christian, Michael Redondo, Adam Beer, and Dr Gregory Cvetanovich have no conflicts of interest to disclose.



**Figure 6** Completed fixation and excised excess tendon. (A) Image showing the final fixation of the long head of the biceps on the anterior humerus. (B) Excised excess tendon after fixation. (Color version of the figure available online.)

Dr Brian Cole reports other from Aesculap/B. Braun, other from American Journal of Orthopedics, other from American Orthopedic Society for Sports Medicine, other from American Shoulder and Elbow Surgeons, personal fees and other from Arthrex, Inc, other from Arthroscopy, other from Arthroscopy Association of North America, other from Athletico, other from Cytori, other from Elsevier Publishing, other from international Cartilage Repair Society, other from Journal of Bone and Joint Surgery-American, other from Journal of Shoulder and Elbow Surgery, other from Journal of the American Academy of Orthopedic Surgeons, other from National Institutes of Health (NIAMS and NICHD), other from Ossur, personal fees and other from Regentis, other from Saunders/Mosby-Elsevier, other from Smith and Nephew, other from Tornier, outside the submitted work.

## References

- Voss A, Cerciello S, Yang J, et al: Open subpectoral tenodesis of the proximal biceps. *Clin Sports Med* 35(1):137-152, 2016
- Duff SJ, Campbell PT: Patient acceptance of long head of biceps brachii tenotomy. *J Shoulder Elbow Surg* 21(1):61-65, 2012
- Kelly AM, Drakos MC, Fealy S, et al: Arthroscopic release of the long head of the biceps tendon: Functional outcome and clinical results. *Am J Sports Med* 33(2):208-213, 2005
- Werner BC, Pehlivan HC, Hart JM, et al: Increased incidence of postoperative stiffness after arthroscopic compared with open biceps tenodesis. *Arthroscopy* 30(9):1075-1084, 2014
- Gombera MM, Kahlenberg CA, Nair R, et al: All-arthroscopic suprapectoral versus open subpectoral tenodesis of the long head of the biceps brachii. *Am J Sports Med* 43(5):1077-1083, 2015
- Green JM, Getelman MH, Snyder SJ, et al: All-arthroscopic suprapectoral versus open subpectoral tenodesis of the long head of the biceps brachii without the use of interference screws. *Arthroscopy* 33(1):19-25, 2017
- Boileau P, Baqué F, Valerio L, et al: Isolated arthroscopic biceps tenotomy or tenodesis improves symptoms in patients with massive irreparable rotator cuff tears. *J Bone Joint Surg Am* 89(4):747-757, 2007
- Walch G, Edwards TB, Boulahia A, et al: Arthroscopic tenotomy of the long head of the biceps in the treatment of rotator cuff tears: Clinical and radiographic results of 307 cases. *J Shoulder Elbow Surg* 14(3):238-246, 2005
- Werner BC, Lyons ML, Evans CL, et al: Arthroscopic suprapectoral and open subpectoral biceps tenodesis: A comparison of restoration of length-tension and mechanical strength between techniques. *Arthroscopy* 31(4):620-627, 2015
- Park JS, Kim SH, Jung HJ, et al: A prospective randomized study comparing the interference screw and suture anchor techniques for biceps tenodesis. *Am J Sports Med* 45(2):440-448, 2017
- Duchman KR, DeMik DE, Uribe B, et al: Open versus arthroscopic biceps tenodesis: A comparison of functional outcomes. *Iowa Orthop J* 36:79-87, 2016
- Patzer T, Santo G, Olender GD, et al: Suprapectoral or subpectoral position for biceps tenodesis: Biomechanical comparison of four different techniques in both positions. *J Shoulder Elbow Surg* 21(1):116-125, 2012
- Chiang FL, Hong CK, Chang CH, et al: Biomechanical comparison of all-suture anchor fixation and interference screw technique for subpectoral biceps tenodesis. *Arthroscopy* 32(7):1247-1252, 2016
- Baleani M, Francesconi D, Zani L, et al: Suprapectoral biceps tenodesis: A biomechanical comparison of a new soft anchor tenodesis technique versus interference screw biceps tendon fixation. *Clin Biomech (Bristol, Avon)* 30(2):188-194, 2015
- Reiff SN, Nho SJ, Romeo AA: Proximal humerus fracture after keyhole biceps tenodesis. *Am J Orthop (Belle Mead NJ)* 39(7):E61-E63, 2010
- Sears BW, Spencer EE, Getz CL: Humeral fracture following subpectoral biceps tenodesis in 2 active, healthy patients. *J Shoulder Elbow Surg* 20(6):e7-e11, 2011
- Beason DP, Shah JP, Duckett JW, et al: Torsional fracture of the humerus after subpectoral biceps tenodesis with an interference screw: A biomechanical cadaveric study. *Clin Biomech (Bristol, Avon)* 30(9):915-920, 2015
- Lancaster S, Smith G, Ogunleye O, et al: Proximity of the axillary nerve during bicortical drilling for biceps tenodesis. *Knee Surg Sports Traumatol Arthrosc* 24(6):1925-1930, 2016
- Gregory JM, Klosterman EL, Thomas JM, et al: Suture technique influences the biomechanical integrity of pectoralis major repairs. *Orthopedics* 38(9):e746-e752, 2015
- Edgar CM, Singh H, Obopilwe E, et al: Pectoralis major repair: A biomechanical analysis of modern repair configurations versus traditional repair configuration. *Am J Sports Med* 45(12):2858-2863, 2017