

# Nonarthroplasty Treatment of Glenohumeral Cartilage Lesions

L. Pearce McCarty III, M.D., and Brian J. Cole, M.D., M.B.A.

---

**Abstract:** Treatment of young, active persons with symptomatic cartilage lesions of the glenohumeral joint represents a significant challenge. Diagnosis of glenohumeral chondral defects is not always straightforward and effective treatment requires familiarity with a number of techniques. Low-demand individuals may accept palliative therapy in the form of arthroscopic debridement as a temporizing solution. However, younger, high-demand individuals require a careful, stepwise approach that includes reparative, restorative, and reconstructive strategies. Reparative strategies use marrow-stimulation techniques to induce formation of fibrocartilage. Restorative tactics attempt to replace damaged cartilage with hyaline or hyaline-like tissue using osteochondral or chondrocyte transplantation. Large lesions that are not candidates for reparative or restorative procedures can be approached using reconstruction methods such as biologic resurfacing. This review examines causes of chondral injury in the glenohumeral joint, discusses diagnostic strategies, and presents a practical framework including palliative, reparative, restorative, and reconstructive options with which one can formulate a treatment plan for these patients. **Key Words:** Glenohumeral—Cartilage lesion—Arthritis—Shoulder.

---

**D**egenerative processes affecting the glenohumeral joint are not uncommon, and may produce significant morbidity in up to 20% of elderly persons.<sup>1</sup> Prosthetic resurfacing of the humerus and glenoid has become the treatment of choice for many of these patients, and the volume of shoulder hemiarthroplasty and total shoulder arthroplasty has risen steadily in the United States, doubling from 10,000 cases a year to more than 20,000 cases a year over the past decade.<sup>2</sup> Many patients obtain durable pain relief and increased functionality as a result of prosthetic resurfacing. Nevertheless, the results of both traditional hemiarthroplasty and total shoulder arthroplasty in younger

people with glenohumeral cartilage loss have not been encouraging.<sup>3</sup> The young, active patient with symptomatic cartilage loss in the glenohumeral joint is not an ideal candidate for total shoulder arthroplasty and poses a challenge in terms of providing lasting pain relief and optimizing functionality. This review focuses on the surgical treatment of glenohumeral cartilage lesions outside of traditional arthroplasty, specifically discussing palliative, reparative, restorative, and reconstructive treatment options and offers an algorithm for patients with glenohumeral cartilage loss.

## INCIDENCE AND ETIOLOGY

The incidence rate of Outerbridge grade II-IV lesions as noted during arthroscopic evaluation of the shoulder has been estimated at 5%.<sup>4,5</sup> The spectrum of articular cartilage abnormalities in the glenohumeral joint includes idiopathic focal defects, chondrolysis, post-traumatic defects, osteochondritis dissecans (OCD), avascular necrosis, postsurgical cartilage abnormalities, and osteoarthritis.

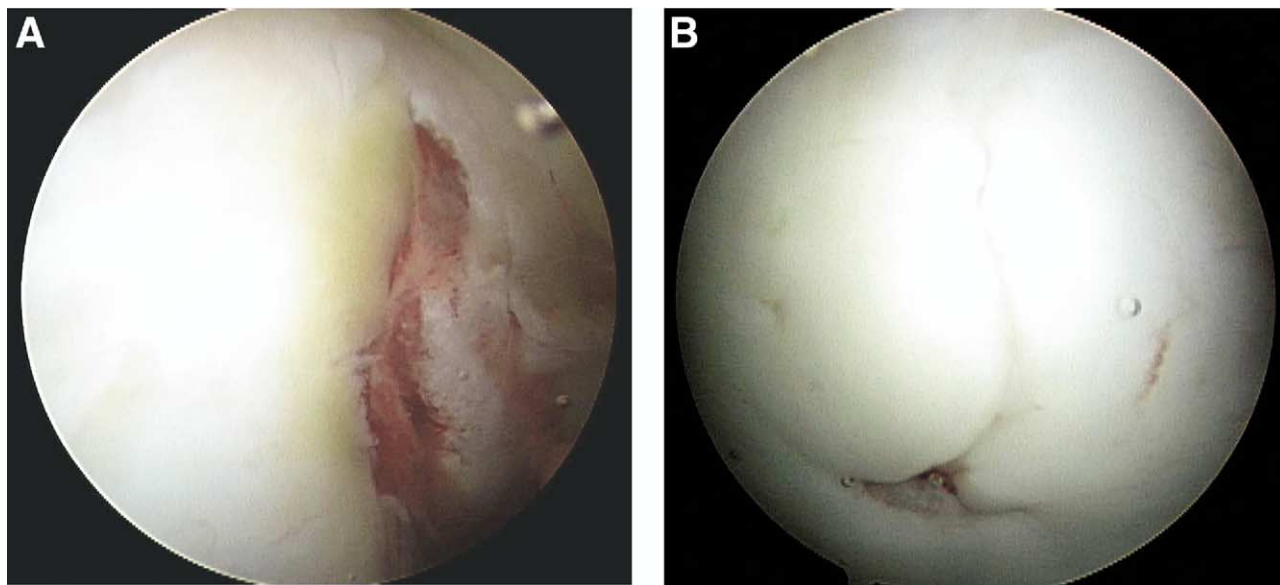
---

*From Sports and Orthopaedic Specialists, Minneapolis, Minnesota (L.P.M.), and Department of Orthopedics and Anatomy, Rush University Medical Center (B.J.C.), Chicago, Illinois, U.S.A.*

*Address correspondence and reprint requests to Brian J. Cole, M.D., M.B.A., Department of Orthopaedic Surgery, Rush University Medical Center, 1725 W Harrison St, Suite 1063, Chicago, IL 60612, U.S.A. E-mail: bcole@rushortho.com*

© 2005 by the Arthroscopy Association of North America  
0749-8063/05/2109-\$30.00/0

doi:10.1016/j.arthro.2005.06.023



**FIGURE 1.** (A) Arthroscopic image shows a large Hill-Sachs lesion following initial antero-inferior dislocation in a 17-year-old football player. (B) Image from the same patient shows chondral injury adjacent to but not directly part of the Hill-Sachs lesion.

Both acute and recurrent shoulder instability have a well-documented association with glenohumeral cartilage lesions.<sup>3,6-10</sup> A large percentage of first-time dislocations result in either a chondral shear injury or an osteochondral compression fracture of the posterolateral humeral head, as classically described by Hill and Sachs in 1940 (Fig 1).<sup>11</sup>

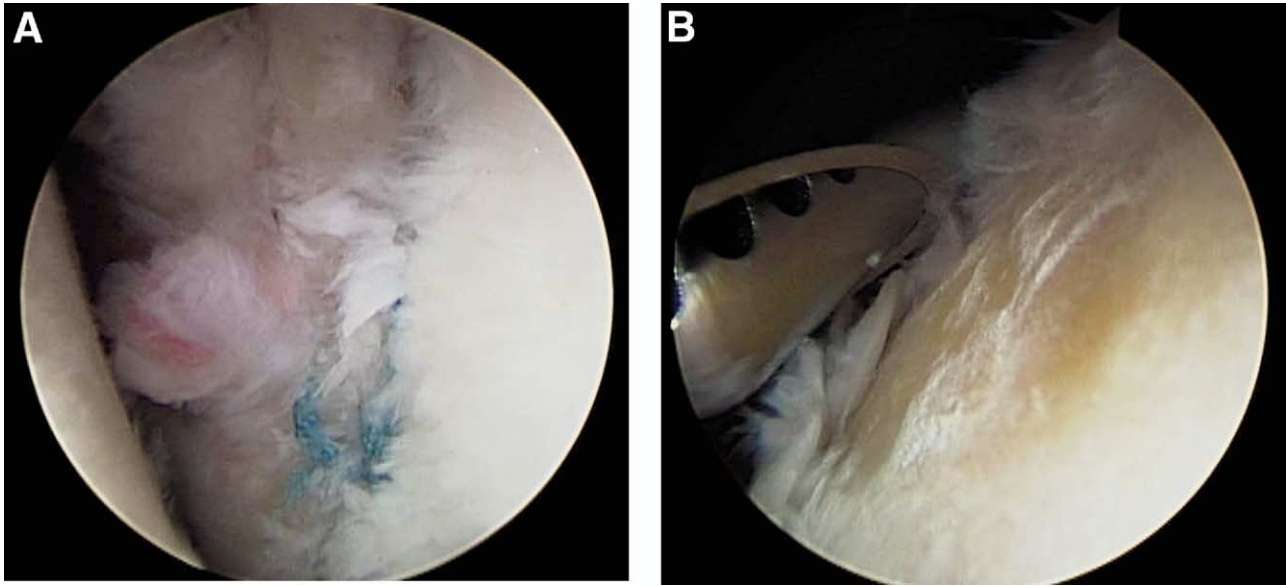
With respect to acute injury, investigators have reported the prevalence of chondral shear injuries and Hill-Sachs lesions among index anterior glenohumeral dislocations to range from 47% to 100% of cases.<sup>7,9,10,12</sup> As an osteochondral defect, the Hill-Sachs lesion can be an independent contributor to recurrent instability, as well as a source of significant discomfort.<sup>13</sup> What remains unclear from these studies are both the acute and long-term effects of these instability-related cartilage injuries. The natural history of the Hill-Sachs lesion or chondral shear injury occurring at the time of index dislocation is unknown.

Cameron and his colleagues<sup>8</sup> reviewed 422 cases from a mixed population of anterior, posterior, and multidirectional instability and found a significant and positive correlation between preoperative glenohumeral osteoarthritis (defined as presence of glenoid or humeral Outerbridge grade III or IV lesions) and time to surgery.<sup>8</sup> In another large retrospective study, Buscayret et al.<sup>6</sup> looked at a series of 570 cases of anterior instability and found an 8.4% prevalence rate of pre-

operative glenohumeral arthritis, positively correlated with 5 independent factors: time to surgical stabilization, presence of the Hill-Sachs lesion, presence of a glenoid rim impaction fracture, age at time of index dislocation, and presence of a rotator cuff tear.<sup>6</sup> Furthermore, Buscayret's study suggests that the presence of cartilage injury (Hill-Sachs lesion or glenoid rim impaction fracture) at the time of the index instability episode may portend development of glenohumeral arthritis.

Recurrent shoulder instability and procedures used to treat recurrent instability have also been correlated with glenohumeral cartilage pathology. Both anatomic reconstructive procedures such as the open Bankart technique, and nonanatomic reconstructions such as the Putti-Platt, Bristow, and Magnuson-Stack procedures have a well-documented association with glenohumeral arthrosis, known in the context of nonanatomic reconstruction as "capsulorrhaphy arthropathy."<sup>11</sup>

Rotator cuff pathology has also been associated with the presence of articular cartilage pathology in the shoulder. Gartsman and Taverna<sup>14</sup> reported a 13% prevalence of cartilage lesions in a series of 200 patients with full-thickness tears of the rotator cuff.<sup>14</sup> However, only 5% of patients had what were considered in the study to be "major" lesions, defined as areas of exposed bone  $\geq 150$  mm<sup>2</sup>. Paley et al.<sup>15</sup> reported a 17% prevalence of osteochondral lesions of the humeral head in a series of 41 high-level overhead



**FIGURE 2.** (A) Arthroscopic image during reoperation shows 2 malpositioned suture anchors near the center of the glenoid after a superior labral repair performed 4 months previously. (B) Image from same patient shows extensive cartilage loss from the humeral head caused by mechanical wear from the anchors.

throwing athletes with arthroscopically confirmed “internal impingement” of the rotator cuff.<sup>15</sup>

Patients presenting with a constellation of symptoms and findings consistent with subacromial impingement syndrome may also, in addition to or in lieu of rotator cuff or other soft-tissue pathology, have a higher prevalence of articular cartilage lesions. Ellman and colleagues<sup>16</sup> reported on a small series of patients diagnosed clinically with subacromial impingement who at the time of arthroscopy were found to have full-thickness cartilage loss ranging from 15 mm in diameter to half the surface area of the humeral head.<sup>16</sup> This population represented approximately 6% of patients having undergone arthroscopy for impingement during the study period, and had a mean age of 51 years. Furthermore, Guntern et al.<sup>17</sup> reported a 29% prevalence rate of humeral cartilage lesions and 15% prevalence of glenoid lesions, in a series of 52 patients having undergone glenohumeral arthroscopy for a diagnosis of subacromial impingement syndrome.<sup>17</sup>

OCD is an uncommon type of cartilage pathology affecting the glenohumeral joint. It differs from other processes in that the primary pathology lies within the subchondral plate, with secondary injury occurring to overlying articular cartilage.<sup>18</sup> Most often described in the femoral condyle, there are only isolated case reports of humeral head and glenoid involvement.<sup>19-23</sup>

Lesions are observed most commonly in young-to-middle-aged male patients along the anterosuperior aspect of the humeral head. The majority of these patients have a history of either a single traumatic event or repetitive microtrauma, although the exact etiology of OCD remains unclear in most cases.<sup>21</sup>

Cartilage loss has also been reported in conjunction with iatrogenic injury to the glenohumeral joint. Malpositioned intra-articular anchors for labral repair can generate significant mechanical destruction (Fig 2). Chondrolysis, in which there is near complete loss of humeral and/or glenoid articular cartilage, has been reported in association with the use of thermal energy during shoulder arthroscopy, as well as with the use of certain chemical dyes during testing of rotator cuff repair integrity.<sup>24-26</sup> Possible mechanisms underlying thermally mediated chondrolysis are under investigation.

## CLINICAL EVALUATION

Any history of direct trauma to the joint, whether fracture, dislocation, or previous operative intervention, should be explored in detail. In the case of the latter, operative reports and, if available, arthroscopic images, should be obtained and reviewed. Mechanical symptoms involving locking or catching of the shoulder, discomfort with changes in the weather, inability

to sleep comfortably on the affected side, and loss of motion can serve as nonspecific but sensitive indicators that the articular surface may be involved. Pain at extremes of motion may result from outlet impingement, whereas pain in mid-ranges associated with mechanical symptoms—especially below shoulder level—may be more indicative of articular cartilage injury.<sup>16</sup> One should keep in mind, however, that cartilage injury in the glenohumeral joint can present with physical findings traditionally suggestive of outlet impingement syndrome.<sup>16,17</sup>

During physical examination, particular attention should be paid to active and passive range of motion, scapulothoracic dyskinesia, and stability. In addition, Ellman and colleagues<sup>16</sup> have described the “compression-rotation” test to assist in discriminating between pain originating from subacromial impingement syndrome and that originating from glenohumeral cartilage lesions.<sup>16</sup> To perform the test, the patient is placed in the lateral recumbent position on the unaffected side and the examiner compresses the humeral head into the glenoid while the patient internally and externally rotates the arm. Provocation of pain with this maneuver is considered suggestive of chondral pathology. The test can be made more specific if Neer’s impingement test is conducted first, particularly if pain with forward flexion is eliminated with subacromial injection of local anesthetic and the compression-rotation test continues to elicit discomfort.

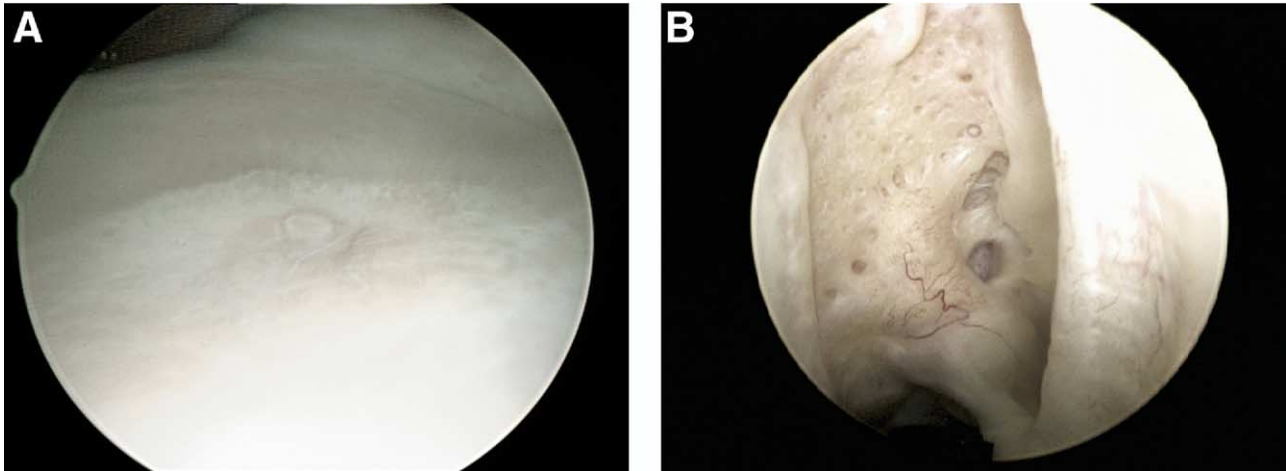
Radiographic examination should begin with true anteroposterior, scapular lateral, and axillary lateral views. In cases of shoulder instability, a West Point view can be helpful in evaluating the anteroinferior glenoid rim, and a Stryker notch view can provide excellent visualization of the posterosuperior humeral head, permitting detection of a Hill-Sachs lesion.<sup>11,27</sup> Computed tomography, and in particular 3-dimensional (3-D) reconstruction, can be useful for volumetric characterization of osteochondral lesions or post-traumatic osseous deformity.

Magnetic resonance imaging (MRI) is the modality of choice for visualizing cartilage defects in the glenohumeral joint. At present, MRI provides primarily morphologic information about the integrity of articular cartilage, but techniques providing physiologic information are on the horizon and promise increased sensitivity and specificity for diagnosing chondral pathology in the early stages.<sup>28</sup> In addition to superior delineation of cartilage defects, MRI holds the added benefit of allowing the clinician to identify other intra-articular pathology and to assess the status of the subchondral bone.

Several pulse imaging sequences have shown excellent sensitivity and specificity for Outerbridge grade II-IV type lesions: proton-density and T2-weighted fast spin-echo (FSE) sequences, fat-suppressed T1-weighted, 3-D spoiled gradient-echo (GRE) sequence, and the 3-D double-echo steady state sequence.<sup>4,29</sup> In the knee, the proton-density and T2-weighted FSE images allow identification of cartilage lesions with sensitivities ranging from 33% to 100%, and specificities ranging from 79% to 99%.<sup>29-31</sup> These pulse sequences provide differential signal intensity with respect to extant joint fluid and articular cartilage and yield an arthrogram-like effect.<sup>28,29,31</sup> An added benefit of proton-density and T2-weighted FSE pulse sequences is that other intra-articular structures can be readily evaluated. Such is not necessarily the case with other dedicated articular cartilage pulse sequences, such as fat-suppressed 3-D spoiled GRE. Imaging with a 1.5-Tesla magnet and a dedicated shoulder coil is sufficient for most clinical scenarios.<sup>28</sup> Finally, although direct MR arthrography increases the contrast between joint fluid and articular cartilage over that observed with traditional pulse sequences, it is unclear whether any advantage is provided in terms of sensitivity, specificity, or predictive value over current dedicated cartilage pulse sequences.<sup>28,30-33</sup> When examined specifically with reference to the glenohumeral joint, sensitivity and specificity for direct MR arthrogram detection of humeral and glenoid cartilage lesions have been reported as 76.5%/69% and 75%/64.5%, respectively.<sup>17</sup>

MRI also provides useful information about OCD lesions of the humeral head and glenoid. Lesion stability is one of the most important factors to define when evaluating OCD, and De Smet et al. reported 97% sensitivity and 100% specificity when using T2-weighted FSE pulse sequences to determine lesion stability.<sup>34</sup>

Even with the use of specialized cartilage sequences and arthrography, MRI has not yet achieved the same sensitivity or positive predictive value as direct visualization, and arthroscopic evaluation remains the gold standard for examination of the glenohumeral articular surface.<sup>30,31</sup> Unlike imaging studies, arthroscopic examination provides both direct visual and tactile data. Inspection should include visualization from both anterior and posterior portals because the sphericity of the humeral head precludes comprehensive inspection from a single viewpoint. The elbow of a standard arthroscopic probe can be used to palpate the defect and surrounding cartilage and delineate the margins of the defect, including transition zones that



**FIGURE 3.** (A) Arthroscopic image of normal, central “bare spot” of the glenoid. (B) Image of normal, posterolateral “bare area” of humeral head.

may not be obvious during routine visual inspection. A calibrated probe with laser marks at 3 to 5 mm intervals can be used to measure the dimensions of the defect.

There are several normal anatomic findings in the glenohumeral joint that can be confused with articular cartilage defects. The glenoid cartilage is thinnest at its center, and the appearance of this central area, or “bare spot,” can be mistaken for a cartilage defect (Fig 3A). The “bare area” of the humeral head is an area devoid of cartilage from the infraspinatus tendon to the articular margin and, like the glenoid bare spot, represents a normal anatomic finding (Fig 3B). The humeral bare area should not be confused with a Hill-Sachs lesion, which is located in a similar region of the humeral head, but is bound by articular cartilage on both the medial and lateral sides.

### NONOPERATIVE TREATMENT

Nonoperative treatment such as nutritional supplementation (e.g., chondroitin/glucosamine sulfate) nonsteroidal anti-inflammatory medications, physical therapy, and corticosteroid injections may be successful in palliating a patient’s symptoms, and represents the first line of treatment. The use of intra-articular viscosupplementation in the glenohumeral joint remains investigational.

Physical therapy can be successful in alleviating pain and increasing function, particularly in patients with minimal radiographic findings and whose pain is coupled with weakness and motion loss. Specific exercises should focus on scapulothoracic mobilization

and strengthening, as well as glenohumeral capsular stretching and rotator cuff strengthening. Furthermore, patients who complain of functional limitations not associated with pain can benefit greatly from occupational therapy in order to learn adaptive approaches to dressing, personal hygiene, and other basic activities.

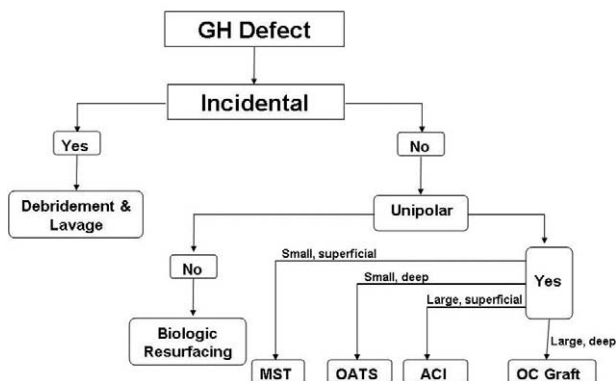
Intra-articular or subacromial injections of corticosteroid can serve both diagnostic and therapeutic purposes. Corticosteroid injections are particularly efficacious in low-demand patients with inflammatory arthropathies, and in these patients may represent an equally therapeutic and more cost-effective treatment option than physical therapy.<sup>35</sup> Patients with symptoms arising from osteoarthritis may also derive benefit from selective corticosteroid injection, but duration of symptomatic relief is unpredictable. However, in young, high-demand individuals with known chondral defects of the glenohumeral joint, serious consideration should be given to definitive, surgical treatment options rather than temporizing treatments such as local injection of corticosteroid.

### SURGICAL TREATMENT

The mere presence of a chondral lesion does not indicate the need for operative treatment. The patient’s complaints must be consistent with the nature and location of the lesion. The symptomatic lesion, identified by imaging studies or arthroscopic examination in a patient without concomitant pathology to explain the patient’s complaints, is the lesion that merits serious consideration for surgical treatment.

The nature of the lesion dictates the treatment strat-

### Emerging Algorithm



**FIGURE 4.** Flow diagram representing our current approach to treatment of glenohumeral cartilage lesions. “Incidental” refers to the case in which separate pathology is identified that explains fully the patient’s signs and symptoms. (GH, glenohumeral; MST, marrow-stimulation technique; OATS, osteochondral autologous transfer; ACI, autologous chondrocyte implantation; OC, osteochondral.)

egy. For example, in the experience of the authors, a large, uncontained defect may be best approached with a fresh osteochondral allograft, whereas a smaller, contained defect may be addressed using marrow stimulation techniques such as microfracture or autologous chondrocyte implantation (ACI). Deeper defects, involving loss of the subchondral plate may be best addressed with reconstitution of bone stock using osteochondral autograft or allograft transfer. Furthermore, the patient’s age and functional status must be factored into the treatment algorithm. For example, the low-demand patient with a focal, symptomatic lesion may respond well to arthroscopic lavage and debridement. We have developed a treatment algorithm that is likely to evolve over the next decade as long-term outcomes become available and permit more rigorous, evidence-based decision making (Fig 4).

The authors classify current nonarthroplasty options for the treatment of symptomatic cartilage lesions of the glenohumeral joint into 5 major categories: palliative, primary repair, reparative, restorative, or reconstructive. Palliative treatment aims to alleviate symptoms and typically involves arthroscopic lavage and debridement. Primary repair involves restoring a patient’s native cartilage to its premorbid condition, typically by fixation of a loose osteochondral fragment. Reparative strategies attempt to stimulate formation of fibrocartilage as reparative tissue to fill a defect, and specific techniques include abrasion chondroplasty, drilling, and microfracture. Restorative treatments re-

place the defect with hyaline or hyaline-like cartilage through osteochondral autograft or allograft transplantation or ACI. The use of massive allografts or biologic interpositional–prosthetic composites are reconstructive options that are typically reserved for bipolar cartilage lesions or unipolar lesions involving most of the articular surface.

### Palliative Treatment

The ideal candidate for these types of procedures is a low-demand individual with shoulder pain resulting from glenohumeral cartilage pathology and who is not a good candidate for total shoulder arthroplasty or who does not want to accept the limitations that accompany it. Other patients who may benefit from palliative treatment (including capsular release) are those with significant degenerative changes associated with capsular contracture.<sup>36</sup> Arthroscopic capsular release is performed as indicated using any of a variety of previously described techniques.<sup>37-39</sup>

Palliative treatment consists primarily of arthroscopic lavage and debridement and seeks to ameliorate symptoms by improving the intra-articular mechanical and biologic milieu.<sup>40</sup> Arthroscopic debridement involves removal of chondral flaps and loose bodies. Debridement down to stable cartilage can be accomplished with a combination of motorized shavers and arthroscopic curettes. In the case of grade IV lesions, the same combination can be used to create a stable, vertical transition zone between the defect and surrounding cartilage. The natural history of cartilage lesions as a function of the transition zone has been studied in a canine model, in which Rudd and colleagues<sup>41</sup> showed that experimentally generated cartilage lesions with beveled edges progressed in severity more rapidly than those with vertical edges.<sup>41</sup>

Symptomatic relief can often be achieved in these cases, but is typically incomplete and transient in nature.<sup>16,36,42</sup> Patients should be educated preoperatively so that expectations are realistic. Reports in the literature cite 80% good or excellent results from arthroscopic debridement over relatively short periods of follow-up.<sup>36,42,43</sup> Cameron et al. reported on a series of 61 patients with grade IV glenohumeral chondromalacia treated with arthroscopic debridement<sup>36</sup>; 36% also underwent arthroscopic capsular release and 48% underwent concomitant arthroscopic procedures other than capsular release. Eighty-eight percent experienced significant pain relief with an average duration of 28 months. Time to maximum pain relief was reported as 11 weeks.

Safran and Baillargeon presented a series of 18 patients with a mean age of 64 years with grade IV glenohumeral chondromalacia.<sup>43</sup> All patients underwent arthroscopic debridement and subacromial bursectomy without decompression or other concomitant procedures; 78% reported significant pain relief at an average follow-up of 24 months.

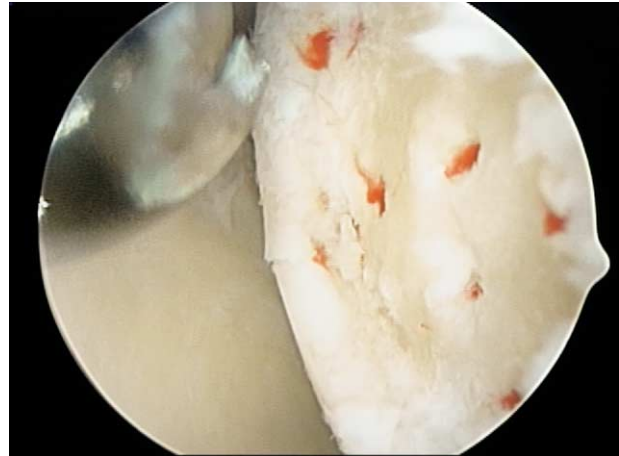
Weinstein et al. reported 78% good or excellent results in a cohort of 27 patients with a mean age of 47 years and with a mean follow-up of 30 months.<sup>42</sup> Patients underwent arthroscopic debridement and subacromial space bursectomy without decompression or other concomitant procedures. Within the group with unsatisfactory results, all patients experienced some degree of pain relief for a minimum of 8 months.

### Primary Repair

OCD of the glenohumeral joint appears only in isolated case reports in the literature, making it difficult to establish a shoulder-specific algorithm.<sup>19-23</sup> Principles applied to treatment of OCD in the knee, however, can be extrapolated to the shoulder, as the underlying pathophysiology is likely the same. Lesions that have been identified as being unstable by either MRI or arthroscopic examination, but that remain attached, should be fixed in situ with either a variable-pitch compression screw or small-diameter lag screw, in addition to being treated with a marrow-stimulation technique such as microfracture to provoke healing across the subchondral plate.<sup>44</sup> Lesions that are partially detached may require elevation, curettage, and autogenous bone grafting followed by fixation. Chronic OCD lesions in which the overlying osteochondral flap is completely detached may not be candidates for primary repair and may be best treated with removal of loose bodies and either a palliative, restorative, or reconstructive procedure depending on symptom severity and the size and depth of the lesion.

### Reparative Treatment

Reparative strategies seek to resurface a defect with fibrocartilage using 1 of several marrow-stimulation techniques: abrasion chondroplasty, drilling, or microfracture. Microfracture was popularized initially by Steadman et al.<sup>44</sup> to treat cartilage lesions in the knee and is the authors' preferred marrow-stimulation technique. Good results have been reported with the use of microfracture to address chondral injury in the knee, and the theoretical risk of thermal damage that can result from mechanical drilling is avoided.<sup>44</sup> For contained, focal, superficial defects in active patients,



**FIGURE 5.** Arthroscopic image of full-thickness chondral lesion of posterior aspect of humeral head after debridement and microfracture.

microfracture represents an appropriate first-line therapy, and does not compromise future restorative or reconstructive options. Osteochondral defects in which the subchondral plate has been violated and where there is bone in addition to cartilage loss are not ideal candidates for reparative techniques.

The operative technique of microfracture for treatment of glenohumeral cartilage lesions is the same as that described for treatment of lesions in the knee. Briefly, using a combination of motorized shavers and arthroscopic curettes, the lesion is debrided down to calcified cartilage, and vertical walls are established. Specially designed awls are then used to penetrate the subchondral plate at points 2 to 3 mm apart, creating exit points for marrow elements (Fig 5). The defect then captures escaping mesenchymal elements, permitting formation of a fibrin scaffold and gradual replacement by fibrocartilage.

The authors are unaware of any peer-reviewed, published reports of series of patients with glenohumeral cartilage defects treated exclusively with microfracture. Siebold and colleagues reported on a series of 5 patients treated with microfracture in combination with periosteal flap coverage.<sup>45</sup> All patients had grade IV cartilage lesions of the humeral head, and all experienced significant pain relief and increased functionality postoperatively, with a mean follow-up of 25 months.

### Restorative Treatment

Restorative treatment options restore a defect to near-normal status by either transfer of hyaline carti-

lage using osteochondral autograft or allograft plugs, or by growth of hyaline-like cartilage through ACI. These options entail significantly greater surgical morbidity than arthroscopic palliative or reparative modalities. At present, both osteochondral and chondrocyte transplantation require shoulder arthrotomy. Further, chondrocyte and autograft transplantation techniques demand separate surgical procedures at the knee with attendant morbidity and risk of complication. The ideal candidate for a restorative procedure, therefore, is a young, active individual with an isolated, focal cartilage defect of the humerus or glenoid who has failed nonoperative and reparative treatments.

Osteochondral *autograft* transfer has been used extensively for lesions within the knee and talus, and results have in general been excellent.<sup>46-48</sup> One advantage shared by both autograft and allograft transfer is the capacity to restore both osseous and chondral deficiencies. One distinct disadvantage of autologous transfer is donor-site morbidity. There are marked limitations in quantity of transferable tissue and the morbidity of the procedure increases with the amount of tissue harvested.

Scheibel et al. recently reported on a series of 8 such osteochondral autologous transfers for focal grade IV chondral lesions of the humeral head.<sup>49</sup> All defects were traumatic in origin. At a mean follow-up of 32.6 months, 6 patients were free of pain, and the 2 remaining patients reported a significant reduction in pain. Postoperative MRI revealed excellent graft incorporation and congruent articular surfaces in all but 1 patient. One patient suffered recurrent effusions in the donor knee and required 2 additional arthroscopic procedures for debridement.

Osteochondral *allograft* transfer follows a similar protocol, matching a donor plug to a recipient site, but without the limitations on transferable tissue imposed by donor-site morbidity. Consequently, allograft transfer can be used for cases of more extensive defects than can be treated effectively by autograft transfer. Grafts are side- and size-matched preoperatively, and fresh or prolonged-fresh grafts (maintained cold with regular medium change for no more than 28 days) are used exclusively. Pulsatile lavage of the graft is used to minimize the graft's immunogenic load. Fixation can be achieved either through press-fit, using specially designed instrumentation originally developed for fashioning allograft plugs for the knee (Arthrex, Naples, FL), or with the use of bioabsorbable pins or compression screws.

The published experience with the use of allografts

for cartilage lesions in the shoulder is limited to case reports.<sup>50-52</sup> Gerber and Lambert<sup>53</sup> reported on a series of 4 patients with chronic posterior dislocations and cartilage lesions involving more than 40% of the humeral head who were treated with osteochondral allografts. Cryopreserved femoral head allografts were used in 3 cases and a fresh autoclaved femoral head in 1 case. At an average follow-up of 68 months, 3 of the 4 patients had little or no pain, and the fourth patient developed pain 60 months after the reconstructive procedure secondary to osteonecrosis of the remaining native humeral head.

Yagishita and Thomas<sup>25</sup> reported the case of a 69-year old man with a chronic anterior dislocation of the humeral head and a large Hill-Sachs lesion measuring  $4 \times 2.5 \times 2$  cm, treated with a preserved frozen femoral head allograft.<sup>25</sup> At 2 years follow-up, the patient had no complaint of pain and had motion equivalent to that of the uninvolved shoulder.

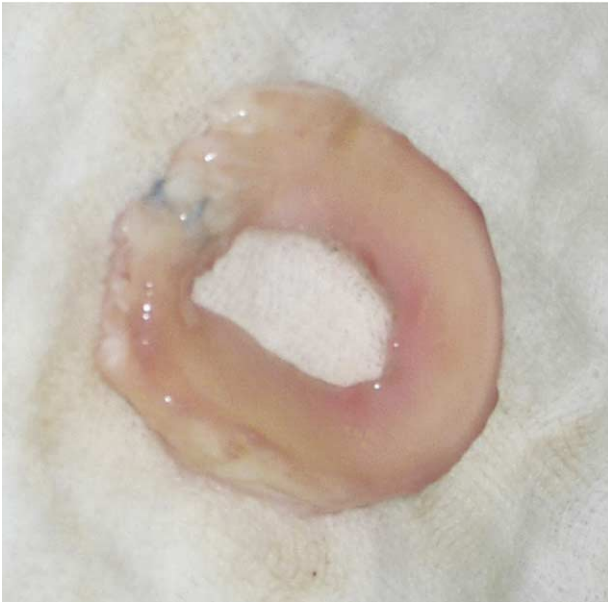Miniaci and Gish reported on a series of 18 patients with recurrent anterior instability and large Hill-Sachs lesions (>25% of the humeral head).<sup>54</sup> Side- and size-matched fresh-frozen osteoarticular humeral head allografts were used to fill the defects. With minimum 2-year follow-up, there were no episodes of recurrent instability and significant improvement was seen in the Western Ontario Shoulder Instability Index.

Use of ACI in the glenohumeral joint is considered to be investigational and experience is very limited in this application. The technique requires a minimum of 2 operations, but the harvest entails minimal donor-site morbidity. Although long-term results are still pending, short and midterm results for cartilage defects in the knee have been excellent.<sup>55,56</sup> With respect to the shoulder, Romeo et al.<sup>57</sup> recently published the report of a 16 year-old baseball player who developed a focal defect of the humeral head following arthroscopic capsulorrhaphy using a radiofrequency device. The standard ACI technique was used with harvest of the periosteal graft from the usual location on the proximal tibia. At the 1-year follow-up, the patient had full, painless range of motion.

## Reconstructive Treatment

Reconstructive treatment modalities provide either biologic, prosthetic, or combination coverage of either the humeral head, glenoid, or both, in an attempt to restore durable functionality to the glenohumeral joint. Furthermore, unlike the treatment strategies discussed thus far, reconstructive options often constitute the final attempt at joint salvage and, once performed,





**FIGURE 6.** A prepared lateral meniscal allograft. The anterior and posterior horns have been sutured together with a 2- to 3-mm overlap using 2 No. 2 nonabsorbable sutures.

often preclude further intervention short of total shoulder arthroplasty. Consequently, only young, active patients with extensive unipolar or bipolar disease and for whom the risk of glenoid loosening and difficulty of revision surgery are considered to be unacceptable are indicated for these procedures.

Specific solutions include focal prosthetic resurfacing (HemiCAP, Arthrosurface, Franklin, MA), massive humeral head allograft, soft-tissue interposition in the form of fascia lata autograft, allograft tendon (e.g., Achilles), porcine small intestine submucosa (DePuy Orthopaedics, Warsaw, IN), or lateral meniscal allografts.<sup>58</sup> Experience with these techniques is largely relegated to a few centers, published data regarding long-term outcomes is scarce, and one may therefore consider these solutions to be investigational in nature.

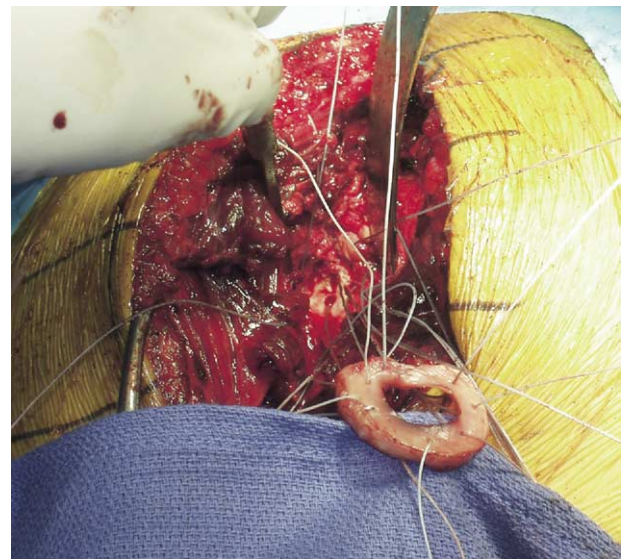
Clinical results following use of biologic interpositional-prosthetic composites are limited. In a small, uncontrolled study, Burkhead and Hutton<sup>58</sup> reported on 6 patients treated with humeral hemiarthroplasty and biologic resurfacing of the glenoid using either anterior capsule or autogenous fascia lata. All patients were young and active and the majority had glenohumeral arthritis that was post-traumatic in nature. With minimum 2-year follow-up, good or excellent results were reported in all patients using Neer's rating scale,

and all patients were able to return to premorbid activities, including firefighting and other heavy work.

Krishnan et al.<sup>59</sup> reported on the use of humeral hemiarthroplasty combined with biologic resurfacing of both the glenoid and acromion in a series of 14 low-demand patients with painful, end-stage rotator cuff tear arthropathy. An Achilles tendon allograft was used for resurfacing of the glenoid and acromion. At 2-year minimum follow-up, 92% of patients had good or excellent results using Neer's rating scale and had little or no pain postoperatively.

A biomechanical, cadaveric study has determined that the glenohumeral joint experiences significant reductions in contact forces with interposition of a lateral meniscal allografts (Creighton, Cole, et al., unpublished data). This should not be confused with a procedure analogous to labral replacement, but rather a soft-tissue implant designed to create a more hospitable environment and reduce glenohumeral contact forces. Patient candidates must understand that these procedures seek to restore functionality and decrease pain, but do not result in a normal joint.

At our institution, 25 patients have been treated with the use of a biologic interpositional-prosthetic composite consisting of standard uncemented humeral hemiarthroplasty in combination with lateral meniscal allografts resurfacing of the glenoid. All patients treated have been active, high-demand individuals with bipolar glenohumeral disease (Figs 6 and 7). In 1 case, a massive humeral head allograft rather than



**FIGURE 7.** Sutures placed circumferentially around the lateral meniscal allograft to permit secure fixation to the glenoid.

conventional humeral hemiarthroplasty was used in combination with a lateral meniscal allograft to the glenoid. With limited follow-up, most patients have enjoyed dramatic pain relief with significant restoration of functionality. Two failures have occurred, 1 was after 4 months caused by trauma, and the other at 10 months after reconstruction resulting from inadequate pain relief.

Despite the conceptual attractiveness of a biologic resurfacing solution to the chondrolytic or osteoarthritic shoulder in young, high-demand individuals, it must be stressed that these procedures will remain investigational until further study can evaluate their effectiveness. They should be considered as salvage procedures in an individual for whom traditional total shoulder arthroplasty is not a feasible option.

### POSTOPERATIVE REHABILITATION

Postoperative rehabilitation can play an important role in the success of these procedures. Patients who have undergone isolated arthroscopic debridement typically follow a simple rehabilitation protocol with general strengthening and range-of-motion exercises in a supervised setting. If a capsular release is performed in conjunction with arthroscopic debridement, the rehabilitation protocol becomes more specific, and patients receive daily, supervised outpatient physical therapy for 2 weeks, followed by 6 to 8 weeks of therapy at a frequency of 3 times weekly.

In cases of microfracture, osteochondral transplantation, or ACI, patients perform at least 600 cycles of pendulum exercises daily, starting on the first postoperative day and continuing for 6 weeks. With respect to microfracture, a recent primate study found that fibrocartilage does not reach a significant degree of maturity until 12 weeks postoperatively, and future rehabilitation protocols may therefore require longer periods of protected motion.<sup>60</sup> Nevertheless, our current rehabilitation protocol for microfracture and other cartilage procedures incorporates active range-of-motion exercises starting at 6 weeks. For procedures that required transection and repair of the subscapularis tendon, we avoid resisted internal rotation and external rotation beyond the range determined to be safe intraoperatively for 12 weeks. Depending on their progression through rehabilitation, most patients are cleared for unrestricted activity at 6 months. However, patients who undergo ACI may require up to 12 months of recovery before being cleared for return to high-level activities. Education on the extended nature of rehabilitation and recovery involved in cartilage

procedures should be provided preoperatively to establish realistic patient expectations with respect to return to activity.

### CONCLUSIONS

Successful treatment of glenohumeral cartilage injury entails a number of challenges. Identification of a chondral lesion as the source of a patient's complaints may be difficult. A detailed history and physical examination are necessary, but often not sufficient for this purpose, and imaging modalities such as MRI with specialized pulse sequences are typically required.<sup>61</sup> Arthroscopy remains the gold standard for evaluating lesion dimensions. Treatment of chondral lesions in the glenohumeral joint depends on multiple patient-based and pathology-based factors, including patient age, expectations, and activity level, as well as lesion area, depth, and location within the joint. Select low-demand individuals may respond well to nonoperative or palliative operative modalities, but high-demand patients require more sophisticated surgical strategies that address cartilage injury using reparative, restorative, or reconstructive techniques. One must also recognize that use of many of these techniques awaits substantiation by well-designed outcomes studies. Both the basic science and practical applications of cartilage repair technology will remain areas where intense research efforts are focused. Treatment recommendations will likely evolve as more evidence regarding the clinical efficacy of these procedures becomes available.

### REFERENCES

1. Matsen FA III, Rockwood CA, Wirth MA, Lippitt SB, Parsons M. Glenohumeral arthritis and its management. In: Rockwood CA, Matsen FA III, Wirth MA, Lippitt SB, eds. *The shoulder*. Philadelphia: WB Saunders, 2003;879-1007.
2. Jain N, Pietrobon R, Hocker S, Guller U, Shankar A, Higgins LD. The relationship between surgeon and hospital volume and outcomes for shoulder arthroplasty. *J Bone Joint Surg Am* 2004;86:496-505.
3. Sperling JW, Antuna SA, Sanchez-Sotelo J, Schleck C, Cofield RH. Shoulder arthroplasty for arthritis after instability surgery. *J Bone Joint Surg Am* 2002;84:1775-1781.
4. Outerbridge RE, Dunlop JA. The problem of chondromalacia patellae. *Clin Orthop* 1975;110:177-196.
5. Iannotti JP, Naranja RJ, Warner JJ. Surgical management of shoulder arthritis in the young and active patient. In: Warner JJ, Iannotti JP, Gerber C, eds. *Complex and revision problems in shoulder surgery*. Philadelphia: Lippincott-Raven, 1997; 289-302.
6. Buscayret F, Edwards TB, Szabo I, Adeleine P, Coudane H, Walch G. Glenohumeral arthrosis in anterior instability before and after surgical treatment: Incidence and contributing factors. *Am J Sports Med* 2004;32:1165-1172.

7. Calandra JJ, Baker CL, Uribe J. The incidence of Hill-Sachs lesions in initial anterior shoulder dislocations. *Arthroscopy* 1989;5:254-257.
8. Cameron ML, Kocher MS, Briggs KK, Horan MP, Hawkins RJ. The prevalence of glenohumeral osteoarthritis in unstable shoulders. *Am J Sports Med* 2003;31:53-55.
9. Hintermann B, Gächter A. Arthroscopic findings after shoulder dislocation. *Am J Sports Med* 1995;23:545-551.
10. Norlin R. Intra-articular pathology in acute, first-time anterior shoulder dislocation: An arthroscopic study. *Arthroscopy* 1993;9:546-549.
11. Hill HA, Sachs MD. The grooved defect of the humeral head. A frequently unrecognized complication of dislocations of the shoulder joint. *Radiology* 1940;35:690-700.
12. Taylor DC, Arciero RA. Pathologic changes associated with shoulder dislocations. Arthroscopic and physical examination findings in first-time, traumatic anterior dislocations. *Am J Sports Med* 1997;25:306-311.
13. Hovelius L, Augustini BG, Fredin H, Johansson O, Norlin R, Thorling J. Primary anterior dislocation of the shoulder in young patients. A ten-year prospective study. *J Bone Joint Surg Am* 1996;78:1677-1684.
14. Gartsman GM, Taverna E. The incidence of glenohumeral joint abnormalities associated with full-thickness, reparable rotator cuff tears. *Arthroscopy* 1997;13:450-455.
15. Paley KJ, Jobe FW, Pink MM, Kvitne RS, ElAttrache NS. Arthroscopic findings in the overhand throwing athlete: Evidence for posterior internal impingement of the rotator cuff. *Arthroscopy* 2000;16:35-40.
16. Ellman H, Harris E, Kay SP. Early degenerative joint disease simulating impingement syndrome: Arthroscopic findings. *Arthroscopy* 1992;8:482-487.
17. Guntern DV, Pfirrmann CW, Schmid MR, et al. Articular cartilage lesions of the glenohumeral joint: Diagnostic effectiveness of MR arthrography and prevalence in patients with subacromial impingement syndrome. *Radiology* 2003;226:165-170.
18. Schenck RC Jr., Goodnight JM. Osteochondritis dissecans. *J Bone Joint Surg Am* 1996;78:439-456.
19. Anderson WJ, Guilford WB. Osteochondritis dissecans of the humeral head. An unusual cause of shoulder pain. *Clin Orthop* 1983;173:166-168.
20. Ganter M, Reichelt A. [Osteochondrosis dissecans of the humeral head]. *Z Orthop Ihre Grenzgeb* 1996;134:73-75.
21. Hamada S, Hamada M, Nishiue S, Doi T. Osteochondritis dissecans of the humeral head. *Arthroscopy* 1992;8:132-137.
22. Ishikawa H, Ueba Y, Yonezawa T, Kurosaka M, Ohno O, Hirohata K. Osteochondritis dissecans of the shoulder in a tennis player. *Am J Sports Med* 1988;16:547-550.
23. Shanley DJ, Mulligan ME. Osteochondrosis dissecans of the glenoid. *Skeletal Radiol* 1990;19:419-421.
24. Nakagawa Y, Ueo T, Miki T, Kotani H, Onishi E, Nakamura T. Glenohumeral osteoarthritis following a "color test" during rotator cuff repair. A case report and a review of the literature. *Bull Hosp Jt Dis* 1998;57:216-218.
25. Yagishita K, Thomas BJ. Use of allograft for large Hill-Sachs lesion associated with anterior glenohumeral dislocation. A case report. *Injury* 2002;33:791-794.
26. Petty DH, Jazrawi LM, Estrada LS, Andrews JR. Glenohumeral chondrolysis after shoulder arthroscopy: Case reports and review of the literature. *Am J Sports Med* 2004;32:509-515.
27. Rokous JR, Feagin JA, Abbott HG. Modified axillary roentgenogram. A useful adjunct in the diagnosis of recurrent instability of the shoulder. *Clin Orthop* 1972;82:84-86.
28. Gold GE, Reeder SB, Beaulieu CF. Advanced MR imaging of the shoulder: Dedicated cartilage techniques. *Magn Reson Imaging Clin North Am* 2004;12:143-159, vii.
29. Verstraete KL, Almqvist F, Verdonk P, et al. Magnetic resonance imaging of cartilage and cartilage repair. *Clin Radiol* 2004;59:674-689.
30. Friemert B, Oberlander Y, Schwarz W, et al. Diagnosis of chondral lesions of the knee joint: Can MRI replace arthroscopy? A prospective study. *Knee Surg Sports Traumatol Arthrosc* 2004;12:58-64.
31. Yoshioka H, Stevens K, Hargreaves BA, et al. Magnetic resonance imaging of articular cartilage of the knee: Comparison between fat-suppressed three-dimensional SPGR imaging, fat-suppressed FSE imaging, and fat-suppressed three-dimensional DEFT imaging, and correlation with arthroscopy. *J Magn Reson Imaging* 2004;20:857-864.
32. Carroll KW, Helms CA, Speer KP. Focal articular cartilage lesions of the superior humeral head: MR imaging findings in seven patients. *AJR Am J Roentgenol* 2001;176:393-397.
33. Rand T, Brossmann J, Pedowitz R, Ahn JM, Haghighi P, Resnick D. Analysis of patellar cartilage. Comparison of conventional MR imaging and MR and CT arthrography in cadavers. *Acta Radiol* 2000;41:492-497.
34. De Smet AA, Ilahi OA, Graf BK. Reassessment of the MR criteria for stability of osteochondritis dissecans in the knee and ankle. *Skeletal Radiol* 1996;25:159-163.
35. Dacre JE, Beeney N, Scott DL. Injections and physiotherapy for the painful stiff shoulder. *Ann Rheum Dis* 1989;48:322-325.
36. Cameron BD, Galatz LM, Ramsey ML, Williams GR, Iannotti JP. Non-prosthetic management of grade IV osteochondral lesions of the glenohumeral joint. *J Shoulder Elbow Surg* 2002;11:25-32.
37. Nicholson GP. Arthroscopic capsular release for stiff shoulders: Effect of etiology on outcomes. *Arthroscopy* 2003;19:40-49.
38. Warner JJ, Allen A, Marks PH, Wong P. Arthroscopic release for chronic, refractory adhesive capsulitis of the shoulder. *J Bone Joint Surg Am* 1996;78:1808-1816.
39. Warner JJ, Allen AA, Marks PH, Wong P. Arthroscopic release of postoperative capsular contracture of the shoulder. *J Bone Joint Surg Am* 1997;79:1151-1158.
40. Hsieh YS, Yang SF, Chu SC, et al. Expression changes of gelatinases in human osteoarthritic knees and arthroscopic debridement. *Arthroscopy* 2004;20:482-488.
41. Rudd RG, Visco DM, Kincaid SA, Cantwell HD. The effects of beveling the margins of articular cartilage defects in immature dogs. *Vet Surg* 1987;16:378-383.
42. Weinstein DM, Bucchieri JS, Pollock RG, Flatow EL, Bigliani LU. Arthroscopic debridement of the shoulder for osteoarthritis. *Arthroscopy* 2000;16:471-476.
43. Safran MR, Baillargeon D. The role of arthroscopy in the treatment of glenohumeral arthritis. Podium presentation. 2004;12:2139-145.
44. Steadman JR, Rodkey WG, Rodrigo JJ. Microfracture: Surgical technique and rehabilitation to treat chondral defects. *Clin Orthop* 2001;391:S362-S369 (suppl).
45. Siebold R, Lichtenberg S, Habermeyer P. Combination of microfracture and periosteal-flap for the treatment of focal full thickness articular cartilage lesions of the shoulder: A prospective study. *Knee Surg Sports Traumatol Arthrosc* 2003;11:183-189.
46. Gautier E, Kolker D, Jakob RP. Treatment of cartilage defects of the talus by autologous osteochondral grafts. *J Bone Joint Surg Br* 2002;84:237-244.
47. Hangody L, Feczko P, Bartha L, Bodo G, Kish G. Mosaicplasty for the treatment of articular defects of the knee and ankle. *Clin Orthop* 2001;391:S328-S336 (suppl).
48. Hangody L, Kish G, Modis L, et al. Mosaicplasty for the treatment of osteochondritis dissecans of the talus: Two to seven year results in 36 patients. *Foot Ankle Int* 2001;22:552-558.
49. Scheibel M, Bartl C, Magosch P, Lichtenberg S, Habermeyer

- P. Osteochondral autologous transplantation for the treatment of full-thickness articular cartilage defects of the shoulder. *J Bone Joint Surg Br* 2004;86:991-997.
50. Bugbee WD, Convery FR. Osteochondral allograft transplantation. *Clin Sports Med* 1999;18:67-75.
51. Convery FR, Meyers MH, Akeson WH. Fresh osteochondral allografting of the femoral condyle. *Clin Orthop* 1991;273:139-145.
52. Garrett JC. Fresh osteochondral allografts for treatment of articular defects in osteochondritis dissecans of the lateral femoral condyle in adults. *Clin Orthop* 1994;303:33-37.
53. Gerber C, Lambert SM. Allograft reconstruction of segmental defects of the humeral head for the treatment of chronic locked posterior dislocation of the shoulder. *J Bone Joint Surg Am* 1996;78:376-382.
54. Miniaci A, Gish MW. Management of anterior glenohumeral instability associated with large Hill-Sachs defects. *Tech Shoulder Elbow Surg* 2004;5:170-175.
55. Peterson L, Minas T, Brittberg M, Lindahl A. Treatment of osteochondritis dissecans of the knee with autologous chondrocyte transplantation: Results at two to ten years. *J Bone Joint Surg Am* 2003;85:17-24 (suppl 2).
56. Peterson L, Minas T, Brittberg M, Nilsson A, Sjogren-Jansson E, Lindahl A. Two- to 9-year outcome after autologous chondrocyte transplantation of the knee. *Clin Orthop* 2000;374:212-234.
57. Romeo AA, Cole BJ, Mazzocca AD, Fox JA, Freeman KB, Joy E. Autologous chondrocyte repair of an articular defect in the humeral head. *Arthroscopy* 2002;18:925-929.
58. Burkhead WZ Jr, Hutton KS. Biologic resurfacing of the glenoid with hemiarthroplasty of the shoulder. *J Shoulder Elbow Surg* 1995;4:263-270.
59. Krishnan SG, Burkhead WZ Jr., Nowinski RJ. Humeral hemiarthroplasty with biologic resurfacing of the glenoid and acromion for rotator cuff tear arthropathy. *Tech Shoulder Elbow Surg* 2004;5:51-59.
60. Gill TJ, McCulloch PC, Glasson SS, Blanchet T, Morris EA. Chondral defect repair after the microfracture procedure: A nonhuman primate model. *Am J Sports Med* 2005;33:680-685.
61. Yulish BS, Montanez J, Goodfellow DB, Bryan PJ, Mulopulos GP, Modic MT. Chondromalacia patellae: Assessment with MR imaging. *Radiology* 1987;164:763-766.