
POSTERIOR CRUCIATE LIGAMENT INJURIES

Although more common than once believed, injuries to the PCL account for between 3 and 20% of all knee ligament injuries. It is estimated that 40% of all PCL injuries are isolated tears. The true incidence is probably much greater than this because many isolated tears remain undetected. Most injuries occur in young males involved in motor vehicle-related accidents ("dashboard injury") and contact sports.

Basic Science

Biomechanics

Kinematics

The PCL is the primary restraint (95%) to posterior tibial translation at 90 degrees of flexion. The PCL and ACL regulate the screw-home mechanism of external tibial rotation in terminal extension. The PCL also acts as a secondary restraint to ER of the tibia in combined posterolateral complex (PLC)

injuries and to varus/valgus stability. The menisofemoral ligaments provide a secondary restraint to posterior tibial translation by tightening with IR and flexion of the tibia. Other secondary restraints to posterior translation include the posterior medial and lateral capsules, the PLC, the MCL and LCL, and central portion of the medial capsule. A significant increase in medial compartment and PF contact pressures occurs after sectioning of the PCL. This has important implications for the development of arthritis in chronic PCL deficiency as well as for rehabilitation of the PCL-injured knee.

Strength and Load

The PCL is not twice as strong as the ACL, as commonly quoted. The anterolateral band (ALB) is about as strong as the entire ACL. The ALB is about twice as strong (about 1200 N versus 450 N) and stiff as the posteomedial band (PMB) and menisofemoral ligaments.

PEARL

Restoration of the anterolateral band (ALB) and accurate placement of the femoral origin are anatomically and biomechanically the most important consideration in reestablishing normal kinematics in the PCL-deficient knee.

Anatomy

Embryology

The cruciate ligaments are first recognized at 7 to 8 weeks gestation as a condensation of vascular synovial mesenchyme. At about 22 weeks gestation, the PCL resembles an adult ligament.

Histology

Like the ACL, the PCL is considered an intracapsular but extrasynovial structure. The histology is as described in Anterior Cruciate Ligament Injuries.

Functional Anatomy

Fascicles of the PCL are divided into two functional (not microscopic) groups

1. anterolateral band: larger, tightens in flexion
1. posteromedial band: smaller, tightens in extension

Additionally, there are two variably present (70 to 100%) menisofemoral ligaments: the anterior (ligament of Humphrey) and posterior (ligament of Wrisberg) (Fig. 35-11).

Surgical Anatomy

The PCL is located near the central axis of the knee, being more vertical in extension and horizontal in flexion. The cross-sectional area of the PCL decreases from proximal to distal, averaging 11 mm in width at its midsection.

Origin

The origin of the PCL is in an anteromedial direction off of the anterolateral medial femoral condyle as a semicircle averaging 32 mm in width.

Insertion

The PCL inserts in a lateromedial direction onto the intra-articular upper surface at the tibial fovea (approximately 1 cm below the tibial surface) as a rectangle averaging 13 mm in width (Fig. 35-11).

The menisofemoral ligaments take origin from the posterior horn of the lateral meniscus and "sandwich" the PCL as they insert onto the anterior and posterior aspects of the posterior PCL near its femoral insertion.

Vascular supply

As in the ACL, the vascular supply of the PCL is primarily from the middle geniculate artery.

Innervation

Innervation is primarily from the posterior articular branches of the tibial nerve. Similar mechanoreceptors as in the ACL have been identified, concentrated at the femoral origin for proprioceptive function.

Examination

The diagnosis is often missed at initial examination unless gross instability is present. Attention to the history and physical examination is paramount to determine the nature and extent of the often complex injury patterns associated with PCL tears.

History

Mechanism

Isolated PCL tears are most commonly caused by:

1. direct trauma to the proximal tibia with the foot plantar flexed ("dashboard injury")
2. downward-directed force to the thigh with the knee in hyperflexion (landing from a jump)

Severe hyperextension injuries are often associated with PCL and posterior capsule injury after the ACL is torn. Posterior cruciate-PLC injuries occur with ER, and a posteromedial varus-directed force causing varus and ER knee instability. Isolated varus or valgus stress can injure the PCL after the respective collateral ligament tears.

Symptoms

Acutely, patients with an isolated sport-related PCL tear may consider it as a minor event and return to play. A mild to moderate effusion or hemarthrosis may develop, but this is less common and severe as after ACL tears. Complaints of instability occur during rapid directional change, as well as with less demanding activities in patients with combined injuries. Pain tends to worsen over time, commonly localizing to the PF area or medial compartment. In chronic PCL-deficiency, up to 70% of patients complain of pain associated with ambulation and 50% with descending stairs.

Physical Examination

Inspection

Observe for mild effusion, anterior tibial contusion, or popliteal ecchymoses. The presence of a varus-thrust gait with or without hyperextension should call attention to the PLC.

Palpation

Tenderness may exist in areas of direct trauma.

Motion

Forceful passive ROM beyond 90 degrees may produce pain.

Special Tests (Figure 35-1)

Posterior Drawer Test

The most sensitive test for PCL insufficiency (Fig. 35-20). The test should be performed with the hip and knee flexed to 45 and 90 degrees, respectively, and the foot in neutral or ER to reduce the secondary restraining effects of the meniscofemoral ligaments and PLC. Grading is identical to the Lachman test described above in Anterior Cruciate Ligament Injuries. Grade II (+ 5 to 10 mm) instability exists when the tibial condyle is flush with the femoral condyle, and it often represents an isolated injury amenable to nonoperative treatment. Grade III instability exists when the tibia is displaced more than 10 mm posteriorly and often represents a combined injury requiring operative treatment. The endpoint (i.e., A = solid and B = soft) may return to normal in the chronically PCL-deficient knee.

PEARL

The medial tibial plateau should be at least 10 mm anterior to the medial femoral condyle when the knee is flexed to 90 degrees in a normal knee. The injured knee should always be compared with the normal knee.

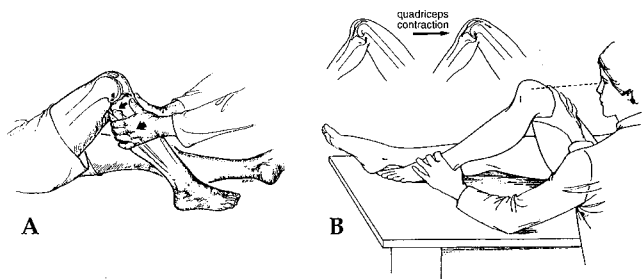


Figure 35-20 Special tests for posterior cruciate ligament (PCL) tears. (A) The posterior drawer test is the most sensitive test used to diagnose a PCL tear. Reproduced with permission from Tria AJ, Klein KS. *An Illustrated Guide to the Knee*. New York, NY: Churchill Livingstone; 1992; (B) The quadriceps active test. As viewed from the side, as the quadriceps contracts, the posterior sag is reduced. Reproduced with permission from Andrews JR, Edwards JC, Satterwhite YE. Isolated posterior cruciate ligament injuries. *Clin Sports Med*. 1994; 13:525, 53.

Posterior Sag Sign

The hips and knees are flexed to 90 degrees while the examiner grasps and lifts the heels of the supine patient. The position of the tibia is compared as viewed from the side. Gravity causes the PCL-deficient knee to rest in the posteriorly subluxated position. This test is more sensitive in chronic injuries.

Quadriceps Active Test

The affected hip and knee are flexed to 90 degrees, and the foot is stabilized in neutral on the table (Fig. 35-20b). Voluntary quadriceps contraction reduces the posteriorly subluxated tibia anteriorly. An active posterior drawer test is performed with voluntary HS contraction from this position.

Lachman Test

A Lachman test will show anterior translation to the level of the normal side with a firm endpoint, and examiners often confuse this finding with ACL-deficiency.

Reverse Pivot Shift Test

Beginning at 90 degrees, the knee is held in ER and passively extended, whereby a shift occurs at 20 to 30 degrees of flexion as the posteriorly subluxated lateral tibial plateau reduces anteriorly. This test has low specificity and can be falsely positive in the normal knee under anesthesia or with generalized ligament laxity. False negatives can occur with biceps femoris spasm.

Collateral Evaluation

Varus laxity at 30 degrees of flexion indicates LCL and possibly PLC injury. Slight opening at 0 degrees may indicate this combined injury, whereas severe opening may indicate additional PCL and, possibly, ACL injury. Increased valgus opening at 30 degrees flexion indicates MCL injury.

Posterolateral Complex Evaluation

Subtle changes in rotation during examination may be found by performing the following maneuvers:

Increased posterior translation, ER, and varus angulation at 30 degrees of knee flexion that decreases at 90 degrees indicates isolated PLC injury. Should these findings increase at 90 degrees, then a combined PCL-PLC injury should be suspected.

Prone passive ER test: Forceful increases in ER beyond 10 degrees (compared with the noninjured knee) of the medial border of the foot in the prone patient at 30 and 90 degrees of knee flexion is interpreted as above.

Posterolateral drawer test: Increased ER of the lateral tibial plateau when performing the posterolateral drawer test in 15 degrees of ER is a less specific test for combined PCL-PLC injury.

ER recurvatum test: This is performed by grasping the great toes of the supine patient with the knee in extension. If the knee falls into varus, hyperextension, and ER, it may indicate isolated PLC injury. Excessive varus and hyperextension may indicate ACL and, possibly, PCL injury.

Instrumented laxity testing: The KT-1000/2000 (Med-metric; San Diego, CA) is not accurate (70% confidence) for the

PCL and has less than 33% sensitivity for a grade I PCL tear and 86% sensitivity for grades II to III tears.

PITFALL

Missing a combined PCL-PLC injury will have a deleterious effect on the outcome of the PCL reconstructed knee.

Aids to Diagnosis

Radiographic Evaluation

Complete radiographic evaluation is discussed in Anterior Knee Pain and Patellofemoral Disorders. Specific findings associated with PCL tears are emphasized in this section. An AP, lateral, axial, and 45 degree PA flexion weight-bearing radiograph should be obtained.

Standard Anteroposterior View

Obtain this study for evidence of avulsion fractures of the PCL, as these should be fixed acutely even if minimally displaced. Check for avulsion fractures of the fibular head (LCL, biceps femoris) and of Gerdy's tubercle (ITB). Chronic injuries need to be evaluated for arthrosis, especially in the PF and medial compartments.

Forty-five Degree Posterolateral View

This view is helpful in identifying subtle joint space narrowing.

Patellar Views (Axial Views)

A Merchant's view is helpful to identify PF arthrosis.

Long Cassette Lower-extremity View

Rule out varus alignment requiring valgus high-tibial osteotomy (HTO) prior to considering PCL reconstruction.

Magnetic Resonance Imaging

Magnetic resonance scanning is both sensitive and specific (100%) in the diagnosis of acute complete tears and somewhat less reliable in identifying partial PCL tears (Figs. 35-21 and 35-22). Meniscal tears (less common than with ACL tears), chondral injury, and PLC injuries are evaluated. Operative treatment of associated pathology (i.e., meniscus, cartilage) can be planned despite nonoperative PCL treatment.

Bone Scan (Technetium Scintigraphy)

Bone scans will show increased activity due to early arthritis, especially in medial and PF compartments in the chronically PCL-deficient knee.

Specific Conditions, Treatment, and Outcome

The goal of treatment in PCL injuries is to relieve symptoms and prevent the development of degenerative arthritis. Treatment options depend on the findings at physical examination, the site of the tear, the presence of associated ligamentous injuries, and the patient's activity level. Most surgeons

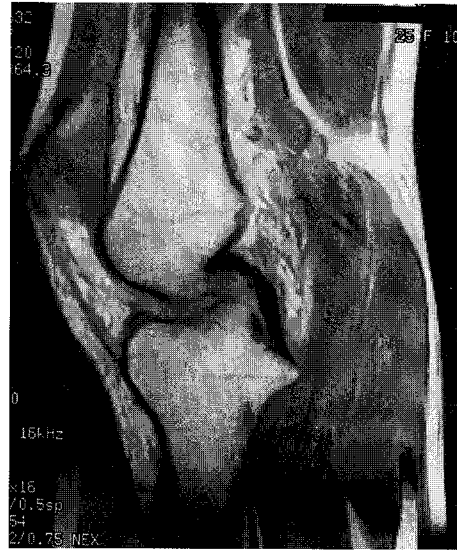

Figure 35-21 Magnetic resonance imaging scan demonstrating a normal PCL.

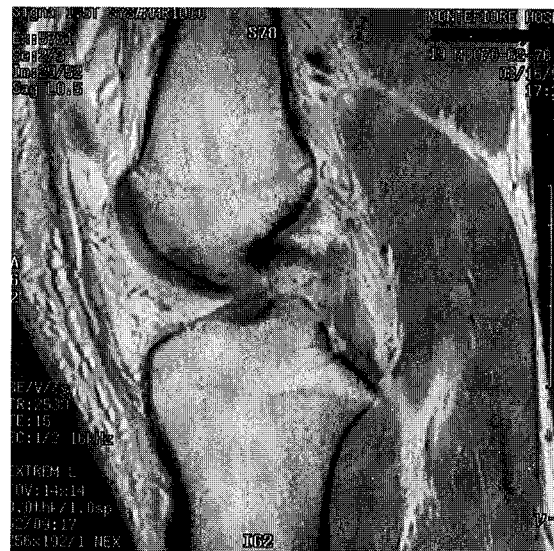


Figure 35-22 Magnetic resonance imaging scan demonstrating a complete tear of the PCL.

agree that nonoperative treatment is appropriate for acute, isolated PCL injuries. Typically, these are patients who present with less than grade III laxity without associated injuries. An algorithm for the treatment of acute PCL injuries other than those associated with avulsion fractures is presented in Fig. 35-23.

Nonoperative Treatment

The natural history of acute and chronic PCL injuries is still a matter of debate. Additionally, the long-term results of PCL reconstruction have not been adequately studied. It is generally accepted that isolated PCL injuries will do relatively well and combined injuries will do poorly when treated nonoperatively. Injuries occurring during athletics tend to do

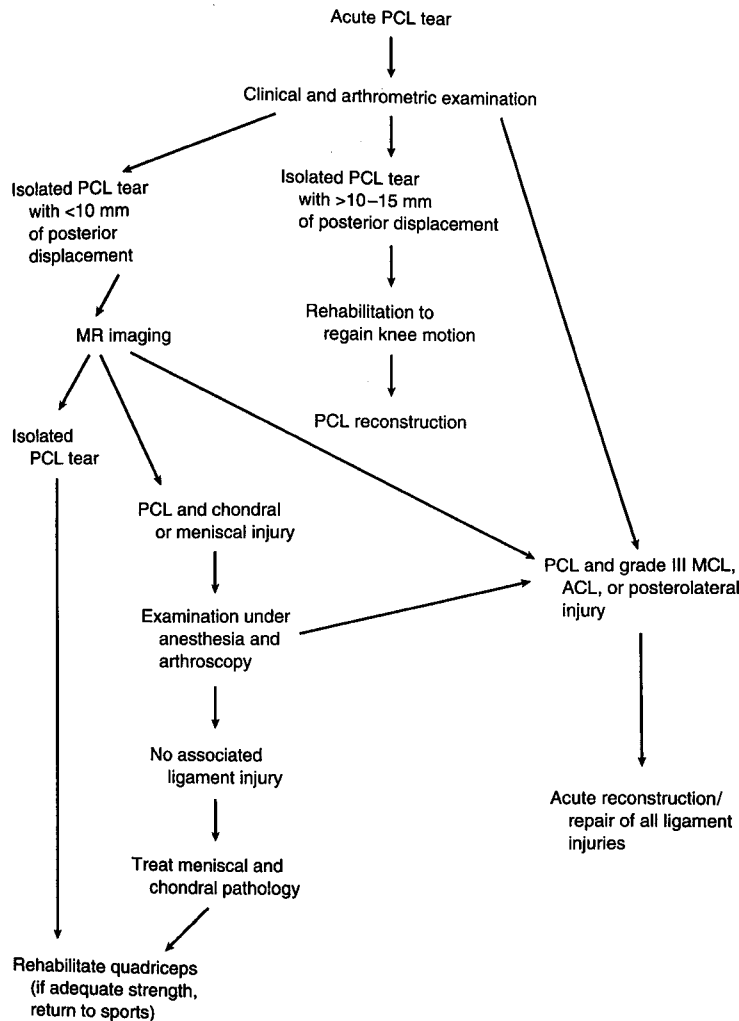


Figure 35-23 Treatment algorithm for suggested management of acute PCL tears. Copyright © 1993 American Academy of Orthopaedic Surgeons. Reproduced with permission from the *Journal of the American Academy of Orthopaedic Surgeons: A Comprehensive Review* 1993;1:72.

much better than those resulting from motor vehicle accidents or falls. Compensatory quadriceps contraction may help patients adapt to PCL-deficiency. It appears that less than 10% of patients with isolated PCL tears will progress to post-traumatic arthritis. The development of pain and degenerative arthritis is more common in patients with combined PCL injuries.

A few long-term studies suggest that the natural history of isolated PCL tears includes three phases:

1. functional adaptation (3 to 18 months)
2. functional tolerance (15 to 20 years)
3. progressive disabling arthritis after 25 years

The rate or extent of this progression depends on several factors including degree of instability, rotatory laxity, meniscectomy, quadriceps muscle weakness, and PF problems.

Nonoperative treatment for isolated PCL tears with less than 10 mm of posterior displacement is not the same as non-treatment. Acutely, isolated PCL injuries should be managed with splinting in extension until motion is tolerated, progressive weight-bearing, and cold therapy with compression. Rehabilitation emphasizes closed-chain strengthening (minisquats, leg presses) until 90% of the quadriceps and HS strength on the normal side is achieved. The patient can

return to athletic activity usually within 3 to 4 weeks. Yearly followup for the development of pain or disability from instability or arthritis should be performed.

Operative Treatment

Surgical reconstruction is generally reserved for:

1. acute bony avulsions
2. symptomatic, chronic PCL-deficiency
3. acute or chronic combined ligament injuries and
4. isolated PCL tears in active young patients with less than 10 mm laxity on posterior displacement testing who complain of instability or pain

Reconstruction in patients with moderate to severe osteoarthritis is not recommended. In the chronic, PCL-deficient patient, evaluation for a varus thrust and chronic PLC deficiency must be undertaken. If the patient does not have a varus thrust, then PCL-PLC reconstruction can be performed (see below). If a patient has a varus thrust, a valgus HTO is indicated with PCL-PLC reconstruction after a 3 to 6 month recovery period. Acute combined PCL-MCL-ACL or PCL-MCL injuries may need all components reconstructed in contrast to ACL-MCL injuries where usually only the ACL is

reconstructed. Combined chronic PCL-MCL insufficiency may require an advancement procedure if laxity persists after PCL reconstruction.

Bony Avulsions

Radiographs document the presence and size of the avulsion fracture. Approached posteriorly, large fragments are secured with screws. Some recommend nonoperative treatment for small avulsions when the posterolateral drawer test is less than 10 mm. If operative treatment is necessary, small fragments are repaired using sutures through drill holes. Primary repair of interstitial PCL tears has been unsuccessful.

Intra-articular Reconstruction of Isolated PCL Injuries

After the decision to reconstruct the PCL has been made, graft selection must be determined. Autograft BPTB or HS and allograft BPTB or Achilles tendon are currently used in PCL reconstruction. The advantages and disadvantages are similar to those listed for ACL reconstruction (see Table 35-1). It is the authors' preference to use fresh-frozen Achilles' tendon allograft because it is technically easier to pass through bone tunnels, affix to the tibia, and has no donor site morbidity. Compared with the HS, it provides higher ultimate tensile strength and better initial fixation. The theoretical risk of human immunodeficiency virus transmission is estimated at 1:1,667,700.

If a grade III MCL, ACL, or PLC injury occurs in association with a PCL injury, reconstruction of all ligaments should be performed. When a knee dislocation has been suspected, appropriate neurovascular evaluation must be performed. Although delaying PCL reconstruction with an associated ACL tear may be appropriate to prevent postoperative arthrofibrosis, it is not recommended for associated PLC injuries as delayed repair is associated with relatively poor results (see below).

Our current arthroscopic technique recreates the ALB of the PCL using a fresh-frozen 11-mm Achilles' tendon allograft (Fig. 35-24). As in ACL reconstruction, examination under anesthesia with side-to-side comparison followed by diagnostic arthroscopy is performed to address associated pathology. The PLC should be evaluated by performing the tests described above. Arthroscopic PCL reconstruction follows six steps as outlined below.

Step 1. Preparation of the notch and ligament insertion sites: A 30 and 70 degree arthroscope through the anterolateral portal is helpful to visualize and prepare the tibial PCL insertion site. A posteromedial portal is made 1 cm above the joint line at the posteromedial edge of the medial femoral condyle. This portal is established by transilluminating the area with the arthroscope placed through the notch along the lateral portion of the medial femoral condyle. It may be helpful to elevate the posterior capsule at the PCL attachment site.

Step 2. Tibial tunnel preparation: A PCL arthroscopic drill guide is inserted through the anteromedial portal and directed through the intercondylar notch over the tibial "footprint," erring slightly lateral to the center of this site. The entrance site along the anteromedial tibia is located about 1 cm below and 2 to 3 cm medial to the tibial tubercle with the guide set at

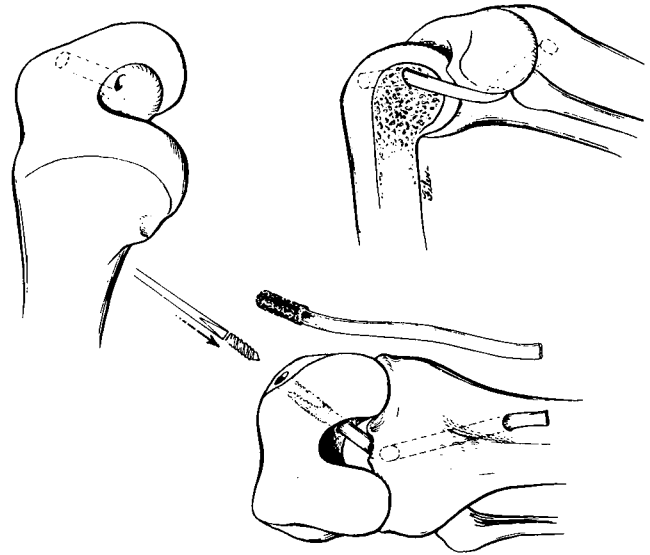


Figure 35-24 Schematic of PCL reconstruction using the Achilles tendon allograft. Reproduced with permission from Harner CD, Miller MD. Graft tensioning and fixation in posterior cruciate ligament surgery. *Op Tech Sports Med.* 1993; 1:116.

45 to 55 degrees. The appropriate-sized cannulated reamer is used over a Kirschner wire under direct visualization.

Step 3. Femoral tunnel placement: A 3-cm longitudinal, medial parapatellar incision is made midway between the medial femoral condyle and the medial patellar edge. The arthroscopic drill guide is set at 30 degrees and inserted through the anteromedial portal with the knee flexed at 90 degrees. The guide is positioned over the anterior portion of the PCL located 8 to 10 mm behind the articular cartilage edge of the medial femoral condyle.

Step 4. Preparation of Achilles tendon graft: An 11-mm wide \times 25- to 30-mm long, bone plug is fashioned at the calcaneal insertion. The soft tissue end is trimmed and tubularized with No. 2 nonabsorbable sutures. Two retention sutures (No. 5 nonabsorbable) are placed through the bone plug.

Step 5. Graft passage: A looped 18-gauge wire is passed through the tibial tunnel and retrieved outside the knee through the femoral tunnel. The graft is drawn into the knee (tendon portion first) by passing the free ends of the No. 2 sutures through the looped end of the wire and drawing it back through the tibial tunnel below.

Step 6. Graft fixation: Femoral fixation is from outside-in with an interference screw (7- 9-mm \times 20 mm). Tension is placed on the tibial end of the graft and the knee is cycled (flexed and extended). Tibial fixation is performed with the knee flexed 70 to 80 degrees and an anteriorly directed force placed upon the back of the tibia; fixation is performed at the anteromedial tibia using a screw and spikewasher.

*Reconstruction of Combined Ligament Injuries***Posterior Cruciate Ligament and Posterolateral Complex**

The PLC has been variably defined to include the following structures: LCL and the PLC (arcuate ligament, popliteal tendon, popliteofibular ligament, fabellofibular ligament and posterolateral capsule) Compared with PCL or ACL tears, isolated injuries to the PLC are uncommon and more frequently seen with combined ligament injuries (ACL or PCL). As already indicated, the disability (pain, instability) of these injuries is far greater than isolated PCL or ACL deficiency. If the PLC is not addressed at the time of PCL (or ACL) reconstruction, it may contribute to early PCL (or ACL) failure and persistent instability. Additionally, the results of late PLC reconstruction are comparatively poor.

If it is determined that there is an associated injury to the PLC, then it should be reconstructed as described above. Some recommend delaying the tibial fixation until after the PLC is reconstructed. Using a curvilinear lateral incision, the PLC is exposed and evaluated. The surgical options include primary repair, advancement or recession, and augmentation or reconstruction. In the chronic setting, it is critical to evaluate limb alignment and to assess for varus thrust during the stance phase of gait. If necessary, a valgus HTO may be performed before or in combination with reconstruction.

Posterior Cruciate Ligament and Anterior Cruciate Ligament

The combination of PCL-ACL injuries should raise the possibility of an acute knee dislocation with spontaneous reduction. Evaluation for neurovascular injury is performed, which can include side-to-side differences in pulses, arteriogram, Doppler ultrasound, or MRI vascular study. Treatment of acute, combined PCL-ACL injuries are delayed for 1 to 3 weeks to watch for vascular injuries and to regain knee motion. As in acute ACL reconstruction, there is a risk for postoperative arthrofibrosis if surgery is performed before motion is regained and significant inflammation has not resolved. We recommend PCL reconstruction first (Achilles tendon allograft or BPTB autograft) followed by ACL reconstruction (BPTB or HS autograft).

PEARL

The normal step-off of the medial tibial plateau (> 10 mm) must be recreated before the posterior cruciate ligament (PCL) graft is secured at the tibia.

Posterior Cruciate Ligament and Medial Collateral Ligament

This is the least common PCL combined injury. In the presence of grades I and II MCL injury, isolated PCL reconstruction should follow the usual protocol (Fig. 35-23). A grade III MCL tear should be addressed by primary repair, advancement, reinforcement, or reconstruction if medial instability remains after PCL reconstruction.

Rehabilitation

The goal of postoperative rehabilitation is to protect the graft from excessive forces until bone-to-bone or tendon-to-bone

healing has occurred. This is more easily accomplished by performing exercises in the prone position to pull the tibia anteriorly, maintaining extension in the brace during the early phase of rehabilitation and avoiding open-chain HS exercise.

The following may be used as a rehabilitation guide:

1. Weight bearing: Partial weight-bearing with crutches for 6 weeks for isolated PCL reconstruction and up to 3 months for combined injury reconstruction.
2. Hinged brace: Locked in extension for 1 week, unlocked for ROM exercises for 6 weeks, and then unlocked continuously until normal gait is established.
3. ROM exercises: Passive knee-flexion exercises are advanced slowly over the first 6 weeks. About two thirds of patients will regain full flexion within 3 to 6 months, and one third will take 9 to 12 months to regain full flexion.
4. Gait: After 6 weeks, the brace is unlocked and emphasis is placed on establishing normal gait. Closed-chain exercises (biking, leg-press, pool) are begun.

Ultimately, muscle strength should be at least 90% of that on the noninjured side. Emphasis is then placed on sport-specific agility and proprioceptive skills by a trained therapist. It is usually 8 to 12 weeks before patients are walking without assistive devices and 8 to 12 months before patients are allowed to return to normal activities.

Results

Most studies reporting the results of PCL reconstruction suffer from the same limitations as those reporting the results of ACL reconstruction, namely, heterogeneous patient-population, varied injury patterns, diverse timing (acute vs. chronic), and varied techniques. Our results show that about 50% of patients can be converted from grade III to II laxity, 35% can achieve a laxity pattern similar to the uninvolved knee, and laxity is not improved at all in 15%. Subjectively, 70% to 80% of the patients noted improvement. In summary, the results of PCL surgery lag behind those of ACL surgery. Adherence to the treatment algorithm and addressing associated pathology at the time of reconstruction is likely to yield the best results.

Complications

Immediate complications are similar to ACL surgery, but specifically include neurovascular injury (pins and drilling) and neuropraxia (prolonged tourniquet use). Vascular injury must be addressed immediately by a vascular surgeon, and most neuropraxias will resolve by 18 months. Late complications include postoperative increases in laxity (usually from technical error or failure to treat associated ligament injury), loss of motion due to excessive graft tensioning or inadequate rehabilitation, and rarely, avascular necrosis of the medial femoral condyle due to femoral tunnel preparation.

Future Directions

A better understanding of the natural history of PCL injuries is needed. Research in the areas of anatomy, biomechanics, and kinematics will help to more accurately reconstruct the PCL. Advancements in graft materials and fixation techniques continue to evolve as research yields new technologies.