

PECTORALIS MAJOR TRANSFER FOR SCAPULAR WINGING

JEFF A. FOX, MD and BRIAN J. COLE, MD, MBA

Scapular winging secondary to serratus anterior dysfunction is often initially misdiagnosed. When it is refractory to conservative treatment, tendon transfers are commonly prescribed. The principal goal of surgical treatment is to re-establish dynamic scapular stability to reduce pain and dysfunction. Multiple surgical reconstruction techniques have been described. Transfer of the sternal head of the pectoralis major muscle is the most commonly utilized technique. In this paper, we describe a minimally invasive technique using a hamstring allograft to augment the tendon to bone fixation of the sternal head of the pectoralis major tendon.

KEY WORDS: scapula, scapular winging, long thoracic nerve, scapular thoracic dyskinesia

© 2003 Elsevier Inc. All rights reserved.

Scapular-thoracic dysfunction including scapular winging is a frequent finding in patients with shoulder pathology. Primary dysfunction of the serratus anterior is one of several potential causes for this condition that in some individuals, results in significant pain and dysfunction. Normally, the serratus anterior maintains scapular stability during humeral elevation by causing upward rotation and protraction of the scapula. Primary dysfunction will cause winging of the scapula during active humeral elevation (Fig 1). While serratus anterior dysfunction is the most common cause of scapular winging, other muscles may also be responsible including weakness of the trapezius and rhomboids.

Most patients with symptoms due to scapular winging will improve with physical therapy dedicated toward periscapular strengthening and activation of the scapular stabilizers. However, a subset of patients will remain symptomatic without significant resolution of their winging. Various tendon transfers have been used to treat symptomatic winging of the scapula including the teres major,¹ rhomboids,² pectoralis minor,³ and the pectoralis major.⁴⁻⁸ The technique for pectoralis major tendon transfer was initially described using an extensile approach with an incision beginning at the coracoid process extending inferiorly and posteriorly around the thorax to the level of the inferior pole of the scapula.⁴⁻⁸ In addition, an autogenous iliotibial band graft was harvested through a second large incision centered over the lateral thigh. Recently, the senior author reported on the results of this technique and observed that some patients complained of muscle herniation and dysfunction due to the iliotibial

band harvest.⁸ Additionally, the incision as initially described, is large and unsightly and technically speaking, is not completely necessary to accomplish tendon dissection, surgical release and insertion into the inferior scapular pole.

We describe the technique for transfer of the sternal head of the pectoralis major through two small incisions using hamstring autograft or allograft to augment the repair. This technique has been previously described by Warner and Navarro utilizing only a hamstring autograft.¹⁶ We prefer to transfer the sternal head of the pectoralis major tendon over the other described tendon transfers because of its potential excursion, its vector of contraction following re-routing against the chest wall, its similar electromyographic activity and similar power to the serratus anterior.⁹ Additionally, we believe that maintaining the clavicular and abdominal head tendinous insertions relatively preserves the normal function of the pectoralis major muscle.

INDICATIONS AND CONTRAINDICATIONS

Scapular winging can result from injury to the long thoracic nerve from trauma, infection and idiopathic etiologies.⁹ Most traumatic injuries to the long thoracic nerve are blunt injuries from a fall or collision that results in a neuropraxia.¹⁰ Injuries during sports participation are a common source of nerve injury.^{11,12} Repetitive strenuous activities also have been reported to cause serratus anterior palsy.⁹ Generally speaking, patients will be evaluated preoperatively with electromyography (EMG) and nerve conduction velocity (NCV) analysis, although many patients will not have electrodiagnostic evidence of long thoracic nerve injury.⁴ If these studies are positive, they are quite helpful to confirm the diagnosis of a long thoracic nerve injury. If one is observing for nerve recovery the tests should be performed every 3 months.¹¹ It is recommended for these studies to assess the spinal accessory nerve because paralysis of the trapezius muscle can compromise the outcome of surgery.⁹

From the Central States Orthopedic Specialist in Tulsa Oklahoma and Department of Orthopedic Surgery and Anatomy (Conjoint), Rush-Presbyterian-St. Luke's Medical Center, Chicago, IL.

Address reprint requests to Jeff A. Fox, MD, Tulsa Sports Medicine and Wellness Center, Central States Orthopedic Specialists, 6585 South Yale Avenue, Suite 200, Tulsa, OK 74136-8315.

© 2003 Elsevier Inc. All rights reserved.

1048-6666/03/1304-0000\$30.00/0

doi:10.1053/S1048-6666(03)00078-8

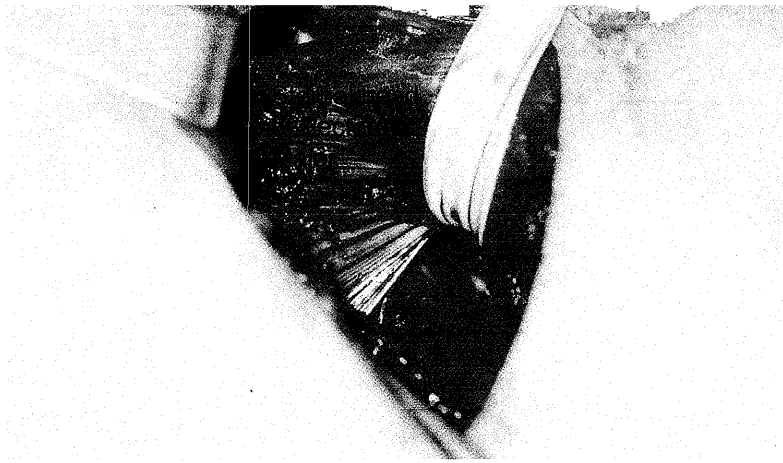


Fig 4. A Pinrose drain is used to retract the sternal head when exposing and then releasing the insertion.

tograft or allograft to lengthen and reinforce the construct. If harvesting an autograft, the ipsilateral knee should be prepped and draped free. The knee can be externally rotated to position for the harvest. There are several descriptions of hamstring harvest which should be reviewed before attempting harvest of the semitendinosus.^{13,14} If using an allograft, a properly thawed semitendinosus tendon is doubled on to itself with the free ends sutured together. Typically, a running baseball type stitch is used incorporating both free tendon edges to each other to create a closed loop of tendon.

The sutured free ends are woven through the pectoralis tendon by passing it transversely through the substance of the tendon about 2 cm from the tendon edge and then passing it again through the tendon, but perpendicular to the first pass. The pectoralis tendon is then tubularized over the semitendinosus tendon for a length of about 3 cm using #5 to 0 nonabsorbable suture or a No. 2.0 Fiberwire (Arthrex Inc, Naples, FL) (Figs 6 and 7).

SCAPULAR PREPARATION

Gentle longitudinal traction of the arm and manual displacement the inferior pole of the scapula anteriorly and laterally moves the intended scapular insertion site in line with the second 4 cm skin incision made over lateral

border of scapula (Fig 2). The latissimus dorsi is split in line with its fibers as the dissection is carried toward the inferior pole of the scapula. The remaining musculature is elevated from the anterior and posterior aspect of the inferolateral scapular border with an electrocautery device and soft tissue elevator. Using a blunt retractor to protect against inadvertent penetration anterior to the scapula, a 7 mm drill or reamer is used to drill a hole at the inferior angle of the scapula in the thin bone proximal the thickened scapular edges (Fig 8). This is approximately 6 to 8 mm from the medial, inferior and lateral aspect of the scapula.

Using digital dissection, the interval deep to the latissimus against the chest wall is bluntly developed creating a tunnel connecting the anterior axillary exposure to the posterolateral scapular exposure. Adequate tunnel dilation is critical to allow smooth excursion of the tendon allograft construct. A long curved hemostat entering through the scapular incision and directed toward the axillary incision is passed within the tunnel and used to retrieve the tendon allograft construct.

The looped end of the allograft is passed from the anterior surface to the posterior surface of the scapula and sewn to itself and the distal edge of the sternal pectoralis major tendon with No. 2.0 Fiberwire (Fig 9). The scapula

Fig 5. Pectoralis tendon released and pulled out. The anterior wound it is now ready to receive the allograft.

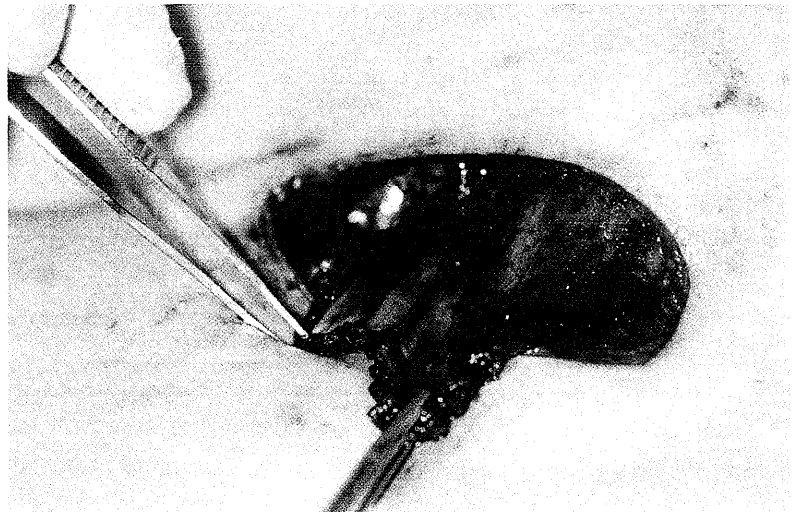
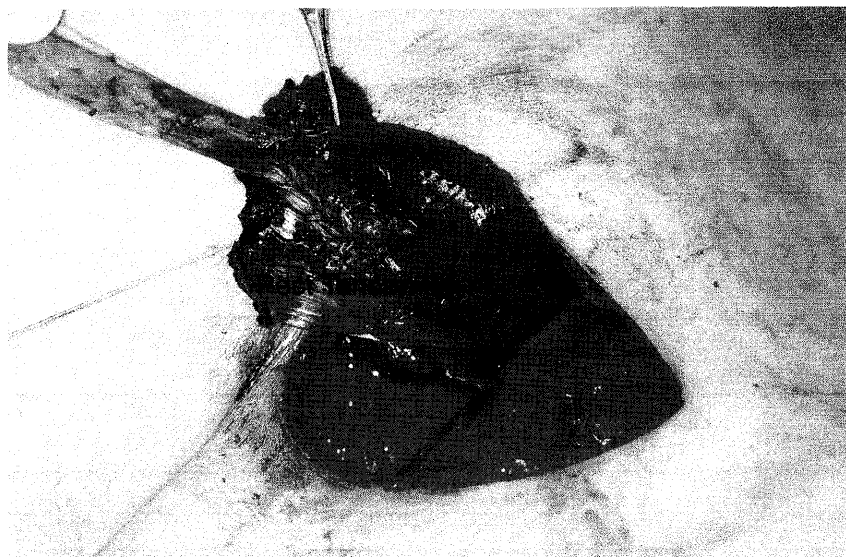


Fig 6. Allograft tendon being sewn onto the pectoralis tendon.



should be protracted and pushed as far lateral as possible during this step. The wound is irrigated and closed in a layered fashion with a subcutaneous monofilament suture used to approximate the skin edges. The arm is placed in a sling with a small abduction pillow situated along the mid-axillary line.

POSTOPERATIVE MANAGEMENT

A sling is worn with the arm at the side for the first 4 weeks and is removed only for exercise and hygiene. Gentle passive motion begins immediately to minimize scarring of the tendon transfer through its soft tissue tunnel. We begin formal physical therapy 7 to 10 days after the procedure. This begins with scapular isometrics with the arm at the side, closed chain protraction and retraction exercises, pendulum exercises and passive and active assisted forward elevation to 90°, abduction to 90° and external rotation to 50°. At 4 weeks active motion is initiated in all planes with no limitation. At 8 weeks we begin gentle scapular strengthening, with no limits on range of motion.

At 3 months strengthening of all the muscles about the shoulder is initiated which may include biofeedback using

surface electrodes over the transferred pectoralis muscle. Asking the patient to adduct the flexed arm against resistance facilitates activation of the muscle. Maintaining adduction and asking the patient to flex the shoulder anterior to the scapular plane advances this activity. These exercises may begin as early as 8 weeks with gravity elimination, but formal strengthening against gravity is delayed for at least 12 weeks. By 4 months, no motion restrictions are placed, but patients are asked to refrain from lifting greater than 25 pounds and to avoid any contact sports or overhead labor responsibilities until 6 to 8 months whereby a more aggressive strengthening program is completed.

RESULTS

Traditionally the pectoralis major transfer has been performed using autogenous fascia lata instead of allograft or autograft hamstring tendons. Connor and coworkers⁹ reported on 11 patients with 91% having a satisfactory result with significant improvement in function and reduction of pain. Perlmutter and Leffert⁵ reviewed 16 patients and found 81% had good or excellent results. There were two failures secondary to trauma. Post⁶ in 1995 reported on

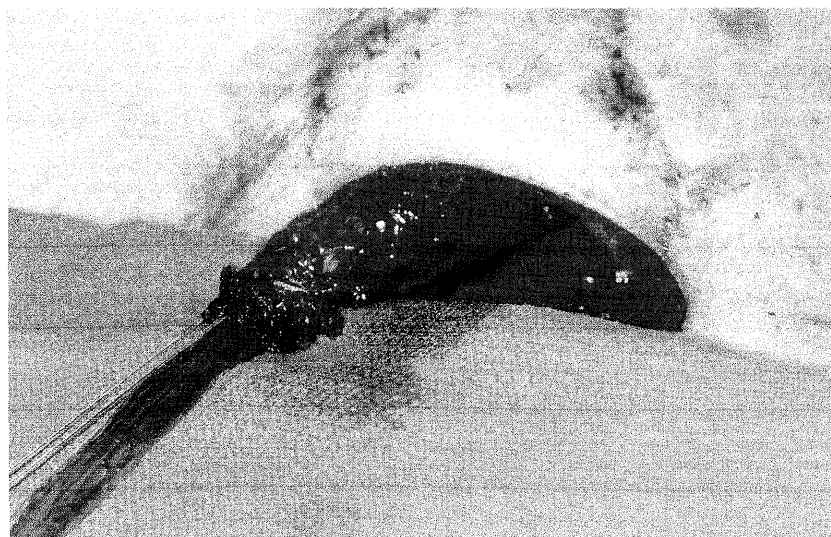


Fig 7. Allograft securely fixed to the pectoralis tendon.

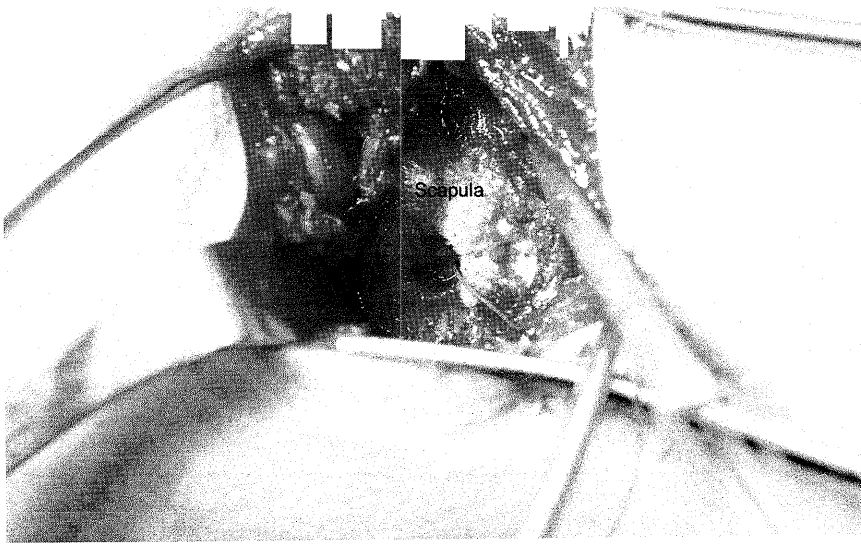


Fig 8. A drill hole has been created in the posterolateral scapula.

eight patients who all were able to return to work with 5 of the 8 given modified work restrictions. Recently, Noerdlinger and coworkers⁸ reported an update on Post's series demonstrating that while complete relieve of pain and function were not always restored, most patients returned to their preoperative level of activity with only minor adaptations. Unfortunately, several patients complained of significant donor site morbidity from the harvest site of the fascia lata autograft. Warner and Navarro¹⁵ reported on 8 patients 7 of whom experienced resolution of their painful scapular winging. In their study they augmented with autogenous semitendinosus and gracilis, not tensor fascia lata.

Our early results using allograft or autograft hamstring tendon to augment the tendon repair in seven patients (follow-up range, 4 months to 5.5 years) have been promising thus far with no complaints of morbidity relating to the hamstring autograft (used in two) and functional re-

sults mirroring those published by Noerdlinger and coworkers.⁸

COMPLICATIONS

Potential complications unique to this procedure include selective denervation of the muscle, entrapment of the soft tissue and neurovascular structures adjacent to the chest wall, scapular fracture with graft failure, and hematoma formation. Clearly identifying the raphe between the clavicular and sternal heads of the pectoralis major muscle tendon unit will facilitate atraumatic dissection of the sternal head medially toward its insertion. This will maximize its excursion and avoid inadvertent tethering of the muscle as it is transferred from its insertion to the inferior pole of the scapula.

If one fails to develop the correct plane between the latissimus muscle and chest wall, it is possible to inadver-

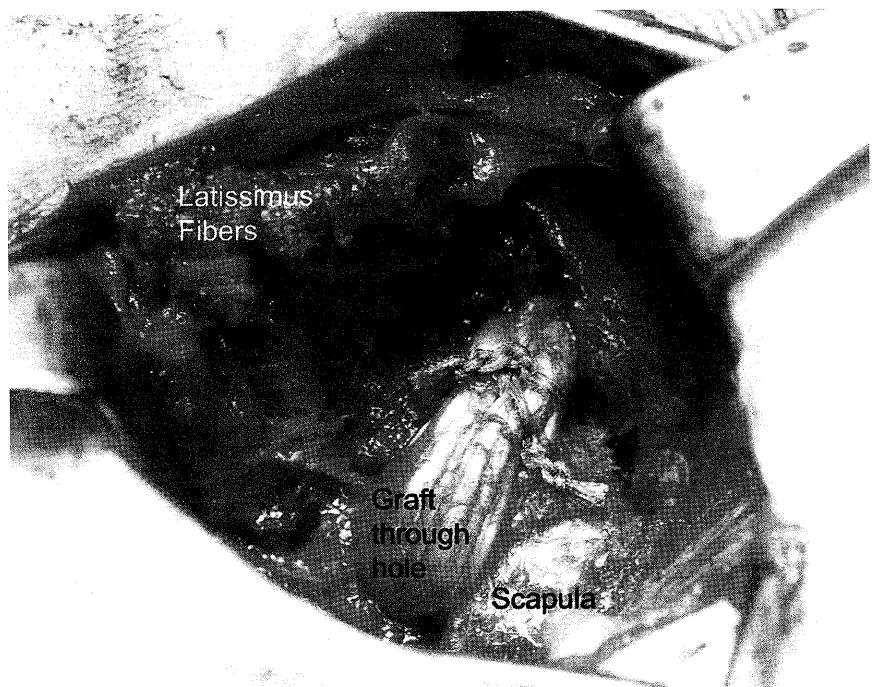


Fig 9. Graft secured through the scapular tunnel.

tently compress portions of the brachial plexus between the tendon and chest wall. This is avoided by clearly palpating the bony margins of the ribs and elevating the latissimus and overlying fat that envelopes the brachial plexus off of the chest wall before passing the tendon. This is easily performed using digital dissection through the axillary incision.

Fracture of the inferior pole of the scapula can occur if the hole is drilled too close to the scapular edge or if overly aggressive therapy begins too early before graft incorporation. This difficult complication can be avoided by carefully dissecting the musculature away from the inferior pole before drilling. An elevator is used to strip the muscles from the anterior and posterior border of the inferior pole for a distance of 2 to 3 cm. Delaying strengthening of the pectoralis major muscle for at least 12 weeks may prevent graft failure from occurring as a delayed complication.

Because the sternal head is detached and directed away from the clavicular head through a potential space created between the chest wall and latissimus muscle, a significant risk exists for hematoma development. To prevent this, we obtain meticulous hemostasis, place a drain postoperatively if required and instruct patients to minimize their activities postoperatively for the first 7 to 10 days.

FUTURE DEVELOPMENTS

The split pectoralis major transfer has proven successful in many small studies. Using an allograft or autograft hamstring tendon decreases the surgical morbidity associated with a second incision on the thigh. Alternatively, it may prove possible to use pure collagen grafts (ie, Graft Jacket, Wright Medical; Restore Patch, DePuy, Inc) as a tissue extender which would virtually eliminate the chance for disease transmission associated with allograft tissue. We have advanced the rehabilitation with an emphasis on achieving early external rotation to prevent motion loss seen in the senior author's recent report.⁸ With proper indications, this surgery can provide patients with signif-

icant improvement from the symptoms associated with dysfunction of the serratus anterior.

REFERENCES

1. Zeier FG: The treatment of winged-scapula. *Clin Orthop* 91:128-33, 1973
2. Herzmark M: Traumatic paralysis of the serratus anterior relieved by transplantation of the rhomboidei. *J Bone Joint Surg Am* 33A:235-238, 1951
3. Perry J: Biomechanics of the Shoulder, in Rowe C (ed): *The Shoulder*. New York, Churchill Livingstone, 1988, pp 1-35
4. Icton J, Harris WR: Treatment of winged scapula by pectoralis major transfer. *J Bone Joint Surg Br* 69:108-10, 1987
5. Perlmutter GS, Leffert RD: Results of transfer of the pectoralis major tendon to treat paralysis of the serratus anterior muscle. *J Bone Joint Surg Am* 81:377-84, 1999
6. Post M: Pectoralis major transfer for winging of the scapula. *J Shoulder Elbow Surg* 4:1-9, 1995
7. Povacz P, Resch H: Dynamic stabilization of winging scapula by direct split pectoralis major transfer: A technical note. *J Shoulder Elbow Surg* 9:76-8, 2000
8. Noerdlinger MA, Cole BJ, Stewart M, Post M: Results of pectoralis major transfer with fascia lata autograft augmentation for scapula winging. *J Shoulder Elbow Surg* 11:345-50, 2002
9. Connor PM, Yamaguchi K, Manifold SG, Pollock RG, Flatow EL, Bigliani LU: Split pectoralis major transfer for serratus anterior palsy. *Clin Orthop* 341:134-42, 1997
10. Gozma ER, Harris WR: Traumatic winging of the scapula. *J Bone Joint Surg Am* 61A:1230-1233, 1979
11. Kuhn JE, Plancher KD, Hawkins RJ: Scapular winging. *J Am Acad Orthop Surg* 3:319-325, 1995
12. Gregg JR, Labosky D, Harty M, Lotke P, Ecker M, DiStefano V, Das M: Serratus anterior paralysis in the young athlete. *J Bone Joint Surg Am* 61:825-32, 1979
13. Grana W: Pearls and pitfalls of hamstring harvest. *Tech Orthoped* 13:337-340, 1998
14. Brown C, Sklar JH: Endoscopic anterior cruciate ligament reconstruction using quadrupled hamstring tendons and endobutton femoral fixation. *Tech Orthoped* 13:281-298, 1998
15. Noerdlinger MA, Cole BJ, Stewart M, Post M: Results of pectoralis major transfer with fascia lata autograft augmentation for scapula winging. *J Shoulder Elbow Surg* 11:345-50, 2002
16. Warner JJ, Navarro RA: Serratus anterior dysfunction. Recognition and treatment. *Clin Orthop* :139-48, 1998