

# The American Journal of Sports Medicine

<http://ajs.sagepub.com/>

---

## Postsurgical Glenohumeral Arthritis in Young Adults

Allison G. McNickle, Daniel R. L'Heureux, Matthew T. Provencher, Anthony A. Romeo and Brian J. Cole  
*Am J Sports Med* 2009 37: 1784 originally published online June 9, 2009  
DOI: 10.1177/0363546509333481

The online version of this article can be found at:

<http://ajs.sagepub.com/content/37/9/1784>

---

Published by:



<http://www.sagepublications.com>

On behalf of:



[American Orthopaedic Society for Sports Medicine](http://www.aossm.org)

**Additional services and information for *The American Journal of Sports Medicine* can be found at:**

**Email Alerts:** <http://ajs.sagepub.com/cgi/alerts>

**Subscriptions:** <http://ajs.sagepub.com/subscriptions>

**Reprints:** <http://www.sagepub.com/journalsReprints.nav>

**Permissions:** <http://www.sagepub.com/journalsPermissions.nav>

# Postsurgical Glenohumeral Arthritis in Young Adults

Allison G. McNickle,\* MS, Daniel R. L'Heureux,\* BS, Matthew T. Provencher,<sup>†</sup> MD, LCDR, MC, USN, Anthony A. Romeo,\* MD, and Brian J. Cole,\*<sup>‡§</sup> MD, MBA

From the \*Department of Orthopaedic Surgery, Rush University Medical Center, Chicago, Illinois, the <sup>†</sup>Department of Orthopaedic Surgery, Naval Medical Center San Diego, San Diego, California, and <sup>‡</sup>Rush Cartilage Restoration Center, Chicago, Illinois

**Background:** Chondrolysis has been reported as a sequela of arthroscopic shoulder surgery. Although the causes have yet to be fully elucidated, basic science and clinical evidence suggest a multifactorial origin. Surgical treatment in young patients with glenohumeral chondrolysis is particularly challenging, with little outcome data.

**Hypothesis:** Glenohumeral chondrolysis has several causes and patterns of presentation. Biological resurfacing is a viable treatment option for symptomatic glenohumeral arthritis.

**Study Design:** Case series; Level of evidence, 4.

**Methods:** Twenty patients (mean age, 19.7 years; range, 13.1-33.8) were referred for management of extensive glenohumeral arthritis after arthroscopy glenohumeral surgery (mean time postoperatively, 26 months; range, 3-73). Sixteen patients had an intra-articular pain pump placed for 2 to 3 days; 2 patients demonstrated prominent implants; and 2 had thermal treatment. Patients underwent revision surgery, including 7 biological resurfacings of the glenoid and humeral head, 4 biological resurfacings of the humeral head alone, and 7 other procedures. Eight patients having biological resurfacing were assessed just before the revision surgery, at a mean time of 3.1 years after revision (range, 1.9-6.5), with the American Shoulder and Elbow Surgeon scale and Simple Shoulder Test, Short Form 12 (physical and mental components), and visual analog scale score for pain.

**Results:** Patient outcomes scores improved from 51 to 71 (American Shoulder and Elbow Surgeon scale,  $P < .01$ ), 7 to 10 (Simple Shoulder Test,  $P < .02$ ), and 5 to 3 (visual analog scale,  $P < .01$ ). Preoperative range of motion demonstrated modest improvements from 119° to 132° of flexion, 42° to 41° of external rotation, and internal rotation from L2 to T12 level. Two patients required an additional surgery: 1 total shoulder arthroplasty and 1 capsular release with debridement.

**Conclusion:** Severe glenohumeral arthritis is a devastating postoperative complication of glenohumeral arthroscopy. Although not a universal finding, the use of glenohumeral pain pumps is a concern, as well as suboptimal anchor placement. Biological resurfacing permits modest functional improvement in a challenging shoulder condition.

**Keywords:** chondrolysis; glenohumeral; arthritis; pain pump; biological resurfacing; outcomes

Primary glenohumeral osteoarthritis predominantly occurs in older individuals; however, a younger cohort of patients has been recently described with end stage glenohumeral arthritis after shoulder arthroscopy. The term *postarthroscopic*

*glenohumeral chondrolysis* (PAGCL) is used to describe young patients with symptomatic glenohumeral chondrolysis and degenerative changes after arthroscopic shoulder procedures.<sup>10,23</sup> The causes of PAGCL have yet to be fully elucidated; however, basic science<sup>5,8,15</sup> and clinical evidence<sup>9,10,12,16,23</sup> have suggested that the problem is likely multifactorial. Although intra-articular pain pumps,<sup>5,8,15</sup> radiofrequency devices,<sup>9,16,18,27</sup> and hardware problems such as prominent anchors<sup>13,30</sup> have been described, the causes of PAGCL are still not completely understood.

Symptomatic glenohumeral chondrolysis due to PAGCL presents a challenging problem in the young active patient, typically younger than 30 years old.<sup>10</sup> Regardless of the cause, the resulting symptoms—pain, stiffness, and decreased range of motion—cause significant disability in many aspects of daily living in this cohort of patients. The surgical treatment for young patients with glenohumeral arthritis is challenging and so remains poorly defined. The

<sup>§</sup>Address correspondence to Brian J. Cole, MD, MBA, Midwest Orthopaedics at Rush, 1725 West Harrison Street, Suite 1063, Chicago, IL 60612 (e-mail: bcole@rushortho.com).

Presented at the interim meeting of the AOSSM, Las Vegas, Nevada, February 2009.

One or more authors has declared a potential conflict of interest: Dr Brian Cole is a consultant for Genzyme Biosurgery Inc (manufacturer of Carticel). All other authors have no commercial or financial involvements.

The views expressed in this article are those of the authors and do not reflect the official policy or position of the Department of the Navy, Department of Defense, or US Government.

TABLE 1  
Patient Demographics and Index Procedure Details<sup>a</sup>

Patient	Age/ Gender	Index Procedure	Pain Pump, Days	Rf	Anchors	Preop CM
1	13.1/M	SLAP	3	None	3 bio	None
2	15.2/F	CR	3	None	None	None
3	15.3/F	SLAP	3	None	3 metal	None
4	15.6/F	CR	3 <sup>b</sup>	Yes	None	None
5	15.6/M	CR	3	Yes	None	None
6	15.9/M	BR	3	None	4 bio	HS
7	15.9/M	OR	3	None	2 bio	None
8	18.5/M	BR	3	None	None	None
9	20.4/M	OR	3	None	None	None
10	21.4/M	OR	3	Yes	1 bio	HS
11	21.7/M	BR	3	None	3 bio	HS
12	24.1/F	CR	2	None	None	None
13	24.2/M	SLAP	3	None	2 bio	None
14	26.4/M	OR	3	None	5 bio	None
15	28.9/M	BR	3	None	None	None
16	34.7/M	OR	3	None	None	None
17	16.9/F	BR	None	None	3 metal <sup>c</sup>	None
18	20.5/M	BR	None	None	2 metal <sup>c</sup>	None
19	14.0/F	CR	None	Bipolar	None	None
20	16.0/M	CR	None	Bipolar	None	None

<sup>a</sup>RF, radiofrequency; CM, chondromalacia; SLAP, superior labrum, anterior to posterior repair; CR, capsulorrhaphy; BR, Bankart repair; OR, other labral or capsular repair; bio, bioabsorbable anchors; HS, Hill-Sachs lesion.

<sup>b</sup>Pain pump contained 0.25% bupivacaine; all others were 0.50% bupivacaine.

<sup>c</sup>Anchors were found to be prominent and required removal within 1 year of placement.

purpose of this study was to investigate the demographics and potential contributing factors associated with the development of PAGCL in a young adult cohort and to report on the outcomes of revision surgery, including biological resurfacing.

MATERIALS AND METHODS

Epidemiology

Over a 5-year period (2003-2008), 20 patients with mean age 19.7 years (range, 13.1-33.8) were referred with symptoms of glenohumeral arthritis at a mean of 26 months (range, 3-73) after initial glenohumeral arthroscopic surgery. Each one met the following inclusion criteria: (1) age younger than 35 years, (2) had undergone glenohumeral arthroscopy with capsular or labral procedure, (3) had intact glenohumeral cartilage at the index procedure, and (4) had ongoing postoperative symptoms of shoulder pain resulting in their referral to this institution. Exclusion criteria included (1) preexisting arthritic changes or cartilage procedure at initial surgery, (2) intra-articular fracture, and (3) neurologic injury. Surgical and medical records, including those from outside practices, were reviewed to determine the potential origin of the arthropathy.

TABLE 2  
Symptom Return, Chondromalacia, and Intervention<sup>a</sup>

Patient	Symptoms Onset, Mo			Postindex CM, Grade		Intervention of Senior Surgeon
	Pain	DROM	Stiffness	Humeral Head	Glenoid	
1	4.0	6.0	—	30 × 30 mm, IV	50%, III	HHA/LMI
2	10.0	—	—	>50%, IV	>50%, III	HC/GJ
3	3.5	3.0	—	30 × 30 mm, IV	30 × 30 mm, II	HHA/LMI
4	3.0	—	3.0	100%, IV	100%, IV	CR
5	3.0	3.0	—	>75%, IV	30%, IV	HHA/LMI
6	20.0	20.0	20.0	100%, IV	100%, IV	HHA/LMI
7	3.5	4.0	—	50%, IV	>50%, IV	None
8	8.5	8.5	8.5	100%, IV	100%, IV	CR
9	4.0	4.0	—	75%, IV	50%, III	HHA/LMI
10	5.0	6.0	6.0	70%, IV	80%, IV	Mfx HH
11	2.0	2.0	2.0	>50%, IV	33%, IV	CR
12	4.0	4.0	4.0	30 × 30 mm, IV	>75%, III	HHA/LMI
13	4.0	4.0	—	25 × 25 mm, IV	>75%, III	None
14	10.0	10.0	—	25%, IV	60%, IV	HC/GJ
15	12.0	12.0	—	100%, IV	25%, III	CR
16	5.0	5.0	5.0	100%, IV	100%, IV	CR
17	3.0	—	—	20 × 20 mm, IV	25%, II	ACI HH
18	2.0	2.0	—	25 × 25 mm, IV	25%, II	HHA/LMI
19	6.0	—	—	25%, IV	25%, III	HHA
20	2.0	—	—	25 × 20 mm, IV	None	ACI HH

<sup>a</sup>CM, chondromalacia (reported in terms of Outerbridge score); DROM, decreased range of motion; HHA, humeral head allograft; LMI, lateral meniscus interposition; HC/GJ, HemiCap/GraftJacket; CR, capsular release; Mfx HH, microfracture of the humeral head; ACI HH, autologous chondrocyte implantation to the humeral head.

The initial procedure included 6 Bankart repairs, 6 capsulorrhaphies, 3 SLAP repairs, and 5 other repairs (eg, posterior labral) (Table 1). Three patients with labral repairs had small Hill-Sachs defects (< 10 × 5 mm) on the posterior-superior humeral head.

Sixteen patients had a postoperative intra-articular glenohumeral pain pump. Catheters with bupivacaine (0.25%-0.50%) were removed by the patient between 48 and 72 hours after surgery. In 2 patients, metal anchors placed along the anterior glenoid for a Bankart repair were prominent and so required removal (< 1 year after placement). These 2 patients also demonstrated extensive humeral head wear-down below the subchondral bone in the area of anchor articulation. Anchors in the other 8 cases were well placed with no loose, prominent, or displaced devices. Exclusive radiofrequency capsular shrinkage was performed in 2 cases and, in 3 patients, as an adjunct to anchor placement. There were no reports of wound dehiscence, nerve paresthesias, or superficial or deep infection.

All patients reported increasing pain at an average of 5.7 months after surgery (range, 2-20), and 15 (75%) demonstrated decreased range of motion starting at a mean of 6.2 months (range, 2-20). Additional complaints included persistent stiffness (n = 7) and weakness (n = 4) (Table 2).

At the referral visit, decreased range of motion was a common finding, with a mean flexion of 119° (range, 40°-175°),

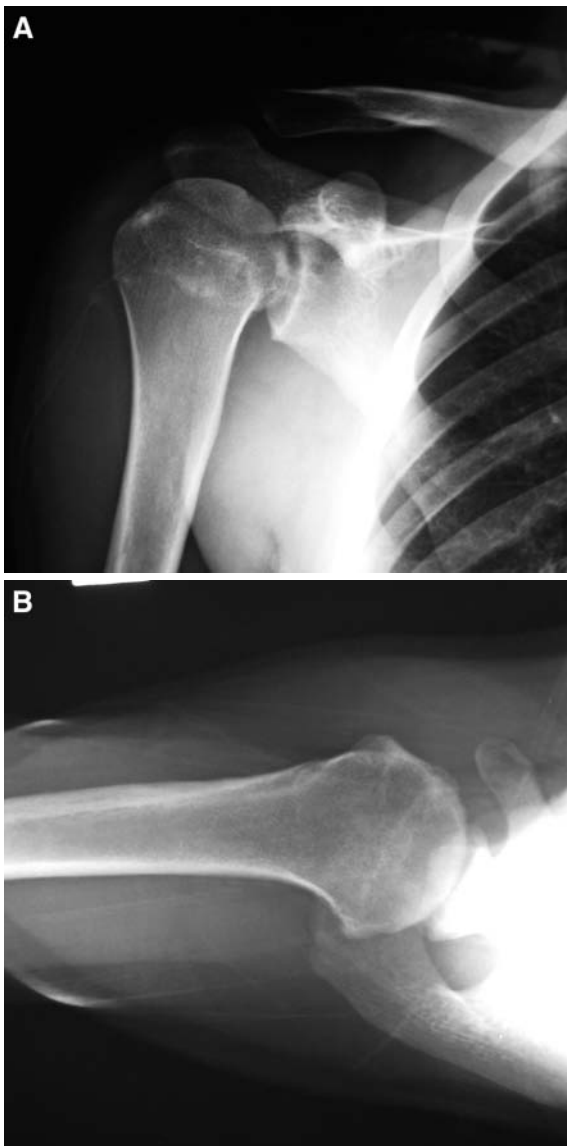
TABLE 3  
Range of Motion<sup>a</sup>

Procedure	Forward Elevation <sup>b</sup>		External Rotation <sup>b</sup> at 0°		Internal Rotation <sup>c</sup> at 0°	
	Preop	Follow-up	Preop	Follow-up	Preop	Follow-up
Capsular release	88 (75-95)	127 (110-140)	11 (0-30)	40 (25-70)	B (GT-L5)	L1 (L2-T12)
Resurfacing	132 (40-175)	133 (90-180)	50 (0-90)	42 (10-85)	T12 (GT-T4)	T12 (GT-T8)
Overall	119 (40-175)	132 (90-180)	42 (0-90)	41 (10-85)	L2 (GT-T4)	T12 (GT-T8)

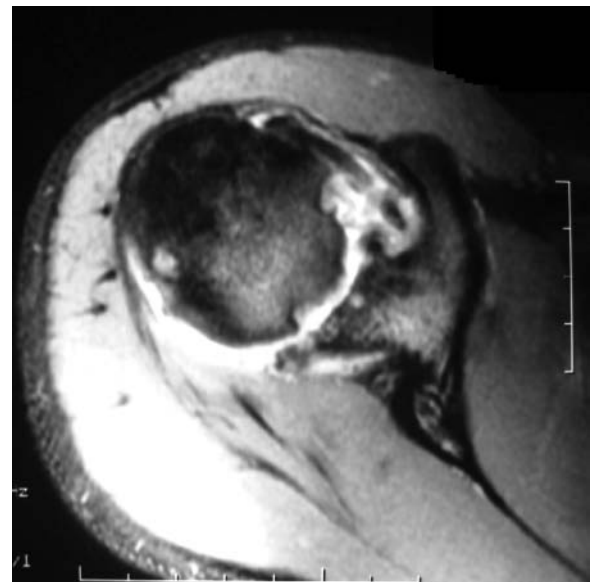<sup>a</sup>Preoperative range of motion was determined at the referral visit before any intervention by the senior surgeons. Range of motion was determined with a goniometer. B, buttock; GT, greater trochanter.

<sup>b</sup>Means (and ranges).

<sup>c</sup>Medians (and ranges).



**Figure 1.** Radiographic evidence of chondrolysis in a 21-year-old male patient after postoperative placement of a bupivacaine pain catheter. A, anteroposterior image demonstrating chondral changes of the humeral head and subchondral cysts. B, axillary radiograph with 1 to 2 mm of joint space remaining, although severely diminished overall.



**Figure 2.** Axial MRI illustrating degenerative changes and loss of the regular cartilage contour; from a 15-year-old male patient at presentation to this institution after postsurgical pain pump placement.

a mean external rotation of 42° at the side (range, 0°-90°), and a median internal rotation to the L2 level (range, greater trochanter to T4) (Table 3). Radiographic and MRI studies demonstrated degenerative changes to the glenohumeral joint in all patients (Figures 1 and 2). Joint space narrowing was noted in 13 of 20 shoulders, including 6 cases of complete obliteration with bone-on-bone contact. Bony changes to the humeral head included subchondral cysts, collapse, and osteophyte formation.

**Surgical Techniques**

Of the 20 patients with PAGCL, 18 underwent surgical revision procedures (by 2 attending surgeons at this institution) for persistent pain and stiffness, at a mean of 33 months after their initial procedure (range, 8-78). In 5 cases, a diagnostic arthroscopy and capsular release were used to evaluate the joint surfaces and increased range of motion before definitive cartilage restoration. Thirteen patients with a mean age of 21.4 years (range, 14.7-28.2)

TABLE 4  
Revision Surgeries Performed

Procedure	n
Bulk humeral head allograft (complete chondral humeral head replacement) and lateral meniscus interposition to the glenoid	7
HemiCap with GraftJacket	2
Humeral head autologous chondrocyte implantation	2
Humeral head allograft plug	1
Humeral head microfracture	1
Arthroscopic capsular release	5

had biological resurfacing of the humeral head (n = 4), glenoid (n = 2), or both (n = 7). Surgical decision making followed published treatment algorithms of Cole et al,<sup>6</sup> as well as McCarty and Cole,<sup>19</sup> which considered the degree of involvement of both the humeral head and the glenoid (Table 4).

Seven patients underwent bipolar biological resurfacing of the glenoid with a lateral meniscus and complete replacement of the chondral surface of the humeral head. Through a deltopectoral approach, the glenoid and humeral head were exposed with a subscapularis takedown technique. The glenoid surgery was performed first by performing an extensive capsular release with Mayo scissors of the rotator interval, the anteroinferior and posterior capsule to 9 o'clock posteriorly. Care was taken to protect the axillary nerve with an inferior-placed Darrach retractor. An anterior glenoid retractor was placed on the anteromedial glenoid neck. For the biological resurfacing procedure, any remaining chondral fragments were removed from the glenoid with a medium-sized curette; then, the glenoid was microfractured with a 45° awl. A lateral meniscus allograft (n = 7) was affixed to the glenoid using a combination of glenoid bone anchors and nonabsorbable No. 2 braided suture.<sup>20,21</sup> Attention was then drawn to the humeral head by externally rotating the humeral head, coupled with the use of a Fukuda retractor. Care was taken to protect the previously grafted glenoid. The humeral head was then resurfaced via a variety of techniques, depending on the size of the lesion and humeral head involvement. For the extensive chondral involvement, a fresh mushroom-shaped humeral head allograft (n = 7) was created on the back table and press fit into the humerus, which was removed with a sagittal saw in a plane parallel to the head articular cartilage margin<sup>6,20</sup> (Figure 3). With more focal involvement, a 25-mm allograft plug (n = 1) from a fresh humeral head donor was implanted with an allograft plug technique.<sup>19</sup>

Biological resurfacing of the humeral head included autologous chondrocyte implantation in 2 patients. This was selected for superficial humeral head lesions without significant subchondral involvement. Autologous chondrocytes were harvested from the intracondylar notch during a diagnostic knee arthroscopy and were expanded *in vitro* (Carticel, Genzyme Biosurgery, Boston, Massachusetts). At implantation, the lesion was exposed and debrided to a

base of subchondral bone. A periosteal patch, from the tibial metaphysis, was sutured to the periphery of the defect with 6-0 Vicryl sutures. A watertight seal was established with fibrin glue, and the cultured chondrocytes were injected with an angiocatheter, as previously described<sup>26</sup> (Figure 4A).

Arthroscopic capsular releases were performed in 5 patients. A lateral decubitus position was briefly used, with the arm in 45° of abduction. With the arthroscope in the posterior portal, a 360° release was started anteriorly with a basket cutter to release the capsule and the capsulo-labral junction. The arthroscope was then placed in the anterosuperior portal high in the rotator interval, and the posterior release was completed. A gentle manipulation under anesthesia was then performed.

Partial metal resurfacing of the humeral head with a HemiCap (Arthrosurface, Franklin, Massachusetts) and dermal graft to the glenoid (GraftJacket, Wright Medical, Arlington, Tennessee) was performed in 2 patients, as previously described.<sup>1</sup> With a similar exposure to the humeral head as described above, a HemiCap metal resurfacing implant was placed on the affected area of the humeral head, ranging in size from 30-40 mm. The dermal graft was placed on the glenoid with a combination of suture anchors and No. 2 nonabsorbable suture to remaining labral tissue, with a similar technique as the lateral meniscus allograft described above. One additional patient had a microfracture of the humeral head for a focal chondral defect. The calcified layer of cartilage was briefly removed with a curette, and approximately 4 subchondral penetrating holes were made with an awl (Figure 4B).

## Surgical Outcomes

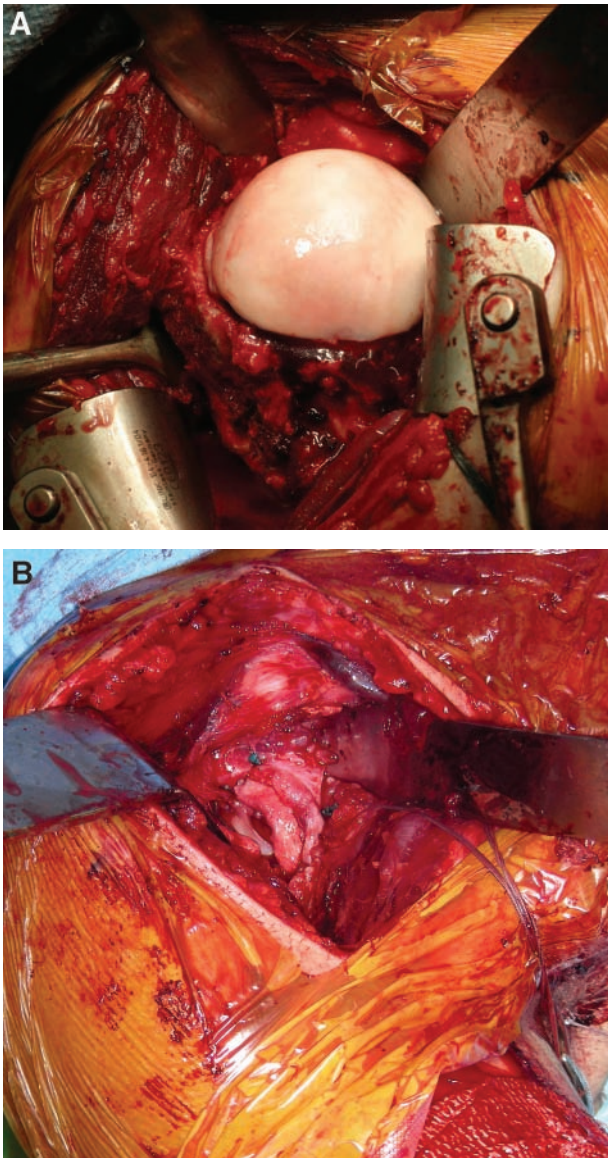
All patients were provided with an initial survey at their referral visit, which contained the Simple Shoulder Test, the American Shoulder and Elbow Surgeons scale, visual analog scale for pain, and the Short Form 12 for overall health (physical and mental component scores). At follow-up visits, a goniometer was used to assess active range of motion in forward flexion, abduction, and internal and external rotation at 0°. Improvement was statistically evaluated using GraphPad Software (San Diego, California) and paired *t* tests. All research protocols were approved by the institutional review board.

## RESULTS

At the time of revision surgery, all patients were noted to have large focal to diffuse changes (ie, grade 3 or 4) to the humeral head, glenoid, or both (Figure 5). One patient had no glenoid damage, whereas the remaining 19 had between 20% and 100% cartilage involvement. Humeral head damage was universally grade 4, extending 50%-100% of the area (Table 2).

For the 5 individuals who underwent capsular release, the mean ranges of motion increased from 88° to 127° (for forward flexion) and from 11° to 40° (for external rotation) and the median internal rotation, from the buttocks to L1.

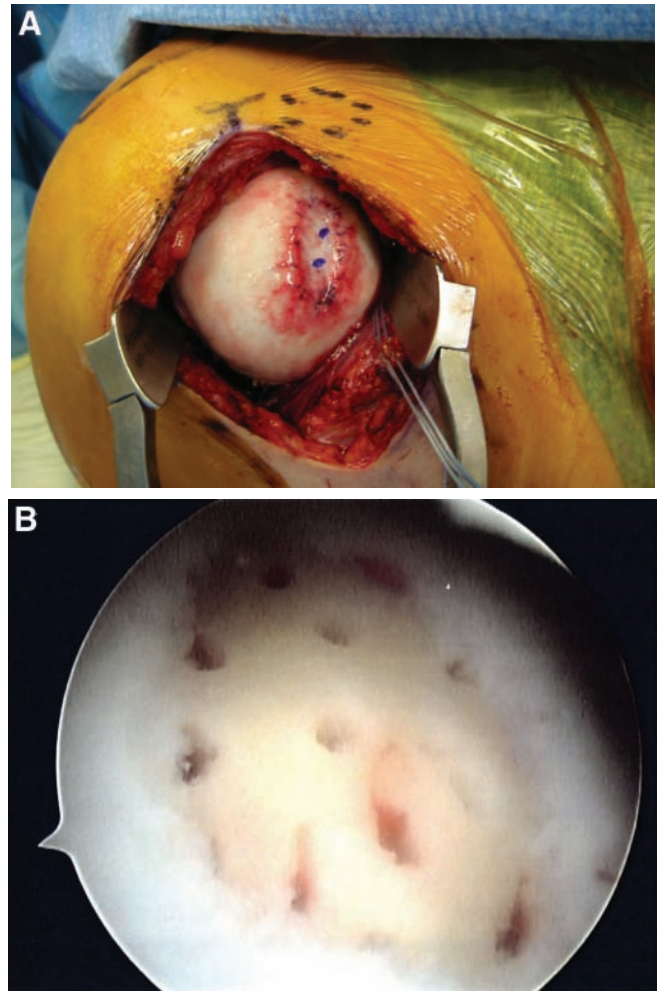




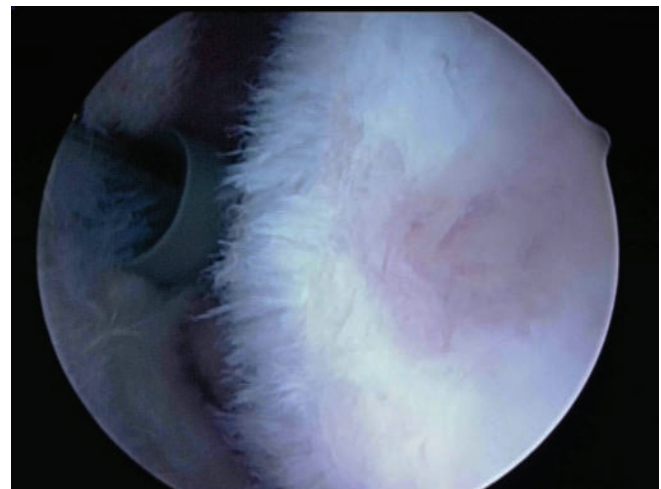
**Figure 3.** Biological resurfacing of the humeral head. A, a mushroom-shaped humeral head allograft is used to replace the entire articular surface. B, a lateral meniscus allograft sutured to the periphery of the glenoid.

Individuals undergoing biological resurfacing (n = 13) had minimal change in mean range of motion—from 132° to 133° of forward flexion, from 42° to 41° of external rotation at the side, and median internal rotation remained unchanged at the T12 level (Table 3).

Eight patients undergoing biological resurfacing completed follow-up surveys at a mean of 3.1 years after the procedure (range, 1.9-6.5). The remainder of the cohort (n = 5) was within 2 years of surgery. Mean outcomes scores improved on the Simple Shoulder Test (from 7 to 10,  $P < .01$ ) and American Shoulder and Elbow Surgeons scale (from 51 to 71,  $P = .018$ ), with a decrease on the visual analog scale for pain (from 5 to 3,  $P = .008$ ). Changes in the Short Form



**Figure 4.** A, completed autologous chondrocyte implantation to the humeral head in a patient with articular cartilage damage due to failed hardware. B, an isolated defect of the central humeral head is microfractured in a 23-year-old male patient 2 years after a reverse Bankart repair.



**Figure 5.** Chondrolysis of the humeral head. The central region is denuded of articular cartilage with surrounding areas of fibriling and fragmentation (Outerbridge grades 3 to 4).

TABLE 5  
Outcome Scores<sup>a</sup>

Patient	Treatment	Follow	SST		ASES		VAS		SF-12 Physical		SF-12 Mental	
		Yr	Preop	Follow	Preop	Follow	Preop	Follow	Preop	Follow	Preop	Follow
5	HHA/LMI	2.1	6	5	36	32	8	7	43	42	38	28
6	HHA/LMI	2.2	5	8	65	63	2	2	34	44	63	59
9	HHA/LMI	1.9	4	6	40	48	5	4	48	47	55	26
10	MFx HH	4.7	9	11	68	90	4	1	47	42	59	64
17	ACI HH	2.1	5	11	38	80	5	1	33	39	53	58
18	HHA/LMI	2.6	9	12	75	92	2	1	35	45	64	62
19	HHA	2.7	6	12	42	78	7	4	43	44	48	56
20	ACI HH	6.5	10	12	45	83	7	2	35	46	48	55
	Average	3.1	7	10	51	71	5	3	40	44	54	51
	<i>P</i>			.009		.018		.008		.124		.596

<sup>a</sup>SST, Simple Shoulder Test; ASES, American Shoulder and Elbow Surgeons scale; VAS, visual analog scale for pain; SF-12, Short Form 12; preop, preoperative score obtained at referral visit; follow, most recent follow-up; HHA, humeral head allograft; LMI, lateral meniscus interposition; Mfx HH, microfracture of the humeral head; ACI HH, autologous chondrocyte implantation to the humeral head.

12 physical and mental component scores were not significant (Table 5).

Additional surgeries were required in 2 patients. One patient with a humeral head allograft and lateral meniscus interposition underwent a capsular release and debridement at 16 months due to significant arthrofibrosis. Preoperatively, he had forward flexion to 90°, external rotation to 20°, and internal rotation to the greater trochanter. He was found to have further glenoid erosion and collapse of the humeral head allograft with prominence of the compression screws. The treatment of another patient receiving a bulk humeral head allograft and lateral meniscus interposition clinically failed and was thus revised to a total shoulder arthroplasty at 15 months after biological resurfacing. Postbiological resurfacing range of motion at 12 months was 155° of forward flexion, external rotation to 40°, and internal rotation to L5. However, the patient described significant pain refractory to nonsteroidal anti-inflammatory drugs therapy and corticosteroid injection.

## DISCUSSION

The goal of this study was to define a cohort of referrals (ie, a young group of patients) whose initial surgical intervention potentially contributed to advanced glenohumeral degenerative changes. A majority of the patients (67%) in the initial referral pool had a traumatic injury to the shoulder with or without multiple dislocations. The entity of dislocation arthropathy is well described, with estimated risks of 9.2% and 19.7% preintervention and postsurgical intervention.<sup>2,28</sup> The present investigation cannot define the total population of patients from which the cohort is drawn; therefore, no incidence can be defined.

This patient set lacks many predisposing factors for arthritic changes—older age, multiple dislocations, and increased time to surgery.<sup>4</sup> In general, this patient population would not otherwise elicit a high index of suspicion for arthritic complications.

In narrowing the scope of this case series, individuals with preexisting arthritic changes were eliminated, in addition to those with traumatic intra-articular fractures, neuropathy, and postoperative infection. Existing intra-articular pathologic lesions represent an abnormal biochemical environment and so confound the analysis of the contribution of operative factors to the progression of arthritis. Chu et al<sup>5</sup> have demonstrated that an intact articular surface conveys partial chondroprotection during continuous exposure to bupivacaine. Three patients with postoperative pain pumps had small Hill-Sachs lesions (< 5 × 10 mm) that could have served as a nidus for further damage.

The role of intra-articular catheters and pumps in pain management after shoulder surgery has not been substantiated, and complications have been reported, such as breakage requiring reoperation.<sup>11,24</sup> Recently, Hansen et al<sup>10</sup> reported intra-articular pain pump use as the only common factor in 12 patients developing postarthroscopic chondrolysis. Similarly, 16 young adults of this cohort had bupivacaine pain pumps and noted a return of symptoms at approximately 6 months postoperatively. At this point of recovery, most protective limitations are removed, and physical therapy or training progresses. The damage—chondrocyte death—likely occurred with exposure to bupivacaine, as has been demonstrated in vitro with as little as 15 minutes of exposure. Regarding osteochondral cores, Chu et al<sup>5</sup> noted that 42% of chondrocytes were dead after exposure to 0.5% bupivacaine, which increased to 75% when articular surface was disrupted. Decreased cell viability and sulfate uptake have been demonstrated in rabbit humeral cartilage after continuous infusion of bupivacaine, with and without epinephrine.<sup>8</sup> The anabolic-catabolic balance of the cartilage is disrupted in favor of catabolism, thereby resulting in the accumulation of chondral damage. Interestingly, the average age of Hansen and colleagues' chondrolysis patients<sup>10</sup> was more than 10 years greater than that of the 16 reported here. The age difference might represent an inherent difference in the client



and referral bases of the authors. However, the difference adds a layer of complexity to the treatment algorithm; that is, our patients are not considered to be good candidates for hemi-shoulder or total shoulder arthroplasty.

Instability repair, especially of the labrum, often necessitates the use of suture anchors to reattach structures to bone. Hardware complications—categorized as incorrect placement, migration, loosening, and breakage—are estimated to cause significant cartilage damage in 40% of cases.<sup>13,30</sup> The 2 patients herein had loosening of 1 or more of their anchors, thereby resulting in prominence within the glenohumeral joint. In both cases, massive damage to the humeral head was incurred, possibly due to direct contact with the jutting metal surface. Damage to the glenoid was less severe, a secondary effect of articulating with the uneven, damaged surface of the humeral head.

Overtightening and tissue ablation are potential complications of radiofrequency use for capsulorrhaphy.<sup>22,25,29</sup> In addition, direct probe application and contact with heated lavage fluid have been demonstrated to decrease the metabolic activity or kill chondrocytes.<sup>14,17,27</sup> Isolated cases of chondrolysis attributed to extensive radiofrequency ablation report a return of symptoms between 1 and 12 months after treatment.<sup>9,12,16,23</sup> A female patient in this cohort demonstrated recurrent instability, possibly resulting from ablation of part of the anterior capsule. However, a male patient had returned stability and no complaints of decreased range of motion (especially, external rotation), which would point toward thermal injury over mechanical alterations due to ablation or overtightening. In both cases, a bipolar radiofrequency device was applied, which has been demonstrated in vitro to cause more chondrocyte death than monopolar devices.<sup>18</sup>

This set of patients represents a particularly challenging clinical scenario. Despite the multiple causes discussed, the resultant lesions compromised a significant percentage of the humeral head and/or glenoid. In an older patient, total shoulder arthroplasty would be an acceptable treatment modality; however, complications with polyethylene wear particles, osteolysis, and loosening result in this being an unfavorable option for younger patients.<sup>21</sup> A majority of this cohort had failed initial palliative treatment (capsular release or manipulation), as described in McCarty and Cole's algorithm<sup>19</sup> for nonarthroplasty treatment of glenohumeral lesions, and so required restorative or reconstructive methods. Especially in a referral population, adequate assessment of the glenohumeral cartilage, capsule, and hardware is essential. At the time of diagnostic arthroscopy, capsular release and debridement were undertaken for evidence of contracture and chondral flaps, respectively. These temporizing measures provide symptomatic relief during the planning of further definitive intervention.<sup>3</sup> Although autologous chondrocyte implantation has demonstrated favorable results in the knee, its application to the humeral head is novel and off-label.<sup>26</sup> However, this treatment was selected for several patients with large irregular lesions that did not extend into the subchondral bone. The most common modality in this series was a humeral head allograft and lateral meniscus interposition. Humeral head allografts were amenable to

large defects and lesions with evidence of subchondral sclerosis or loss. Placement of a lateral meniscus glenoid component reduces the total force to the glenoid surface, potentially increasing the life span of the reconstruction.<sup>7</sup> More important, this salvage procedure replicates glenohumeral architecture without eliminating the possibility of future arthroplasty. Given the recent implementation of this technique, the long-term outcomes and durability have yet to be elucidated, and additional studies are needed to delineate efficacy of surgical treatment in this challenging cohort of patients.

## ACKNOWLEDGMENT

This publication was made possible by T32 AR052272 from the National Institute of Arthritis and Musculoskeletal and Skin Diseases (NIAMS)/National Institute of Health (NIH) (A.G.M.).

## REFERENCES

- Burkhead WZ Jr, Hutton KS. Biologic resurfacing of the glenoid with hemiarthroplasty of the shoulder. *J Shoulder Elbow Surg.* 1995;4:263-270.
- Buscayret F, Edwards TB, Szabo I, Adeleine P, Coudane H, Walch G. Glenohumeral arthrosis in anterior instability before and after surgical treatment: incidence and contributing factors. *Am J Sports Med.* 2004;32:1165-1172.
- Cameron BD, Galatz LM, Ramsey ML, Williams GR, Iannotti JP. Non-prosthetic management of grade IV osteochondral lesions of the glenohumeral joint. *J Shoulder Elbow Surg.* 2002;11:25-32.
- Cameron ML, Kocher MS, Briggs KK, Horan MP, Hawkins RJ. The prevalence of glenohumeral osteoarthritis in unstable shoulders. *Am J Sports Med.* 2003;31:53-55.
- Chu CR, Izzo NJ, Pappas NE, Fu FH. In vitro exposure to 0.5% bupivacaine is cytotoxic to bovine articular chondrocytes. *Arthroscopy.* 2006;22:693-699.
- Cole BJ, Yanke A, Provencher MT. Nonarthroplasty alternatives for the treatment of glenohumeral arthritis. *J Shoulder Elbow Surg.* 2007;16(5)(suppl):S231-S240.
- Creighton RA, Cole BJ, Nicholson GP, Romeo AA, Lorenz EP. Effect of lateral meniscus allograft on shoulder articular contact areas and pressures. *J Shoulder Elbow Surg.* 2007;16:367-372.
- Gomoll AH, Kang RW, Williams JM, Bach BR, Cole BJ. Chondrolysis after continuous intra-articular bupivacaine infusion: an experimental model investigating chondrotoxicity in the rabbit shoulder. *Arthroscopy.* 2006;22:813-819.
- Good CR, Shindle MK, Kelly BT, Wanich T, Warren RF. Glenohumeral chondrolysis after shoulder arthroscopy with thermal capsulorrhaphy. *Arthroscopy.* 2007;23:797, e791-e795.
- Hansen BP, Beck CL, Beck EP, Townsley RW. Postarthroscopic glenohumeral chondrolysis. *Am J Sports Med.* 2007;35:1628-1634.
- Holmes TT, Buzzell JE, Dunn WR, Kuhn JE. Intra-articular pain pump catheter breakage after arthroscopic shoulder surgery: a case series. *J Shoulder Elbow Surg.* 2007;16(6):e6-e9.
- Jerosch J, Aldawoudy AM. Chondrolysis of the glenohumeral joint following arthroscopic capsular release for adhesive capsulitis: a case report. *Knee Surg Sports Traumatol Arthrosc.* 2007;15:292-294.
- Kaar TK, Schenck RC Jr, Wirth MA, Rockwood CA Jr. Complications of metallic suture anchors in shoulder surgery: a report of 8 cases. *Arthroscopy.* 2001;17:31-37.
- Kaplan LD, Chu CR, Bradley JP, Fu FH, Studer RK. Recovery of chondrocyte metabolic activity after thermal exposure. *Am J Sports Med.* 2003;31:392-398.



15. Karpie JC, Chu CR. Lidocaine exhibits dose- and time-dependent cytotoxic effects on bovine articular chondrocytes in vitro. *Am J Sports Med.* 2007;35:1621-1627.
16. Levine WN, Clark AM Jr, D'Alessandro DF, Yamaguchi K. Chondrolysis following arthroscopic thermal capsulorrhaphy to treat shoulder instability: a report of two cases. *J Bone Joint Surg Am.* 2005;87:616-621.
17. Lu Y, Edwards RB III, Nho S, Cole BJ, Markel MD. Lavage solution temperature influences depth of chondrocyte death and surface contouring during thermal chondroplasty with temperature-controlled monopolar radiofrequency energy. *Am J Sports Med.* 2002;30:667-673.
18. Lu Y, Edwards RB III, Nho S, Heiner JP, Cole BJ, Markel MD. Thermal chondroplasty with bipolar and monopolar radiofrequency energy: effect of treatment time on chondrocyte death and surface contouring. *Arthroscopy.* 2002;18:779-788.
19. McCarty LP III, Cole BJ. Nonarthroplasty treatment of glenohumeral cartilage lesions. *Arthroscopy.* 2005;21:1131-1142.
20. McCarty LP III, Cole BJ. Reconstruction of the glenohumeral joint using a lateral meniscal allograft to the glenoid and osteoarticular humeral head allograft after bipolar chondrolysis. *J Shoulder Elbow Surg.* 2007;16(6):e20-e24.
21. Nicholson GP, Goldstein JL, Romeo AA, et al. Lateral meniscus allograft biologic glenoid arthroplasty in total shoulder arthroplasty for young shoulders with degenerative joint disease. *J Shoulder Elbow Surg.* 2007;16(5)(suppl):S261-S266.
22. Park HB, Yokota A, Gill HS, El Rassi G, McFarland EG. Revision surgery for failed thermal capsulorrhaphy. *Am J Sports Med.* 2005;33:1321-1326.
23. Petty DH, Jazrawi LM, Estrada LS, Andrews JR. Glenohumeral chondrolysis after shoulder arthroscopy: case reports and review of the literature. *Am J Sports Med.* 2004;32:509-515.
24. Quick DC, Guanche CA. Evaluation of an anesthetic pump for postoperative care after shoulder surgery. *J Shoulder Elbow Surg.* 2003;12:618-621.
25. Rath E, Richmond JC. Capsular disruption as a complication of thermal alteration of the glenohumeral capsule. *Arthroscopy.* 2001;17(3):E10.
26. Romeo AA, Cole BJ, Mazzocca AD, Fox JA, Freeman KB, Joy E. Autologous chondrocyte repair of an articular defect in the humeral head. *Arthroscopy.* 2002;18:925-929.
27. Ryan A, Bertone AL, Kaeding CC, Backstrom KC, Weisbrode SE. The effects of radiofrequency energy treatment on chondrocytes and matrix of fibrillated articular cartilage. *Am J Sports Med.* 2003;31:386-391.
28. Samilson RL, Prieto V. Dislocation arthropathy of the shoulder. *J Bone Joint Surg Am.* 1983;65:456-460.
29. Wong KL, Williams GR. Complications of thermal capsulorrhaphy of the shoulder. *J Bone Joint Surg Am.* 2001;83(suppl 2, pt 2):151-155.
30. Zuckerman JD, Matsen FA III. Complications about the glenohumeral joint related to the use of screws and staples. *J Bone Joint Surg Am.* 1984;66:175-180.

---

For reprints and permission queries, please visit SAGE's Web site at <http://www.sagepub.com/journalsPermissions.nav>