

## CHAPTER 9

# c0009 Preserving the Articulating Surface of the Knee

BRYAN M. SALTZMAN, MD • DAVID R. CHRISTIAN, BS •  
MICHAEL L. REDONDO, MA, BS • BRIAN J. COLE, MD, MBA

### s0010 INTRODUCTION

p0010 Hyaline articular cartilage plays an integral role in the function of the knee joint. Isolated chondral lesions are incompletely understood, but once damaged, there is very little capacity for spontaneous healing due to intrinsically poor blood supply (Fig. 9.1). Thus, the risk of patient pain, effusions, mechanical symptoms, decreased activity and quality of life, and the possibility of progression to diffuse osteoarthritis (OA) remain a concern.<sup>1,2</sup> Between 30,000 and 100,000 chondral procedures are performed annually in the United States,<sup>3</sup> and an annual incidence growth of 5% has been reported.<sup>4</sup> The lesions are most commonly found in the medial compartment, followed by the patellofemoral compartment,<sup>5</sup> and have been theorized to occur in approximately 12% of the population.<sup>6,7</sup>

p0015 Numerous surgical interventions have been developed and refined over the last few decades in an attempt to preserve the articular surface of the knee. Conservative treatment options have more recently focused attention on injectable biologics in an effort to stimulate the body's natural resources and create an intraarticular milieu suitable for healing. Reparative marrow-stimulation techniques—most notably microfracture—can be used at the site of a chondral defect in an attempt to induce fibrocartilage repair tissue formation after penetration of the subchondral bone.<sup>8,9</sup> Restorative cartilage procedures (mosaicplasty, osteochondral allograft/autograft, particulated juvenile cartilage graft, autologous chondrocyte implantation [ACI]), by contrast, replace the native defect site with host or donor articular hyaline cartilage. These latter options have garnered more attention in the last decade as advanced efforts to provide pain relief, alter arthritic progression patterns, and hopefully delay or avoid arthroplasty.<sup>4</sup>

p0020 Generally, varying specifications for use exists for each of the aforementioned procedures. However, no unified consensus exists on which cartilage repair or restoration technique exhibits the most successful

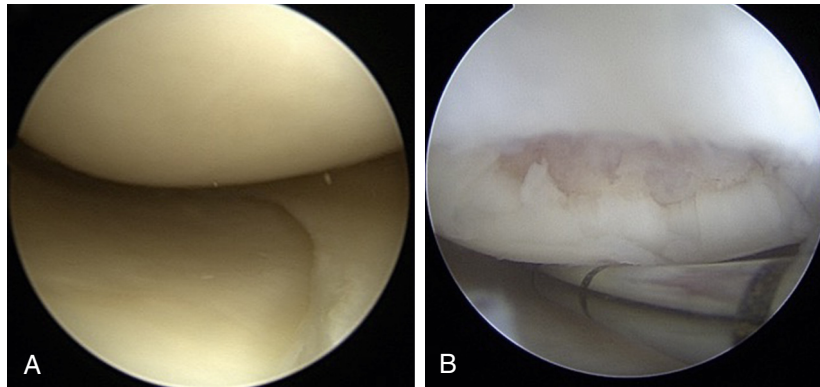
long-term clinical outcomes. This chapter focuses on the basic science of cartilage structure, discusses the aforementioned surgical and nonsurgical preservation techniques for the articular cartilage of the knee joint, and highlights expected future directions of study in the topic of surface cartilage defect treatment.

### BASICS OF CARTILAGE STRUCTURE

Cartilage is present in various parts of the human body and it is categorized into three different types: fibrocartilage, elastic cartilage, and hyaline cartilage. Each type has a unique function, structure, and composition. Hyaline cartilage, also known as articular cartilage, covers the articular surfaces between bones to provide a load-supporting, low-friction interface. This type of cartilage has low cell density and low proliferative activity and is avascular in nature, which makes innate regeneration nearly impossible.

Hyaline cartilage is primarily composed of water, chondrocytes, and an extracellular matrix (ECM). Chondrocytes are the cellular component of this type of cartilage and are highly differentiated cells with low proliferative activity. They are found in low abundance—only 1%–5% of cartilage by volume—but have high metabolic activity because they are responsible for maintaining homeostasis within the elaborate ECM.<sup>10</sup> Mature chondrocytes lack cell–cell interactions and are instead surrounded by a pericellular matrix that extends radially from the cell surface. Chondrocyte function is affected by the surrounding environment including factors such as the compressive load within a joint, a phenomenon referred to as mechanotransduction.<sup>11</sup> The ECM is composed of water and molecules including collagen, proteoglycans, and superficial zone protein. Water is the largest component of articular cartilage, responsible for 70%–80% by weight, and interacts with the extracellular components through its polar molecular structure to provide unique biomechanical properties.<sup>10</sup>

2 SECTION III Clinical Applications in Sports Medicine



f0010

**FIG. 9.1 Articular Cartilage.** (A) Intraoperative arthroscopic images of healthy, normal knee cartilage of the femur (superior) and tibia (inferior) with normal meniscus visible (right) compared with (B) International Cartilage Restoration Society (ICRS) grade IV focal chondral defect of the femoral condyle.

p0035 There are more than 28 types of collagen identified within the human body. Type II collagen is the most prevalent type within hyaline cartilage and comprises approximately 50% of its dry weight. It is also a major component of the ECM. All types of collagen share a central core composed mostly of glycine, proline, and hydroxyproline causing the formation of a left-handed helix.<sup>12</sup> These individual helices further assemble into right-handed triple helix microfibrils that form larger fibrils through end-to-end fusion and lateral bundling.<sup>12</sup> These collagen fibrils are then arranged in different orientations in relation to the articular surface depending on their depth within the hyaline cartilage structure, and they provide stiffness to the tissue allowing it to bear weight.

p0040 The articular cartilage ECM also contains other molecules, the most prevalent of which are proteoglycans consisting of a protein core and many polysaccharides (primarily glycosaminoglycans [GAGs]) extending perpendicularly. GAGs are linear polysaccharides composed of repeating disaccharide units. The most common GAGs in hyaline cartilage are hyaluronan, dermatan sulfate, keratan sulfate, chondroitin 6-sulfate, and chondroitin 4-sulfate.<sup>10</sup> Hyaluronan is unique in that it is the largest GAG, does not carry a negative charge, and is able to bind strongly with aggrecan—the main proteoglycan found in articular cartilage. The strong binding between hyaluronan and aggrecan results in the formation of large proteoglycan aggregates, and a fixed negative charge within the ECM causes a significant osmotic pressure in the cartilage's interaction with synovial fluid.<sup>10</sup> The end result is significant accumulation of fluid and swelling, known as

the Donnan effect, that works with the collagen structure to produce the weight-bearing capability of articular cartilage.<sup>13</sup>

Synovial fluid directly plays an important role in maintaining the articular cartilage. Synovial fluid is composed of protein-rich plasma ultrafiltrate and hyaluronan.<sup>10</sup> As cartilage is avascular, the synovial fluid is responsible for providing nutrients through simple diffusion and compression–relaxation cycles during weight-bearing. It also contains a protein called “superficial zone protein”—or lubricin—which is also present on the surface of hyaline cartilage and contributes to the lubrication and ease of joint movement.<sup>10</sup> Additionally, synovial fluid contributes to the load-bearing capacity by increasing its viscosity in response to pressure.

Articular cartilage is divided based on depth and composition into four structural zones: the superficial zone, the middle or transitional zone, the deep or radial zone, and the calcified zone.<sup>10</sup> The outermost layer of cartilage is covered by the *lamina splendens*, which is a layer of proteins thought to be produced by the accumulation of proteins from synovial fluid that acts as a protective, low-friction layer for the cartilage.<sup>14</sup> Immediately deep to that is the superficial layer of cartilage, which is densely packed with collagen fibers oriented parallel to the articulating surface and with a low concentration of proteoglycans.<sup>10</sup> Chondrocytes in the superficial layer are flat in shape and also oriented parallel to the articulating surface. They produce proteins to lubricate the articular surface such as lubricin, which are not present in deeper zones.<sup>10</sup> The middle zone is responsible for 40%–60% of cartilage thickness and has the highest concentration of proteoglycans. It has low

p0045

p0050

cellular density, and its most prevalent ECM component is type II collagen arranged in arches.<sup>15</sup> The chondrocytes here are round and produce a large amount of type II collagen and proteoglycans, specifically aggrecan. The deep zone has a lower cell density than the superficial or middle zones and contains type II collagen fibers oriented perpendicular to both the subchondral bone and articular surface. The chondrocytes in the deep zone appear elongated and are oriented parallel to the collagen fibers.<sup>10</sup> Finally, the calcified zone contains hydroxyapatite and acts as a transitional zone between the cartilage and subchondral bone.<sup>10</sup>

p0055

Injury to the articular surface can occur secondary to trauma of the joint causing disruption of the cartilage and formation of a focal chondral defect. The deeper cartilage layers, or possibly the subchondral bone, become exposed leading to pain, stiffness, and loss of function. If left untreated, focal chondral defects can progress to OA over time due to further degeneration of the surrounding cartilage. OA is caused by a combination of degenerative and abnormal remodeling processes within the cartilage in response to repetitive stress. Cartilage has low proliferative capacity making these processes nearly irreversible. Changes in the ECM begin in the superficial zone with the appearance of erosions, fissures, and fibrillation. The disruption of the collagen network results in a loss of proteoglycans that eventually inhibits its biomechanical function. The innate type II cartilage shows decreased fiber diameter while the type I cartilage concentration increases, representing the formation of fibrocartilage. Fragmentation continues until the subchondral bone becomes exposed, which allows direct force to be applied to the bone causing remodeling and thickening. Chondrocytes also undergo a series of changes during the development of OA including proliferation and pericellular matrix remodeling.<sup>10</sup> Eventually, the chondrocytes die and release necrosis factors that induce apoptosis of surrounding chondrocytes. This leads to further degradation of the cartilage structure and eventual exposure of the subchondral bone.

## s0020 ORTHOBIOLOGIC INJECTIONS

### s0025 Hyaluronic Acid

p0060

Hyaluronic acid (HA) is naturally present throughout the human body but specifically is found within articular cartilage and synovial fluid. As OA progresses, the synovial fluid shifts toward lower-molecular-weight HA, leading to a decrease in its viscoelastic properties. Lower-molecular-weight HA is also strongly associated with higher levels of pain. Intraarticular HA injections

have been used for many years as a treatment for OA directed at replenishing the concentration of HA and increasing the average molecular weight.

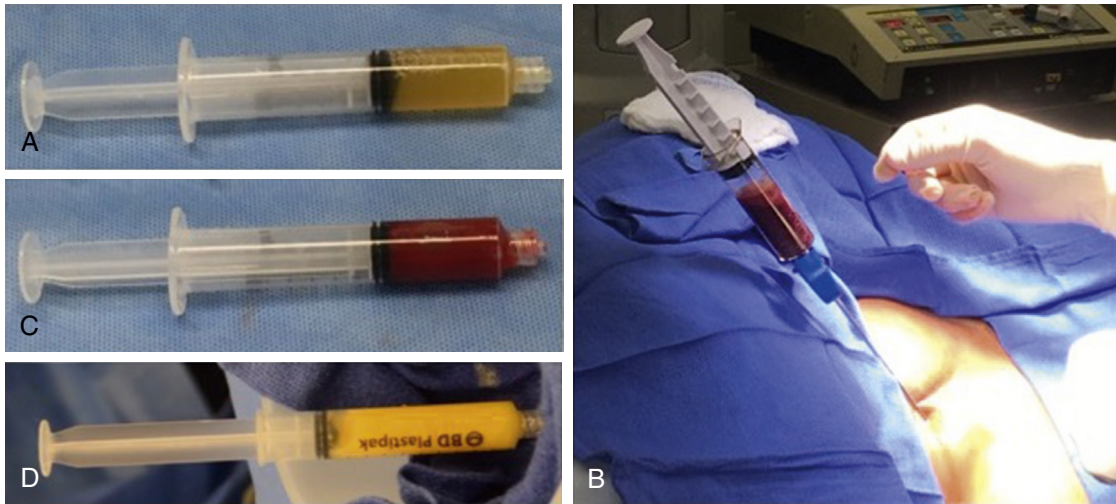
Intraarticular HA injections are most commonly believed to reduce symptoms of OA through mechanisms of chondroprotection.<sup>16</sup> Within the joint, HA binds to cluster of differentiation 44 (CD44) and inhibits the expression of interleukin (IL)-1 $\beta$ , consequently inhibiting the synthesis of matrix metalloproteinases that have catabolic enzymatic activity toward collagen fibers causing the destruction of articular cartilage. The HA-CD44 binding pathway also augments chondroprotection through decreased apoptosis of chondrocytes, allowing preserved synthesis of the cartilage ECM and slowed degeneration. The current literature suggests that higher-molecular-weight HA is more effective at inducing these mechanisms of chondroprotection than lower-molecular-weight HA.<sup>16</sup> Additionally, intraarticular HA injections have been shown to increase the synthesis and impair the degradation of aggrecan, thus slowing the progression of OA. Many studies have also suggested an anti-inflammatory effect through decreased synthesis of IL-8, IL-6, prostaglandin-E<sub>2</sub> (PGE<sub>2</sub>), and tumor necrosis factor- $\alpha$  (TNF $\alpha$ ), in addition to the decrease in IL-1 $\beta$ . Some studies suggest a mechanical mechanism of action by increasing the viscosity of synovial fluid, which provides increased lubrication of the articular surface, and shock absorption.<sup>16</sup> Few studies have reported that HA decreases the extent of subchondral bone changes in addition to functioning as an analgesic.

p0065

Intraarticular HA injections have shown variable outcomes in the current medical literature. Several studies and metaanalyses report statistically significant improvement in pain and function scores in patients with OA receiving HA injections while others suggest no difference between treatment and placebo. Also highly debated is whether the observed statistical difference is clinically relevant, as often times it has not exceeded the minimum clinically important difference (MCID).<sup>17</sup> The efficacy of high-molecular-weight HA versus low-molecular-weight HA for treatment of OA has been discussed with some reports suggesting improved pain reduction with high-molecular-weight HA while others report no difference at all. While these studies have investigated the short-term benefit, recent literature suggests no difference in time to knee surgery or arthroplasty in patients receiving low-, medium-, or high-molecular-weight HA.<sup>18</sup> Owing to the variable results in the medical literature, the current American Academy of Orthopaedic Surgeons (AAOS) guidelines

p0070

4 SECTION III Clinical Applications in Sports Medicine



f0015

**FIG. 9.2 Orthobiologic Injections.** (A) 10 cc syringe containing approximately 5 cc of platelet-rich plasma (PRP) isolated from a venous blood sample. (B) Bone marrow aspiration from the right iliac crest. (C) 10 cc syringe containing approximately 5 cc of bone marrow aspirate concentrate (BMAC) prepared after centrifugation of bone marrow aspirate (BMA). (D) 10 cc syringe containing approximately 8 cc of adipose tissue and adipose-derived stem cell prepared from adipose tissue collected during liposuction.

state that a recommendation cannot be made for the use of intraarticular HA injections for OA.

s0030 **Platelet-Rich Plasma**

p0075 Platelet-rich plasma (PRP) is plasma containing supraphysiologic levels of platelets and platelet-derived growth factors used as a therapeutic modality for treatment of symptomatic cartilage defects and OA. PRP is produced from a patient's venous blood that has been centrifuged to isolate the platelets, plasma, and growth factors (Fig. 9.2). Platelets produce  $\alpha$  granules, which contain many growth factors including transforming growth factor- $\beta$  (TGF- $\beta$ ), fibroblast growth factor (FGF), and platelet-derived growth factor (PDGF).<sup>19</sup> These growth factors have been found to be involved in tissue repair, and the goal is that PRP injections in theory could contribute to cartilage regeneration.

p0080 Recent in vitro and in vivo studies have shown that PRP functions by inducing cartilage regeneration and decreasing inflammation. Chondrocytes treated in vitro with PRP have shown increased proliferation and increased synthesis of type II collagen and GAGs.<sup>20</sup> Additionally, in vitro studies have shown that PRP inhibits nuclear factor- $\kappa$ B (NF- $\kappa$ B), which is a transcription factor for the expression of proinflammatory and catabolic cytokines IL-1 $\beta$  and

TNF $\alpha$ .<sup>20</sup> In vivo, synovial fluid samples aspirated at 12 and 24 months after PRP injections trended toward decreased levels of IL-1 $\beta$  and TNF $\alpha$ , although the difference compared with treatment with HA was not statistically significant.<sup>21</sup>

The existing literature varies in terms of PRP preparation technique, platelet concentration, white blood cell concentration, amount injected into the joint, and presence of an activating agent such as calcium chloride. The therapeutic range for platelet concentration is thought to be between two and six times higher than physiologic levels.<sup>20</sup> A recent systematic review of six level I studies found significant improvement in clinical outcomes and Western Ontario and McMaster Universities Osteoarthritis Index (WOMAC) scores on OA patients treated with PRP when compared with HA at 3–12 months after injection.<sup>22</sup> Very few studies have investigated outcomes past 1 year, but the available data suggest a decline in outcomes between 1 and 2 years after injection.<sup>20</sup> The nuances of ideal PRP preparation to help maximize efficacy have begun to be elucidated in recent years, however. A systematic review of nine level I and level II studies that differentiated between leukocyte-rich and leukocyte-poor PRP found significant improvement in OA patients treated with leukocyte-poor PRP compared with HA or placebo but not

p0085

with leukocyte-rich PRP. These data support the need for standardization of PRP preparations in order to maximize efficacy in all patients.<sup>23</sup>

s0035 **Bone Marrow-Derived Stem Cells**

p0090 Mesenchymal stem cells (MSCs) have been of great interest for use in cartilage restoration and repair owing to their inherent regenerative potential. Bone marrow aspiration (BMA) has become one of the preferred techniques of acquiring MSCs, but stem cells only account for 0.001%–0.01% of nucleated cells in bone marrow.<sup>24</sup> It is typically concentrated, usually through centrifugation, to produce bone marrow aspirate concentrate (BMAC) with higher concentrations of MSCs. Once concentrated, BMAC is then injected into the joint of interest either as an isolated treatment or augmentation to surgical treatment.

p0095 In addition to MSCs, bone marrow also contains high levels of growth factors and cytokines including vascular endothelial growth factor (VEGF), PDGF, TGF- $\beta$ , and bone morphogenic protein 2 and 7 (BMP-2, BMP-7), which are known to have anabolic and anti-inflammatory effects.<sup>25</sup> Although PRP contains these same growth factors, BMAC has significantly higher concentrations.<sup>26</sup> This mixture of growth factors has been identified to play a variety of roles in the cartilage regeneration capabilities of BMAC. VEGF and PDGF both promote angiogenesis, which increases the blood supply to the subchondral bone and normally avascular cartilage to promote regeneration.<sup>26</sup> TGF- $\beta$  and BMP both play a role in the chondrogenic differentiation of MSCs, which then synthesize type II collagen and GAGs.<sup>26</sup> Collectively, the MSCs and accompanying molecules promote cartilage regeneration at the articular surface.

p0100 The results of intraarticular BMAC joint injections are promising both as an isolated treatment and as augmentation to procedures such as osteochondral collagen scaffolds. When compared with matrix induced chondrocyte implantation (MACI) for patellofemoral chondral lesions, significant improvement was seen in both groups, but MACI outcomes declined between years 1 and 2 whereas BMAC outcomes continued to improve.<sup>27</sup> Additionally, chondral lesions treated with BMAC showed complete coverage in 80% of patients.<sup>25</sup> When used in conjunction with collagen scaffolds to treat chondral defects, the repaired lesions showed better tissue similarity to surrounding hyaline cartilage by both magnetic resonance imaging (MRI) and histology compared with controls.<sup>25,28</sup> As a whole, the existing literature suggests that the

treatment of chondral lesions with MSCs in BMAC provides good outcomes as either an isolated or combined treatment.

**Adipose-Derived Mesenchymal Stem Cells**

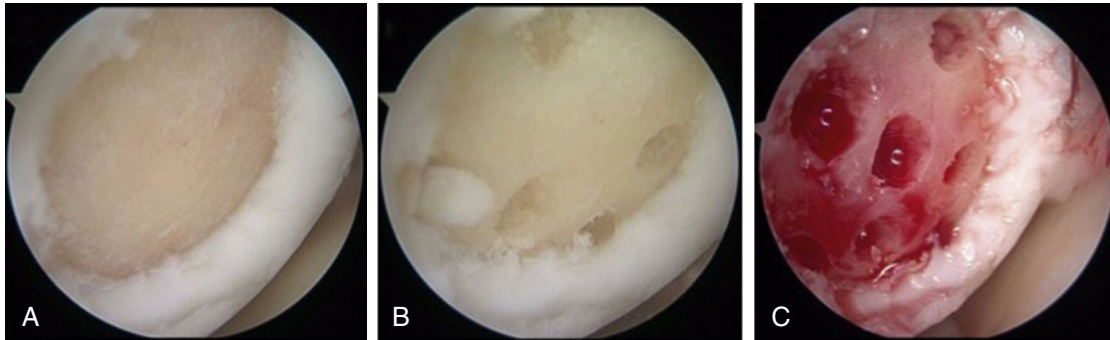
Adipose tissue also contains MSCs termed adipose-derived mesenchymal stem cells (ASCs), which were first described in 2001.<sup>29</sup> These cells have been found to have endodermal, mesodermal, and ectodermal proliferative potential, making them a great candidate to aid in cartilage restoration. ASCs are obtained via liposuction, and the adipose sample is then purified to isolate the stem cells. The stem cell concentration has typically been found to be significantly higher than that of BMAC.<sup>29</sup>

Similar to both PRP and BMAC, ASCs have been shown in vitro and in animal studies to have anti-inflammatory and chondroprotective characteristics.<sup>30,31</sup> The exact mechanism has not been elucidated, but they appear to be activated by inflammation and in part modulate inflammation and cartilage remodeling through prostaglandin E2 (PGE<sub>2</sub>).<sup>30,31</sup> The initial results of treating chondral defects with ASCs have been promising in relation to both clinical symptoms and lesion appearance. The first randomized control trial performed by Jo et al. found that intraarticular ASC injections in OA patients provide significant clinical improvement and cartilage regeneration observed by both MRI and second-look arthroscopy.<sup>32</sup> There also appears to be a dose-dependent effect for ASCs that will be critical, as its preparation becomes standardized.<sup>33</sup> Further investigation is needed to determine the long-term outcomes, but intraarticular ASCs provide a promising therapeutic avenue for symptomatic chondral lesions and OA.

**MARROW STIMULATION/MICROFRACTURE**

Microfracture (MFX) is a common surgical procedure used in the treatment of focal chondral defects of the knee (Fig. 9.3). The technique relies on marrow stimulation from the subchondral bone allowing the recruitment of MSCs for the formation of fibrocartilage repair.<sup>34</sup> However, the outcomes of MFX surgery have been variable. Short-term clinical outcomes (<24 months) for MFX surgeries have been shown to have a high efficacy for small chondral lesions regardless of whether traumatic or degenerative etiology.<sup>35,36</sup> A seminal systematic review including 3122 patients by Mithoefer et al. demonstrated that the average knee function scores remained above the preoperative level and that the short-term clinical improvement rate of MFX surgeries was 75%–100%.<sup>37</sup>

6 SECTION III Clinical Applications in Sports Medicine



f0020

**FIG. 9.3 Microfracture Surgery.** Intraoperative arthroscopic photographs of a right knee medial femoral condyle focal chondral defect (A) treated with microfracture surgery (B), (C).

However, these same authors also demonstrated that the long-term outcomes of MFX showed reduced durability over time. After 24 months postoperatively, 47%–80% of MFX patients reported functional decline from their original improvements.<sup>37</sup> Moreover, 67%–86% of subjects reported a decline in long-term improvement rate after 24 months.<sup>37</sup> In another review by Steinwachs et al., this decline in long-term clinical outcomes occurred even sooner (18 months postoperatively) in older patients and in patients with larger defects (>2.5 cm<sup>2</sup>).<sup>38</sup>

p0120

Long-term outcomes in high activity level patients, such as athletes, have also been questionable. A prospective study by Gobbi et al. followed athletes in order to measure their improvement after MFX.<sup>39</sup> The participants demonstrated an improved Tegner activity scale at 2 years postoperatively, yet 80% of the athletes in the study progressively declined in sport activity at final follow-up.<sup>39</sup> In two studies following National Basketball Association (NBA) patients who underwent MFX, a significant correlation was observed between MFX and decreased minutes per game, decreased player efficiency rating, or points per game.<sup>40,41</sup> More importantly, 21% of the NBA players treated with MFX did not return to professional competition in the NBA.<sup>40</sup> The predominant causal factors for poor long-term clinical outcome include inadequate clot stability and the concept that fibrocartilage is not the ideal replacement for defects in the articular cartilage, as it by comparison is soft and has a decreased ability to tolerate with shear stresses. Ultimately, this decreases the longevity and the outcomes seen with the MFX technique.<sup>42</sup>

p0125

Recently, new innovations in augmentation strategies for MFX have been developed. A current advancement in MFX augmentation includes fixation of a collagen synthetic matrix over the drilled subchondral bone to act as an exogenous scaffold. The MSCs brought to the surface by MFX drilling interact with

the collagen scaffold enhancing clot stability and MSC adhesion, organization, and differentiation into chondrocytes.<sup>42</sup> The collagen-based scaffold's intent is to promote and maintain the chondrocytic phenotype and type II collagen synthesis to ultimately fill the defect with regenerated natural hyaline-like cartilage.<sup>43</sup> These MFX augmentation techniques seek to use potential autologous sources of cartilage regeneration in a fast, one-step, inexpensive procedure.<sup>44</sup>

p0130

Most of the collagen scaffold augmentations of MFX provide equal or better short-term clinical outcomes when compared with MFX alone.<sup>44–46</sup> Autologous matrix induced chondrogenesis (AMIC; ChondroGide), the arguably most well-studied collagen scaffold worldwide, uses a collagen type-III/I matrix bilayer matrix to serve as its natural scaffold.<sup>42</sup> AMIC short-term outcomes at follow-up of 1 and 2 years have been demonstrated to be as effective as MFX.<sup>47</sup> In a prospective randomized-controlled study by Anders et al., patients with a mean defect size of 3.4 cm<sup>2</sup> were randomized and treated either with MFX alone or an AMIC technique.<sup>48</sup> Clinical outcomes (modified Cincinnati and International Cartilage Restoration Society [ICRS] score) were evaluated in 30 patients at 1 year and 27 patients at 2 years postoperatively. Clinical outcomes were significantly improved at 1 and 2 years postoperatively for all techniques used with no statistical difference between the techniques.<sup>48</sup> However, AMIC has also exhibited promise in eliminating the two major weaknesses of MFX: long-term clinical outcomes and the ability to successfully treat larger size defects. The evidence for long-term clinical outcomes for AMIC is sparse, yet promising. A prospective randomized-controlled trial of 47 patients (mean defect size 3.6 ± 1.6 cm<sup>2</sup>) treated either with MFX or AMIC demonstrated improved outcomes in all cohorts at 2 years postoperatively; however, a significant and progressive score degradation was observed in the MFX group.<sup>49</sup> At

that 2-year mark, only 11%–22% of all patients in the study described their knee function as abnormal, while at 5-year follow-up the percentage of MFx patients rose to 66%, whereas the percentage remained stable at 6%–7% for AMIC patients.<sup>49</sup> Additionally, Schiavone et al. displayed a potential future for the use of AMIC in larger articular cartilage defects.<sup>50</sup> The study examined a median defect size of 4.3 cm<sup>2</sup> (range, 2.9–8 cm<sup>2</sup>) at median follow-up of 7 years. The results demonstrated a significant improvement from a mean international knee documentation committee (IKDCR) score of 31.7 (±8.9) points preoperatively to 80.6 (±5.3) and a significant improvement in Lysholm test when comparing preoperative score to final follow-up.

p0135 MFx and exogenous scaffolds can be further augmented by the use of PRP. Little is currently known about the addition of PRP to collagen graft augmented MFx procedures, but some evidence has shown that PRP can aid in recruitment of bone marrow MSCs from the underlying subchondral bone.<sup>51</sup> BioCartilage (Arthrex Inc., Naples, FL) is a novel technique that combines a dehydrated allograft cartilage ECM scaffold and the addition of PRP.<sup>44</sup> The ECM is made up of type II collagen, proteoglycans, and cartilaginous growth factors, which are components of native articular cartilage.<sup>44</sup> Few peer-reviewed studies on BioCartilage outcomes are available, but in a study by Fortier et al.<sup>43</sup> the authors reported that BioCartilage-treated knee lesions had significantly higher ICRS repair scores when compared with MFx alone at 2, 6, and 13 months postoperatively via repeat arthroscopy in equine models. Furthermore, when histology was examined, BioCartilage-repaired defects had significantly better formation of type II collagen than the control defects.<sup>43</sup> The increase in type II collagen allows hyaline-like cartilage to regenerate within the defect, which is optimal for repair.<sup>43</sup>

s0050 **CHONDROCYTE IMPLANTATION INDICATIONS AND OUTCOMES**

p0140 While the aforementioned procedures result in fibrocartilage formation, which has biomechanical characteristics inferior to that of native cartilage, the following cartilage restoration procedures actually replace hyaline cartilage by cell-based implantation or osteochondral grafting, with or without the subchondral bone, using host or donor articular cartilage.<sup>52</sup> These procedures include single-stage (mosaicplasty, osteochondral allograft/autograft, particulated juvenile cartilage graft) and two-stage (ACI) interventions. Not unexpectedly, regardless of technique, those patients who are younger, more active, with shorter preoperative symptom

duration, fewer prior cartilage procedures, without concurrent ligamentous or meniscal deficiency, and with smaller isolated defects on the medial femoral condyle have the greatest expectations for superior outcomes.<sup>8</sup> In the evaluation of these often complex patients, the orthopaedic surgeon must perform a thorough history and physical examination. It is necessary to identify the location and duration of symptoms, presence of knee swelling or instability, and a patient's goals of care. Concomitant pathology of the meniscus, ligament(s), or mechanical axis must be addressed in a concurrent or staged fashion in order to provide a biomechanically sound environment for chondrocyte implantation surgery.

**Osteochondral Autograft**

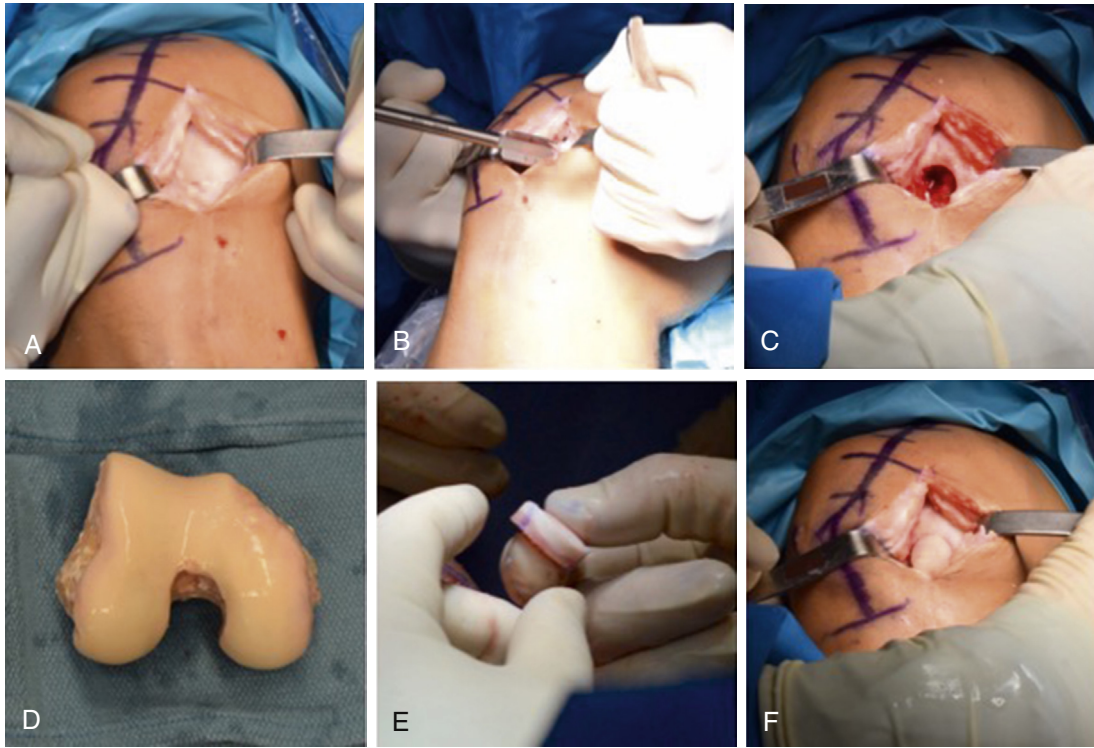
Osteochondral autograft, also known as osteoarticular transfer system (OATS), includes whole-tissue transfer of cancellous autograft bone, normal subchondral bone tidemark, and mature hyaline articular cartilage, which immediately provides a new, functional chondral surface. This allows for a more rapid rehabilitation than the fibrocartilage maturation process of MFx or the cell-based maturation of ACI.<sup>53</sup> The technology is beneficial in the treatment of full-thickness lesions. Either one single, large plug or multiple smaller plugs (known as mosaicplasty) of osteochondral tissue are transferred from non-weight-bearing areas (i.e., the periphery of the femoral condyles or superolateral/superomedial femoral trochlea) to the site of chondral loss.<sup>54</sup> While osteochondral autografting can be technically difficult, its durability and successful outcomes particularly in high-demand patient populations makes it a popular option in the surgeon's armamentarium.<sup>2</sup> In general, clinical outcomes up to 17 years postoperatively have demonstrated good to excellent results in more than 90% of patients with defects between 1 and 5 cm<sup>2</sup> in size.<sup>55</sup> However, morbidity including pain and discomfort at the donor/harvest site of the autograft is a concern.<sup>55</sup>

Depending on defect location, size, ability to obtain perpendicular access, and surgeon experience, the lesions can be managed via all-arthroscopic or open techniques.<sup>2</sup> The donor tissue is gathered by positioning the harvesting tool perpendicular to the cartilage surface, impacting to a depth of 10-mm, and removing the intact plug.<sup>56</sup> The recipient site is prepared to accept the donor plug using a corresponding recipient core harvester, curettes, and/or motorized shavers to obtain stable vertical margins. The graft is gently inserted and impacted in a press-fit manner, so it is flush with the native surrounding cartilage. Harvest plugs should be

s0055  
p0145

p0150

8 SECTION III Clinical Applications in Sports Medicine



f0025

**FIG. 9.4 Osteochondral Allograft.** Intraoperative photographs of a (A) right knee medial femoral condyle focal chondral defect being (B) reamed to excise (C) the chondral defect. The (D) allograft tissue is then prepared to create (E) an osteochondral plug that is then (F) implanted to reconstruct the articular surface.

limited to 3–4 cm<sup>2</sup> in size to avoid donor site morbidity and to allow the donor surface to reconstitute.<sup>56</sup> After osteochondral autograft transplantation, the strongest MRI finding that correlates with clinical outcomes are defect fill and repair tissue structure, highlighting the importance of this reconstitution process.<sup>57</sup> While osteochondral lesions between 1 and 8 cm<sup>2</sup> have been treated by this technique, those lesions with <2 cm<sup>2</sup> are associated with superior outcomes.<sup>54</sup>

p0155

Hangody and Fules<sup>58</sup> reported their findings from 597 femoral condyles and 76 tibial plateaus treated by osteochondral autograft mosaicplasty. At up to 10 years postoperatively, 92% of patients undergoing femoral condyle treatment had good or excellent results, with 87% good/excellent findings for those with tibial plateau treatment. Solheim et al.<sup>59</sup> found higher failure rates in patients who were women, over 40 years of age, and with defect size >3 cm<sup>2</sup> in their evaluation of 73 patients between 5 and 14 years postoperatively. Systematic review of nine studies with 607 patients by Lynch et al.<sup>60</sup> demonstrated significant improvements,

with return to sport as early as 6 months after surgery, and superior results for lesions <2 cm<sup>2</sup>. Pareek et al.<sup>54</sup> systematically reviewed 10 studies with a total of 610 patients (mean defect size, 2.6 cm<sup>2</sup>) with an average age of 27.0 years at the time of surgery. At a long-term mean 10.2 years' follow-up, 72% of patients demonstrated successful outcomes, and the reoperation rate was 19%. IKDC and Lysholm scores improved significantly, but there was no improvement in Tegner score over the long-term despite a return-to-sport rate of 85%. The authors noted that increased age, greater numbers of previous surgical procedures, and increasing defect size correlated with risk of failure.

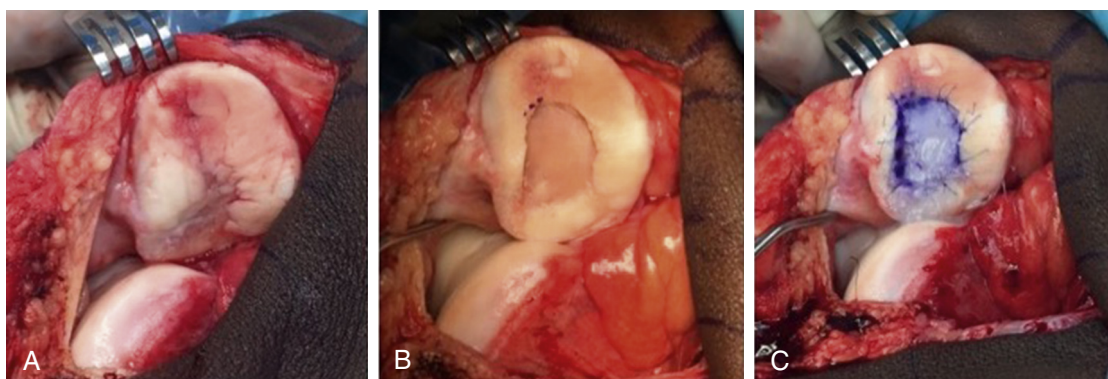
### Osteochondral Allograft

Osteochondral allograft transplantation allows treatment of chondral lesions that are too large (>2 cm<sup>2</sup>) to be effectively treated with OATS and can be performed in a single-stage unlike ACI (Fig. 9.4). Plain radiographs are used for sizing purposes to find a matching donor.<sup>61</sup> This allows for transfer of size-matched cartilage and subchondral

s0060

p0160





f0030

**FIG. 9.5 Autologous Chondrocyte Implantation.** Intraoperative photographs of a (A) chondral defect of the left patella in which (B) the cartilage defect is debrided and (C) treated with autologous chondrocyte implantation.

bone into osteochondral lesions of the knee. It provides a good salvage option for failed prior cartilage restoration procedures as well.<sup>61</sup> However, concerns with allograft use persist, including the risk for disease transmission, graft availability, technical difficulty, cost, and the long-term viability of cadaver chondrocytes and graft resorption.<sup>56,62</sup> The highest level of chondrocyte viability is seen with fresh osteochondral allografts, with storage times ideally <24 days,<sup>61,63</sup> and while frozen allografts demonstrate lower disease transmission rates, they additionally have inferior biological and biomechanical properties than their fresh allograft counterparts.<sup>64</sup>

p0165

Advantages of this technique include the one-step procedure, large defect sizes that can be addressed, salvage ability of the procedure, and restoration of both subchondral bone and surface hyaline cartilage.<sup>65</sup> The highest rates of success are seen with younger patients, normal or corrected malalignment, unipolar lesions, and defects with <1 year of symptomatic duration.<sup>66</sup> Patients younger than 25 years of age with preoperative symptoms <1 year of duration have a higher rate of return to sport following allograft transplantation than their counterparts.<sup>67</sup> Further disadvantages include mismatch of graft contour to the native joint, risk of disease transmission, and graft availability.<sup>65</sup> Negative prognostic factors for osteochondral allograft outcomes include patient age >50 years, 2+ prior surgeries, preoperative symptom duration >1 year, bipolar lesions, limb malalignment, and Workers' Compensation status.<sup>68-70</sup> One of the major limitations of osteochondral allograft may be with patellofemoral lesions, as this technology has not had great success within this compartment of the knee.<sup>71</sup>

p0170

Chahal et al.<sup>72</sup> systematically reviewed 19 studies with 644 knees at a mean follow-up of 58 months, which underwent osteochondral allograft transplantation of

the knee. Most grafts identified were procured fresh (61%), and the most common indication for transplantation was posttraumatic injury (38%). Nearly half (46%) of patients had concurrent procedures, and the mean defect size was 6.3 cm<sup>2</sup> across all included studies. The overall failure rate was 18%, but outcomes were overall favorable with high satisfaction rates at this intermediate follow-up. The authors reported superior outcomes in younger patients with unipolar lesions and shorter symptomatic duration. De Caro et al.<sup>73</sup> found similar success for osteochondral allograft in their systematic review, with overall excellent results achieved, improvement in clinical scores, a survivorship rate of 89% at 5 years postoperatively, and a high rate of return to sport. While bony integration was typically achieved, the authors found that cartilage integration was scant or failed to occur, particularly with frozen grafts.

Assenmacher et al.<sup>65</sup> found similar findings with systematic review of long-term outcome studies, where five studies totaling 291 patients demonstrated significant improvement in all clinical outcome scores. At 12.3 years postoperatively, the mean failure rate was 25%, and 72% of these failures were for conversion to arthroplasty. The reoperation rate was 36%. Patellofemoral lesions were associated with decreased clinical improvement and greater reoperation rates.

p0175

### Autologous Chondrocyte Implantation

ACI works by the induction of hyaline-like cartilage formation, and while it previously had been considered a second-line treatment option, recent evidence suggests that its use as a primary intervention in certain patients is warranted (Fig. 9.5).<sup>74</sup> ACI may be the most appropriate option for young, active patients with a relatively short duration of preoperative symptoms, a

s0065

p0180

10 SECTION III Clinical Applications in Sports Medicine

large full-thickness surface chondral defect (>4 cm<sup>2</sup>), and no prior cartilage procedures.<sup>8,75</sup> Ideal candidates also have minimal or no involvement of the subchondral bone.

p0185 ACI treatment of focal cartilage defects in the patellofemoral as well as tibiofemoral compartments has evolved tremendously since first being utilized in 1994.<sup>8,76</sup> Increasing generations have incorporated a periosteal cover, a collagen membrane cover, and several three-dimensional scaffolds with varying means of fixation to contain the chondrocytes.<sup>8</sup> The procedure requires two stages: first, autologous chondrocytes are harvested via chondral biopsy samples and are cultured and amplified in vitro. The chondral biopsy is commonly performed at the superolateral edge of the lateral femoral condyle, the superomedial edge of the medial femoral condyle, or the intercondylar notch in order to obtain about 200–300 mg of tissue.<sup>75</sup> Up to 48 million cells can be obtained via standard cell culture means.<sup>75</sup> Secondly, 3–8 weeks later, these cultured cells are implanted at the focal defect site. The cultured chondrocytes are most commonly implanted via arthrotomy, but all-arthroscopic techniques have been described.<sup>77</sup>

p0190 The first-generation procedure included implantation of the cultured chondrocytes under a periosteal patch with resorbable sutures and fibrin glue. The second-generation technique suspends the cultured cells with a membrane of type I/III collagen. Third-generation techniques utilize an ECM chondroinductive/-conductive scaffold to which the cultured cells attach, and this is implanted at the time of surgery.<sup>74</sup> The periosteal graft used to contain the autogenous cells has been a source of required reoperation in order to debride hypertrophic tissue in as many as 50% of cases in some reports.<sup>78</sup> The patellofemoral joint is at particularly high risk for such a complication. Adverse effects of the procedure have included joint stiffness and periosteal hypertrophy requiring revision procedures.<sup>79</sup> The use of a type I/III absorbable collagen membrane in second-generation ACI versus native periosteum in first-generation means has demonstrated a reduction in reoperation rate of 80% for symptomatic graft hypertrophy.<sup>80</sup> Third-generation ACI techniques simplify the procedure and have lower complication rates and superior graft quality than the preceding generations.<sup>81</sup> Second- and third-generation ACI demonstrate accelerated weight-bearing protocols over the first-generation technique.<sup>82</sup> As an additional tool, characterized chondrocyte implantation utilizes a genetic profile marker score to optimize the phenotype of the cultured cartilage tissue.<sup>83</sup>

While ACI has demonstrated significant improvements in large-sized (>4 cm<sup>2</sup>) full-thickness chondral defects of young adults at short- and mid-term follow-up, less evidence exists for the long-term course in these patients. However, MRI and histologic data suggest that ACI techniques restore nearly native cartilage appearance. The strongest MRI findings after ACI that correlate with clinical outcomes are graft hypertrophy and repair tissue signal.<sup>57</sup> p0195

Long-term outcomes have shown durability of ACI at up to 11 years postoperatively.<sup>84</sup> Systematic review of high-level evidence evaluating ACI<sup>8</sup> suggests that there is a trend for ACI to demonstrate improved outcomes in comparison with MFX, but no conclusion could be made with regards to differences with osteochondral autograft transplantation. Biopsies after ACI continue to show maturation for up to 24 months postoperatively, but the timing of maturation of cartilage repair and its clinical correlation is still somewhat ambiguous.<sup>85</sup> In the patellofemoral joint, ACI with patellofemoral osteotomy has shown significantly greater improvements in multiple clinical domains when compared with ACI in isolation, without any significant differences in the rate of total complications.<sup>86</sup> p0200

A systematic review by DiBartola et al.<sup>87</sup> evaluated ACI in the adolescent knee, and identified five studies with 115 patients at a mean 16.2 years of age with chondral defect size of mean 5.3 cm<sup>2</sup>. At a mean 52.3 months postoperatively, all studies reported improvement in clinical outcome measures, with graft hypertrophy being the most common complication (7.0%) and shorter duration of preoperative symptoms being the only identifiable variable that influenced outcomes. Peterson et al.<sup>88</sup> published on long-term follow-up of 224 patients with first-generation ACI at 10–20 years postoperatively. They reported that 92% were satisfied with their outcome and would have the procedure performed again. p0205

**Particulated Minced Cartilage**

Implantation of minced cartilage allows for a single-stage application technique of natural chondral tissue. This technology is appropriate for the treatment of chondral defects without significant bone loss.<sup>89</sup> The minced pieces of hyaline cartilage are often supplemented within a scaffold delivery system.<sup>62</sup> Lesion should be contained and between 1 and 6 cm<sup>2</sup>, patient BMI below 35 kg/m<sup>2</sup>, chondral defect grade 3 or higher, and subchondral bone relatively nonedematous.<sup>90</sup> The most commonly reported adverse effects after this type of treatment are joint stiffness and effusion, with s0070 p0210

reoperation most commonly occurring for graft delamination and hypertrophy.<sup>90</sup>

p0215 Cartilage autograft implantation system (CAIS) procedure includes harvesting of cartilage from a non-weight-bearing area of the knee through a CAIS harvester, followed by dispersion of the minced cartilage pieces onto a copolymer foam scaffold, stabilization with a fibrin sealant, and stapling into the defect site with resorbable polydioxanone staples.<sup>62</sup> While the technology has shown promise histologically and through imaging in large animal studies, human studies confirming its efficacy are limited at this time. By contrast, DeNovo NT Graft ("Natural Tissue Graft," Zimmer Inc., Warsaw, IN/ISTO Technologies Inc., St. Louis, MO) includes particulated allograft cartilage tissue from juvenile (<13-year-old) donors. The minced cartilage is implanted at the time of surgery and stabilized with fibrin glue adhesive,<sup>62</sup> and does not stimulate any immunogenic response.<sup>91</sup> It has an ~40-day shelf life.<sup>89</sup>

p0220 While clinical data are somewhat limited, there are some data published with promising clinical outcomes and histologic findings with hope for increased restorative and proliferative potential.<sup>90</sup> Tompkins et al.<sup>92</sup> reported on use of DeNovo in the patella for defects of a mean  $2.4 \pm 1.2$  cm<sup>2</sup> size at an average of 28 months postoperatively. While 2 of 15 grafts required debridement because of hypertrophy, mean fill on MRI was 89%. Farr et al. demonstrated a favorable type II/I collagen ratio on immunohistochemistry biopsies in 25 patients who underwent DeNovo NT treatment; at 2 years postoperatively, there were no reoperations required in this cohort.<sup>93</sup> However, the long-term efficacy of this technology in terms of cartilage histology and symptomatic relief remains to be seen. Ultimately, further high-level human studies are necessary to better scrutinize the technology and corroborate the promising basic science and animal study findings.

### s0075 **COMPARISONS OF SURGICAL INTERVENTIONS**

p0225 ACI has shown a slower clinical response when compared with osteochondral autograft, which is not unexpected given the immediate presence of hyaline cartilage with the latter as compared with the remodeling process that occurs with the former.<sup>8</sup> Mundi et al.<sup>94</sup> performed a metaanalysis of 12 randomized trials with a cumulative 765 patients and a mean lesion size of  $3.9 \pm 1.3$  cm<sup>2</sup>. The authors reported no significant difference in functional outcomes or pain at

intermediate-term follow-up for marrow stimulation, ACI, and osteochondral autograft transfer techniques, despite all generally showing efficacy in treatment.

Harris et al.<sup>8</sup> conducted a systematic review of level I and II studies comparing ACI with either MFx or osteochondral autograft. In three of seven studies comparing ACI with MFx, clinical outcomes were superior with ACI after 1–3 years postoperatively, one study demonstrated superior results 2 years after MFx, and the final three studies demonstrated no differences in these interventions after 1–5 years. With both procedures, younger patients with shorter duration of preoperative symptoms and fewer prior surgeries demonstrated the best outcomes. The authors noted that clinical outcomes after MFx deteriorated after 1.5–2 years postoperatively. In the identified studies comparing ACI with osteochondral autograft, equivalent short-term clinical outcomes were identified although in the two relevant studies there was more rapid improvement with the latter. Equivalent outcomes were noted between open and all-arthroscopic techniques of ACI, but complication rates after open, periosteal cover, first-generation ACI was higher in four studies. The authors ultimately reported that a chondral defect size of >4 cm<sup>2</sup> was predictive of superior outcomes with ACI over either MFx or osteochondral autograft.<sup>8</sup>

Osteochondral autograft has shown through systematic review to have superior clinical results, less reoperation, a higher rate of return to sport, and maintenance of sports function when compared with MFx. However, outcome improvements were not different from ACI, yet the latter had a lower failure rate at 10-year follow-up.<sup>60</sup>

In a systematic review of 44 studies, Krych et al.<sup>53</sup> evaluated 2549 patients with an average age of 35 years to assess the optimal surgical cartilage restoration treatment of chondral defects in athletic populations. The authors found that return to sport at some level was 76% overall but that the greatest return rate was after osteochondral autograft (93%; at a mean 5.2 months postoperatively), followed by osteochondral allograft (88%; at a mean 9.6 months), ACI (82%; at a mean 11.8 months), and MFx (58%; at a mean 9.1 months). However, there may be a selection bias in these findings in terms of patient age and lesion sizes of those treated with autograft.

Schrock et al.<sup>79</sup> compared the functional outcomes and cost-effectiveness of MFx, osteochondral autograft transplantation, and first- and second-generation ACI. They found all to be effective surgical procedures with increases in functional outcomes scores at short-term follow-up, with second-generation ACI having

12 SECTION III Clinical Applications in Sports Medicine

statistically greater improvements than the others. Interestingly, MFx was found to be the most cost-effective treatment, and first-generation ACI, the least cost-effective.

these amniotic membrane products continues to evolve, so will the clinical applications in cartilage restoration efforts.

s0080 p0250 **FUTURE DIRECTIONS**

The current focus on healthcare costs and cost-efficacy in treatment options is likely to play a role in future study and implementation of treatment options. Restrictions imposed by the Food and Drug Administration (FDA) have made further progress difficult in some respects as well in this field of orthopedics. It is clear that collaborative efforts with multicenter research and standardization of treatment regimens will be important to furthering this area of study. Additionally, collaboration among engineers, scientists, and orthopedic surgeons will continue to help spur further technologic advancements.<sup>95</sup>

p0255 Combination therapies of the aforementioned cartilage surgery and orthobiologics must be evaluated more closely to better replicate the native cartilage and joint homeostasis.<sup>95</sup> Additional methods of ACI including matrix ACI with growth factors are still evolving in an effort to improve the bioscaffold for implanted chondrocytes and produce type II collagen closer to native cartilage.<sup>75</sup> Continued efforts are expected with production of three-dimensional, ECM bioscaffolds as acellular sheets, layered scaffolds, hydrogels, and decellularized osteochondral allografts given their cytocompatibility and positive influence on stem cell behavior including growth, differentiation, migration and viability in the setting of cartilage restoration.<sup>96</sup> Future investigations may also include gene therapy, using biologic factors to suppress proinflammatory cytokines.<sup>97</sup>

p0260 The use of cell sources (i.e., bone marrow MSCs, umbilical cord cells, embryonic stem cells, and ASCs) in isolation and with the aforementioned cartilage regeneration procedures will continue to receive research attention and efforts.<sup>89</sup> The use of amniotic membrane products for cartilage restoration is gaining momentum in the last decade. As a source of pluripotent cells, this technology provides a highly organized collagen, antifibrotic and antiinflammatory product, which may be beneficial when utilized as an alternate tissue engineering scaffold for MSCs or delivery of chondrocytes or by chondrogenic differentiation or proliferation.<sup>98</sup> Although, no human studies are available to date, as the preliminary studies have been performed in animal models and through in vitro research. As the regulatory process around

**CONCLUSIONS**

Isolated, symptomatic chondral or osteochondral defects of the knee are a challenging pathology for orthopaedic surgeons to combat. The multitude of current surgical and nonsurgical options used to address these cartilage injuries underscores the notion that surgeons do not yet have a conclusion on which is superior to its counterparts. Continued research efforts are necessary to better understand the appropriate settings, mechanisms of application, and patient populations for the aforementioned orthobiologics and surgical techniques.<sup>99</sup> Independent of the treatment option being utilized, successful outcomes are contingent on proper patient selection and appropriate indications.<sup>89</sup> Every patient's treatment regimen should be individualized based on age, lesion size, patient activity and preference, and treatment costs.<sup>97</sup>

Joint injections with orthobiologic agents work to decrease symptoms caused by inflammation and joint viscosity. However, disease-modifying effects are not readily evident.<sup>89</sup> No orthobiologic or cartilage procedure can entirely reproduce the native structure and function of true hyaline cartilage.<sup>89</sup> From a surgical standpoint, smaller lesions (<2 cm<sup>2</sup>) are best treated with MFx or osteochondral autograft, with the latter showing more durable outcomes in higher demand patients. Lesions of intermediate size (2–4 cm<sup>2</sup>) can be treated well in general by ACI or osteochondral autografting, but lesions considered large (>4 cm<sup>2</sup>) have evidence to support use of ACI or osteochondral allograft.<sup>2</sup>

**REFERENCES**

1. Alford JW, Cole BJ. Cartilage restoration, part 1: basic science, historical perspective, patient evaluation, and treatment options. *Am J Sports Med.* 2005;33:295–306.
2. Richter DL, Tanksley JA, Miller MD. Osteochondral autograft transplantation: a review of the surgical technique and outcomes. *Sports Med Arthrosc Rev.* 2016;24:74–78.
3. Montgomery SR, Foster BD, Ngo SS, et al. Trends in the surgical treatment of articular cartilage defects of the knee in the United States. *Knee Surg Sports Traumatol Arthrosc.* 2014;22(9):2070–2075.
4. McCormick F, Harris JD, Abrams GD, et al. Trends in the surgical treatment of articular cartilage lesions in the United States: an analysis of a large private-payer database over a period of 8 years. *Arthroscopy.* 2014;30(2):222–226.

s0085

p0265

p0270

s0090

- Ciccotti MC, Kraeutler MJ, Austin LS, et al. The prevalence of articular cartilage changes in the knee joint in patients undergoing arthroscopy for meniscal pathology. *Arthroscopy*. 2012;28:1437–1444.
- Aroen A, Loken S, Heir S, et al. Articular cartilage lesions in 993 consecutive knee arthroscopies. *Am J Sports Med*. 2004;32:211–215.
- Basad E, Ishaque B, Bachmann G, Sturz H, Steinmeyer J. Matrix-induced autologous chondrocytes implantation versus microfracture in the treatment of cartilage defects of the knee: a 2-year randomized study. *Knee Surg Sports Traumatol Arthrosc*. 2010;18:519–527.
- Harris JD, Siston RA, Pan X, Flanigan DC. Autologous chondrocyte implantation: a systematic review. *J Bone Joint Surg Am*. 2010;92:2220–2233.
- Steadman JR, Rodkey WG, Briggs KK. Microfracture to treat full-thickness chondral defects: surgical technique, rehabilitation, and outcomes. *J Knee Surg*. 2002;15:170–176.
- Camarero-Espinosa S, Rothen-Rutishauser B, Foster EJ, Weder C. Articular cartilage: from formation to tissue engineering. *Biomater Sci*. 2016;4:734–767.
- Szafranski JD, Grodzinsky AJ, Burger E, Gaschen V, Hung HH, Hunziker EB. Mechanotransduction: effects of compression on deformation of intracellular organelles and relevance to cellular biosynthesis. *Osteoarthr Cartil*. 2004;12:937–946.
- Eyre DR. Collagens and cartilage matrix homeostasis. *Clin Orthop Relat Res*. 2004;(suppl 427):S118–S122.
- Cohen NP, Foster RJ, Mow VC. Composition and dynamics of articular cartilage: structure, function and maintaining healthy state. *J Orthop Sports Phys Ther*. 1998;28:203–215.
- Thambyah A, Broom N. On how degeneration influences load-bearing in the cartilage–bone system: a microstructural and micromechanical study. *Osteoarthr Cartil*. 2007;15:1410–1423.
- Hunziker EB, Michel M, Studer D. Ultrastructure of adult human articular cartilage matrix after cryotechnical processing. *Microsc Res Tech*. 1997;37(4):271–284.
- Altman RD, Manjoo A, Fierlinger A, Niazi F, Nicholls M. The mechanism of action for hyaluronic acid treatment in the osteoarthritic knee: a systematic review. *BMC Musculoskelet Disord*. 2015;16:321–331.
- O’Hanlon CE, Newberry SJ, Booth M, et al. Hyaluronic acid injection therapy for osteoarthritis of the knee: concordant efficacy and conflicting serious adverse events in two systematic reviews. *Syst Rev*. 2016;5:186–197.
- Shewale AR, Barnes CL, Fischbach LA, Ounpraseuth ST, Painter JT, Martin BC. Comparison of low-, moderate-, and high-molecular-weight hyaluronic acid injections in delaying time to knee surgery. *J Arthroplasty*. 2017;32(10):2952–2957.
- Abrams GD, Frank RM, Fortier LA, Cole BJ. Platelet-rich plasma for articular cartilage repair. *Sports Med Arthrosc Rev*. 2013;21:213–219.
- Laver L, Marom N, Dnyanesh L, Mei-Dan O, Espregueira-Mendes J, Gobbi A. PRP for degenerative cartilage disease: a systematic review of clinical studies. *Cartilage*. 2017;8(4):341–364.
- Cole BJ, Karas V, Hussey K, Merkow DB, Pilz KP, Fortier LA. Hyaluronic acid versus platelet-rich plasma: a prospective, double-blind randomized controlled trial comparing clinical outcomes and effects on intraarticular biology for the treatment of knee osteoarthritis. *Am J Sports Med*. 2017;45:339–346.
- Meheux CJ, McCulloch PC, Lintner DM, Varner KE, Harris JD. Efficacy of intra-articular platelet-rich plasma injections in knee osteoarthritis: a systematic review. *Arthroscopy*. 2016;32:495–505.
- Riboh JC, Saltzman BM, Yanke AB, Fortier L, Cole BJ. Effect of leukocyte concentration M on the efficacy of platelet-rich plasma in the treatment of knee osteoarthritis. *Am J Sports Med*. 2016;44:792–800.
- Kasten P, Beyen I, Egermann M, et al. Instant stem cell therapy: characterization and concentration of human mesenchymal stem cells in vitro. *Eur Cells Mater*. 2008;16:47–55.
- Chahla J, Dean CS, Moatshe G, Pascual-Garrido C, Cruz RS, LaPrade RF. Concentrated bone marrow aspirate for the treatment of chondral injuries and osteoarthritis of the knee: a systematic review of outcomes. *Ortho J Sports Med*. 2016;4:1–8.
- Holton J, Imam M, Ward J, Snow M. The basic science of bone marrow aspirate concentrate in chondral injuries. *Orthop Rev*. 2016;8:80–84.
- Gobbi A, Chaurasia S, Karnatzikos G, Nakamura N. Matrix-induced autologous chondrocyte implantation versus multipotent stem cells for the treatment of large patellofemoral chondral lesions: a nonrandomized prospective trial. *Cartilage*. 2015;6:82–97.
- Krych AJ, Nawabi DH, Farshad-Amacker NA, et al. Bone marrow concentrate improves early cartilage phase maturation of a scaffold plug in the knee: a comparative magnetic resonance imaging analysis to platelet-rich plasma and control. *Am J Sports Med*. 2016;44:91–98.
- Kasir R, Vernekar VN, Laurencin CT. Regenerative engineering of cartilage using adipose-derived stem cells. *Regen Eng Transl Med*. 2015;1:42–49.
- ter Huurne M, Schelbergen R, Blattes R, et al. Anti-inflammatory and chondroprotective effects of intraarticular injection of adipose-derived stem cells in experimental osteoarthritis. *Arthritis Rheum*. 2012;64:3604–3613.
- Manferdini C, Maumus M, Elena G, et al. Adipose-derived mesenchymal stem cells exert antiinflammatory effects on chondrocytes and synoviocytes from osteoarthritis patients through prostaglandin E2. *Arthritis Rheum*. 2013;65:1271–1281.
- Jo CH, Lee YG, Shin WH, et al. Intra-articular injection of mesenchymal stem cells for the treatment of osteoarthritis of the knee: a proof-of-concept clinical trial. *Stem Cells*. 2014;32:1254–1266.

14 SECTION III Clinical Applications in Sports Medicine

33. Pak J, Lee JH, Kartolo WA, Lee SH. Cartilage regeneration in human with adipose tissue-derived stem cells: current status in clinical implications. *BioMed Res Int*. 2016;5:192–200.
34. Case JM, Scopp JM. Treatment of articular cartilage defects of the knee with microfracture and enhanced microfracture techniques. *Sports Med Arthrosc*. 2016;24(2):63–68. <https://doi.org/10.1097/JSA.000000000000113>. PMID: 27135288.
35. Ergelet C, Vavken PJ. Microfracture for the treatment of cartilage defects in the knee joint—a golden standard?. *Clin Orthop Trauma*. 2016;7(3):145–152. <https://doi.org/10.1016/j.jcot.2016.06.015>. PMID: 27489408.
36. Falah M, Nierenberg G, Soudry M, Hayden M, Volpin G. Treatment of articular cartilage lesions of the knee. *Int Orthop*. 2010;34(5):621–630. <https://doi.org/10.1007/s00264-010-0959-y>. PMID: 20162416.
37. Mithoefer K, McAdams T, Williams RJ, Kreuz PC, Mandelbaum BR. Clinical efficacy of the microfracture technique for articular cartilage repair in the knee: an evidence-based systematic analysis. *Br Am J Sports Med*. 2009;37(10):2053–2063. <https://doi.org/10.1177/0363546508328414>. PMID: 19251676.
38. Steinwachs MR, Guggi T, Kreuz PC. Marrow stimulation techniques. *Injury*. April 2008;39(suppl 1):S26–S31. <https://doi.org/10.1016/j.injury.2008.01.042>. PMID:18313469.
39. Gobbi A, Nunag P, Malinowski K. Treatment of full thickness chondral lesions of the knee with microfracture in a group of athletes. *Knee Surg Sports Traumatol Arthrosc*. 2005;13(3):213–221. PMID:15146311.
40. Cerynik DL, Lewullis GE, Joves BC, Palmer MP, Tom JA. Outcomes of microfracture in professional basketball players. *Knee Surg Sports Traumatol Arthrosc*. 2009;17(9):1135–1139. <https://doi.org/10.1007/s00167-009-0765-5>. PMID:19296083.
41. Namdari S, Baldwin K, Anakwenze O, Park MJ, Huffman GR, Sennett BJ. Results and performance after microfracture in national basketball association athletes. *Am J Sports Med*. 2009;37(5):943–948. <https://doi.org/10.1177/0363546508330150>. PMID:19251677.
42. Lee YH, Suzer F, Thermann H. Autologous matrix-induced chondrogenesis in the knee: a review. *Cartilage*. 2014;5(3):145–153. <https://doi.org/10.1177/1947603514529445>. PMID: 26069694.
43. Fortier LA, Chapman HS, Pownder SL, et al. BioCartilage improves cartilage repair compared with microfracture alone in an equine model of full-thickness cartilage loss. *Am J Sports Med*. 2016;44(9):2366–2374. <https://doi.org/10.1177/0363546516648644>. PMID:27298478.
44. Abrams GD, Mall NA, Fortier LA, Roller BL, Cole BJ. BioCartilage: background and operative technique. *Operative Tech Sports Med*. 2013;21(2):116–124.
45. Gille J, Behrens P, Volpi P, et al. Outcome of autologous matrix induced chondrogenesis (AMIC) in cartilage knee surgery: data of the AMIC registry. *Arch Orthop Trauma Surg*. 2013;133(1):87–93. <https://doi.org/10.1007/s00402-012-1621-5>. PMID:23070222.
46. Kusano T, Jakob RP, Gautier E, Magnussen RA, Hoogewoud H, Jacobi M. Treatment of isolated chondral and osteochondral defects in the knee by autologous matrix-induced chondrogenesis (AMIC). *Knee Surg Sports Traumatol Arthrosc*. 2012;20(10):2109–2115. PMID: 22198419.
47. Siclari A, Mascaro G, Gentili C, Cancedda R, Boux E. A cell-free scaffold-based cartilage repair provides improved function hyaline-like repair at one year. *Clin Orthop Relat Res*. 2012;470(3):910–919. <https://doi.org/10.1007/s11999-011-2107-4>. PMID: 21965060.
48. Anders S, Volz M, Frick H, Gellissen J. A randomized, controlled trial comparing autologous matrix-induced chondrogenesis (AMIC®) to microfracture: analysis of 1- and 2-year follow-up data of 2 centers. *Open Orthop J*. 2013;7:133–143. <https://doi.org/10.2174/1874325001307010133>. PMID: 23730377.
49. Volz M, Schaumburger J, Frick H, Grifka J, Anders S. A randomized controlled trial demonstrating sustained benefit of Autologous Matrix-Induced Chondrogenesis over microfracture at five years. *Int Orthop*. 2017;41(4):797–804. <https://doi.org/10.1007/s00264-016-3391-0>. PMID: 28108777.
50. Schiavone Panni A, Del Regno C, Mazzitelli G, D’Apolito R, Corona K, Vasso M. Good clinical results with autologous matrix-induced chondrogenesis (Amic) technique in large knee chondral defects. *Knee Surg Sports Traumatol Arthrosc*. 2017. <https://doi.org/10.1007/s00167-017-4503-0>. PMID: 28324152.
51. Patel S, Dhillon MS, Aggarwal S, Marwaha N, Jain A. Treatment with platelet-rich plasma is more effective than placebo for knee osteoarthritis: a prospective, double-blind, randomized trial. *Am J Sports Med*. 2013;41(2):356–364. <https://doi.org/10.1177/0363546512471299>. PMID: 23299850.
52. Bobic V, Noble J. Articular cartilage—to repair or not to repair. *J Bone Joint Surg Br*. 2000;82:165–166.
53. Krych AJ, Pareek A, King AH, Johnson NR, Stuart MJ, Williams III RJ. Return to sport after the surgical management of articular cartilage lesions in the knee: a meta-analysis. *Knee Surg Sports Traumatol Arthrosc*. 2017;25(10):3186–3196.
54. Pareek A, Reardon PJ, Maak TG, Levy BA, Stuart MJ, Krych AJ. Long-term outcomes after osteochondral autograft transfer: a systematic review at mean follow-up of 10.2 years. *Arthroscopy*. 2016;32(6):1174–1184.
55. Hangody L, Dobos J, Balo E, Panics G, Hangody LR, Berkes I. Clinical experiences with autologous osteochondral mosaicplasty in an athletic population: a 17-year prospective multicenter study. *Am J Sports Med*. 2010;38:1125–1133.
56. Brophy RH, Wojahn RD, Lamplot JD. Cartilage restoration techniques for the patellofemoral joint. *J Am Acad Orthop Surg*. 2017;25(5):321–329.
57. Blackman AJ, Smith MV, Flanigan DC, Matava MJ, Wright RW, Brophy RH. Correlation between magnetic resonance imaging and clinical outcomes after cartilage repair surgery in the knee: a systematic review and meta-analysis. *Am J Sports Med*. 2013;41(6):1426–1434.

58. Hangody L, Fules P. Autologous osteochondral mosaicplasty for the treatment of full-thickness defects of the weight-bearing joints: ten years of experimental and clinic experience. *J Bone Joint Surg Am.* 2003;85-A(suppl 2):25–32.
59. Solheim E, Hegna J, Oyen J, et al. Results at 10 to 14 years after osteochondral autografting (mosaicplasty) in articular cartilage defects in the knee. *Knee.* 2013;20:287–290.
60. Lynch TS, Patel RM, Benedick A, Amin NH, Jones MH, Miniaci A. Systematic review of autogenous osteochondral transplant outcomes. *Arthroscopy.* 2015;31(4):746–754.
61. Zouzas IC, Bugbee WD. Osteochondral allograft transplantation in the knee. *Sports Med Arthrosc Rev.* 2016;24:79–84.
62. McCormick F, Yanke A, Provencher MT, Cole BJ. Minced articular cartilage—basic science, surgical technique, and clinical application. *Sports Med Arthrosc Rev.* 2008;16:217–220.
63. Williams SK, Amiel D, Ball ST, et al. Prolonged storage effects on the articular cartilage of fresh human osteochondral allografts. *J Bone Joint Surg Am.* 2003;85:2111–2120.
64. Allen RT, Robertson CM, Pennock AT, et al. Analysis of stored osteochondral allografts at the time of surgical implantation. *Am J Sports Med.* 2005;33:1479–1484.
65. Assenmacher AT, Pareek A, Reardon PJ, Macalena JA, Stuart MJ, Krych AJ. Long-term outcomes after osteochondral allograft: a systematic review at long-term follow-up of 12.3 years. *Arthroscopy.* 2016;32(10):2160–2168.
66. Chui K, Jeys L, Snow M. Knee salvage procedures: the indications, techniques and outcomes of large osteochondral allografts. *World J Orthop.* 2015;6(3):340–350.
67. Gudas R, Gudaite A, Pocius A, et al. Ten-year follow-up of a prospective, randomized clinical study of mosaic osteochondral autologous transplantation versus microfracture for the treatment of osteochondral defects in the knee joint of athletes. *Am J Sports Med.* 2012;40(11):2499–2508.
68. Gross AE, Shasha N, Aubin P. Long-term follow-up of the use of fresh osteochondral allografts for posttraumatic knee defects. *Clin Orthop Relat Res.* 2005;435:79–87.
69. Krych AJ, Robertson CM, Williams III RJ. Return to athletic activity after osteochondral allograft transplantation in the knee. *Am J Sports Med.* 2012;40:1053–1059.
70. Levy YD, Gortz S, Pulido PA, McCauley JC, Bugbee WD. Do fresh osteochondral allografts successfully treat femoral condyle lesions? *Clin Orthop Relat Res.* 2013;471:231–237.
71. Torga Spak R, Teitge RA. Fresh osteochondral allografts for patellofemoral arthritis: long-term followup. *Clin Orthop Relat Res.* 2006;444:193–200.
72. Chahal J, Gross AE, Gross C, et al. *Arthroscopy.* 2013;29(3):575–588.
73. De Caro F, Bisicchia S, Amendola A, Ding L. Large fresh osteochondral allografts of the knee: a systematic clinical and basic science review of the literature. *Arthroscopy.* 2015;31(4):757–765.
74. Welch T, Mandelbaum B, Minas T. Autologous chondrocyte implantation: past, present, and future. *Sports Med Arthrosc Rev.* 2016;24:85–91.
75. Gillogly SD, Wheeler KS. Autologous chondrocyte implantation with collagen membrane. *Sports Med Arthrosc Rev.* 2015;23:118–124.
76. Brittberg M, Lindahl A, Nilsson A, Ohlsson C, Isaksson O, Peterson L. Treatment of deep cartilage defects in the knee with autologous chondrocyte implantation. *N Engl J Med.* 1994;331:889–895.
77. Marcacci M, Kon E, Zaffagnini S, et al. Arthroscopic second-generation autologous chondrocyte implantation. *Knee Surg Sports Traumatol Arthrosc.* 2007;15:610–619.
78. Gillogly SD, Arnold R. Autologous chondrocyte implantation and anteromedialization for isolated patellar articular cartilage lesions: 5- to 11-year follow-up. *Am J Sports Med.* 2014;42:912–920.
79. Schrock JB, Kraeutler MJ, Houck DA, McQueen MB, McCarty EC. A cost-effectiveness analysis of surgical treatment modalities for chondral lesions of the knee. *Orthop J Sports Med.* 2017;5(5):2325967117704634.
80. Gomoll AH, Probst C, Farr J, et al. Use of a type I/III bilayer collagen membrane decreases reoperation rates for symptomatic hypertrophy after ACI. *Am J Sports Med.* 2009;37S:20–23.
81. Zhang C, Cai Y, Lin X. Autologous chondrocyte implantation: is it likely to become a savior of large-sized and full-thickness cartilage defect in young adult knee? *Knee Surg Sports Traumatol Arthrosc.* 2016;24:1643–1650.
82. Goyal D, Goyal A, Keyhani S, Lee EH, Hui JHP. Evidence-based status of second- and third-generation autologous chondrocyte implantation over first generation: a systematic review of level I and II studies. *Arthroscopy.* 2013;29(11):1872–1878.
83. Saris DB, Vanlauwe J, Victor J, et al. Characterized chondrocyte implantation results in better structural repair when treating symptomatic cartilage defects of the knee in a randomized controlled trial versus microfracture. *Am J Sports Med.* 2008;36:235–246.
84. Peterson L, Brittberg M, Kiviranta I, Akerlund EL, Lindahl A. Autologous chondrocyte transplantation. Biomechanics and long-term durability. *Am J Sports Med.* 2002;30:2–12.
85. Gikas P, Morris T, Carrington R, Skinner J, Bentley G, Briggs T. A correlation between the timing of biopsy after autologous chondrocyte implantation and the histological appearance. *J Bone Joint Surg Br.* 2009;91:1172–1177.
86. Trinh TQ, Harris JD, Siston RA, Flanigan DC. Improved outcomes with combined autologous chondrocyte implantation and patellofemoral osteotomy versus isolated autologous chondrocyte implantation. *Arthroscopy.* 2013;29(3):566–574.
87. DiBartola AC, Wright BM, Magnussen RA, Flanigan DC. Clinical outcomes after autologous chondrocyte implantation in adolescents' knees: a systematic review. *Arthroscopy.* 2016;32(9):1905–1916.

**16**      **SECTION III**    Clinical Applications in Sports Medicine

88. Peterson L, Vasiliadis HS, Brittberg M, et al. Autologous chondrocyte implantation: a long-term follow-up. *Am J Sports Med.* 2010;38:1117–1124.
89. Yanke AB, Chubinskaya S. The state of cartilage regeneration: current and future technologies. *Curr Rev Musculoskelet Med.* 2015;8:1–8.
90. Riboh JC, Cole BJ, Farr J. Particulated articular cartilage for symptomatic chondral defects of the knee. *Curr Rev Musculoskelet Med.* 2015;8:429–435.
91. Adkisson HD, Martin JA, Amendola RL, et al. The potential of human allogeneic juvenile chondrocytes for restoration of articular cartilage. *Am J Sports Med.* 2010;38:1324–1333.
92. Tompkins M, Hamann JC, Diduch DR, et al. Preliminary results of a novel single-stage cartilage restoration technique: particulated juvenile articular cartilage allograft for chondral defects of the patella. *Arthroscopy.* 2013;29:1661–1670.
93. Farr J, Tabet SK, Margerrison E, Cole BJ. Clinical, radiographic, and histological outcomes after cartilage repair with particulated juvenile articular cartilage: a 2-year prospective study. *Am J Sports Med.* 2014;42(6):1417–1425.
94. Mundi R, Bedi A, Chow L, et al. Cartilage restoration of the knee: a systematic review and meta-analysis of level I studies. *Am J Sports Med.* 2015;44(7):1888–1895.
95. Zlotnicki JP, Geeslin AG, Murray IR, et al. Biologic treatments for sports injuries II think tank—current concepts, future research, and barriers to advancement, part 3: articular cartilage. *Orthop J Sports Med.* 2016;4(4):1–11.
96. Monibi FA, Cook JL. Tissue-derived extracellular matrix bioscaffolds: emerging applications in cartilage and meniscus repair. *Tissue Eng.* 2017;23(4):386–398.
97. Richter DL, Schenck RC, Wascher DC, Treme G. Knee articular cartilage repair and restoration techniques: a review of the literature. *Sports Health.* 2015;8(2):153–160.
98. Riboh JC, Saltzman BM, Yanke AB, Cole BJ. Human amniotic membrane-derived products in sports medicine: basic science, early results, and potential clinical applications. *Am J Sports Med.* 2016;44(9):2425–2434.
99. Anz AW, Hackel JG, Nilssen EC, Andrews JR. Application of biologics in the treatment of the rotator cuff, meniscus, cartilage, and osteoarthritis. *J Am Acad Orthop Surg.* 2014;22:68–79.



# MAZZOCCA: 09

## Non-Print Items

### **Abstract**

Numerous surgical interventions have been developed and refined over the last few decades in an attempt to preserve the articular surface of the knee. Conservative options have more recently focused attention on injectable biologics in an effort to stimulate the body's natural resources and create an intraarticular milieu suitable for healing. Reparative marrow-stimulation techniques can be used at the site of a chondral defect in an attempt to induce fibrocartilage repair tissue formation after penetration of the subchondral bone. Restorative cartilage procedures, by contrast, replace the native defect site with host or donor articular cartilage. This chapter focuses on the basic science of cartilage structure, discusses the aforementioned surgical and nonsurgical preservation techniques for the articular cartilage of the knee joint, and highlights expected future directions of study in the realm of surface chondral defect treatment.

**Keywords:** Autologous chondrocyte implantation; Cartilage; Knee; Orthobiologics; Osteochondral; Restoration.