

SECTION X

Articular Cartilage Procedures and Rehabilitation of the Arthritic Knee



Author: Noyes;

31-1

31

c00031

Knee Articular Cartilage Restoration Procedures

Joshua D. Harris, MD, Brian J. Cole, MD, MBA

OUTLINE

u0010	Indications, 31-2	Preoperative Planning, 31-7	u0045
u0015	Contraindications, 31-4	Intraoperative Evaluation and Operative Technique, 31-8	u0050
u0020	Clinical Biomechanics, 31-4	Clinical Outcomes, 31-9	u0055
u0025	Clinical Evaluation, 31-5		
u0030	History, 31-5		
u0035	Physical Examination, 31-6		
u0040	Diagnostic Tests, 31-7		

s0010

INDICATIONS

Management of symptomatic focal chondral and osteochondral defects in the knee is complex and multifactorial. The most salient principle in evaluation of the clinical presentation of patients with focal chondral defects of the knee should focus on “treating the patient” and not the defect. This means avoiding linear reasoning in the presence of a known defect that lacks an inexorable nexus with a patient’s clinical presentation. The existence of a lesion on magnetic resonance imaging (MRI) or arthroscopic image should not automatically indicate surgery. It is well known that chondral defects are highly prevalent in both symptomatic and asymptomatic patients (Table 31-1). The incompletely understood natural history of articular cartilage lesions and the predictability of their surgical outcome mandates ensuring that the defect is clinically relevant and a competent source of the patient’s symptoms.

p0115

Ascribing symptoms to a lesion warrants determination of the exact location of the defect that is tender on exam, if this location of pain is exacerbated by weight bearing, if biologic activity is present via detection of an effusion, and if there is a reduction of pain with intraarticular injection. Articular cartilage is an aneural tissue. Thus the presence of a defect does not necessarily produce pain. However, patients with full-thickness lesions may demonstrate clinically important limitations in pain, function, sports and recreation, and quality of life as measured by Knee Injury and Osteoarthritis Outcome Score (KOOS) subscores.³¹ These limitations are not significantly different than those experienced by subjects with arthritis enrolled for osteotomy or arthroplasty and may be worse than those with anterior cruciate ligament (ACL) deficiency.³¹ The exact mechanism accounting for pain caused by pathology in an aneural tissue is not completely understood. Stimulation of periarteriolar nociceptive fibers in the subchondral bone is one theory.³⁸ In addition, the intraarticular biologic inflammatory milieu likely plays a large role with reduced anabolic factors and increased catabolic and nociceptive factors. This leads to synovitis, effusion, capsular distention, and pain.

31-2

Once the determination that a defect is symptomatic has been made, conservative treatment options may commence. These include, but are not limited to, rest, activity modification (typically reduction in load including reductions in body mass index [BMI]), oral antiinflammatory medications, glucosamine, chondroitin, methylsulfonylmethane, injection therapies (steroid [methylprednisolone, triamcinolone, betamethasone], nonsteroid [ketorolac], hyaluronate viscosupplementation, platelet-rich plasma [PRP]), and physical therapy with modalities. Despite the therapeutic effect of injections, the diagnostic effect of added local anesthetic may provide more clinically useful information in determining the severity of symptomatology and may hint at the responsiveness to subsequent treatment.

In the situation of failed conservative treatment, surgical decision-making is predicated upon the patient’s informed consent. This includes recognition of and addressing the patient’s preoperative expectations. Complete disclosure of the surgical algorithm (Figs. 31-1 and 31-2) and each technique’s advantages, disadvantages, risks, benefits, alternatives, expected outcomes, and postoperative rehabilitation is warranted. The algorithm for selection of the optimal technique is based on multiple patient factors (age, gender, activity level, BMI, symptom duration), limb and knee-related factors (meniscus, cruciate and collateral ligaments, alignment), and defect-specific factors (location, size, depth, subchondral bone). There are three general categories for surgical procedures designed to address articular cartilage pathology in the knee: (1) palliative (chondroplasty, debridement, lavage, meniscectomy); (2) repair (microfracture, drilling, abrasion, augmented scaffold-supported marrow-stimulation techniques); and (3) restoration (osteochondral autograft, osteochondral allograft, autologous chondrocyte implantation [ACI], and other chondrocyte- and mesenchymal stem cell-based therapies).

In addition to the treatment of the defect, concomitant limb and knee pathology must be addressed in either simultaneously or staged fashion. These entities include meniscal preservation (repair or transplantation),²⁷ alignment correction (varus or valgus malalignment treatment with proximal tibial or distal femoral unloading osteotomies, respectively; and patellofemoral malalignment treatment with

t0010

TABLE 31-1 Prevalence of Chondral Defects in the Knee Based on Unique Subject Populations

Subject Population	Prevalence
All ages: all defect locations, sizes, depths	60%-63% ^{5,9,33,45}
All ages: all defect locations, sizes, only full-thickness defects	16% ^{2,9,33,45}
All defect locations: age <40 years, only full-thickness defects	5%-7% ^{9,33,45}
Concomitant anterior cruciate ligament tear	16%-46% ⁶
All locations: amateur and professional athletes, only full-thickness defects	36% ¹⁵
All locations: asymptomatic professional basketball players, runners	59%-77% ^{15,35,44}

From Harris JD, Brophy RH, Jia G, et al. Sensitivity of magnetic resonance imaging for detection of patellofemoral articular cartilage defects. *Arthroscopy*. 2012;28(11):1728-1737.

CRITICAL POINTS Indications and Contraindications

- Indications**
- Symptomatic full-thickness chondral defect.
 - Symptoms include direct tenderness at lesion, activity-related weight-bearing pain, effusion, response to injection.
 - Treat concomitant pathology (meniscus, alignment, ligament).
 - Patient selection and addressing expectations is critical.
- Contraindications**
- Asymptomatic.
 - Patients unwilling or unable to comply with postoperative rehabilitation.
 - Uncorrected concomitant pathology (meniscus, alignment, ligament).
 - Osteoarthritis.

b0010

s0020

p0065

u0065

u0070

u0075

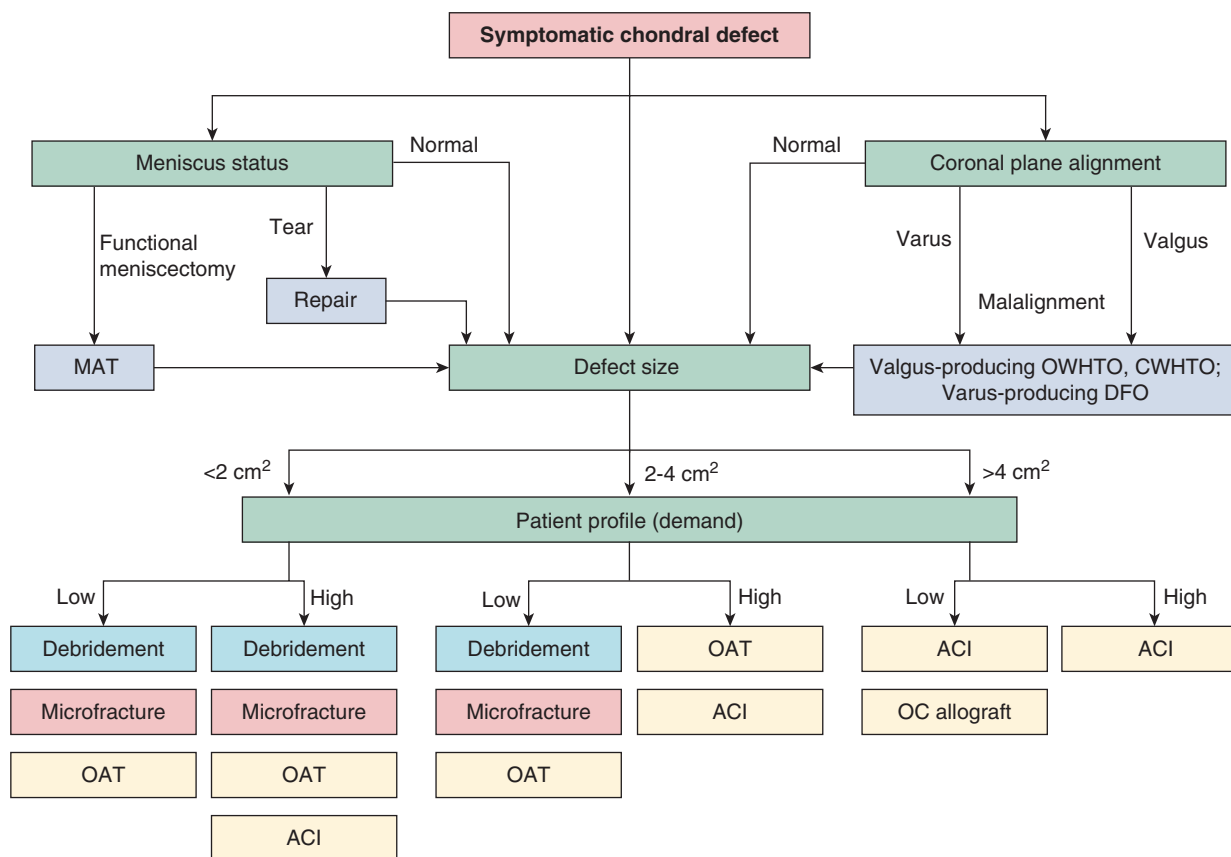
s0025

p0090

u0085

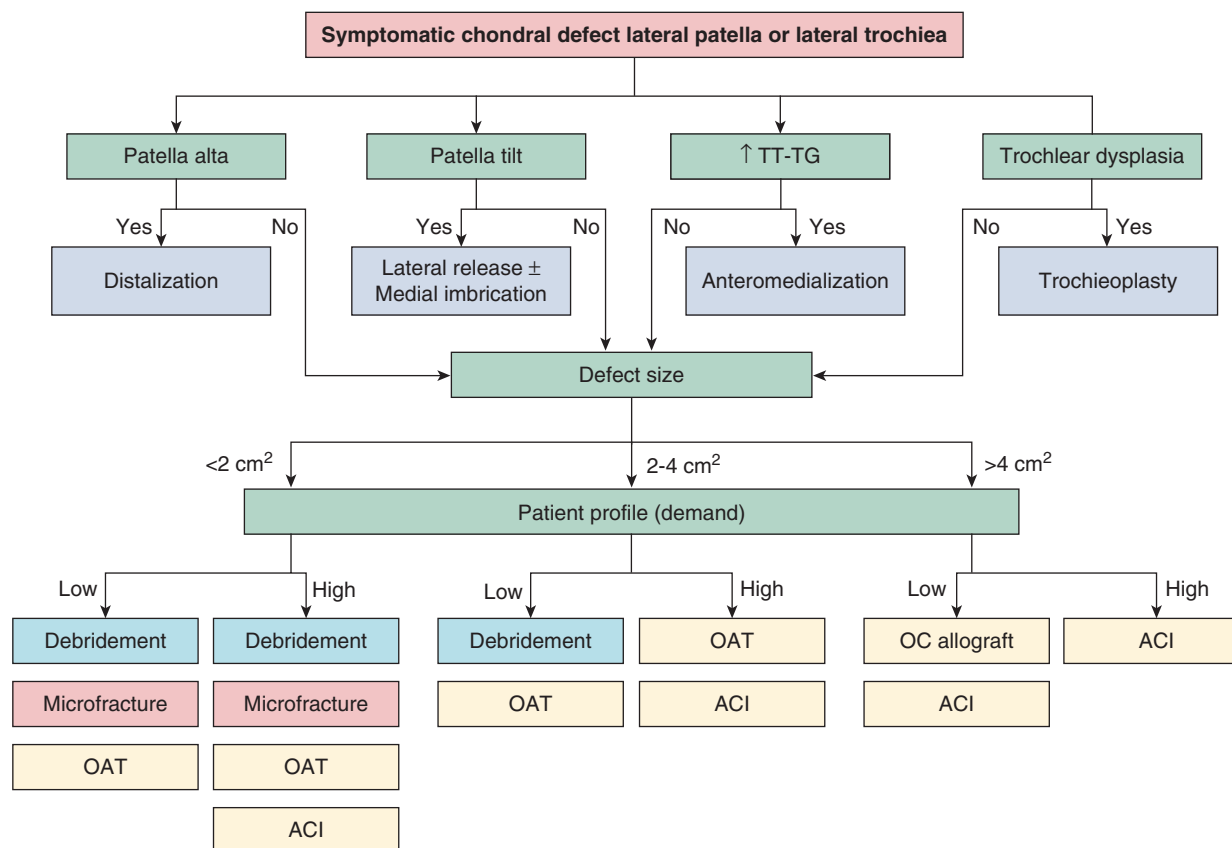
u0090

u0095



f0010

FIG 31-1 Management of symptomatic chondral defect in the tibiofemoral compartment (medial or lateral femoral condyle and/or tibial plateau). Concomitant pathology, such as meniscal deficiency and/or coronal plane malalignment should be addressed simultaneously or in a staged fashion. The most important defect-specific parameter dictating treatment choice is size (cm^2). Yellow shading denotes cartilage restoration, red shading denotes cartilage repair, purple shading denotes cartilage palliation. *ACI*, Autologous chondrocyte implantation; *CWHTO*, closing-wedge high tibial osteotomy; *DFO*, distal femoral osteotomy; *HTO*, high tibial osteotomy; *MAT*, meniscal allograft transplantation; *OAT*, osteochondral autograft transplantation; *OC*, osteochondral allograft *OWHTO*, opening-wedge high tibial osteotomy.



f0015

FIG 31-2 Management of symptomatic chondral defect in the patellofemoral compartment (trochlea, patella). Concomitant issues such as patella tilt, alta, increased tibial tubercle-trochlear groove (TT-TG), and trochlear dysplasia should be addressed simultaneously or in a staged manner. Centrally or medially located defects warrant different unloading osteotomy techniques. Medial patellofemoral cartilage pathology is a contraindication to medialization osteotomy. The most important defect-specific parameter dictating treatment choice is size (cm^2). Yellow shading denotes cartilage restoration, red shading denotes cartilage repair, purple shading denotes cartilage palliation. *ACI*, Autologous chondrocyte implantation; *OAT*, osteochondral autograft transplantation; *OC*, osteochondral allograft.

anteromedialization Fulkerson-type tibial tubercle osteotomy),^{24,43} and knee ligament reconstruction.⁶ The time commitment, intensity, and duration of the postoperative rehabilitation must not be overlooked or underestimated. The time to return to impact activities and return to sport must be discussed. Further, in the setting of competitive athletes, the following factors play a significant role: timing of surgery (in or off season, stage of career); level of sport (high school, collegiate, elite amateur, professional); scholarship, contract, or bonus status; and opinions of stakeholders in the athlete's care (owners, managers, coaches, trainers, agents, teammates, family, friends, spouses). Given the prevalence with which chondral pathology is identified in professional athletes' knees,^{15,35,44} the length of time required to rehabilitate following surgery,²² and the subsequent implications (time lost to team, financial), it is critical to carefully and appropriately select the correct surgical technique in this patient population. As a general consideration, if there is an extraarticular treatment (e.g., osteotomy) that can predictably relieve or improve an athlete's symptoms, strong consideration for delaying an intraarticular procedure (e.g., articular cartilage transplantation) until his or her career is over is a reasonable option.

s0030 CONTRAINDICATIONS

p0135 There are several groups of subjects that are not candidates for articular cartilage restorative techniques in the knee. There is currently no

role for prophylactic cartilage restoration in asymptomatic subjects. However, two exceptions to this contraindication exist; large surface area osteochondritis dissecans lesions and posterolateral meniscectomy in active females with valgus lower extremity alignment. In general, low-level symptoms should drive most early decision making rather than the theoretical risk of progression. There are no clear data that shows that neglect leads to inexorable progression or, conversely, that treatment may halt or attenuate progression. Patients with osteoarthritis have an irreversible process illustrated via diffuse degenerative changes of subchondral bone sclerosis, subchondral cyst formation, osteophytes, and joint space narrowing. Patients not willing or unable to comply with the postoperative guidelines and rehabilitation protocols are contraindicated. Other contraindications include uncorrected comorbidities (meniscal deficiency, malalignment, ligamentous insufficiency), malignancy, and infection. Relative contraindications include elevated body mass index, tobacco use,^{3,4,34} and inflammatory arthritides such as rheumatoid arthritis, psoriatic arthritis, gout, and pseudogout.

CLINICAL BIOMECHANICS

The knee is subjected to high loads during simple tasks such as gait and squatting, and even higher forces during sports involving sprinting and jumping.^{16,41} These result from external (ground reaction force,

s0035

perturbation) and internal (muscle forces, joint reaction force) sources.⁴⁰ Small alterations in the direction or angle of a force acting upon the knee can significantly influence the magnitude of forces observed.⁴² This effect is demonstrated with both ACL injury and focal chondral defects in the knee.

p0170 ACL injury leads to translational and rotational disturbances in the knee. These kinematic shifts lead to altered articular cartilage stress in that regions of articular cartilage that were unloaded preinjury are now loaded and regions of articular cartilage that were loaded preinjury are now unloaded. Because of the mechanosensitivity of chondrocytes and their low level of adaptability and reparability, the knee is susceptible to cartilage degeneration and progression with activity, especially in the setting of previous surgery or excessive BMI. In the presence of a focal chondral defect, the rim of the lesion may bear the load from the opposing articular surface, similar to a car driving over a pothole (Fig. 31-3). This stress concentration has been observed in several biomechanic models. Guettler and associates²¹ showed that, for defects larger than 10 mm in diameter, stress concentration occurs around the rim (at 2.2 mm from the rim medially and 3.2 mm from the rim laterally). Eventually, the size (diameter) enlarges enough so that the opposing articular surface contacts and transmits stress to the exposed subchondral bone within the full-thickness defect. This is dependent upon the defect size, location, and shape.

p0175 Flanigan and colleagues¹⁴ showed that there were condyle-specific thresholds for contact on exposed subchondral bone within circular defects and stress concentration around the defect at defect sizes greater than 1.61 cm² and 1.99 cm², respectively. In a separate investigation, Flanigan and coworkers¹³ demonstrated that there were both shape-dependent and condyle-specific thresholds for contact on exposed subchondral bone within oval-shaped defects. Oval-shaped defects with the long axis in the coronal plane (medial to lateral) on the lateral condyle had the lowest size threshold for exposed subchondral bone contact (0.73 cm²) and oval-shaped defects with the long axis in the sagittal plane (anterior to posterior) on the medial condyle actually had no size threshold (contact not observed). Stress concentration around the defect rim was observed in all defects, regardless of shape, size, or location. The stress dissipated with increasing radius away from the center of the lesion. Harris and associates²⁶ have also shown that the defect wall geometry (vertical versus 45-degree beveled; see Fig. 31-3) may play a large role in rim stress concentration, exposed intralesional subchondral bone contact, and subsequent defect progression. These mechanics are all based on condylar/meniscal/plateau geometry, especially coronal and sagittal plane radii of curvature.

p0180 The preferential greater lateral-biased defect loading mechanics is based on the unique geometries of the lateral and medial femoral condyles and their interaction with menisci and tibial plateaus. The mean sagittal and coronal plane radii of curvature for the lateral condyle are smaller than the medial condyle. Further, the sagittal radius

differs from the coronal radius. This, in effect, creates more “point loading” on the more “convex-on-convex” lateral compartment versus the more congruent “convex-on-concave” medial compartment. Clinically, this may translate to significantly greater risk of subchondral bone changes in full-thickness defects on the lateral condyle, as well as speak to the incrementally greater vulnerability that the lateral compartment has following meniscectomy. This “bone boss” “intralesional osteophyte” effect has been observed in subjects undergoing ACI by Henderson and associates.³² Patients with a bone boss had a longer duration of symptoms (greater time of subchondral bone experiencing opposing articular surface contact, more microcracks and microfractures).³² Additionally, Alford and colleagues¹ demonstrated that lateral compartment lesions progress more rapidly than medial and are likely to become symptomatic at smaller sizes. These findings suggest that not only should tibiofemoral lesions be surgically treated differently than patellofemoral, but also lateral femoral condyle lesions should be treated differently than medial condylar lesions. Earlier intervention for lateral lesions may be desirable. The intervention type (entire osteochondral unit [osteochondral autograft, allograft] vs. surface [chondral] treatments) likely also matters.

CLINICAL EVALUATION


s0040

History

s0045

Patients with symptomatic focal chondral defects of the knee experience pain that is reproducibly located at the site of the defect, is primarily activity-related (especially with axial load and weight bearing with tibiofemoral lesions, and especially with stairs or prolonged knee flexion with patellofemoral lesions), is associated with effusions (indicative of a biologically active synovitis process and capsular distention), and is often associated with a temporary relief of symptoms with intraarticular local anesthetic injection. Although single-dose intraarticular local anesthetic and corticosteroid injection is effective in significantly reducing pain, we recommend caution with certain anesthetic and corticosteroid injection combinations caused by potential articular cartilage chondrotoxicity. These include betamethasone sodium phosphate, betamethasone acetate, triamcinolone acetonide, 0.5% bupivacaine, 1% lidocaine or 0.25% bupivacaine combined with betamethasone acetate or sodium phosphate, and 1% lidocaine combined with methylprednisolone acetate or triamcinolone acetonide.^{5,8,10}

p0240

Because of this potential iatrogenic damage, we recommend 1% 

CRITICAL POINTS Clinical Biomechanics

- p0145 • Stress concentration occurs around the rim of full-thickness articular cartilage defects in the knee.
- u0105 • Defects may progress based on several defect specific factors: size, shape, compartment, location.
- u0110 • Lateral lesions may progress more rapidly than medial because of convex-on-convex mechanics (versus convex-on-concave medially) between the femoral condyle and tibial plateau.
- u0115 • With vertical walled lesions, although there is a lower volume of cartilage in the defect and on the exposed subchondral bone by the opposing surface, the stress concentration around the defect rim is greater.

CRITICAL POINTS Clinical Evaluation

- Pain reproducibly located at the site of the defect. p0190
- Pain primarily activity-related (weight bearing with tibiofemoral and stairs or prolonged knee flexion with patellofemoral). u0125
- Associated with intermittent effusions. u0130
- Temporary relief with intraarticular local anesthetic injection. u0135
- Focus on not only the exact location of tenderness (at the defect), but also concomitant pathology, including alignment, meniscal status, ligamentous sufficiency. u0140
- Gait evaluation, proximal and distal musculature (i.e. atrophy), extremity rotational profile, and pedal arch. u0145
- Weight-bearing plain radiographs, including long-leg alignment view, are initial diagnostic evaluation of choice. u0150
- Non-contrast MRI can detail the status of articular cartilage, subchondral bone, effusion, and concomitant pathology. u0155
- Advanced MRI sequences (e.g. dGEMRIC) may characterize collagen and proteoglycan content better than conventional MRI. u0160

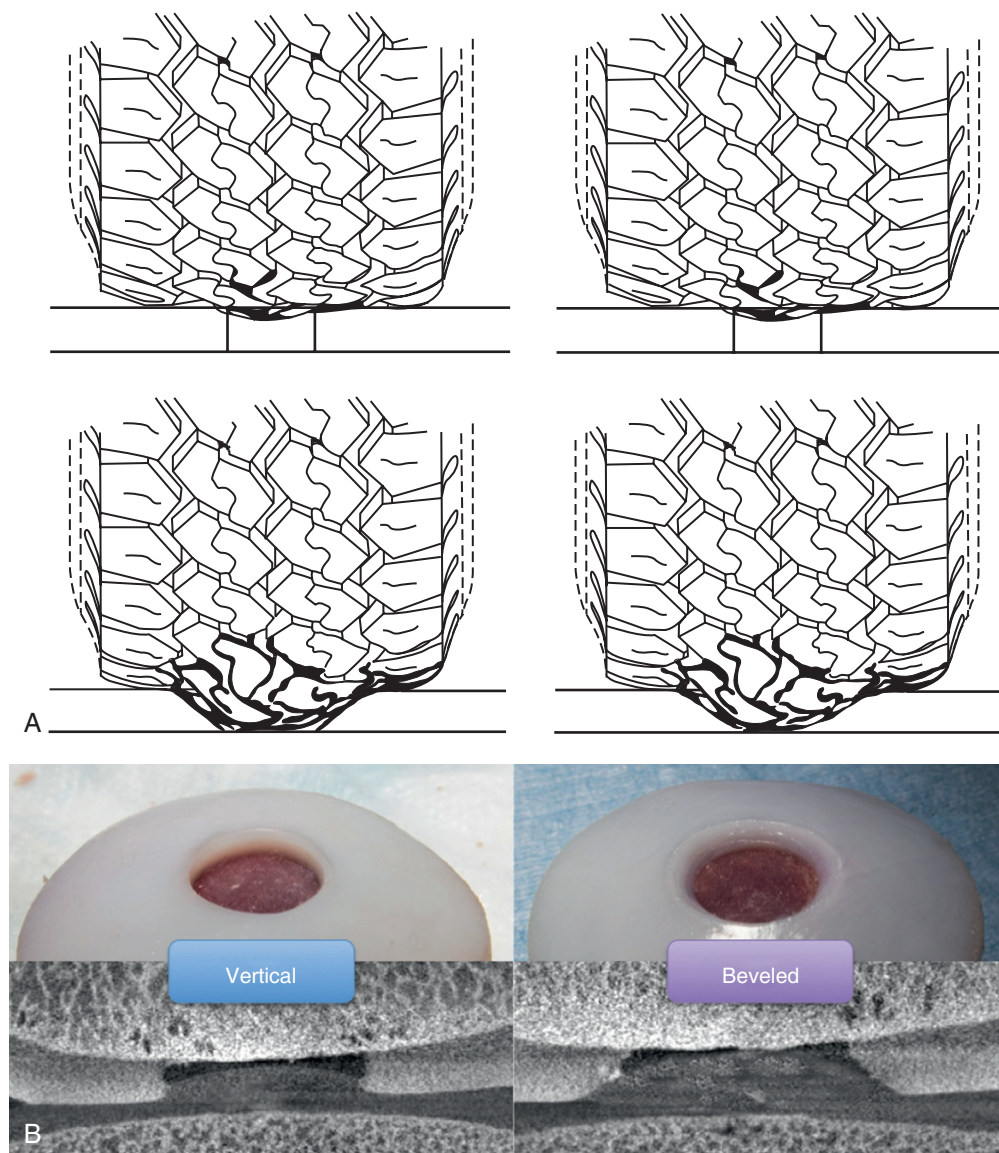


FIG 31-3 A, The top images illustrate a full-thickness chondral defect with vertical walls. Although there is greater stress concentration around the rim of the defect, the exposed subchondral bone is more protected. The presence of a defect increases the pressure on the rim of the defect ($\text{Pressure} = [\text{Force}/\text{Surface area}]$) because of a smaller surface area of articulating contact areas. The bottom right image illustrates enlargement of the lesion diameter with maintenance of vertical walls so that the exposed intralesional subchondral bone is contacted by the opposing articular surface. The bottom left image illustrates beveling of the lesion so that the exposed subchondral bone is contacted by the opposing articular surface. However, in addition, there is greater surface area of articular cartilage contact distribution with subsequent reduction in stress. We recommend vertical over beveled walls for cartilage repair surgery because it better contains the new cartilage tissue within the defect. **B**, The top two images are vertical and beveled lesions in cadaveric bovine femoral condyles. Upon axial load at the defect by the opposing intact tibial articular surface, visualized on microcomputed tomography, the stress concentration around the defect rim is greater—although there is a lower volume of cartilage in the defect and on the exposed subchondral bone by the opposing surface with the vertical wall lesion.

f0020

lidocaine for short- and 0.5% ropivacaine for long-term anesthesia, and dexamethasone as the corticosteroid of choice, because these medications have not demonstrated chondrotoxicity in combination in the literature. Preoperative duration of symptoms is highly variable. The mean preoperative duration of symptoms can range from as few as 6 months to more than 15 years, and the number of prior preoperative surgeries can range from none to 30.^{22,27,30,43}

Physical Examination

s0050

The physical examination of subjects with symptomatic chondral defects should focus not only on the defect itself, but also on concomitant pathology. Initial assessment should focus on gait observation. Antalgic patterns indicate pain in the extremity, Trendelenburg gait indicates a contribution of hip abductor weakness to knee pain,

quadriceps avoidance patterns are observed with patellofemoral lesions, and knee flexion contractures are seen with hamstring tightness (from multiple spine, pelvis, hip, and lower extremity sources; patella baja; and patellofemoral pain). Coronal plane alignment should be evaluated during double- and single-leg stance and gait for evaluation of static and dynamic alignment and assessment of thrust.

p0250 Lower extremity rotational profiles may be grossly evaluated via inspection for femoral version and tibial torsion via in-toeing or out-toeing. Foot observation examination should be performed during standing and ambulating, and double- and single-heel rises should be done for arch assessment.

p0255 Inspection for muscle atrophy at all muscle groups should be performed (this can be quantitatively evaluated with both circumference measurements, manual muscle testing, and isokinetic testing). Palpation is a critical component of the examination, especially focusing on tenderness at the site of the lesion. Although detection of large effusions is straightforward in most subjects, smaller effusions may require milking and ballottement of the patella to detect. Wilson's test may be used to diagnose a classical location osteochondritis dissecans (OCD) lesion on the lateral aspect of the medial femoral condyle. This maneuver is performed by internally rotating the tibia with the knee in a flexed position and then extending the knee while maintaining internal rotation. Pain will reproducibly occur at 30 degrees of flexion as the tibial spine contacts the defect. External tibial rotation will alleviate the pain. The sensitivity and specificity of the physical examination for diagnosis of OCD is 91% and specificity 69%, respectively, which is greater than MRI.³⁷ In addition to the defect itself, cruciate and collateral ligament stability should be assessed via Lachman, anterior and posterior drawer, sag, and quadriceps active tests and varus/valgus stress tests at 0 and 30 degrees of knee flexion. Posterolateral corner structures may be evaluated via external rotation recurvatum and dial testing, posterolateral drawer, and reverse pivot shift tests.

s0055 **Diagnostic Tests**

p0260 Plain radiographs of the knee and full-length alignment films are the initial diagnostic evaluation of choice for evaluation of patients with chondral defects in the knee. A weight-bearing anteroposterior view, weight-bearing 45-degree flexion posteroanterior view, weight-bearing lateral view in 30 degrees of flexion, and patellofemoral view (Mercer merchant or sunrise) are our preferred series. A full-length hip-to-ankle weight-bearing anteroposterior view allows for determination of the mechanical axis of the lower extremity. All plain radiographs should use a spherical radiographic magnification marker of known size to permit calculation of meniscal and/or osteochondral allograft sizes.

p0265 Noncontrast MRI is useful for evaluation of the articular cartilage, underlying subchondral bone, menisci, ligaments, tendons, and joint fluid. Proton density-weighted, intermediate-weighted, and T2-weighted images provide the best contrast resolution for articular cartilage evaluation. Fluid-sensitive sequences, such as T2 weighted and short-tau inversion recovery (STIR), are able to best differentiate the hyperintense synovial fluid-articular cartilage interface. Thus surface lesions are best evaluated with these sequences. Although fluid-sensitive sequences help to identify subchondral edema, they make it difficult to evaluate the articular cartilage-subchondral bone junction. Acquisitions without fat suppression help to clearly delineate the latter. MRI may be particularly useful in the evaluation of stable delamination injury in which the articular cartilage surface is intact, but the underlying cartilage and/or subchondral bone is damaged. These injury types may be missed by the gold standard articular cartilage evaluation, arthroscopy, because the surface is not breached. Although some types of cartilage lesions are difficult to completely characterize via MRI, this is usually because of the lesion thickness, its orientation

and shape, the magnet strength (signal to noise ratio spatial resolution), and the imaging plane orientation relative to the defect. Regions of cartilage softening and superficial fibrillation or fissures may be missed by conventional MRI sequences. Advanced sequences, such as T2 mapping, T2*, T1ρ, sodium imaging, and dGEMRIC (delayed gadolinium-enhanced MRI of cartilage) may be useful to evaluate early articular cartilage damage via ultrastructural details of collagen and proteoglycan pathology.

PREOPERATIVE PLANNING

s0060

Based on the patient's clinical history, physical examination, imaging work-up, and preoperative discussion with informed consent, a surgical treatment may be recommended. Prior records (operative report and arthroscopic photographs) are an important component of the decision-making algorithm (see Figs. 31-1 and 31-2), because they give the treating surgeon information regarding defect size, defect peripheral walls, subchondral bone appearance, meniscal and ligamentous status, and opposing articular surface ("kissing" lesions). It is critical to recognize and appreciate all patient-, limb-, knee-, and defect-specific factors (Table 31-2) that may influence the surgical outcome.

Each patient and their cartilage defect should be approached individually and not always according to a cookbook algorithm. In other words, "treat the patient, not the defect." Algorithms are general guidelines that use various patient and defect factors to help the surgeon and patient select a certain type of surgery. For patients with symptomatic chondral defects in the knee, a prerequisite to cartilage repair

p0305

CRITICAL POINTS Preoperative Planning

b0025

- Thorough history and physical examination ("treat the patient, and not the defect"), including prior record review (operative reports, arthroscopic photographs). p0275
- Preoperative informed consent includes a discussion of the intensity, frequency, and duration of postoperative rehabilitation and the patient's ability to comply with it. u0170
- Evaluate and treat all concomitant pathology (meniscus, alignment, ligament) either simultaneously or in a staged fashion. u0175
- Specific surgical techniques are based on patient-, limb-, knee-, and defect-specific factors. u0180
- Defect-specific factors include size, location, depth, shape, walls. u0185

TABLE 31-2 Patient-, Limb-, Knee-, and Defect-Specific Factors That Influence Outcome of Articular Cartilage Surgery in the Knee

t0015

Patient	Limb	Knee	Defect
Age	Coronal alignment	Meniscal status	Size
Body mass index	Patellofemoral "alignment"	Ligament status	Location
Smoking status	Muscle atrophy	Prior surgeries	Depth
Duration symptoms	Contracture	Effusion	Shape
Goals			Subchondral bone
Rehab compliance			Walls
			Single vs. multiple

or restoration is the ability to comply with the postoperative protocol in frequency, intensity, and duration. In the tibiofemoral compartment, small lesions (<2 cm²) are frequently treated with debridement chondroplasty in both low- and high-demand subjects. However, in certain high-demand subjects and subjects who have failed a prior chondroplasty, both microfracture and osteochondral autograft are reliable options. If the subchondral bone plate is disrupted, then osteochondral autograft may be preferred because of the restoration of the entire osteochondral unit. There are several surgical options for medium (between 2 cm² and 4 cm²) and large (>4 cm²) lesions. In low-demand subjects, debridement chondroplasty, microfracture, and ACI are viable surface treatment options. The ability to obtain vertical walls (for both microfracture and ACI) is sometimes difficult because of peripheral defect location. This precludes containment of the mesenchymal clot in microfracture or chondrocyte containment in ACI. In the situation of poor lesion containment, osteochondral allograft may be the best surgical choice. In the situation of subchondral bone loss, osteochondral allograft and ACI (“sandwich technique” with bone graft) are both viable options. Failed surface treatments (e.g., microfracture, ACI) may be revised with osteochondral allograft.

p0310 In the patellofemoral compartment, the geometry of the articulating surfaces is very different from that of the femoral condyles. In addition to compressive load, a large amount of shear stress is placed on both native and repaired articular cartilage. Thus most articular cartilage repair and restoration procedures are performed in conjunction with a tibial tubercle osteotomy. In the presence of patella alta, a distalization is recommended. If the tibial tubercle to trochlear groove (TT-TG) distance is elevated (>20 mm), then an anteromedialization (Fulkerson-type) osteotomy is recommended. A caveat to anteromedialization is the proximal and/or medial patellar or trochlear lesion, because this defect location would be overloaded with the osteotomy. In the setting of concomitant lateral patellar instability and an incompetent medial patellofemoral ligament (MPFL), an MPFL reconstruction is warranted. As with the tibiofemoral compartment, small (<2 cm²) defects may be successfully addressed with debridement chondroplasty in both low- and high-demand patients. In certain high-demand subjects and in subjects that have failed a prior debridement, microfracture and osteochondral autograft may be useful for small trochlear lesions. However, in the patella, osteochondral graft (both autograft and allograft) may be difficult because of size, angle, and cartilage thickness mismatch limitations. For medium and large defects on the patella, the only technique able to successfully match the patellar articulating surface geometry is ACI. For medium and large trochlear lesions, both ACI and osteochondral allograft may be used. In the presence of subchondral bone loss, osteochondral allograft is appropriate. Following surface treatment (e.g., microfracture, ACI) failure, just as in the tibiofemoral compartment, lesions may be revised with osteochondral allograft.

p0315 In preparation for cartilage palliation techniques (chondroplasty, debridement, lavage, meniscectomy), standard knee arthroscopy equipment should be available. These include arthroscope, video tower, cannula(s), shavers, curettes, gouges, biters, graspers, and radio-frequency devices.

p0320 In preparation for cartilage repair (microfracture, drilling, abrasion, augmented scaffold-supported marrow-stimulation techniques), additional equipment should include microfracture awls of various angles, Kirschner wires, small-bore drill bits, other proprietary drills (PowerPick and PowerPick XL [Arthrex], which provides 1.5 mm-diameter drill, with 4- or 6-mm depth, at 30 or 45 degrees angle options, and NanoFx [Arthrosurface], which provides 1 mm-diameter drill, with 9-mm depth), and arthroscopic burs of various sizes. Additional matrix scaffold augmentation may be added to standard

marrow-stimulation techniques to stabilize the mesenchymal clot and potentially improve cell differentiation into a more hyaline-like cartilage repair. These include autologous matrix-induced chondrogenesis (AMIC), BioCartilage, and BST-CarGel. AMIC uses a porcine collagen (type I/III) matrix (Chondro-Gide, Geistlich Pharma) with conventional microfracture and fibrin glue. BioCartilage (Arthrex) is a homologous mixture of 1 mL of the patient’s platelet rich plasma (PRP) and 1 mL of BioCartilage, a dehydrated micronized allograft articular cartilage extracellular matrix, placed on a microfractured defect. BST-CarGel (Primal Healthcare) is a chitosan-based biopolymer mixture of the patient’s whole blood and a glycerophosphate buffer placed on a microfractured defect.

Currently, BioCartilage and DeNovo NT (Zimmer) are the only p0325 minced articular cartilage technologies commercially available for use in the United States. BioCartilage is an augmented marrow stimulation technique that relies upon the patient’s subchondral bone mesenchymal stem cells and PRP, in addition to the dehydrated minced juvenile allograft articular cartilage, to form the cartilage repair tissue. DeNovo NT is different from BioCartilage in that it intentionally does not violate the subchondral bone. DeNovo NT is a chondroconductive, chondroinductive, and chondrogenic product composed of 1 mm³ fragments of juvenile (<13 years) articular cartilage embedded in fibrin adhesive at the time of implantation. Similar to BioCartilage, DeNovo NT is “minimally manipulated” and thus does not require U.S. Food and Drug Administration (FDA) premarket approval. Also similarly, both BioCartilage and DeNovo NT take advantage of the greater migration and proliferation capacity of juvenile cells (vs. adult cells) without immunogenicity.

In preparation for cartilage restoration (osteochondral autograft, p0330 osteochondral allograft, ACI, other chondrocyte and mesenchymal stem cell-based therapies), additional equipment should include instruments and equipment for the open arthrotomy, including defect sizing tools, retractors, scissors, forceps, rongeurs, and scalpel blades. For osteochondral grafts, various sizes of osteochondral graft donor and recipient reamers and cannulated sizing blocks, osteochondral graft preparation back-table workstations, small oscillating saws, and saline pulse lavage are necessary. For ACI and other cell-based therapies, epinephrine-soaked neuropatties, thrombin, fibrin glue, mineral oil, glycerin, small (e.g., 6-0) absorbable suture, tuberculin syringe, 18-gauge plastic Angiocath, type I-III collagen membrane or periosteum, and cells are required.

For all cartilage repair or restoration techniques, the postoperative p0335 rehabilitation begins immediately following surgery. This requires preoperative acquisition of the postoperative equipment. These include continuous passive motion (CPM) machines, crutches, brace, ice cryotherapy and/or compression devices, and mechanical thromboembolic disease socks (e.g., thromboembolic hose, compression stockings).

INTRAOPERATIVE EVALUATION AND OPERATIVE TECHNIQUE

s0065

Tourniquets are frequently used in knee arthroscopy and arthrotomy. Their use in articular cartilage repair and restoration requires cognizance of their inflation status during surgery. If inflated during marrow-stimulation techniques, the tourniquet should be deflated and the arthroscopic pump turned off to visualize subchondral marrow content (fat and blood) exude to verify sufficient depth of penetration of awl, drill, or wire. In ACI, it is critical to ensure the tourniquet is deflated during defect preparation so that complete hemostasis may be achieved before chondrocyte implantation.

Evaluation of the defect via arthroscopy or arthrotomy is standard- p0385 ized and should include assessment and recording of size (measured

CRITICAL POINTS Intraoperative Evaluation and Operative Technique

- Deflate tourniquet during marrow-stimulation techniques to observe subchondral marrow contents (fat and blood) exuding to ensure sufficient depth of penetration of awl, drill, pick, or wire.
- Deflate tourniquet during autologous chondrocyte implantation during defect preparation so that complete hemostasis can be achieved before chondrocyte implantation.
- Assess and record defect size, depth, location, shape, number, and wall status.
- Ensure complete removal of abnormal, unstable, damaged articular cartilage back to stable rim with vertical walls.
- If unable to obtain vertical walls because of reaching peripheral articular cartilage edge, it is better to leave some damaged cartilage to form a wall for cartilage fill rather than removing it so that no wall would be able to contain cartilage fill.
- Removal of the calcified cartilage zone is important in both microfracture and autologous chondrocyte implantation.
- Avoid excessive subchondral bone removal, as this may stimulate overgrowth and intralesional osteophyte formation.

in anterior to posterior plane and medial to lateral plane), depth (partial thickness, full thickness without subchondral bone loss, full thickness with bone loss), location (femoral condyle, trochlea, patella, tibial plateau), number (single vs. multiple, “kissing” bipolar lesions), shape (defect shape in relation to condyle shape), and wall status (lesion with contained vertical walls or uncontained peripheral lesions). Defect preparation should include sharp removal of unstable loose damaged articular cartilage back to intact healthy articular cartilage with full-thickness vertical walls. In both microfracture and ACI, removal of the zone of calcified cartilage improves repair tissue integration with the underlying subchondral bone. Violation of the subchondral bone should be avoided, especially with ACI, because this causes bleeding and greater proportions of fibrocartilage repair. Excessive removal of subchondral bone also may stimulate subchondral bone overgrowth, intralesional osteophyte formation, and eventual repair breakdown.

Osteochondral allograft is an open single-stage articular cartilage restoration procedure in the knee. The surgical approach and technique vary based on lesion location, with either a medial or lateral parapatellar miniarthrotomy used for exposure. Defect preparation involves recipient site sizing and assurance that the surrounding normal osteochondral unit is stable, with sufficient walls to support the donor plug. The recipient site is reamed to a depth with a healthy subchondral bone bed (typically 6-9 mm). The recipient site articular cartilage thickness is measured at multiple clock-face references (typically 12, 3, 6, and 9 o'clock). The donor allograft is obtained from a qualified tissue bank, with the graft stored at 4° C and used between 14 and 28 days following harvest. It is opened and soaked in cold saline to avoid dramatic temperature changes, which may be chondrotoxic. A surface area- and depth-matched donor plug is then prepared. Before implantation, the donor plug is washed with sterile saline pulse lavage to remove any potential immunogenic subchondral bone marrow elements. The plug is then manually press-fit into the recipient site with gentle finger pressure. It is critical to ensure flush placement of the donor plug in the recipient site because proud or recessed plug placement has been shown to significantly increase contact pressure and subsequent articular cartilage degeneration.¹¹ If secure graft fixation is questionable, then a recessed bioabsorbable screw may be placed in the center of the graft.

ACI is a two-stage cartilage restoration procedure in the knee. Stage one involves a knee arthroscopy, defect assessment, and cartilage biopsy, followed by a chondrocyte culture expansion in vitro. The biopsy may be obtained from multiple locations. However, it is usually taken from the superior lateral (or medial) edge of the intercondylar notch. The biopsy is taken with a sharp curette or gouge, approximately 5 mm wide, 10 to 14 mm long, and is 200 to 300 milligrams and contains approximately 200,000 to 300,000 chondrocytes. This can yield up to four vials of 12 million chondrocytes per vial. The cells are cryopreserved for up to 2 years. After the surgical date is selected, the cells are thawed and cultured for 4 weeks. Upon delivery the day (or the day before) of surgery, the cells expire within 48 hours.

The second stage of ACI involves either a medial or lateral parapatellar miniarthrotomy for exposure. Defect preparation involves removal of all unstable, loose, degenerated articular cartilage with creation of stable normal vertical walls. The calcified cartilage zone should be removed. However, do not be too aggressive in removal of this layer, because it will stimulate subchondral bleeding and subsequent fibrocartilage formation. If bleeding is encountered (with the tourniquet down), epinephrine- or thrombin-soaked neuropatties should be used to obtain complete hemostasis. The risk of periosteal hypertrophy precludes use of periosteum for a graft cover.²⁹ Currently, most surgeons use a type I-III porcine collagen membrane (considered off-label use) for the chondrocyte cover. The porous side of the membrane may or may not (surgeon preference) be seeded with chondrocytes before suturing into the defect. Absorbable 6-0 suture is used (with mineral oil lubrication) in simple interrupted fashion, spaced 2 to 3 mm apart. The needle is initially passed on the patch side then through the articular cartilage. The needle should exit the articular cartilage approximately 3 mm from the edge of the lesion. The suture knot should be placed on the patch side, relatively recessed in relation to the surface of the surrounding articular cartilage. The final one or two suture locations should be at the most superior aspect of the defect, so that none of the chondrocyte solution may leak out (following a watertightness test). The suture line may be reinforced for water-tightness with fibrin glue. An 18-gauge Angiocath and a tuberculin syringe are used to aspirate the resuspended cell solution. The solution is injected under the patch, the patch sutured closed, and then fibrin glued. Intraarticular drains should not be used postoperatively to avoid iatrogenic damage to the patch, cells, or both.

Postoperative rehabilitation is similar for both osteochondral allograft and ACI. Defect location (tibiofemoral versus patellofemoral) dictates the weight bearing and motion restrictions following surgery. For tibiofemoral lesions, a brief (6 weeks) non-weight-bearing period commences following surgery (contrary to patellofemoral, in which weight bearing can begin as long as the knee is locked in extension in a brace). CPM is important in the early postoperative period (first 6 weeks) because the biological properties of articular cartilage and range of motion are significantly improved with CPM.³⁶ Weight bearing progresses from 6 through 12 weeks, while full symmetric pain-free motion is concurrently achieved. Core and lower extremity strengthening continues beyond 3 months and functional sport-specific training may begin between 3 and 6 months. However, return to sport is restricted to beyond 9 to 12 months. Concurrent meniscal allograft transplantation and/or osteotomy may alter weight-bearing and motion limitations in the first 6 to 8 weeks after surgery.

CLINICAL OUTCOMES

Several synthetic systematic reviews and metaanalyses have been published that report on clinical, radiographic, and histologic outcomes after articular cartilage surgery in the knee. Overall, early clinical

reports were small, retrospective case series of levels III and IV evidence. Later publication dates have increasingly yielded larger, high-quality, level I evidence randomized comparative trials. Overall, with time, the level of evidence and methodological quality of knee articular cartilage surgery publications have significantly improved.²⁸ The rapid proliferation of the number of original research and synthetic review publications prompted the development of a valid and reliable knee articular cartilage condition-specific study methodological quality score.²³

p0415 A systematic review of level I and II evidence studies on clinical outcomes after microfracture identified 15 studies (6 long term and 9 short term) for analysis.¹⁹ These investigations compared microfracture to either ACI or osteochondral graft (autograft or allograft). At short-term follow-up in younger subjects, low-demand subjects, and those with smaller lesion size, microfracture demonstrated good clinical outcomes. However, beyond 5 years after surgery, treatment failures and osteoarthritis were observed, regardless of lesion size. This review parallels the findings of other systematic reviews and meta-analyses. A level IV evidence meta-analysis of articular cartilage repair in athletes revealed that microfracture outcomes deteriorated with time.²² Significantly better clinical outcomes were observed with either ACI or osteochondral autograft. Results after microfracture were significantly worse with larger defect size (> 4 cm²). Rate of return to sport was significantly lower after microfracture versus ACI or osteochondral autograft. A separate but similar systematic review identified age, level of play, preoperative duration of symptoms, defect size, and repair tissue morphology as significant predictors of return to sport in athletes after microfracture.³⁹ A significant limitation of these reviews with regard to microfracture is that many fail to address and/or discuss concomitant pathology.²⁵ Several investigations compare “cartilage restoration” techniques, such as ACI or osteochondral autograft (which often have simultaneous correction of alignment and meniscus), to microfracture (which is frequently performed in isolation). Thus this bias remains unaddressed and a current limitation of the articular cartilage literature.

p0420 Just as in microfracture, several systematic reviews and meta-analyses of ACI exist, analyzing short- to long-term outcomes and comparing with osteochondral graft and marrow stimulation procedures. Within these investigations, several compare different generations of ACI, with identification of optimal outcomes and avoidance of complications. A level I and II evidence systematic review demonstrated that a collagen membrane base was significantly better than periosteal cover ACI.¹⁷ Further, matrix-associated had similar outcomes to collagen membrane-based ACI. However, the strength of the evidence in the latter review was weak because of short duration of follow-up, small numbers of subjects, medium-sized lesions, and younger ages of subjects. A separate but similar systematic review of level I and II evidence studies compared ACI with microfracture and osteochondral autograft.³⁰ Microfracture outcomes deteriorated after 18 to 24 months. ACI and osteochondral autograft demonstrated similar improvements in short-term outcomes. Younger subjects and those with shorter preoperative duration of symptoms and fewer prior surgical interventions had the best outcomes after both microfracture and ACI. Defect size greater than 4 cm² was predictive of significantly improved outcomes versus microfracture or osteochondral autograft.

p0425 A systematic review of 82 studies (over 5000 subjects and 6000 defects) analyzed the rate of failures, complications, and reoperations after all generations of ACI.²⁹ The failure rate after was low (1.5%-7.7%) across all generations. Failure rate (7.7%) and unplanned reoperation rate (27%) was highest after periosteal cover ACI. Graft hypertrophy and delamination was most commonly observed after periosteal cover ACI. Arthrofibrosis was most common after arthroscopy-based ACI (versus all-arthroscopic implantation).

A systematic review of level I and II evidence clinical outcomes after osteochondral cylinder techniques analyzed eight studies (in comparison with microfracture and ACI).¹⁸ Superior clinical outcomes and earlier return to sport was demonstrated after osteochondral autograft versus microfracture. Although mean lesion size was small (<3 cm²), there was no significant observed difference between osteochondral autograft and ACI. Histologic examination consistently demonstrated hyaline cartilage in the transplanted plugs but no hyaline cartilage between the plugs.

No level I or II evidence exists regarding osteochondral allograft use in the knee. However, for focal and diffuse single-compartment chondral or osteochondral lesions, osteochondral allograft predictably and significantly improves patient-reported outcomes and results in high patient satisfaction.⁷ At 5-year follow-up, overall satisfaction approaches 90% and 65% of patients have little or no radiographic osteoarthritis. Short-term complications are infrequent (<3%). Failures, although variably defined (repeat surgery, revision cartilage surgery, osteotomy, or conversion to arthroplasty), are uncommon (<18%). Survival rates decline with time: 91% to 95% at 5 years,^{12,20} 76% to 85% at 10 years,^{12,20} and 74% to 76% at 15 years.^{12,20} Prognostic factors that may negatively influence clinical outcomes include diagnosis of spontaneous osteonecrosis of the knee, bipolar lesions, age greater than 50 years, patellofemoral lesions, Workers' Compensation status, preoperative duration of symptoms greater than 12 months, and failure to address malalignment or meniscal deficiency.⁷

REFERENCES

1. Alford J, Lewis P, Kang R, Cole B. Rapid progression of chondral disease in the lateral compartment of the knee following meniscectomy. *Arthroscopy*. 2005;21(12):1505-1509.
2. Aroen A, Loken S, Heir S, et al. Articular cartilage lesions in 993 consecutive knee arthroscopies. *Am J Sports Med*. 2004;32:211-215.
3. Behery O, Siston RA, Harris JD, Flanigan DC. Treatment of cartilage defects of the knee: expanding on the existing algorithm. *Clin J Sport Med*. 2014;24(1):21-30.
4. Behery OA, Harris JD, Karnes JM, Siston RA, Flanigan DC. Factors Influencing the Outcome of Autologous Chondrocyte Implantation: A Systematic Review. *J Knee Surg*. 2012.
5. Braun HJ, Wilcox-Fogel N, Kim HJ, Pouliot MA, Harris AH, Dragoo JL. The effect of local anesthetic and corticosteroid combinations on chondrocyte viability. *Knee Surg Sports Traumatol Arthrosc*. 2012;20(9):1689-1695.
6. Brophy R, Zeltser D, Wright R, Flanigan D. Anterior cruciate ligament reconstruction and concomitant articular cartilage injury: Incidence and treatment. *Arthroscopy*. 2010;26(1):112-120.
7. Chahal J, Gross AE, Gross C, et al. Outcomes of osteochondral allograft transplantation in the knee. *Arthroscopy*. 2013;29(3):575-588.
8. Chu CR, Coyle CH, Chu CT, et al. In vivo effects of single intraarticular injection of 0.5% bupivacaine on articular cartilage. *J Bone Joint Surg Am*. 2010;92(3):599-608.
9. Curl W, Krome J, Gordon E, Rushing J, Smith B, Poehling G. Cartilage Injuries: A Review of 31,516 Knee Arthroscopies. *Arthroscopy*. 1997;13(4):456-460.
10. Dragoo JL, Danial CM, Braun HJ, Pouliot MA, Kim HJ. The chondrotoxicity of single-dose corticosteroids. *Knee Surg Sports Traumatol Arthrosc*. 2012;20(9):1809-1814.
11. Elguizaoui S, Flanigan DC, Harris JD, Parsons E, Litsky AS, Siston RA. Proud osteochondral autograft versus synthetic plugs—contact pressures with cyclical loading in a bovine knee model. *Knee*. 2012;19(6):812-817.
12. Emmerson BC, Gortz S, Jamali AA, Chung C, Amiel D, Bugbee WD. Fresh osteochondral allografting in the treatment of osteochondritis dissecans of the femoral condyle. *Am J Sports Med*. 2007;35(6):907-914.
13. Flanigan DC, Harris JD, Brockmeier PM, Lathrop RL, Siston RA. The effects of defect size, orientation, and location on subchondral bone

- contact in oval-shaped experimental articular cartilage defects in a bovine knee model. *Knee Surg Sports Traumatol Arthrosc.* 2012.
14. Flanigan DC, Harris JD, Brockmeier PM, Siston RA. The effects of lesion size and location on subchondral bone contact in experimental knee articular cartilage defects in a bovine model. *Arthroscopy.* 2010;26(12):1655-1661.
 15. Flanigan DC, Harris JD, Trinh TQ, Siston RA, Brophy RH. Prevalence of chondral defects in athletes' knees: a systematic review. *Med Sci Sports Exerc.* 2010;42(10):1795-1801.
 16. Fregly BJ, Besier TF, Lloyd DG, et al. Grand challenge competition to predict in vivo knee loads. *J Orthop Res.* 2012;30(4):503-513.
 17. Goyal D, Goyal A, Keyhani S, Lee EH, Hui JH. Evidence-based status of second- and third-generation autologous chondrocyte implantation over first generation: a systematic review of level I and II studies. *Arthroscopy.* 2013;29(11):1872-1878.
 18. Goyal D, Keyhani S, Goyal A, Lee EH, Hui JH, Vaziri AS. Evidence-based status of osteochondral cylinder transfer techniques: a systematic review of level I and II studies. *Arthroscopy.* 2014;30(4):497-505.
 19. Goyal D, Keyhani S, Lee EH, Hui JH. Evidence-based status of microfracture technique: a systematic review of level I and II studies. *Arthroscopy.* 2013;29(9):1579-1588.
 20. Gross AE, Shasha N, Aubin P. Long-term followup of the use of fresh osteochondral allografts for posttraumatic knee defects. *Clin Orthop Relat Res.* 2005;435:79-87.
 21. Guettler J, Demetropoulos C, Yang K, Jurist K. Osteochondral defects in the Human Knee-Influence of defect size on cartilage rim stress and load redistribution to surrounding cartilage. *Am J Sports Med.* 2004;32(6):1451-1458.
 22. Harris J, Brophy R, Siston R, Flanigan D. Treatment of chondral defects in the athlete's knee. *Arthroscopy.* 2010;26(6):841-852.
 23. Harris J, Erickson B, Cvetanovich GL, et al. Development of a Valid and Reliable Knee Articular Cartilage Condition-Specific Study Methodological Quality Score. *Orthop J Sports Med.* 2014;2(2):1-9.
 24. Harris J, McNeilan R, Siston R, Flanigan D. Survival and clinical outcome of isolated high tibial osteotomy and combined biological knee reconstruction. *Knee.* 2013.
 25. Harris J, Walton D, Erickson B, et al. Return to Sport and Performance After Microfracture in the Knees of National Basketball Association Players. *Orthop J Sports Med.* 2013;1(6):1-8.
 26. Harris J, Yanke A, Espinoza Orias AA, et al. Effect of Vertical or Beveled Chondral Defect Creation on Rim Deformation. Paper presented at: International Cartilage Repair Society 11th World Congress; September 18, 2013, 2013; Izmir, Turkey.
 27. Harris JD, Cavo M, Brophy R, Siston R, Flanigan D. Biological knee reconstruction: a systematic review of combined meniscal allograft transplantation and cartilage repair or restoration. *Arthroscopy.* 2011;27(3):409-418.
 28. Harris JD, Erickson BJ, Abrams GD, et al. Methodologic quality of knee articular cartilage studies. *Arthroscopy.* 2013;29(7):1243-1252, e1245.
 29. Harris JD, Siston RA, Brophy RH, Lattermann C, Carey JL, Flanigan DC. Failures, re-operations, and complications after autologous chondrocyte implantation—a systematic review. *Osteoarthritis Cartilage.* 2011;19(7):779-791.
 30. Harris JD, Siston RA, Pan X, Flanigan DC. Autologous chondrocyte implantation: a systematic review. *J Bone Joint Surg Am.* 2010;92(12):2220-2233.
 31. Heir S, Nerhus T, Rotterud J, et al. Focal cartilage defects in the knee impair quality of life as much as severe osteoarthritis. *Am J Sports Med.* 2010;38(2):231-237.
 32. Henderson IJ, La Valette DP. Subchondral bone overgrowth in the presence of full-thickness cartilage defects in the knee. *Knee.* 2005;12(6):435-440.
 33. Hjelle K, Solheim E, Strand T, Muri R, Brittberg M. Articular cartilage defects in 1,000 knee arthroscopies. *Arthroscopy.* 2002;18(7):730-734.
 34. Kanneganti P, Harris JD, Brophy RH, Carey JL, Lattermann C, Flanigan DC. The effect of smoking on ligament and cartilage surgery in the knee: a systematic review. *Am J Sports Med.* 2012;40(12):2872-2878.
 35. Kaplan L, Schurhoff M, Selesnick H, Thorpe M, Uribe J. MRI of the knee in asymptomatic professional basketball players. *Arthroscopy.* 2005;21(5):557-561.
 36. Knapik DM, Harris JD, Pangrazzi G, et al. The basic science of continuous passive motion in promoting knee health: a systematic review of studies in a rabbit model. *Arthroscopy.* 2013;29(10):1722-1731.
 37. Kocher MS, DiCanzio J, Zurakowski D, Micheli LJ. Diagnostic performance of clinical examination and selective magnetic resonance imaging in the evaluation of intraarticular knee disorders in children and adolescents. *Am J Sports Med.* 2001;29(3):292-296.
 38. Mach DB, Rogers SD, Sabino MC, et al. Origins of skeletal pain: sensory and sympathetic innervation of the mouse femur. *Neuroscience.* 2002;113(1):155-166.
 39. Mithoefer K, Hambly K, Della Villa S, Silvers H, Mandelbaum BR. Return to sports participation after articular cartilage repair in the knee: scientific evidence. *Am J Sports Med.* 2009;37(suppl 1):167S-176S.
 40. Quatman CE, Harris JD, Hewett TE. Biomechanical outcomes of cartilage repair of the knee. *J Knee Surg.* 2012;25(3):197-206.
 41. Reilly DT, Martens M. Experimental analysis of the quadriceps muscle force and patello-femoral joint reaction force for various activities. *Acta Orthop Scand.* 1972;43(2):126-137.
 42. Schipplein OD, Andriacchi TP. Interaction between active and passive knee stabilizers during level walking. *J Orthop Res.* 1991;9(1):113-119.
 43. Trinh TQ, Harris JD, Siston RA, Flanigan DC. Improved Outcomes With Combined Autologous Chondrocyte Implantation and Patellofemoral Osteotomy Versus Isolated Autologous Chondrocyte Implantation. *Arthroscopy.* 2013.
 44. Walczak BE, McCulloch PC, Kang RW, Zelazny A, Tedeschi F, Cole BJ. Abnormal findings on knee magnetic resonance imaging in asymptomatic NBA players. *J Knee Surg.* 2008;21(1):27-33.
 45. Widuchowski W, Widuchowski J, Trzaska T. Articular cartilage defects: Study of 25,124 knee arthroscopies. *Knee.* 2007;14:177-182.