

Shoulder

4

Brian J. Cole, M.D., and Leonid I. Katolik, M.D.

I. Anatomy

A. Osteology. The shoulder is a complex structural unit composed of three bones—the clavicle, scapula, and humerus—and four articulations—the acromioclavicular (AC), sternoclavicular (SC), scapulothoracic (ST), and glenohumeral (GH) joints.

1. Clavicle (Fig. 4-1). The clavicle is S-shaped and is the first bone in the body to ossify and the last to fuse (the medial growth plate fuses in the early 20s). The clavicle articulates with the manubrium of the sternum through the SC joint, a gliding joint with a complete intra-articular disk. Elevation of the arm from 0° to 90° results in rotation along its longitudinal axis of up to 30° and elevation of the clavicle at the SC joint of approximately 0° to 40°.

The clavicle is attached to the scapula through the AC joint ligaments and to the coracoid by the coracoclavicular (CC) ligaments (the conoid medially and the trapezoid laterally). The AC ligaments primarily prevent anteroposterior instability of this joint and the CC ligaments prevent inferior displacement of the acromion and coracoid from the distal clavicle. The AC joint has an incomplete intra-articular disk, potentially predisposing it to degenerative changes.

2. Scapula (Figs. 4-2, 4-3, and 4-4). The scapula is the site of 17 muscle insertions and origins. It articulates with the chest wall (posterior ribs 2-7). It is angled 30° anterior and has a 3° upward tilt. There are two major ST bursae: the *scapulothoracical* (between the trapezius and the superomedial angle of the scapula) and the *infraserratus* (between the chest wall and the serratus anterior). Less consistently there exists a supraserratus bursa (between the subscapularis and the serratus anterior). Occasionally, these become inflamed and may cause pain. There are also several adventitial bur-

sae that arise in response to injury or irritation (Fig. 4-5).

The scapula has two important prominences. The *coracoid process* is the origin of the conjoined tendon (the short head of the biceps and the coracobrachialis), the insertion of the pectoralis minor, and the attachment site for the coracoacromial (CAL), coracohumeral, and transverse scapular ligaments. The *acromion* is the broad dorso-lateral expansion of the scapular spine. It is the site of origin of most of the deltoid muscle and serves as the insertion site for part of the trapezius muscle and the CAL.

3. Humeral Head (Figs. 4-6 and 4-7). The humeral head approximates a sphere in 90% of individuals, with an average diameter of 43 mm. It is normally retroverted an average of 30° relative to the transepicondylar axis of the distal humerus. The articular surface is inclined an average of 130° superiorly relative to the shaft. The humeral head may also be offset medially and posteriorly up to 1 cm relative to the axis of the humeral shaft. The greater (GT) and lesser (LT) tuberosities located on opposite sides of the bicipital groove are the attachment sites for the rotator cuff tendons (GT—supraspinatus, infraspinatus, teres minor; LT—subscapularis). The long head of the biceps tendon is constrained in the bicipital groove by the transverse humeral ligament and the subscapularis tendon.
4. Glenoid. The lateral thickening of the scapula provides the bony articulation with the humeral head. Version of the glenoid may range from 7° of retroversion to 10° of anteversion, with an average of 5° of upward tilt. The surface is pear-shaped and is approximately 20% narrower superiorly than inferiorly. The average vertical and transverse diameters are 35 and 25 mm, respectively.

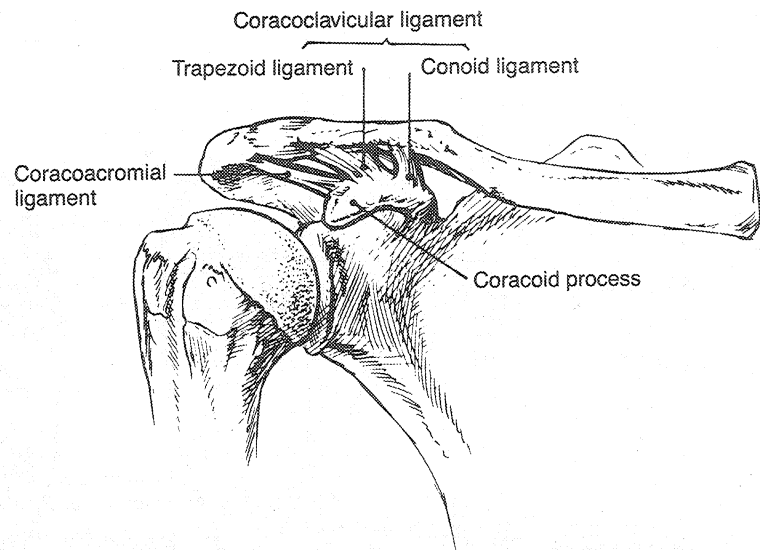


Figure 4-1. Anatomy of the acromioclavicular and coracoclavicular ligaments. *A*, Drawing demonstrating ligaments attached to the coracoid process. *B*, Dissection specimen showing the coracoclavicular ligament consisting of the conoid ligament (C) and trapezoid ligament (T). Also shown are the coracoacromial ligament (CA), acromioclavicular ligament and joint (AC), and conjoined (conj.) tendon.

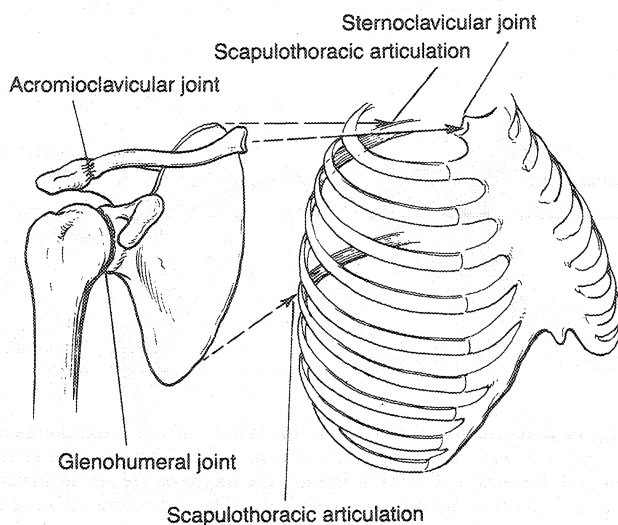
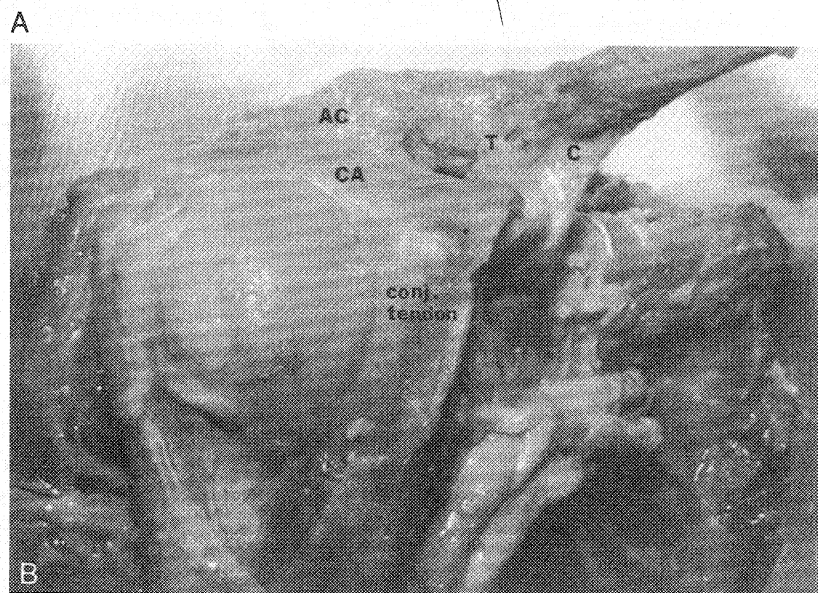


Figure 4-2. The shoulder girdle is attached to the thorax via the sternoclavicular and scapulothoracic articulations. (From Warner JJP, Caborn DN: Overview of shoulder instability. *Crit Rev Phys Rehabil Med* 4:145-198, 1992.)

B. Glenohumeral Joint. The glenohumeral joint is congruent articulation with <2 mm mismatch in the radius of the curvature between the glenoid and the humeral head. This minimal size mismatch contributes to a relative lack of intrinsic stability; however, the matched concavity and convexity of articular surfaces provide stability when muscle forces compress the joint. Although it approximates ball-and-socket kinematics, only one third of the humeral head is covered by the glenoid in any position of rotation.

1. **Glenohumeral Ligaments** (Figs. 4-8 and 4-9; Color Figures 13 and 14). These are discrete capsular thickenings that function as checkreins at the limits of rotation, preventing excessive GH translation that occurs with joint instability. Significant variation in the presence and size of these ligaments exists. Their function is dependent on arm position and the direction of applied force on the shoulder joint.

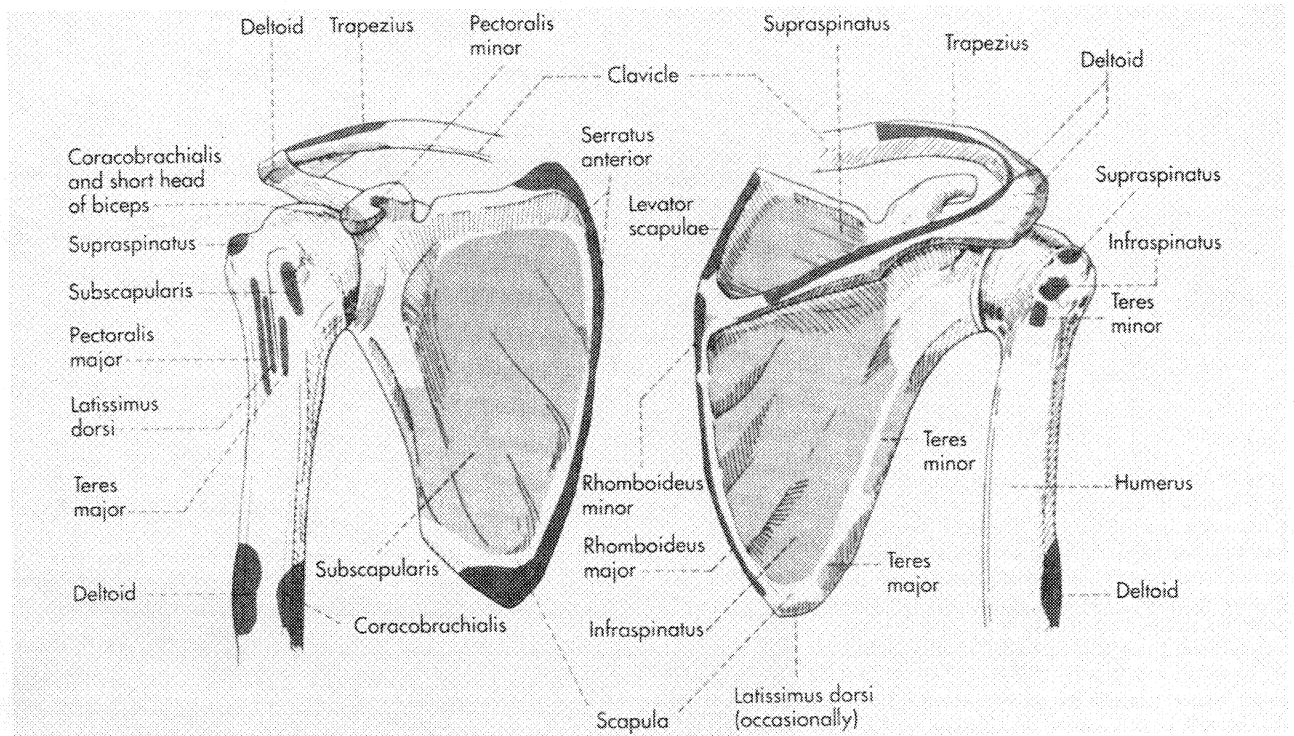


Figure 4-3. Origins and insertions of shoulder girdle muscles. (From Jenkins DB: Hollinshead's Functional Anatomy of the Limbs and Back, 6th ed. Philadelphia: WB Saunders, 1991.)

2. Glenoid Labrum (Fig. 4-10). This is a fibrous ring attaching to the glenoid articular surface through a fibrocartilaginous transition zone and an anchor point for capsuloligamentous structures. Below the glenoid equator the labrum is firmly attached. Above the equator it is more mobile and meniscal in nature. Decreased vascularity of the superior labrum may explain its vulnerability to disruptions (superior labrum anterior-posterior [SLAP] lesions). It deepens the glenoid socket, thus enhancing the con-

cavity-compression effect created with muscle contraction.

C. Muscles (see Fig. 4-3; Table 4-1). Shoulder girdle muscles originate from and insert onto the acromion, clavicle, coracoid, scapula spine and body, glenoid, and proximal humerus. Normal function is requisite to maintaining glenohumeral stability and pain-free range of motion.

II. Biomechanics

A. Introduction. The shoulder is a minimally constrained articulation. Soft tissue structures acting in concert with joint architecture play a

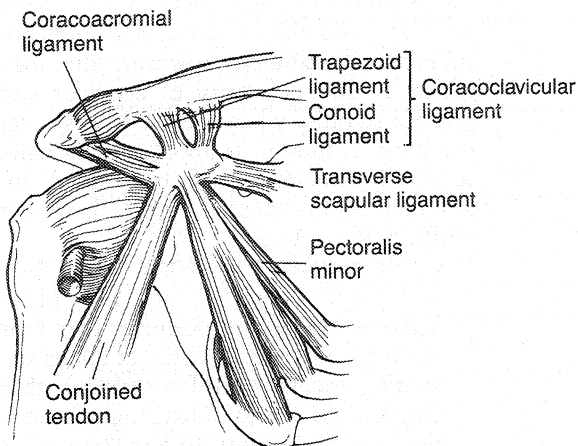


Figure 4-4. Attachments of muscles and ligaments to the coracoid process.

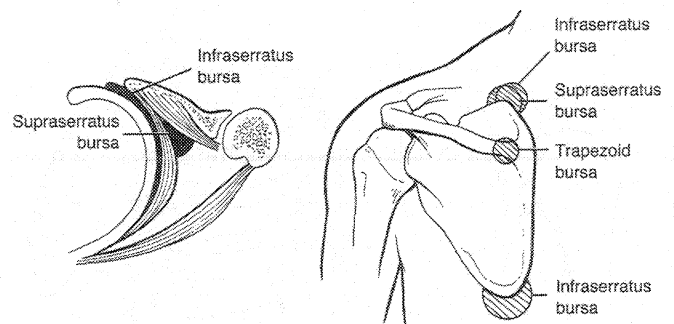
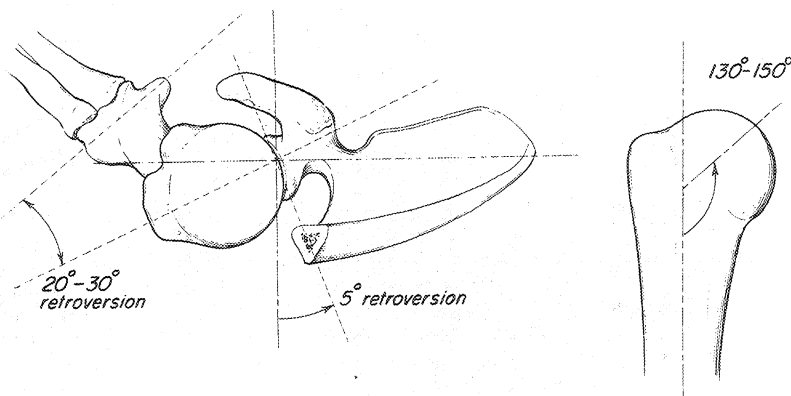


Figure 4-5. Anatomic and adventitial bursae of the scapulothoracic articulation. *Left*, The infraserratus bursa is found between the serratus and the chest wall. Its borders are the origin of the serratus laterally and the rhomboid muscles medially. The supraserratus bursa is found between the serratus anterior and the subscapularis, with the lateral border extending to the insertion of the serratus. *Right*, Sites where symptomatic bursae may occur and the bursae that are affected. (From Kuhn JE, Plancher KD, Hawkins RJ: Symptomatic scapulothoracic crepitus and bursitis. J Am Acad Orthop Surg 6:268, 1998.)

Figure 4-6. Normal articular orientations of the glenohumeral joint. (From Warner JJP, Caborn DN: Overview of shoulder instability. Crit Rev Phys Rehabil Med 4:145-198, 1992.)



major role in maintaining stability. An understanding of the biomechanics of the shoulder requires an appreciation of the joint anatomy as well as an understanding of the static and dynamic factors that confer joint stability.

B. Static Restraints

1. **Articular Version.** The combined retroversion of the glenoid and the humeral head is 30° to 40°. Excessive retroversion or increased anteversion is occasionally associated with instability and may play a role in the development of arthritis.
2. **Articular Conformity (Fig. 4-11).** Articular conformity provides the foundation for the rotator cuff muscles to establish a concavity-compression effect. Only 25% to 30% of the humeral articular surface is in contact with the glenoid at any position of arm rotation. Saha has described this as the *glenohumeral index*, which is proportionate to the degree of glenohumeral stability ($GH = x/y$, where x and y represent the diameters of the glenoid and humeral head, respectively). Conditions such as glenoid dysplasia, glenoid fracture, and labral detachment reduce the GH index, making the joint more susceptible to instability due to decreased articular surface area and glenoid socket depth.

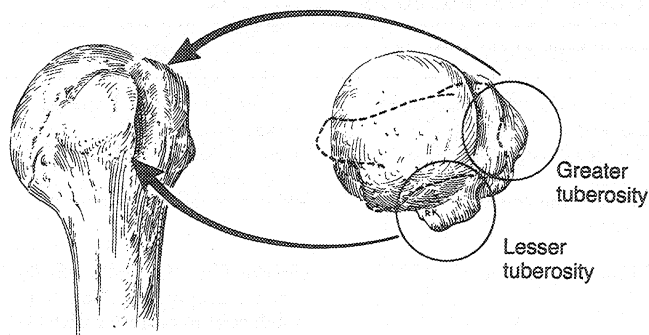


Figure 4-7. Relationship of greater and lesser tuberosities to the bicipital groove. (From Jobe CM: Gross anatomy of the shoulder. In Rockwood CA Jr, Matsen FA III [eds]: The Shoulder. Philadelphia: WB Saunders, 1990, p 47.)

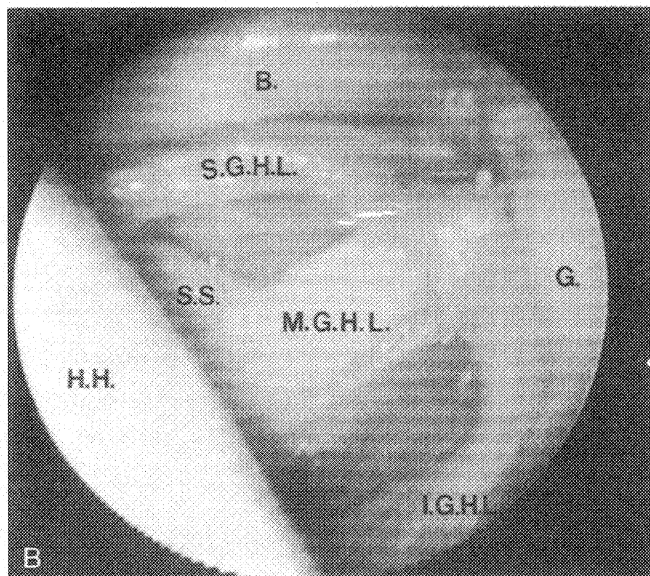
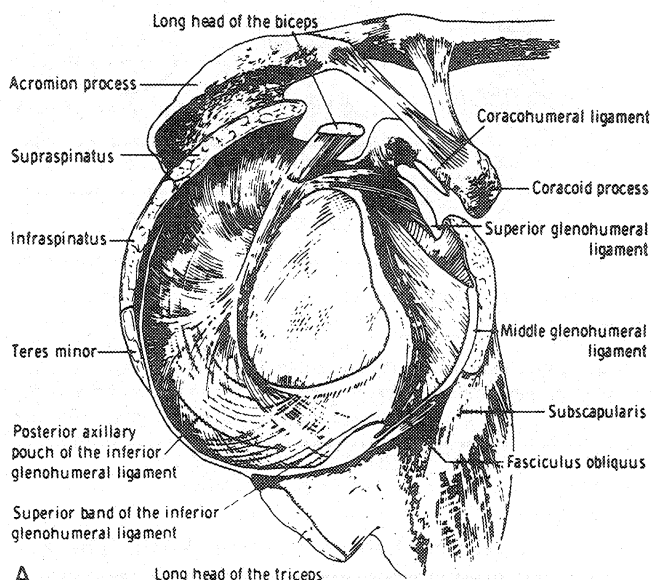


Figure 4-8. Glenohumeral ligaments. *A*, Anatomic identification. *B*, Arthroscopic view. B., biceps; H.H., humeral head; G., glenoid; S.S., subscapularis tendon; S.G.H.L., superior glenohumeral ligament; M.G.H.L., middle glenohumeral ligament; I.G.H.L., inferior glenohumeral ligament.

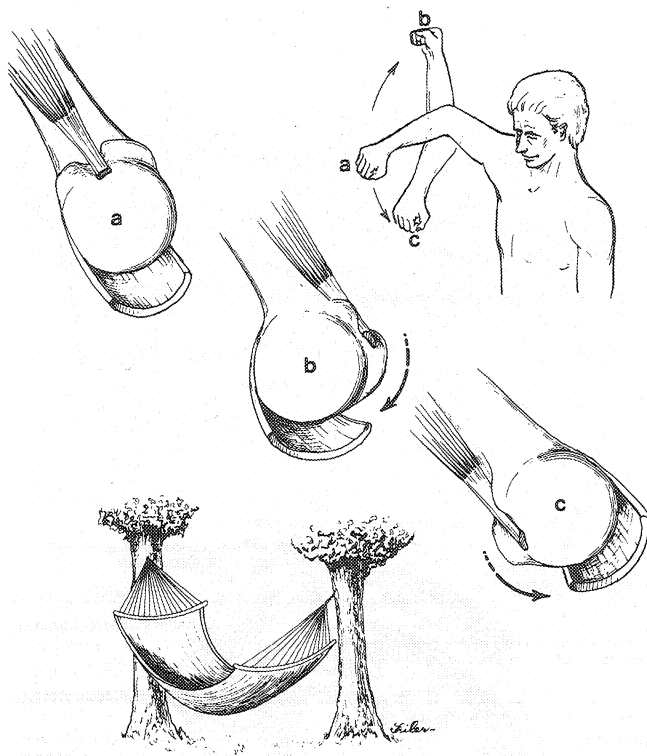


Figure 4-9. The inferior glenohumeral complex prevents anterior, posterior, and inferior dislocation by functioning like a hammock that supports the humeral head. With the arm in neutral, the ligament complex is relatively static (a). In external rotation (b) and internal rotation (c), the ligament complex rotates to the front and back of the shoulder, respectively, functioning as a checkrein against dislocation of the humeral head. (From Warner JJP, Caborn DN: Overview of shoulder instability. Crit Rev Phys Rehabil Med 4:145-198, 1992.)

3. **Glenoid Labrum** (see Fig. 4-10). The glenoid labrum increases the depth and surface area of the glenoid. As an anchor point for the capsuloligamentous structures, it deepens the glenoid concavity, reducing the tendency for excessive glenohumeral translation with arm motion. Labrum excision decreases the

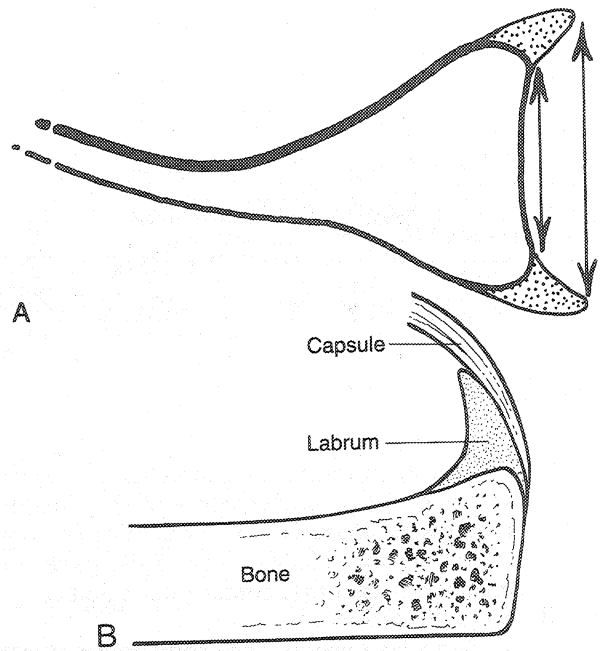


Figure 4-10. A, Superior (coronal) view of the scapula and glenoid. The glenoid labrum is a fibrocartilaginous extension of the edges of the glenoid that increases the surface area and depth of the glenoid fossa, thereby increasing stability of the joint. (From Warner JJP, Caborn DN: Overview of shoulder instability. Crit Rev Phys Rehabil Med 4:145-198, 1992.) B, Transverse section through the glenoid. Note that the capsule is intimately associated with the labrum.

depth of the socket by 50% and reduces resistance to instability by 20%.

4. **Negative Intra-Articular Pressure** (Fig. 4-12). The shoulder joint acts as a closed compartment with a flexible diaphragm. The weight of the arm tending to pull the joint surfaces away from one another causes a negative pressure (vacuum effect) resisting distraction in proportion to the force tending to displace the humeral head. In addition, there exists an *adhesion-cohesion* stabilizing effect secondary to the viscous and

Table 4-1.

Shoulder Muscle Origin, Insertion, and Function

Muscle	Origin	Insertion	Action
Trapezius	Superior nuchal line, ligamentum nuchae, spinous processes C7-T12	Lateral third of clavicle, acromion and scapular spine	Elevates, retracts, and rotates, scapula
Latissimus dorsi	Spinous processes T6-12, thoracolumbar fascia, iliac crest, inferior 3 ribs	Floor of intertubercular groove of humerus	Extends, adducts, medially rotates humerus
Teres major	Dorsum of inferior angle of scapula	Medial crest of intertubercular groove of humerus	Adducts, medially rotates arm
Deltoid	Lateral third of clavicle, acromion, scapular spine	Deltoid tuberosity of humerus	Anterior fibers flex and medially rotate arm; medial fibers abduct arm; posterior fibers extend and laterally rotate arm
Subscapularis	Subscapular fossa	Lesser tuberosity	Medially rotates and adducts arm
Supraspinatus	Supraspinatus fossa	Superior facet of greater tuberosity	Abducts arm with deltoid
Infraspinatus	Infraspinous fossa	Middle facet of greater tuberosity	Laterally rotates arm
Teres minor	Superior-lateral border of scapula	Inferior facet of greater tuberosity	Laterally rotates arm

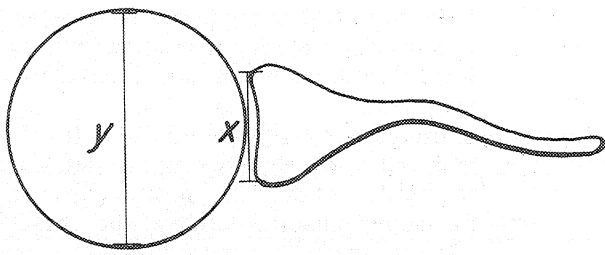


Figure 4-11. Glenohumeral index ($GH_1 = x/y$). This illustrates the size mismatch between the glenoid diameter and humeral head diameter. (From Warner JJP, Carbon DN: Overview of shoulder instability. *Crit Rev Phys Rehabil Med* 4:145-198, 1992.)

intermolecular properties of the synovial fluid. This is analogous to water tending to keep two glass surfaces together. These factors seem to play a role only in low-load situations and are relatively unimportant in clinical instability.

5. Capsuloligamentous Structures (see Figs. 4-8, 4-9, 4-13, and 4-14). These are discrete capsular thickenings composed primarily of type I collagen. Nomenclature is based on their glenoid attachment from superior to inferior and anterior to posterior. They are normally lax in midrange rotation with a surface area two times that of the humeral head. They function as static checkreins limiting excessive translation and rotation through reciprocal tightening at the extremes of motion and relaxation during midrange arm rotation. Clinical and experimental studies have validated that the capsule is prone to stretching at repetitive low loads (e.g., swimming) and thus it is likely that all traumatic injuries cause some degree of capsular laxity, even in the presence of a Bankart lesion or labral detachment.

- a. Superior Glenohumeral Ligament (SGHL) and Coracohumeral Ligament (CHL).

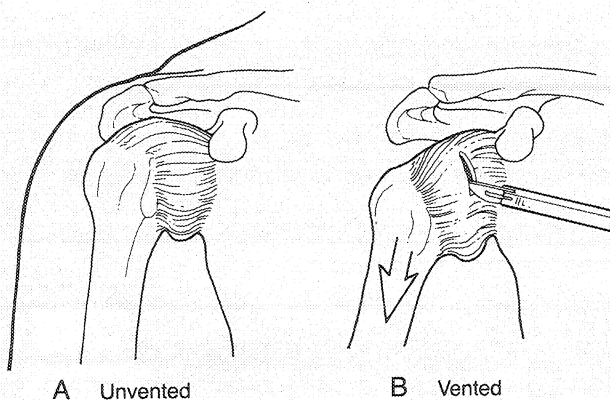


Figure 4-12. Demonstration of normal negative intra-articular pressure. A, Unvented capsule. B, Vented capsule. (Note the inferior subluxation of the humerus.)

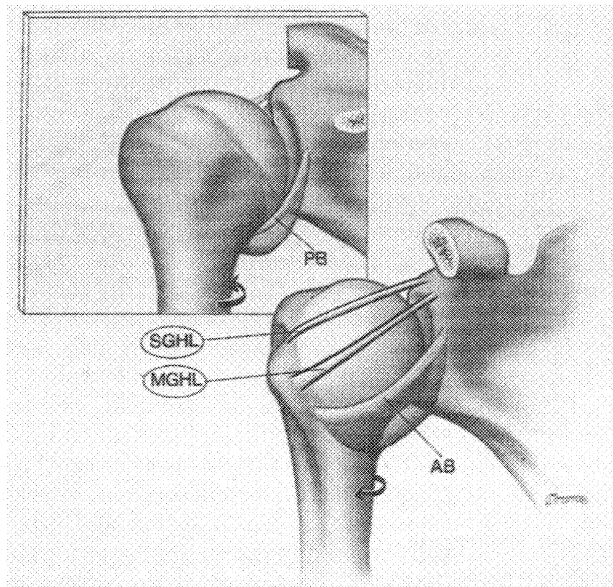


Figure 4-13. The superior and middle glenohumeral ligaments tighten with adduction and external rotation. SGHL, superior glenohumeral ligament; MGHL, middle glenohumeral ligament; AB, anterior band (of the inferior glenohumeral ligament complex); PB, posterior band (of the inferior glenohumeral ligament complex). (From Warner JJP, Deng X-H, Warren RF, Tozilli AP: Static capsuloligamentous restraints to superior-inferior translation of the glenohumeral joint. *Am J Sports Med* 20:675-685, 1992.)

Origin: supraglenoid tubercle and coracoid process, respectively. Insertion: LT. Present in >90% of individuals, they constitute the reinforcing structures of the rotator interval. Their parallel course provides similar static restraining effects.

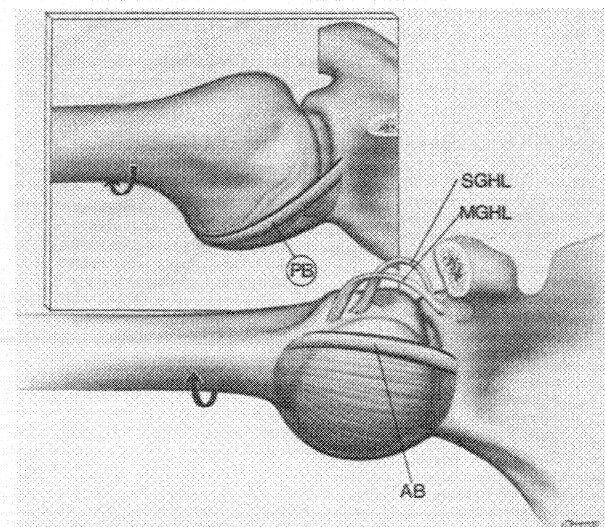


Figure 4-14. The inferior glenohumeral ligament complex tightens with abduction and external rotation. SGHL, superior glenohumeral ligament; MGHL, middle glenohumeral ligament; AB, anterior band (of the inferior glenohumeral ligament complex); PB, posterior band (of the inferior glenohumeral ligament complex). (From Warner JJP, Deng X-H, Warren RF, Tozilli AP: Static capsuloligamentous restraints to superior-inferior translation of the glenohumeral joint. *Am J Sports Med* 20:675-685, 1992.)

They limit inferior translation and external rotation when the arm is adducted and posterior translation when the arm is forward flexed, adducted, and internally rotated. Additionally, these structures are thought to prevent anterosuperior migration of the humeral head.

- b. Middle Glenohumeral Ligament (MGHL). Origin: glenoid tubercle or anterosuperior labrum. Insertion: LT, coursing oblique to the SGHL and CHL. Present in only 60% to 80% of individuals as either a discrete band or a thickening of the anterior capsule confluent with the inferior glenohumeral ligament complex (IGHLC). It statically limits external rotation of the adducted humerus, inferior translation of the adducted and externally rotated humerus, and anterior and posterior translation of the partly abducted (45°) and externally rotated arm.
 - c. IGHLC. Origin: the inferior half of the glenoid neck or the anterior inferior labrum. Insertion: inferior to the MGHL on LT. The IGHLC is a discrete anterior and posterior band with an interposed axillary pouch acting as a hammock-like structure that undergoes reciprocal tightening and loosening depending on arm position. In external rotation, the complex moves anteriorly. In internal rotation the complex moves posteriorly. The IGHLC functions as the primary restraint to anterior, posterior, and inferior GH translation between 45° and 90° of GH elevation.
6. Posterior Capsule. The capsule proximal to the posterior band of the IGHLC is the thinnest portion (<1 mm) of the shoulder capsule and is thus blamed for poor results following surgery for posterior instability. It may limit posterior translation in the forward flexed, adducted, and internally rotated arm.
 7. Rotator Interval (Figs. 4-15 and 4-16). This is an area of the shoulder capsule defined by the borders of the supraspinatus superiorly, the subscapularis inferiorly, the coracoid process medially, and the biceps and humerus laterally. It is variably reinforced by the SGHL, MGHL, and CHL. The rotator interval region may be completely devoid of tissue or composed of loosely arranged collagen representing a "rotator interval capsular defect," a normal variant in the stable shoulder. It may contribute to inferior instability of the adducted arm when associated with clinical GH instability. Alternatively, an excessively "tight" rotator interval may be associated with adhesive capsulitis or postoperative stiffness.
- C. Dynamic Restraints. Because the capsuloligamentous structures function principally at the extremes of rotation, dynamic restraints are required to help maintain GH stability during midrange arm rotation.
1. Joint Compression. Rotator cuff and biceps enhance the concavity-compression effect, centering the humeral head on the glenoid (steering effect) during arm rotation.
 2. Rotator Cuff. Through direct capsular attachments, rotator cuff contraction may create capsular tension, thereby stabilizing the joint. Alternatively, the musculotendinous units themselves may restrain GH translation by becoming rigid with contraction.
 3. Scapular Rotators. These comprise the trapezius, rhomboids, latissimus dorsi, serratus anterior, and levator scapulae. In co-

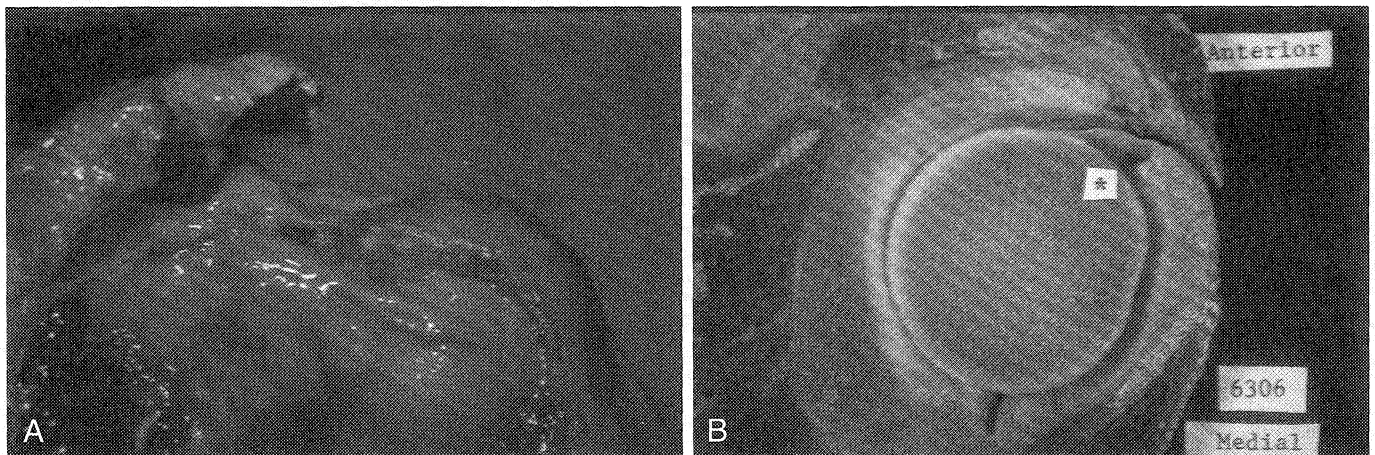


Figure 4-15. Photograph of an adult specimen showing the rotator interval capsular region. *A*, Gross specimen showing the rotator interval opening between the supraspinatus and subscapularis muscle tendons. *B*, Sagittally sectioned specimen showing the rotator interval capsule as an attenuated region of the capsule. *, rotator interval region.



Figure 4-16. Photomicrograph of an adult specimen (hematoxylin and eosin, $\times 200$) taken from within the rotator interval region. The lack of organization of the collagen bundles is shown.

ordination with the rotator cuff, they maintain a stable glenoid platform during arm rotation. Generally, in the absence of pathology, there is a 2:1 ratio of humeral-

to-scapular elevation. Abnormal ST rhythm during active forward elevation is associated with several underlying shoulder conditions, including shoulder instability.

4. Long Head of the Biceps. This dynamic structure enhances GH stability by increasing torsional rigidity of the joint when both the shoulder is rotating and the elbow is flexing. While possibly important for stability in the throwing shoulder, it may be less important in a shoulder with a rotator cuff tear.
5. Proprioception. This is a reflex mechanism whereby position sense receptors may sense capsular stretch and arm rotation, allowing for a coordinated muscle response that dynamically protects the joint from instability.

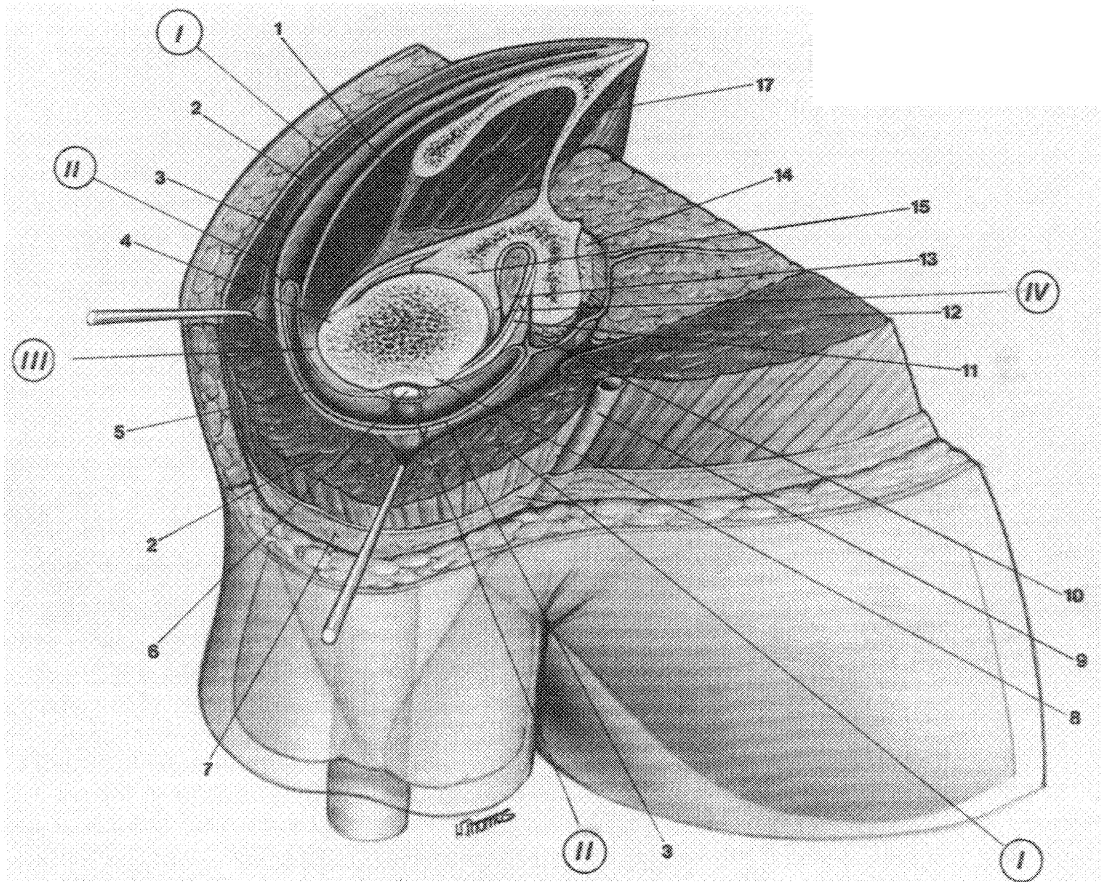


Figure 4-17. Cross-sectioned view of the right shoulder at the level of the lesser tuberosity. Note the four layers of the shoulder: **Layer Components:** (I) Deltoid (2), pectoralis major (12), fascia (7), cephalic vein (9); (II) Conjoined tendon (10), pectoralis minor (14); (III) Fascia (3), subdeltoid bursa (5), rotator cuff muscles (1, 17), suprascapular neurovascular bundle (not shown); (IV) Glenohumeral capsule (11), greater tuberosity (4), biceps long head (6), lesser tuberosity (8), synovium (13), glenoid (15). (From Cooper DE, O'Brien SJ, Warren RF: Supporting layers of the glenohumeral joint: An anatomic study. *Clin Orthop* 289:144-155, 1993.)