

## Autologous Osteochondral Transplantation: Background, Surgical Indications, and Results

R. Alexander Creighton • Brian J. Cole

The ability to treat symptomatic chondral lesions has improved over the past 10 years. These lesions are difficult because of the requirement of articular cartilage to withstand marked stress and its lack of intrinsic ability to heal. Patients who suffer from this entity are often physically demanding and wish to maintain their active lifestyle. Over 900,000 Americans are affected annually by chondral lesions of the knee and undergo more than 200,000 surgical procedures for high-grade lesions.<sup>1</sup> The treating physician and patient must have realistic goals and understand the complexity of the problem. There is an obvious difference between osteoarthritis and chondral lesions. The former, osteoarthritis, is a diffuse process displaying radiographic changes and disruption on opposing sides of the joint surface and currently represents a contraindication to treatment with many of the available nonarthroplasty solutions. The latter, chondral lesions that are focal with minimal radiographic changes, are often treatable with nonarthroplasty solutions. Even though the natural history of isolated chondral lesions remains unknown, some reports have shown that cartilage injuries have a greater than 50% chance of becoming symptomatic with demonstrable joint space narrowing.<sup>1</sup> The clinical course is multifactorial and related to the size, location, depth, chronicity, patient comorbidity (cruciate deficiency, meniscal damage, limb malalignment, and high body mass index), and previous operative interventions. If a symptomatic lesion does not respond to conservative treatment, surgical intervention is warranted. The treatment goal is to diminish pain and swelling, improve function, and prevent progression with minimal morbidity and at the lowest cost to the health care system. It is reasonable to recommend treatment sooner rather than later. How we deal with these injuries should be critically evaluated because what we do today may be considerably different from what we do in the future.

---

The outcome of a cartilage injury is dependent on the size, depth, extent, and location of the damage. Classification of these lesions as modified by the International Cartilage Repair Society (ICRS) is dependent on the extent and depth of the lesion (Table 24-1). The avascularity and high matrix-to-cell ratio of cartilage make healing

and repair limited at best. In a horse model, Convery and colleagues<sup>2</sup> assessed the effect of *defect* size. In the distal end of the femur of horses, they demonstrated that a larger 9-mm-diameter lesion did not heal but a smaller 3-mm lesion did repair in a 3-month period.

The total incidence of these lesions, whether symptomatic or asymptomatic, is unknown. If acute hemarthrosis develops after a sports- or work-related injury, it has been proposed that 5% to 10% of patients have a full-thickness chondral injury.<sup>22</sup> Curl and associates<sup>23</sup> retrospectively reviewed 31,516 knee arthroscopies. Chondral lesions were reported in 19,827 (63%), with over 60% of these lesions being grade III or grade IV chondral lesions. Of the patients with grade IV lesions, 5% were younger than 40 years. Smaller lesions may not be totally asymptomatic either. Levy and colleagues<sup>24</sup> reported on 23 isolated chondral defects in 15 high-caliber soccer players. Thirty-three percent of these lesions were less than 10 mm in diameter, but all players reported knee pain limiting their ability to play soccer.

The clinician must have a high index of suspicion when evaluating patients with focal chondral defects. They can occur in isolation or with other intra-articular pathology. A thorough history and physical examination are a must to decipher symptom-provoking activities, previous injuries, and associated pathology. Symptoms may be subtle but often include localized pain, swelling, catching, and giving way. The symptoms are due to abnormal stress on subchondral bone, debris, and exposed tissue.

Diagnostic imaging is required and helpful in the evaluation of these patients. Our standard protocol begins with standard weightbearing anteroposterior, Merchant, long-leg alignment, and non-weightbearing lateral views. Additionally, a 45-degree flexion weightbearing, posteroanterior radiograph can provide information on subtle joint space narrowing that traditional extension views may underestimate.<sup>25</sup> Magnetic resonance imaging (MRI) may provide extra information in difficult cases. Potter and associates<sup>24</sup> found MRI to be more sensitive than plain radiographs in detecting focal chondral defects, although there are still issues with sensitivity and specificity. MRI techniques, including two-dimensional fast spin-echo and three-dimensional fat suppression, provide the most detail in evaluating articular cartilage.

After diagnosing a focal chondral defect, the magnitude of the patient's symptoms and the extent of the lesion determine the treatment regimen. In highly symptomatic

patients, nonsurgical management is largely ineffective and should be reserved for very low-demand patients wishing to avoid or delay surgery. Nonsurgical management includes activity modification, nonsteroidal anti-inflammatory drugs, intermittent corticosteroid injections, braces, oral or injectable chondroprotective agents, and physical therapy.

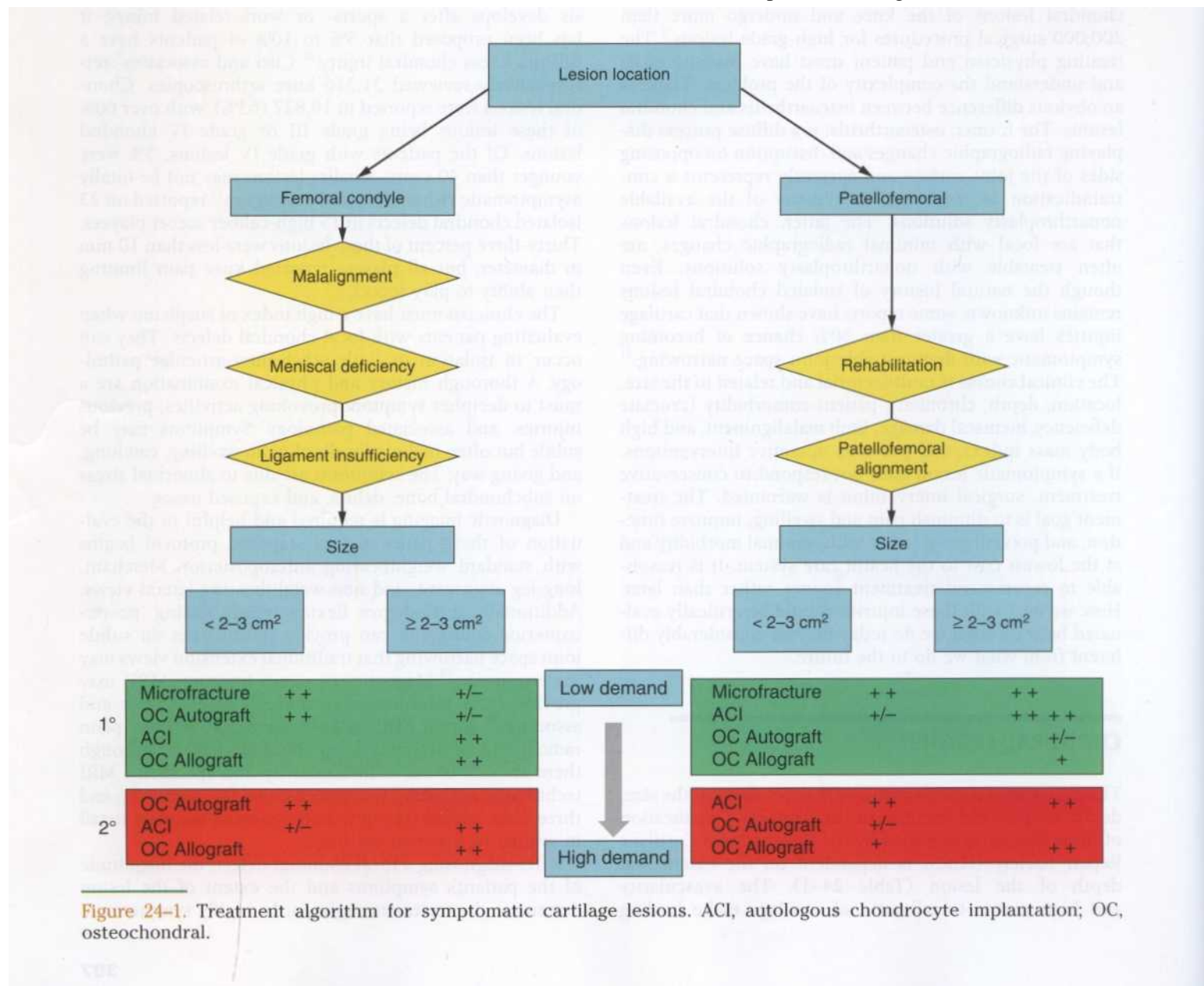
**Table 24-1.** Modified International Cartilage Repair Society Chondral Injury Classification System

GRADE OF INJURY	DESCRIPTION
Grade 0	Normal
Grade I	Superficial fissuring
Grade II	Less than half the cartilage depth
Grade III	Greater than the cartilage depth to the subchondral plate
Grade IV	Osteochondral lesion through the plate
Osteochondritis dissecans	Stability, continuity, depth

Once the decision to proceed with surgery has been made, the next decision is the type of surgery to perform. A number of surgical options are available for the treatment of chondral and osteochondral lesions. These interventions all have different success rates that depend on the patient's age, activity level, and the size, location, and depth of the lesion (Fig. 24-1). Options include lavage and debridement (palliative), marrow stimulation technique (reparative), and osteochondral grafting and autologous chondrocyte implantation (restorative). In this chapter we are focusing on the plug technique for autologous osteochondral transplantation.

**AUTOLOGOUS OSTEOCHONDRAL GRAFTING**

Because chondral lesions are often an expression of damage at the tidemark-subchondral bone interface, it makes intuitive sense to replace the entire cartilage-bone unit when possible. In a goat model, Jackson and



**Figure 24-1.** Treatment algorithm for symptomatic cartilage lesions. ACI, autologous chondrocyte implantation; OC, osteochondral.

associates" found that large, untreated lesions in the weightbearing surface of the medial femoral condyle led to progressive changes in both articular cartilage and bone over time, as well as the surrounding tissues. Osteochondral autograft transplantation is the only surgical technique that restores the height and shape of the articulating surface with composite autologous material. Use of this grafting technique reduces the area of fibrocartilage fill, which has been found to be inferior to true hyaline cartilage. The main disadvantage of the autologous technique is the availability of grafts and the technical demands of the procedure.

We believe that the ideal indication for this technique is a symptomatic patient with a full-thickness femoral chondral defect measuring 10 to 20 mm in diameter with stable surrounding cartilage. These lesions are frequently found in the central weightbearing area of the medial femoral condyle in an anterior cruciate ligament (ACL)-deficient knee, but they are often asymptomatic and observed by us until they become problematic. The upper age limit of the patient is around 50 years, and in general, deep large osteochondral defects are not suitable for an osteochondral autograft transplantation procedure.

#### TECHNIQUE

After appropriate anesthesia, patient positioning, and examination under anesthesia, diagnostic arthroscopy is performed to critically evaluate the joint for other associated pathology and the lesion itself. Documentation of the size of the lesion and depth, as well as the condition of the surrounding articular cartilage, is paramount to ensure that the lesion is suitable for osteochondral transplantation. The size of the lesion is appropriately measured with the use of color-coded sizers (Arthrex, Inc., Naples, FL) (Fig. 24-2).

Our preferred donor site is along the lateral edge of the lateral femoral condyle, proximal to the sulcus terminalis. This area has three main advantages. First, it is exposed to less contact pressure than other potential donor sites

are.<sup>11</sup> Second, it has a convex articular surface that mimics the weightbearing surface of the femoral condyles, where this technique is most often used.<sup>1</sup> Finally, this site is very easy to access with limited morbidity. We prefer to perform a limited arthrotomy to ensure a perpendicular harvest under direct visualization (Fig. 24-3). Alternatively, it may be accessed through a standard lateral portal with the knee in approximately 30 degrees of flexion. Other donor sites are along the superolateral margin of the intercondylar notch. One must thoroughly evaluate this area for fibrocartilage in an ACL-deficient knee, which is inappropriate for transfer. Limitations of this area include an inability to harvest plugs larger than 6 mm in diameter. The surgeon should have already determined whether to transfer a single or multiple osteochondral plugs from evaluation of the defect.

It is paramount that the harvester be perpendicular to ensure a circular graft. The depth markings on the barrel of the harvester should be visible at all times, either directly or arthroscopically. Using a mallet, the harvester is impacted to a depth of approximately 10 to 15 mm. The harvester is removed after the appropriate depth has been attained by abruptly rotating it clockwise 90 degrees and counterclockwise 90 degrees. Gentle rocking superiorly and inferiorly may be necessary to fracture the cancellous bone.

After appropriate sizing, the recipient site is prepared. It is cored to the appropriate depth to match the donor plug and cut at a perpendicular angle similar to the manner in which the donor graft was harvested (Fig. 24-4). The surgeon may need to hyperflex the knee to obtain the appropriate angle. Alternatively, an accessory portal or a limited arthrotomy may be necessary to access the defect. The socket is checked by visualization and the calibrated alignment stick to ensure the correct depth and angle before placing the donor plug (Fig. 24-5).

The donor harvester is placed inside the recipient site, and the donor graft is gently extruded. The collar pin of the harvester is advanced until the pin is flush with the pin calibrator. The pin is designed to advance the graft so that 1 mm of the graft is exposed. A sizer 1 mm larger than



Figure 24-2. OATS set with color-coded sizers by Arthrex, Inc. (Naples, FL).

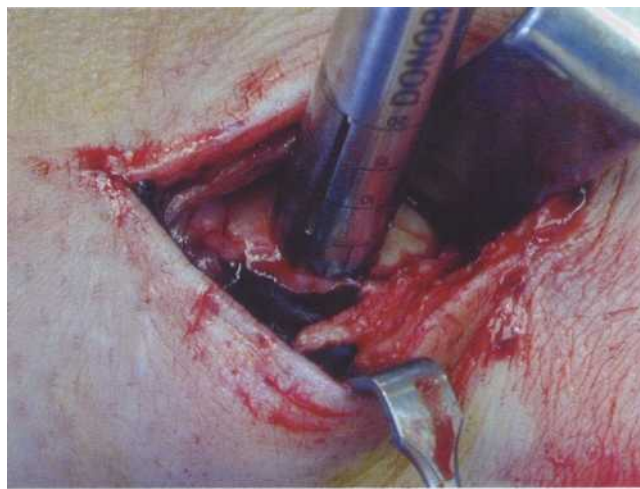

Figure 24-3. Limited arthrotomy for an osteochondral donor plug.

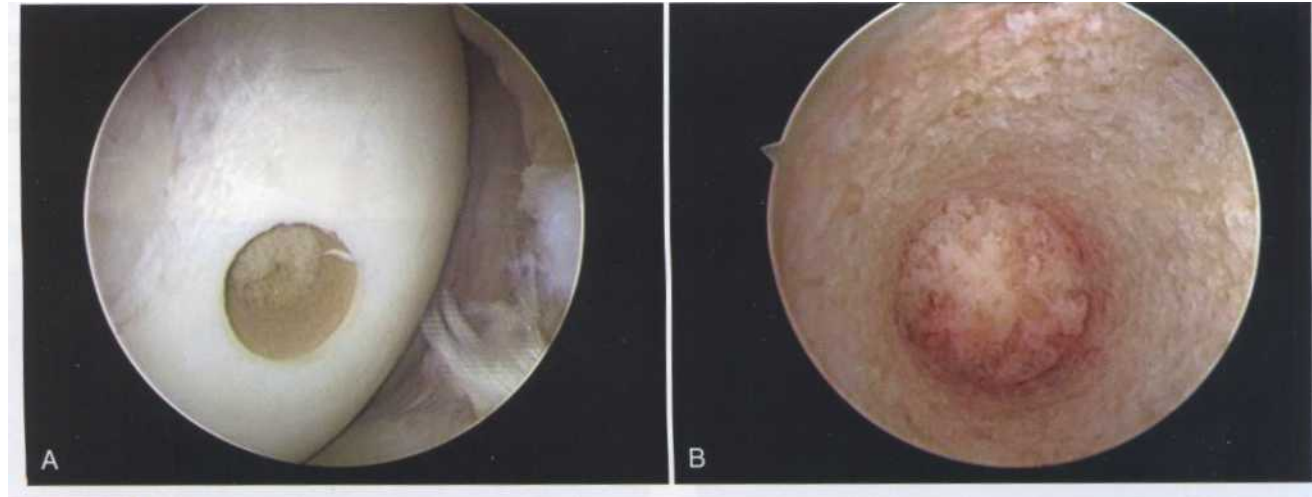
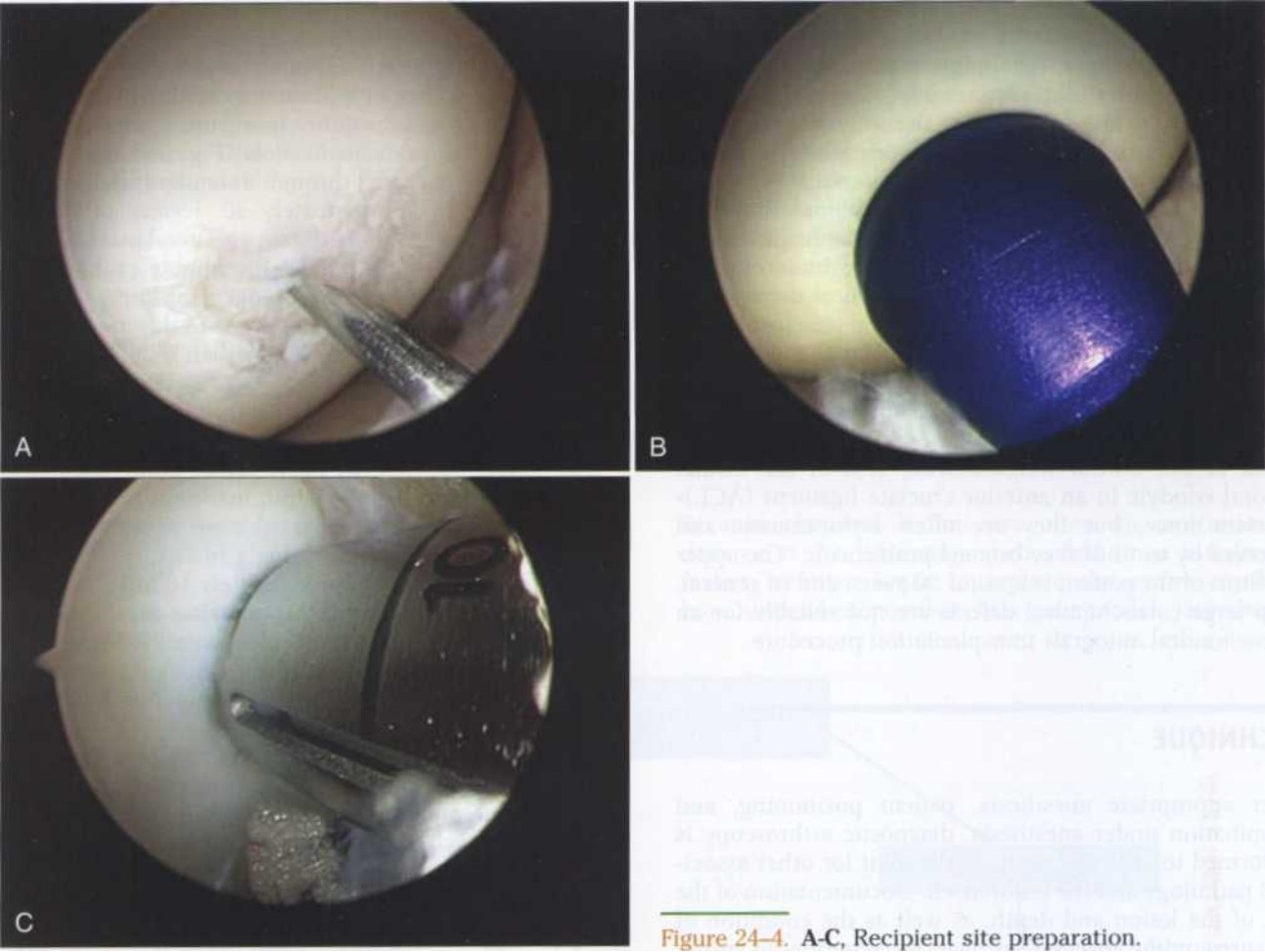


Figure 24-5. A and B, The recipient site is double-checked.

the graft is used, and gentle tapping fully seats the plug; progress is checked periodically (Fig. 24-6).

If the procedure calls for multiple cores, each transfer should be completed before subsequent creation of the recipient sockets. This technique ensures that the donor sockets are placed appropriately and usually prevents socket wall blowout. It is necessary to fill the defect as completely as possible, usually at least 60% to 80% (Fig. 24-7).

The donor plug holes are usually left unfilled. They fill with a combination of cancellous bone and fibrocartilage at the 12-week mark. It may take up to 1 year for these holes to fill to the level of surrounding articular cartilage. Ongoing research is evaluating different composite materials to fill these defects in an effort to decrease postoperative hematoma formation and to stimulate earlier filling (Fig. 24-8).<sup>10</sup>

Postoperatively, if the procedure is performed appropriately with a well-contained defect, early weightbearing and motion are encouraged. After a multiple-plug technique, full range of motion and protected weightbearing are advised for the first 4 weeks. At 4 weeks, full weightbearing is allowed. Sporting activities are not recommended until 4 to 6 months postoperatively.

The most frequent complication after osteochondral transfer surgery is hemarthrosis. Other complications include pain, donor site morbidity, graft fracture, condylar fracture, and loose bodies. Mosaicplasty has similar complications, but there is higher potential for donor site morbidity and the possibility of avascular necrosis if too many donor grafts are chosen from the same area. In several instances, plug failure has been observed by the senior author when multiple small plugs have been implanted (Fig. 24-9).

---

## RESULTS

The first type of cartilage transfer was performed in 1908 by Judet.<sup>11</sup> He transplanted post-traumatic fragments into their defects and obtained pain relief. A study by Papadopoulos<sup>12</sup> found that lesions smaller than 5 mm survived longer than 2 years. Daniel and associates<sup>13</sup> in 1963 showed the importance of bone for survival of the cartilage. Campbell and colleagues also came to this conclusion in a dog model, in which 1- by 2-cm plug survival was related to at least a 5-mm bone plug. The first case report of the

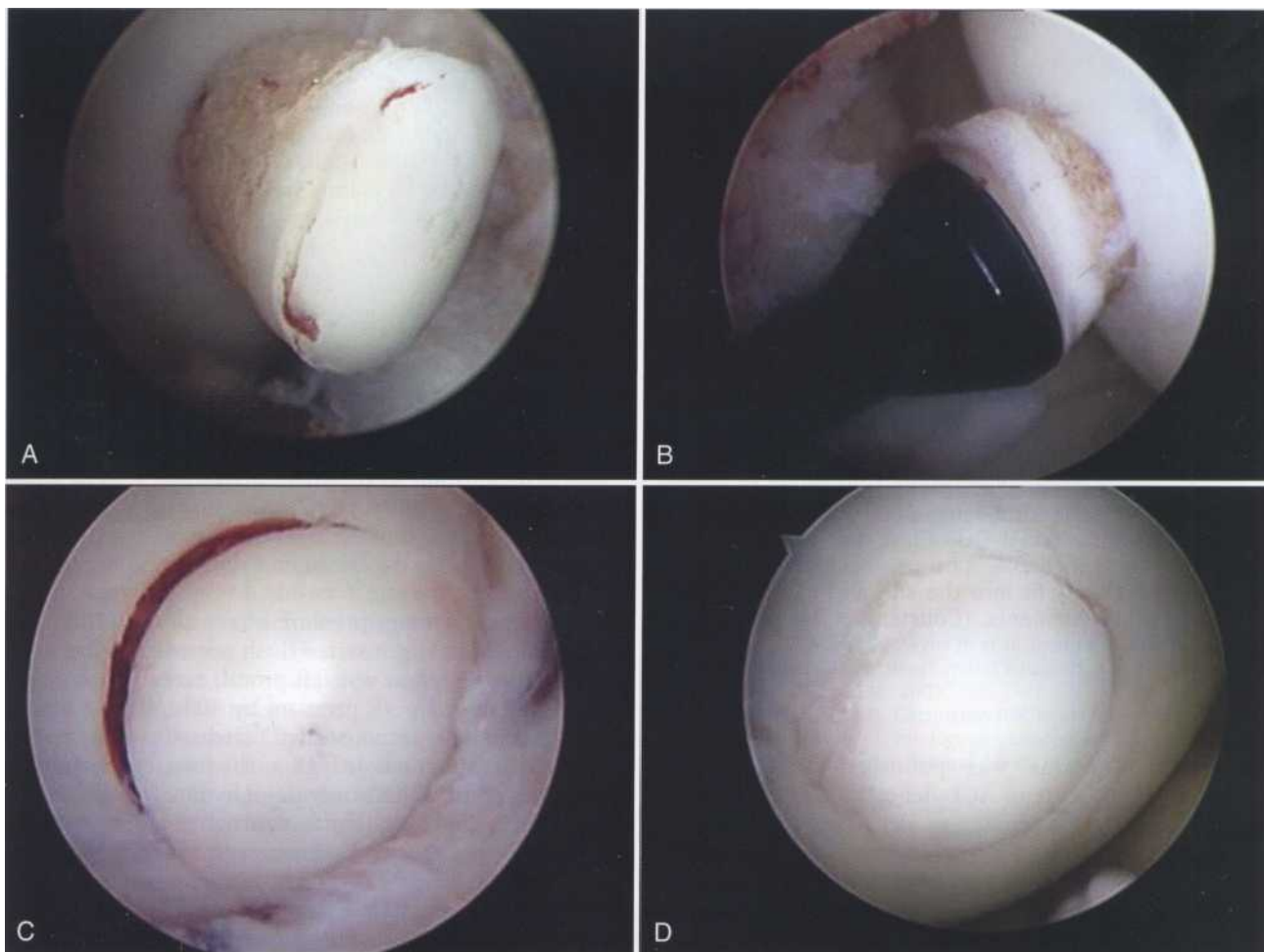


Figure 24-8: A-D. The donor graft is placed inside the recipient site.

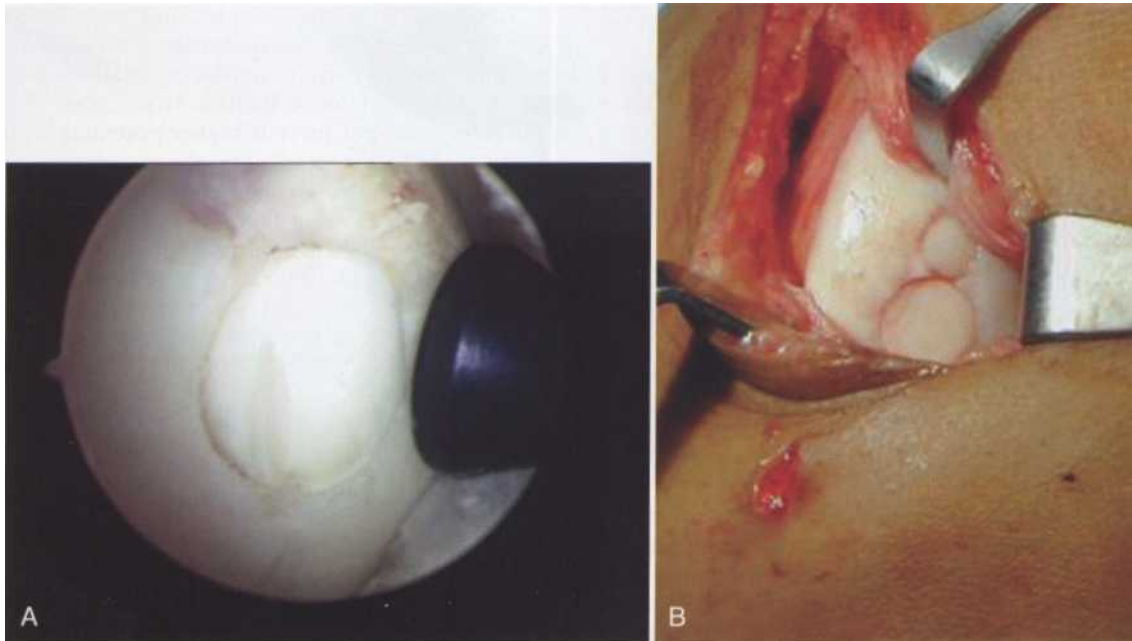


Figure 21. A and B, Multiple plugs.

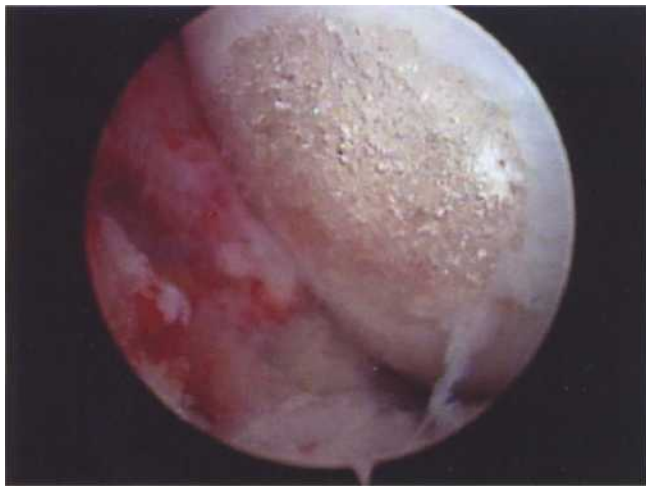

Figure 24-H. Osteochondral defect filled with a 9-mm-diameter OsteoBiologics TruFit BGS Plug. At the time of implantation, the resorbable, porous, backfill scaffold is contoured and tightly fit into the site and has filled with blood and cellular elements. (Courtesy of Wayne Gersoff, M.D., Denver.)

arthroscopic technique was published in 1993 and involved a patient with an ACL-deficient knee." Duchow and associates" used a porcine model to evaluate the stability of press-fit-implanted osteochondral grafts. They found that failure loads were significantly lower for 10- than for 15-mm-long grafts, as well as for 8- versus 11-mm-diameter grafts. In addition, repeated implantation and levering the graft at harvest reduce primary stability. Koh and colleagues" assessed the effect of graft height

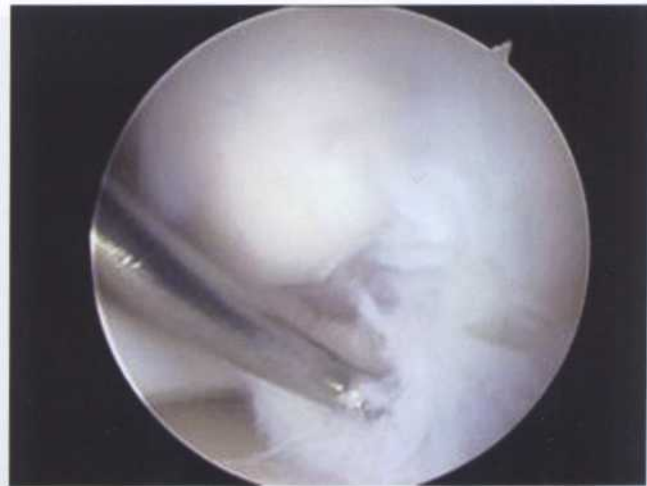

Figure 24-9. Failure of the multiple-plug technique.

mismatch on contact pressure after osteochondral grafting. A plug that was inserted flush normalized the contact pressure. A plug that was left proud, even 0.5 mm, significantly increased peak pressure by 40%. A plug that was countersunk also demonstrated increased contact pressure by about 10%, but not as high as the contact pressure with an empty defect. This study demonstrates the importance of the graft matching the host's articular geometry.

Bobic<sup>3</sup> reported on the treatment of 12 patients with chronic ACL deficiency and full-thickness femoral condyle lesions greater than 10 mm in diameter. He treated the ACL deficiency with a patellar tendon graft and the osteochondral lesion by osteochondral autograft transplantation with modified tubular instruments. The

multiple osteochondral cylinders were obtained from the notch area. During second-look arthroscopy at 2 years, 10 of 12 grafts were satisfactory in terms of visual and probed inspection.

Hangody and associates<sup>13</sup> used various techniques to treat 227 patients who had chondral lesions ranging from 1 to 9 cm<sup>2</sup>. Superior results were achieved in patients treated with mosaicplasty versus abrasion arthroplasty, microfracture, or Pridie drilling. Treatment of these chondral lesions by penetration of the subchondral bone appeared to deteriorate over time, with improvement ranging from 0% to 34% at 5 years. Mosaicplasty maintained its results at 5 years with an 87% success rate.

Jakob and colleagues<sup>16</sup> treated chondral lesions of the knee in 52 consecutive patients by mosaicplasty with an average follow-up of 37 months. Twenty-three patients were classified as ICRS grade III and 29 as grade IV. Knee function was improved in 92% of patients. Four patients did require surgery for graft failure. They found that patients who required 8 to 12 plugs, 6 to 7 mm in diameter, had more of a problem with donor site morbidity. The authors concluded that autologous osteochondral transplantation is an appropriate option for the treatment of full-thickness osteochondral defects. However, this treatment is limited by the size of the lesion and the number of plugs that can be harvested.

Hangody and Fules<sup>12</sup> reported on their 10-year experience of autologous osteochondral transplantation. Eight hundred thirty-one patients were evaluated over this period. The investigators reported good to excellent results in 92% of femoral condylar implants, 87% of those treated by tibial resurfacing, 79% of patellar or trochlear mosaicplasties, and 94% of talar lesions. Donor site morbidity was assessed by the Bandi score. Long-term morbidity was found in 3% of patients. Other complications included 4 deep infections and 36 painful postoperative hemarthroses. Eighty-three patients were evaluated by second-look arthroscopy. Sixty-nine showed congruent articular gliding surfaces, histological evidence of hyaline cartilage, and fibrocartilage filling of the donor sites.

Andres and associates<sup>1</sup> looked at the effectiveness of osteochondral autograft transplantation in the treatment of osteoarthritic cartilage lesions. Twenty-two transplantations were performed for isolated or multiple degenerative cartilage lesions. At a minimum follow-up of 24 months, the isolated cartilage lesions had significantly better pain relief and functional scores based on the Western Ontario and McMaster Universities Osteoarthritis Index. The authors concluded that osteochondral autograft transplantation is effective in treating isolated arthritic lesions but that it appears to be contraindicated in patients with multiple lesions.

Horas and coworkers<sup>14</sup> performed a prospective, randomized study comparing 40 patients treated by autologous chondrocyte implantation (ACI) with 40 treated by osteochondral cylinder transplantation (OCT) in the knee joint with a 2-year follow-up. Both groups improved their Meyers score and Tegner activity score, but the Lysholm score of the ACI group lagged behind that of the OCT group at 6, 12, and 24 months. Histomorphologic biopsy in a small number of patients demonstrated that the OCT group retained their hyaline cartilage character, whereas

the ACI group consisted mainly of fibrocartilage. The authors concluded that both treatments decreased patients' symptoms but that the ACI group lagged behind the OCT group.

Bentley and associates also performed a prospective, randomized comparison of ACI versus mosaicplasty for osteochondral defects of the knee. Fifty-eight patients were treated with ACI and 42 with mosaicplasty, the mean size of the defect was 4.66 cm<sup>2</sup>, and the mean follow-up was 19 months (12 to 26). Using the Cincinnati and Stanmore scores with objective clinical assessment, 88% of the ACI group had excellent or good results, whereas 69% of the mosaicplasty group had excellent or good results. Arthroscopy at 1 year revealed ICRS grades of I or II in 82% of the ACI group but only 34% of the mosaicplasty group. It should be noted that all five of the mosaicplasties performed on the patella failed. The authors concluded that ACI is superior to mosaicplasty in repair of articular defects in the knee.

---

## CONCLUSION

Treatment of symptomatic chondral lesions continues to evolve. Autologous osteochondral transplantation is the only surgical technique that restores the height and shape of the articulating surface with composite autologous material. It has a steep learning curve and is technically dependent. We prefer to perform a limited lateral arthrotomy to ensure a perpendicular donor harvest. In addition, proper preparation of the recipient site is important to ensure flush seating of the plug and limit the possibility of damage to the hyaline cartilage of the plug. We believe that the ideal indication for this technique is a symptomatic patient with a full-thickness femoral chondral defect 10 to 20 mm in diameter and stable surrounding cartilage. The upper age limit of patients is around 50 years, and deep, large osteochondral defects are not suitable for osteochondral autograft transplantation in our opinion. It is always important to individualize any treatment technique toward a particular patient and lesion and to correct any associated ligament laxity, limb malalignment, or significant meniscal deficiency.

## References

1. Andres BM, Mears SC, Wenz JF, et al: Treatment of osteoarthritic cartilage lesions with osteochondral autograft transplantation. *Orthopedics* 26:1121-1126, 2003.
2. Bentley G, Biant LC, Carrington RW, et al: A prospective, randomized comparison of autologous chondrocyte implantation versus mosaicplasty for osteochondral defects in the knee. *J Bone Joint Surg Br* 85:223-230, 2003.
3. Bobic V: Arthroscopic osteochondral autograft transplantation in anterior cruciate ligament reconstruction: A preliminary clinical study. *Knee Surg Sports Traumatol Arthrosc* 3:262-264, 1996.
4. Campbell CJ, Ishida H, Takahashi H, Kelly F: The transplantation of articular cartilage. An experimental study in dogs. *J Bone Joint Surg Am* 45:1579-1592, 1963.
5. Cole B, Frederick R, Levy A, Zaslav K: Management of a 37-year old man with recurrent knee pain. *J Clin Outcomes Management* 6:46-57, 1999.

6. Convery FR, Akeson WH, Keown GH: The repair of large osteochondral defects: An experimental study in horses. *Clin Orthop* 82:253-262, 1972.
7. Curl WW, Krome J, Gordon ES, et al: Cartilage injuries: A review of 31,516 knee arthroscopies. *Arthroscopy* 13:456-460, 1997.
8. Daniel GA, Kahn DS, Entin MA: Experimental autogenous transplantation of hemi-joints in dogs. *Surg Forum* 14:460-461, 1963.
9. Duchow J, Hess T, Kohn D: Primary stability of press-fit- implanted osteochondral grafts. *Am J Sports Med* 28:24-27, 2000.
10. Feczko P, Hangody L, Varga J, et al: Experimental results of donor site filling for autologous osteochondral mosaicplasty. *Arthroscopy* 19:755-761, 2003.
11. Garretson RB III, Katolik LI, Cole BJ, et al: Contact pressure at osteochondral donor sites in the patellofemoral joint. *Am J Sports Med* 32:967-974, 2004.
12. Hangody L, Fules P: Autologous osteochondral mosaicplasty for the treatment of 4dl-2riii KUess Ltrirrs i -weighty itwenig 'rinte. ; r ne Joint Surg Am 85:27-32, 2003.
13. Hangody L, Kish G, Karpati Z, et al: Mosaicplasty for the treatment of articular cartilage defects: Application in clinical practice. *Orthopedics* 21:751-756, 1998.
14. Horas U, Pelinkovic D, Herr G, et al: Autologous chondrocyte implantation and osteochondral cylinder transplantation in cartilage repair of the knee joint. *J Bone Joint Surg Am* 85:185-192, 2003.
15. Jackson DW, Lalor PA, Aberman HM, Simon TM: Spontaneous repair of full-thickness defects of articular cartilage in a goat model: A preliminary report. *J Bone Joint Surg Am* 83:53-64, 2001.
16. Jakob RP, Franz T, Gautier E, et al: Autologous osteochondral grafting in the knee: Indications, results, and reflections. *Clin Orthop* 401:170-184, 2002.
17. Judet H: Essai sur les greffes des tissus [articulaires](#). *CR Acad Sci* 146:193, 1908.
18. Koh JL, Wirsing K, Lautenschlager E, Zhang LO: The effect of graft height mismatch on contact pressure following osteochondral grafting. *Am J Sports Med* 32:317-320, 2004.
19. Levy AS, Lohnes J, Sculley S, et al: Chondral delamination of the knee in soccer players. *Am J Sports Med* 24:634-639, 1996.
20. Matsusue Y, Yamamuro T, Hama H: Arthroscopic multiple osteochondral transplantation to the chondral defect in the knee associated with anterior cruciate ligament disruption. *Arthroscopy* 9:318-321, 1993.
21. Messner K, Maletius W: The long-term prognosis for severe damage to weight-bearing cartilage in the knee: A 14-year clinical and radiographic follow-up in 28 young athletes. *Acta Orthop Scand* 67:165-168, 1996.
22. Noyes FR, Bassett RW, Grood ES, Butler DL: Arthroscopy in acute traumatic hemarthrosis of the knee: Incidence of anterior cruciate tears and other injuries. *J Bone Joint Surg Am* 62:687-695, 1980.
23. Pan. li: Reduction and percutaneous fixation of mobile fractures. *Acta Med Acad Sci Hung* 2:581-618, 1951.
24. Potter H, Linklater L, Allen A, et al: Magnetic resonance imaging of articular cartilage of the knee: An evaluation with use of fast-spin-echo imaging. *J Bone Joint Surg Am* 80:1276-1284, 1998.
25. Rosenberg T, Paulos L, Darker R, et al: The 45-degree PA flexion weight-bearing radiograph of the knee. *J Bone Joint Surg Am* 70:1479-1483, 1988.
26. Simonian PT, Sussmann PS, Wickiewicz TL, et al: Contact pressures at osteochondral donor sites in the knee. *Am J Sports Med* 26:491-494, 1998.
27. Terukina M, Fujioka H, Yoshiya S, et al: Analysis of the thickness and curvature of articular cartilage of the femoral condyle. *Arthroscopy* 19:969-973, 2003.