

Shoulder: Diagnostic Arthroscopy

AUGUSTUS D. MAZZOCCA, FRANK G. ALBERTA,
BRIAN J. COLE, AND ANTHONY A. ROMEO

The diagnostic examination is a key component of all shoulder arthroscopy. The arthroscope gives the surgeon the ability to visually inspect and palpate the intra-articular and subacromial anatomy. The arthroscopic shoulder examination should proceed in a stepwise fashion, and it is important that all structures be evaluated consistently. To ensure that this is done in a reproducible manner, the glenohumeral joint can be divided into sectors.

The *anterosuperior sector* includes the rotator interval, consisting of the coracohumeral ligament (CHL), superior glenohumeral ligament (SGHL), and biceps tendon; the *superior sector* includes the superior labrum and superior glenoid articular surface; the *posterior sector* includes the posterior labrum, posterior band of the inferior glenohumeral ligament (IGHL), and posterior glenoid articular surface; the *inferior sector* includes the axillary pouch; the *anterior sector* includes the subscapularis tendon and its insertion on the humerus, middle glenohumeral ligament (MGHL), anterior labrum, anterior glenoid articular surface, and anterior band of the IGHL; and the *humerus* includes the rotator cuff insertion, bare area, and entire humeral articular surface.

Surgical Technique

Diagnostic arthroscopy of the shoulder starts with insertion of the arthroscope into the glenohumeral joint through the posterior portal. The arthroscope passes through the skin, the posterior deltoid, and the infraspinatus–teres minor interval. The position of the posterior portal is variable but is generally established 2 cm inferior and 1 cm medial to the posterolateral edge of the acromion, avoiding the neurovascular structures located in the quadrangular space, triangular space, and

triangular interval (Fig. 9–1). These spaces are located 7 to 8 cm inferior to the posterolateral corner of the acromion. The quadrangular space is formed by the teres minor superiorly, the teres major inferiorly, the long head of the triceps medially, and the humeral shaft laterally. The posterior humeral circumflex vessels and the axillary nerve pass through the quadrangular space. The triangular space contains the circumflex scapular vessels, and the triangular interval contains the radial nerve and the deep brachial artery. The triangular space is bounded by the long head of the triceps laterally and the two teres muscles medially.

The anterior portal is created through the rotator interval, and a cannula is inserted to be used for outflow (Fig. 9–2). This portal is generally in line with the acromioclavicular joint, approximately 2 or 3 cm inferior to the anterolateral edge of the acromion. The musculocutaneous nerve can generally be found 3 to 5 cm distal and just medial to the coracoid process.

Superior Sector

Upon entering the joint, the surgeon should see the triangle formed by the biceps tendon superiorly, the humeral head laterally, and the subscapularis inferiorly. The biceps tendon and the glenoid labrum surrounding the entire glenoid have the appearance of an inverted comma or Q.⁵ The biceps tendon attaches to the supraglenoid tubercle at the posterosuperior aspect of the glenoid rim. The biceps origin either is attached to the superior labrum or sends fibers to the anterosuperior and posterosuperior labrum (Fig. 9–3). The first portion of this examination can be done before distention of the capsule with fluid. This allows visualization and quantification of the amount of erythema on the biceps tendon. Once the fluid has been introduced, the pressure

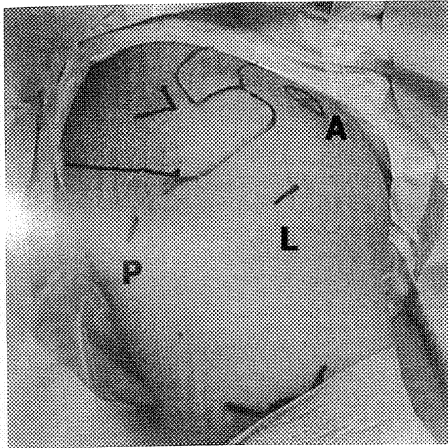


Figure 9-1 Intraoperative photograph of standard shoulder portals drawn before the incision. A, anterior portal; L, lateral solid working portal; P, posterior portal.

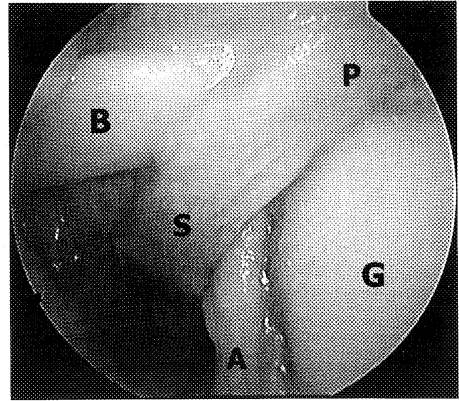


Figure 9-3 Arthroscopic image from a posterior viewing portal. The biceps tendon (B), superior glenohumeral ligament (S), and the labrum, both anterior and posterior, are intimately related. A, anterior labrum; G, glenoid surface; P, posterior labrum.

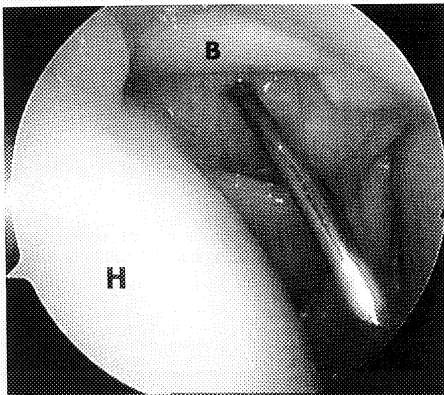


Figure 9-2 Arthroscopic image from a posterior viewing portal. The spinal needle marks the position of the anterior rotator interval portal. B, biceps tendon; H, humeral head.

tamponades the microinflammation and “washes” it out. This can be a helpful adjunct to the diagnosis of biceps tendinosis.¹⁵

The superior labrum should be evaluated for tears, detachment, or other abnormalities that could represent the clinical entity known as the superior labral anterior to posterior (SLAP) lesion.¹⁵ A probe can be used from the anterior portal to look under the labrum to evaluate whether it is denuded. Burkhart and Morgan⁵ described the peel-back phenomenon in evaluating overhead athletes. When the arm is abducted and externally rotated, the superior labrum may rotate off the superior glenoid posteriorly and superiorly (Fig. 9-4).

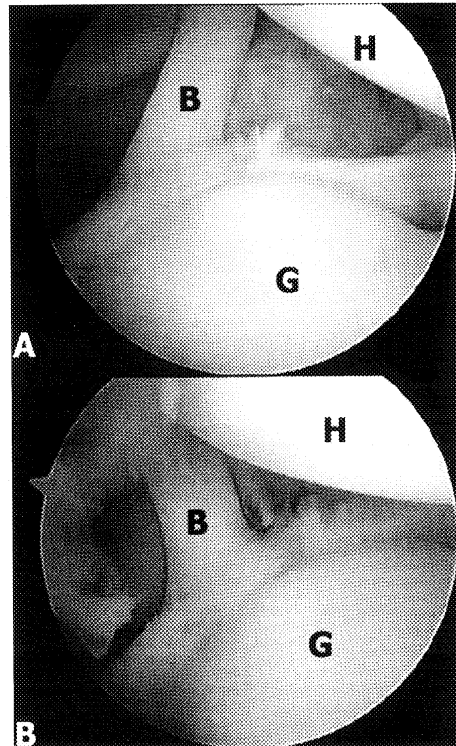


Figure 9-4 In abduction and external rotation, the superior labrum can rotate posterior and medially from the superior glenoid (peel-back phenomenon). A, Superior labrum with the arm in neutral position. B, Superior labrum with the arm in abduction and external rotation, demonstrating peel back. Note the change in the orientation of the biceps tendon (B). G, glenoid; H, humeral head.

Anterosuperior Sector

The CHL should be evaluated as it encircles the biceps tendon. This ligament originates at the base of the coracoid and then spans out, sending fibers that circle the biceps tendon, intertwine with the supraspinatus tendon, and insert in front of the subscapularis tendon insertion. The SGHL also attaches to the superior portion of the glenoid but is in a different plane from the CHL. The SGHL runs from the anterosuperior aspect of the glenoid to the upper part of the lesser tuberosity and is considered by some to be the floor of the bicipital groove (Fig. 9-5). The SGHL works with the CHL in preventing anterior translation of the humeral head with the arm adducted and externally rotated. The SGHL also prevents inferior subluxation of the humeral head (sulcus sign) with the arm at the side. The biceps can be followed distally into the bicipital groove. Forward elevation with the elbow flexed, combined with internal rotation of the

arm, may assist in viewing the biceps as it passes underneath the transverse humeral ligament. To visualize the biceps tendon, which is located in the intertubercular groove, the probe can be placed superior to the tendon and used to "pull" the tendon down into the joint (Fig. 9-6).

The bicipital groove is further bordered by the subscapularis tendon medially and the supraspinatus tendon laterally (Fig. 9-7). The supraspinatus tendon can be seen adjacent to the biceps with abduction and external rotation (Fig. 9-8). The SGHL and CHL form the medial

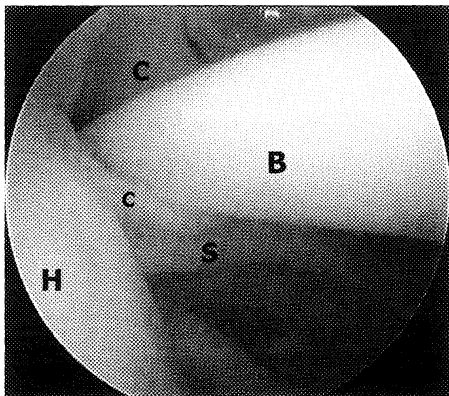


Figure 9-5 Arthroscopic image from a posterior viewing portal demonstrating the biceps tendon sling. B, biceps tendon; C, coracohumeral ligament; H, humeral head; S, superior glenohumeral ligament.

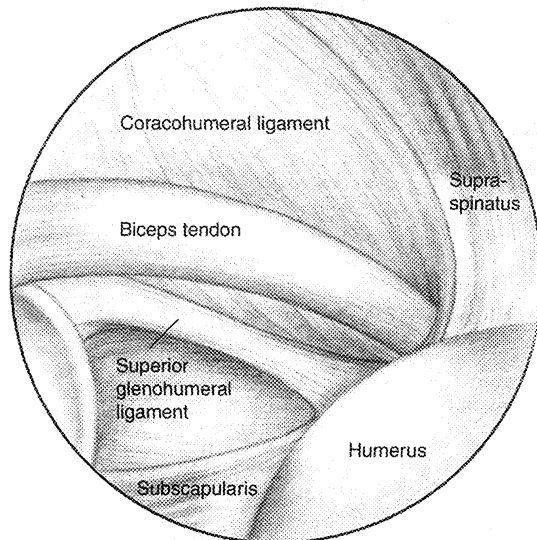


Figure 9-7 Relationship of anterosuperior structures to the biceps tendon and its groove. The subscapularis (medially) and the supraspinatus (laterally) tendons border the bicipital groove.

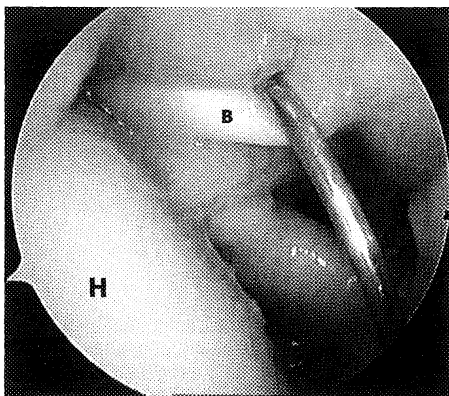


Figure 9-6 The biceps tendon (B) can be examined by pulling it into the joint with a hook probe. This allows full evaluation of the tendon distal to its intra-articular portion. H, humeral head.

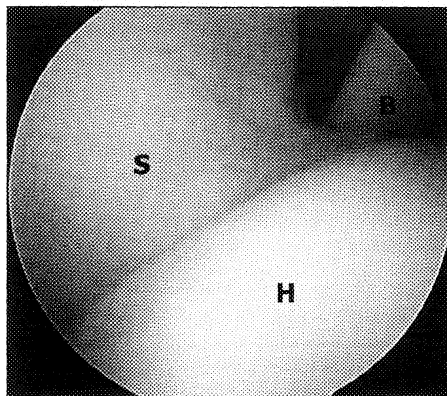


Figure 9-8 The supraspinatus tendon contributes to the stability of the biceps tendon (B) in its groove, a relationship that is especially appreciated in abduction and external rotation. H, humeral head; S, superior glenohumeral ligament.

sling of the biceps. Damage to these structures can result in biceps instability or pain.

Finally, the anterosuperior labrum can be evaluated. The labrum has been described as being triangular in cross section, with its free edge directed at the glenoid center. It is made up of dense, fibrous connective tissue and anchored to the osseous rim of the glenoid. The hyaline cartilage of the glenoid articular surface frequently extends under and beyond this free edge. Significant normal variability exists in the appearance of the anterosuperior labrum; this can include physiologic detachment and confluence with the MGHL (Buford complex), simple detachment (sublabral hole), or complete absence. A probe can be inserted through the anterior portal as previously described and used to examine all labral and ligamentous structures. Notation of labral atrophy, fraying, and amount of movement should always be made, as this information may aid in diagnosis.

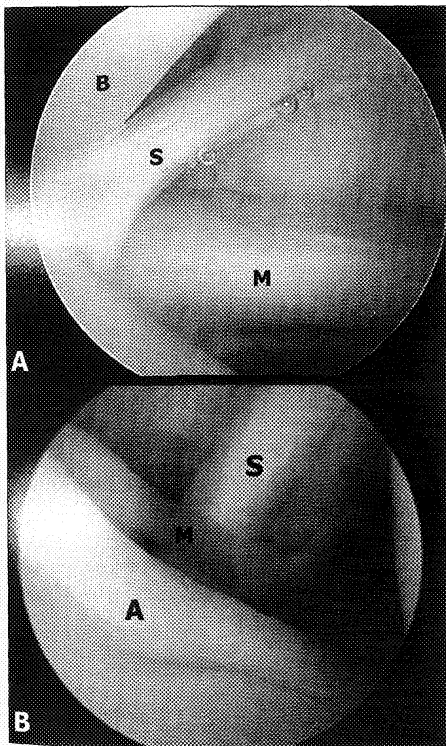


Figure 9-9 The middle glenohumeral ligament (MGHL) is variable in its appearance and consistency. It crosses the superior rolled edge of the subscapularis tendon at a 60-degree angle. **A**, Cordlike MGHL with a high origin from the superior glenoid. **B**, Thin MGHL with its typical relationship to the subscapularis tendon. **A**, anterior labrum; **B**, biceps; **M**, middle glenohumeral ligament; **S**, superior glenohumeral ligament.

Anterior Sector

With the arthroscope in the posterior portal and the 30-degree objective facing laterally, the rolled upper edge of the subscapularis is examined. The MGHL is variable in thickness and intersects the subscapularis at a 60-degree angle (Fig. 9-9).⁶ It can be a veil of tissue or a cordlike structure, as in the Buford complex. This normal anatomic variant consists of a cordlike MGHL with a high origin off the glenoid at the base of the biceps tendon. Frequently, the anterosuperior labrum is absent in these cases.¹⁴ The MGHL arises from the anterior humeral neck just medial to the lesser tuberosity and inserts on the medial and superior glenoid rim and scapular neck. Its function is to resist anterior translation of the humeral head at 45 degrees of abduction.⁸ In diagnostic glenohumeral arthroscopy, it is also important to examine the subscapularis recess. Loose bodies can be lodged here and will not be discovered unless this area is actually visualized. Inferiorly, the anterior and anteroinferior labrum can be inspected. Sublabral defects of the anterosuperior labrum can be seen in 60% of patients. In 10%, the defect is a complete hole and communicates with the subscapularis recess. These are normal variants and should not be mistaken for labral pathology. Any detachment of the labrum below the glenoid equator (at the level of the rolled edge insertion of the subscapularis), however, is generally considered pathologic.

The articular surface of the glenoid and humerus must be examined in detail. The articular cartilage of the glenoid thins at the center. The surrounding cartilage should be examined for full-thickness lesions, fibrillation, and softening. The treatment of such lesions is still controversial, but they must be noted. Large articular lesions can manifest as a feeling of instability as the humeral head articulates with the lesion and the sensation of "chunks" in various positions of rotation and abduction (Fig. 9-10).

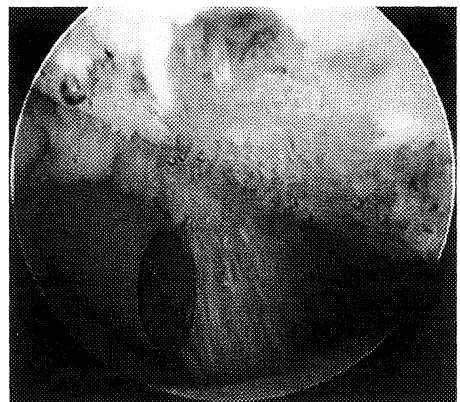


Figure 9-10 Large humeral head articular cartilage defect that can cause mechanical symptoms.

Inferior Sector

The inferior sector is examined for evidence of synovitis and the presence of loose bodies. As the assistant holds traction in 20 to 30 degrees of abduction with the arm in a beach chair position, the anterior band of the IGHL can be inspected. The IGHL runs from the glenoid to the anatomic neck of the humerus (Fig. 9-11). The anterior band of the IGHL prevents anterior translation of the humeral head when the arm is abducted 90 degrees and externally rotated. It also restricts inferior translation when the arm is abducted and internally rotated. The humeral attachment of the anterior band is best visualized from the anterior portal. It is from this view that a humeral avulsion of the glenohumeral ligament (HAGL) can be seen (Fig. 9-12). The axillary pouch is then inspected. The capsule of the axillary pouch is thin, and beneath it lies the axillary nerve. This relationship should always be considered when performing suture capsular plication or thermal capsulorrhaphy (Fig. 9-13).

Posterior Sector

The posteroinferior labrum and the posterior band of the IGHL can be inspected sequentially. The posterior band of the IGHL prevents inferior translation of the

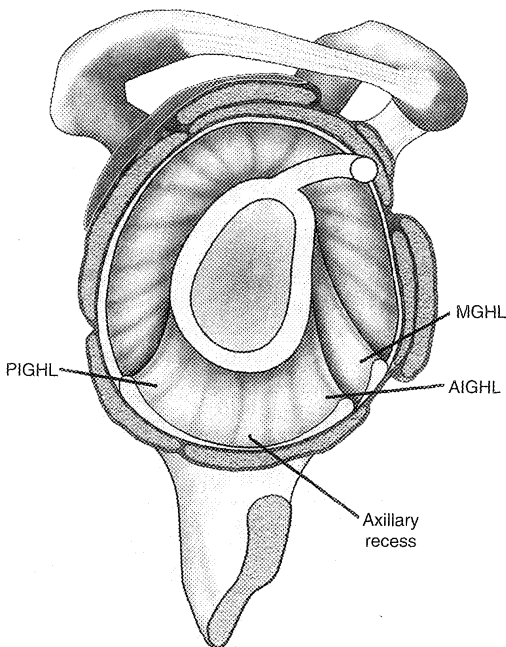


Figure 9-11 The inferior glenohumeral ligament (IGHL) forms a sling that cradles the inferior portion of the shoulder joint, with thickenings at its anterior and posterior edges. Its function is dependent on the position of the arm. AIGHL, anteroinferior glenohumeral ligament; MGHL, middle glenohumeral ligament; PIGHL, posteroinferior glenohumeral ligament.

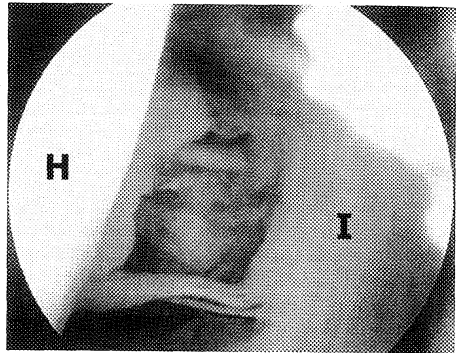


Figure 9-12 Humeral avulsion of the glenohumeral ligament (HAGL). Typically, the anterior structures of the shoulder are damaged at their glenoid insertions during dislocation. An HAGL lesion develops when they fail at their humeral insertion instead. H, humeral head; I, inferior glenohumeral ligament.

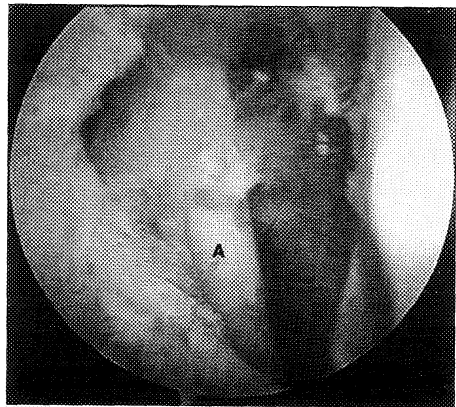


Figure 9-13 Arthroscopic view of the axillary nerve (A) just outside the inferior capsule. The nerve lies just inferior to the inferior pouch and can be injured during capsular release, suture plication, and other anterior or inferior procedures.

humeral head when the arm is abducted 90 degrees and externally rotated. It also prevents posterior translation when the arm is abducted and internally rotated (Fig. 9-14).⁹ From this position, the posterior insertion of the rotator cuff can be evaluated for fraying associated with internal impingement. The arm should be abducted to 90 to 110 degrees and maximally externally rotated. Fraying and contact of the posterior labrum and the rotator cuff tendon in a patient with pain can be indicative of internal impingement.

Humerus and Rotator Cuff Insertion

Evaluating the supraspinatus tendon insertion beginning just posterior to the biceps tendon is performed with slight forward elevation and external rotation of the humerus (see Fig. 9-8). Placing an 18-gauge spinal

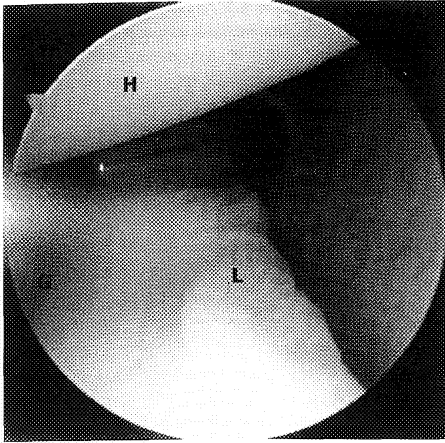


Figure 9-14 Anterior arthroscopic view showing the posterior tuberosity and capsule. The cannula is in the posterior portal. G, glenoid; H, humeral head; L, labrum.

needle percutaneously and passing a monofilament suture into the joint assists in identifying partial-thickness tears by viewing the suture from within the subacromial space following intra-articular arthroscopy (Fig. 9-15).

By observing the posterior and inferior humerus, the bare area can be visualized. This is an area of bare bone with remnants of old vascular channels. This bare area also correlates with the attachment of the infraspinatus tendon. It can be used as a landmark in rotator cuff surgery to align the infraspinatus to its footprint (Fig. 9-16).

Subacromial Evaluation

After complete glenohumeral arthroscopy, the posterior portal cannula and trocar are withdrawn through the interval between the infraspinatus and teres minor muscles. The trocar is withdrawn so as not to bring in any of the rotator cuff musculature when entering the subacromial space. The trocar and cannula are angled more superiorly than with glenohumeral arthroscopy, and the posterior border of the acromion is palpated with the trocar. The trocar is then placed underneath the acromion and inserted in an anterior direction. Palpation of the anterior joint with the opposite hand aids in determining how large the acromion is in relation to the length of the cannula. Both these factors give the surgeon feedback about how far the trocar has been advanced into the space. The subacromial bursa is an anterior structure (Fig. 9-17A). After initially aiming anteromedially, the trocar is placed as lateral as possible (Fig. 9-17B). The trocar is removed, and the arthroscope is inserted. When fluid is allowed to distend this potential space, a "room with a view" should be seen (Fig. 9-17C). Soft tissue obscures the view, the surgeon must withdraw and reposition the arthroscope. There is a tendency to be either too medial or too anterior. The anatomic references are reassessed, and the procedure is

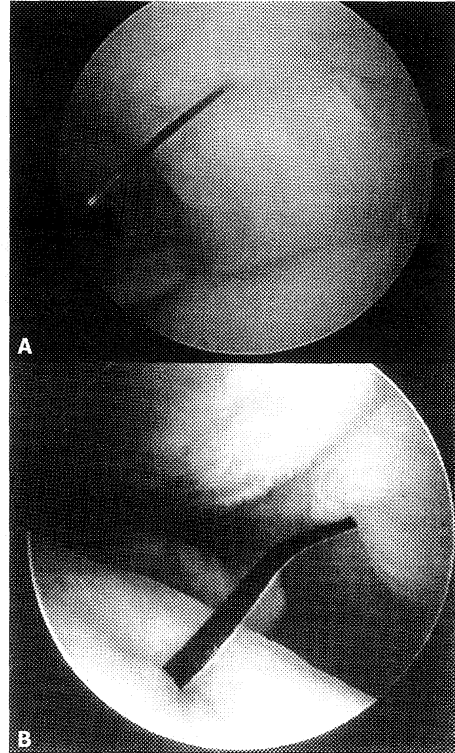


Figure 9-15 A suture can be used to mark the intra-articular location of a partial-thickness rotator cuff tear (A), which can be located in the subacromial space (B), to evaluate the extent of the tear.

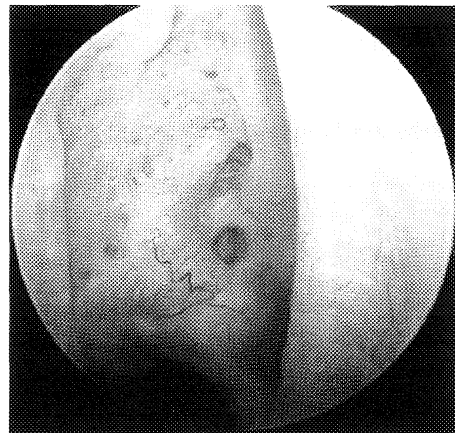

Figure 9-16 Bare area of the humeral head. This landmark corresponds to the insertion of the infraspinatus tendon and can serve as a guide in rotator cuff surgery.

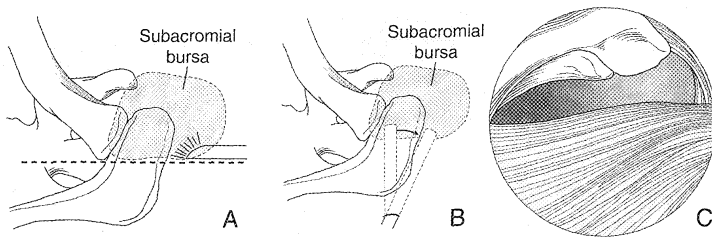


Figure 9-17 A and B, The subacromial bursa is an anterior structure that is easily viewed from either the posterior or lateral portal. C, Posterior view of the subacromial space provides a "room with a view" once the scope is inserted and distention is achieved.

repeated. The posterior portal must be low enough to allow a smooth transition into and out of the subacromial space. If the posterior portal is too close to the scapular spine, a shaver placed through this portal must be aimed inferiorly to get under the acromion, therefore limiting access to the anterior acromion. If an arthroscopic distal clavicle excision is part of the planned procedure, the posterior portal can be made slightly medial so that the angle of attack is more in line with the acromioclavicular joint.

Alternatively, the anterior portal can be used by passing the arthroscope and trocar through the posterior portal and out the anterior aspect of the shoulder. A plastic outflow cannula is placed over the scope sheath and withdrawn to the center of the subacromial space. Following reinsertion of the camera into its sheath, a spinal needle can be used for triangulation to establish the lateral working portal (described next).

The lateral subacromial working portal is essential for subacromial decompression and other work in the bursal space. It should be made at the junction of the anterior one third and posterior two thirds of the acromion (corresponding to the posterior border of the clavicle) and approximately 2 to 3 cm lateral to the lateral edge of the acromion (see Fig. 9-1). This position provides excellent access and angle of attack for instrument use during subacromial decompression. If the cutting block technique for decompression is used, the arthroscope can easily be switched to this lateral portal. Viewing from the lateral portal gives excellent perspective and helps the surgeon judge the extent and plane of resection.

Considerations and Complications

Shoulder arthroscopy is a minimally invasive procedure with significantly less postoperative pain compared with many similar open procedures. The decreased pain with shoulder arthroscopy is due to the lack of layer-by-layer dissection, minimizing the morbidity of soft tissue damage. One disadvantage of arthroscopy is the visual distortion caused by the parallax of the 30- or 70-degree arthroscope. This distortion makes it difficult to determine the smoothness of certain surfaces, especially when dealing with the anterior acromion.

Bleeding in the subacromial space is a problem that has been studied extensively. Morrison et al.¹¹ reported that maintaining a pressure difference (systolic blood pressure minus subacromial space pressure) equal to or

less than 49 mm Hg can prevent bleeding. The acromial branch of the coracoacromial artery is usually transected just lateral to the acromioclavicular joint as the coracoacromial ligament is being resected. Thermal ablation electrocautery devices can facilitate the coagulation of these vessels and help control generalized subacromial bleeding. If bleeding obscures the field of view, the arthroscope should be advanced against the suspected area of bleeding so that the fluid coming from the inflow sheath dilutes the blood enough to allow visualization of the bleeding vessel and the use of electrocautery to control the hemorrhage.

Articular damage can be caused by the sharp corners of the arthroscope or by thermal ablation devices. Such damage can be caused on entrance to the joint and is more likely in the case of inaccurate portal placement.

Other difficulties with shoulder arthroscopy include the extravasation of fluid into the soft tissues.¹⁰ Older patients with poor tissue quality have a greater risk of extravasation because their fascia and capsule are not strong enough to contain the fluid in the glenohumeral or subacromial space. This is rarely a clinical problem, but it can make working with portals and cannulas difficult.

True complications are rare, especially if the surgeon pays strict attention to detail. Proper portal placement avoids the majority of neurovascular complications of shoulder arthroscopy. With the patient in the lateral decubitus position, traction in the operative limb may cause neurapraxia.⁷ The position that seems to result in the greatest traction on the brachial plexus is 30 degrees of forward elevation and 70 degrees of abduction.⁷ The risk of infection is rare in shoulder arthroscopy and has been reported to occur in less than 1% of cases.¹

Other general areas of concern include the effect of epinephrine in the arthroscopic irrigation solution. This could cause an arrhythmia or generalized vasoconstriction, increasing the systemic vascular resistance and pulmonary pressure and causing pulmonary edema.

If large individuals with thick necks are extubated too quickly, they can experience laryngospasm. The force generated by the accessory muscles of inspiration can cause a negative-pressure pulmonary edema.

Other complications can be caused by anesthesia. Interscalene blocks have proved to be a successful method of pain control. Reported complications include hematoma formation, phrenic and recurrent laryngeal nerve block, vasovagal attack, pneumothorax, total spinal anesthesia, high epidural block, Horner syndrome, and cardiac arrest.¹² Dietzel and Ciullo⁴ reported four cases

of spontaneous pneumothorax after shoulder arthroscopy. All these patients had a history of smoking or asthma, and all had been operated on in the lateral decubitus position.

A patient with deep venous thromboembolism was reported by Burkhart.² This patient had pain and swelling 3 days after surgery, and venography showed thrombosis of the basilic vein. Because deep vein thrombosis is so rare, its occurrence should prompt investigation for a hypercoagulable state.

Conclusion

Diagnostic arthroscopy is a critical and necessary component of any arthroscopic shoulder procedure. An understanding of normal anatomy helps determine appropriate treatment for pathoanatomy found to be present in specific clinical scenarios. Although arthroscopy provides a sensitive mechanism for evaluating articular anatomy, the risk of overdiagnosing an anatomic finding as a pathologic entity is a real concern. Clearly, attention to the history, mechanism of injury, physical findings, and examination under anesthesia is necessary to associate the arthroscopic findings with clinically relevant pathology.

References

1. Armstrong RW, Bolding F, Joseph R: Septic arthritis following arthroscopy: Clinical syndromes and analysis of risk factors. *Arthroscopy* 8:213-223, 1992.
2. Burkhart SS: Deep venous thrombosis after shoulder arthroscopy. *Arthroscopy* 6:61-63, 1990.
3. Burkhart SS, Morgan CD: The peel back mechanism: Its role in producing and extending posterior type II SLAP lesions and its effect on SLAP repair rehabilitation. *Arthroscopy* 14:637-640, 1998.
4. Dietzel DP, Ciullo JV: Spontaneous pneumothorax after shoulder arthroscopy: A report of four cases. *Arthroscopy* 12:99-102, 1996.
5. Ellman H, Gartsman GM: *Arthroscopic Shoulder Surgery and Related Procedures*. Philadelphia, Lea & Febiger, 1993, p 67.
6. Gohlke F, Essigkrug B, Schmitz F: The pattern of the collagen fiber bundles of the capsule of the glenohumeral joint. *J Shoulder Elbow Surg* 3:111-128, 1994.
7. Hamada S, Hamada M, Nishiue S, Doi T: Osteochondritis dissecans of the humeral head [case report]. *Arthroscopy* 8:132-137, 1992.
8. Jobe CM: Posterior superior glenoid impingement: Expanded spectrum. *Arthroscopy* 11:530-536, 1995.
9. Jobe FW, Giangarra CE, Kvitne RS, Glousman RE: Anterior capsulolabral reconstruction of the shoulder in athletes in overhand sports. *Am J Sports Med* 19:428-434, 1991.
10. Jurvelin JS, Jurvelin JA, Kiviranta I, Klausner RJ: Effects of different irrigation liquids and times on articular cartilage: An experimental, biomechanical study. *Arthroscopy* 10:667-672, 1994.
11. Morrison DS, Schaefer RK, Friedman RL: The relationship between subacromial pressure, blood pressure, and visual clarity during arthroscopic subacromial decompression. *Arthroscopy* 11:557-560, 1995.
12. Schaffer BS, Tibone JE: Arthroscopic shoulder instability surgery complications. *Clin Sports Med* 4:737-767, 1999.
13. Snyder SJ, Karzel RP, del Pizzo W, et al: SLAP lesions of the shoulder. *Arthroscopy* 6:274-279, 1990.
14. Williams MM, Snyder SJ, Buford D: The Buford complex—the “cord-like” middle glenohumeral ligament and absent anterosuperior labrum complex: A normal anatomic capsulolabral variant. *Arthroscopy* 10:241-247, 1994.
15. Yamaguchi K. Personal communication, AAOS Advanced Shoulder Course, July 2002.