

VIII. Shoulder Instability

- A. Introduction. Laxity is asymptomatic passive translation of the humeral head on the glenoid. It is required for normal shoulder motion and changes with the position of the arm as static restraints tighten and decrease translation. Instability is a pathologic condition manifesting as pain due to excessive translation of the humeral head on the glenoid during active shoulder motion. Instability represents a spectrum of injury to, or dysfunction of, the dynamic and static shoulder stabilizers. Matsen and Arntz describe two different extremes of instability, AMBRI(I) and TUBS. The AMBRI(I) variant is described as *a*traumatic, *m*ultidirectional, *b*ilateral, responsive to *r*ehabilitation, or failing that, *i*nferior capsular shift. The second *i* refers to contemporary thinking regarding closure of the rotator interval due to its contribution to inferior instability. The TUBS variant is described as *t*raumatic, *u*nidirectional, with *B*ankart lesion, responding to surgery. These variants represent the ends of a continuum of mixed pathology associated with instability.
- B. Pathoanatomy (Table 4-6). Instability is associated with several pathologies. The "essential lesion" is thought to be detachment of the anchoring point of the IGHIL and MGHL from the glenoid (Bankart lesion). It is present in up to 90% of cases of traumatic anterior dislocations (Fig. 4-74). More recently, cadaver studies have shown that isolated Bankart lesions may cause only minimal increases in anterior translation. Other pathologies associated with instability include capsular rupture, avulsion, intrasubstance injury, and plastic deformation from repeated submaximal trauma. Hill-Sachs lesions (present in 80% of traumatic anterior

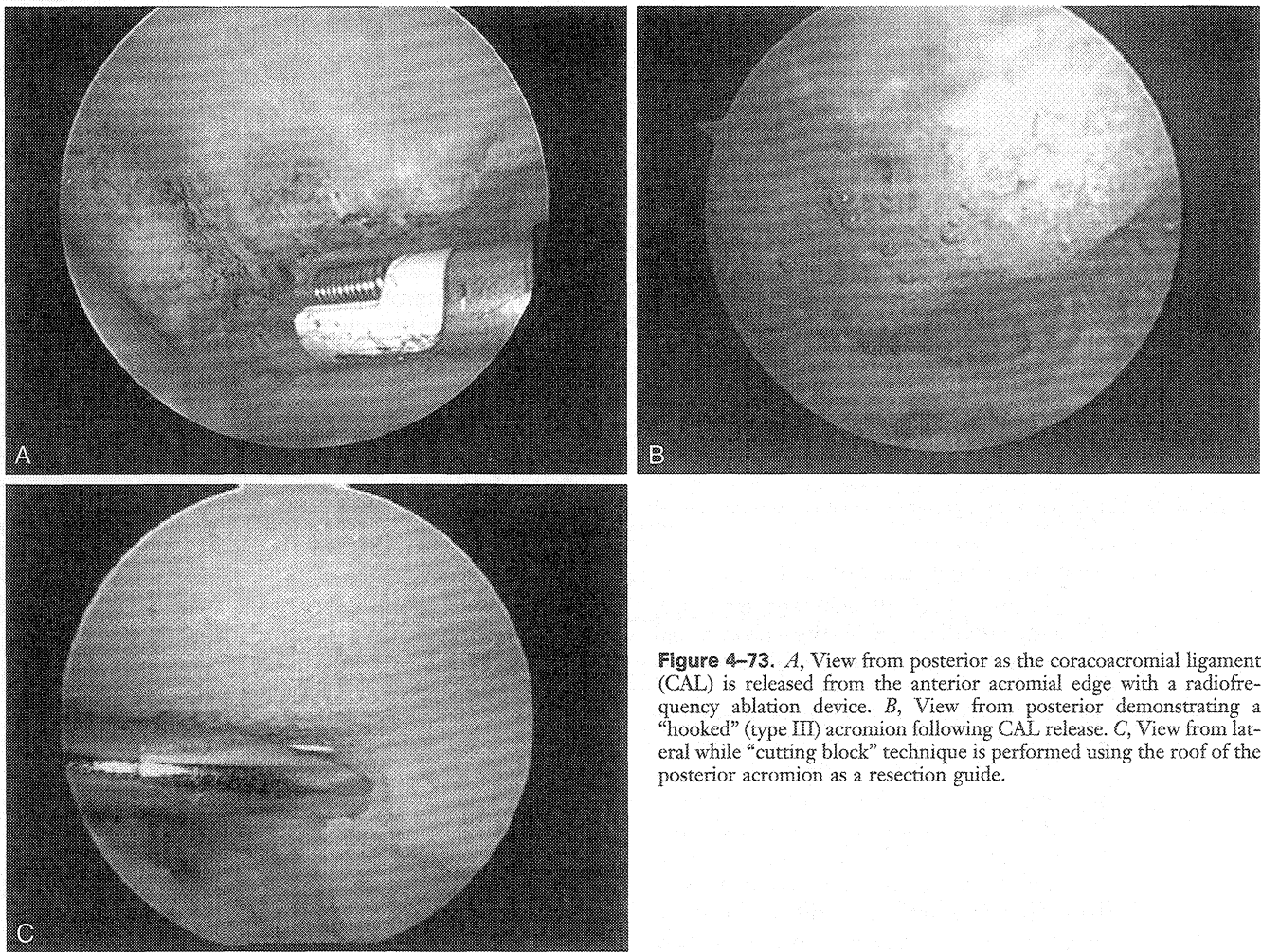


Figure 4-73. *A*, View from posterior as the coracoacromial ligament (CAL) is released from the anterior acromial edge with a radiofrequency ablation device. *B*, View from posterior demonstrating a “hooked” (type III) acromion following CAL release. *C*, View from lateral while “cutting block” technique is performed using the roof of the posterior acromion as a resection guide.

Table 4-6.

Pathoanatomy of Shoulder Instability

Stability Factor	Pathoanatomy
Articular congruity	Fracture Bankart lesion Arthritis
Labrum	Congenital dysplasia Fraying Bankart lesion
Capsuloligamentous structures	Tear Deformation Loss of proprioceptive feedback Congenital laxity
Glenoid/humeral version	Trauma Dysplasia
Negative intra-articular pressure	Capsular tear or laxity Rotator interval defect
Biceps	SLAP lesion Tendon rupture
Rotator cuff	Traumatic tear Cumulative microtrauma
Scapulothoracic motion	Dyskinesia Long thoracic nerve palsy

SLAP, superior labrum anterior-posterior.

From Cole BJ, Warner JJP: Anatomy, biomechanics, and pathophysiology of glenohumeral instability. In Iannotti JP, Williams GR (eds): Disorders of the Shoulder: Diagnosis and Management. Philadelphia: Lippincott Williams & Wilkins, 1999.

dislocations and 25% of subluxations) and bony Bankart lesions disrupt the normal anatomic relationship of the GH joint. Articular lesions involving more than 30% of the articular surface contribute to instability even following capsular repair and may need to be addressed surgically. Abnormal articular version may also contribute to instability.

C. Diagnosis. The mechanism of injury and associated symptoms are determined. The most common form of instability is traumatic *anterior* instability occurring most often with the arm in abduction and external rotation. The presence of a Bankart lesion is likely. If minimal trauma, such as reaching overhead, causes dislocation, capsular laxity is often a component, and consideration of *multidirectional instability* must be entertained. Additional clues include inherent ligamentous laxity and repetitive microtrauma such as that seen in throwers, gymnasts, and swimmers. Pain while carrying objects at the side offers an additional clue to multidirectional instability. A posteriorly directed force to the proximal humerus or an indirect force to the flexed and internally rotated arm is a common mechanism for *posterior* in-

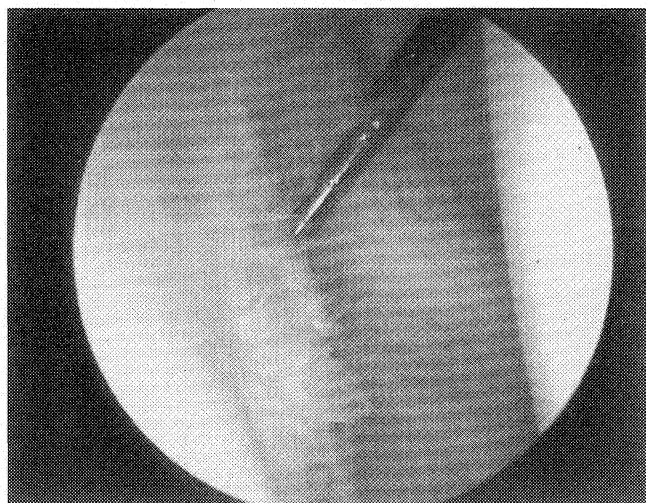


Figure 4-74. Arthroscopic view of Bankart lesion with detachment of the glenoid labrum from the 2 o'clock to the 6 o'clock position on a right shoulder.

stability. A history of alcohol use, epilepsy, and electrocution are additional clues to this diagnosis. Unfortunately, posterior instability is initially missed at the time of dislocation in up to 50% of patients, and chronic posterior instability, like multidirectional instability, is often associated with nonspecific pain and not the perception of frank instability.

Evaluation of both shoulders is critical. As alluded to earlier, the apprehension and relocation maneuvers are important physical examination tests for anterior instability, as are the sulcus test (rotator interval insufficiency) and tests that load the labrum (SLAP lesion). Pain with forward elevation and internal rotation may be associated with posterior instability, as is an associated voluntary component. A neurologic examination of the upper extremity, particularly the axillary nerve, must be documented. Radiographs are reviewed for a bony Bankart lesion or a Hill-Sachs lesion. MRI is useful for imaging labral and cuff lesions. Careful classification of instability allows a proper matching of treatment regimens to the pathology present. A system based on degree of instability, frequency of occurrence, direction, and etiology is used.

D. Treatment

1. **Initial Treatment.** Closed reduction is performed and postreduction radiographs are obtained. Reduction maneuvers include prone gravity-assisted reduction and gentle supine traction-countertraction. Pre- and postreduction neurovascular examinations are performed, as is an evaluation of the integrity of the rotator cuff (especially important in patients over age 40 years).
2. **Nonoperative Treatment.** Despite conflicting evidence that immobilization may reduce recurrence, 2 to 4 weeks of immobilization (longer for younger patients) fol-

lowed by aggressive rehabilitation focused on strengthening the dynamic stabilizers is generally recommended. Improving neuromuscular function and proprioceptive feedback may lead to symptomatic resolution. Success rates following prolonged rehabilitation of patients with atraumatic shoulder instability (80%) are better than in patients following traumatic instability (20%). Although controversial, some authors suggest arthroscopic stabilization in young patients who will continue to engage in high-risk activities and whose age-related recurrence rates are in excess of 90%. This is especially true if athletes are unable to compete following efforts at rehabilitation.

3. **Surgical Treatment.** To date, no truly randomized prospective study with a pure patient population has compared arthroscopic and open stabilization techniques. Arthroscopic reconstruction allows identification and treatment of concomitant pathology, has a lower morbidity, reduced pain, improved cosmesis, and potentially earlier functional recovery. Potential disadvantages include the relative learning curve and the inability to effectively address some capsulolabral and bony pathology.

- a. **Examination under Anesthesia (EUA)** (Fig. 4-75). The humeral head is centered on the glenoid, and the amount of translation of the humeral head is graded and compared with the other side. Similarly, inferior laxity is tested and scored as previously described. Testing the shoulder in adduction, 45° and 90° of abduction, and internal and external rotation evaluates the integrity of the capsuloligamentous structures to guide

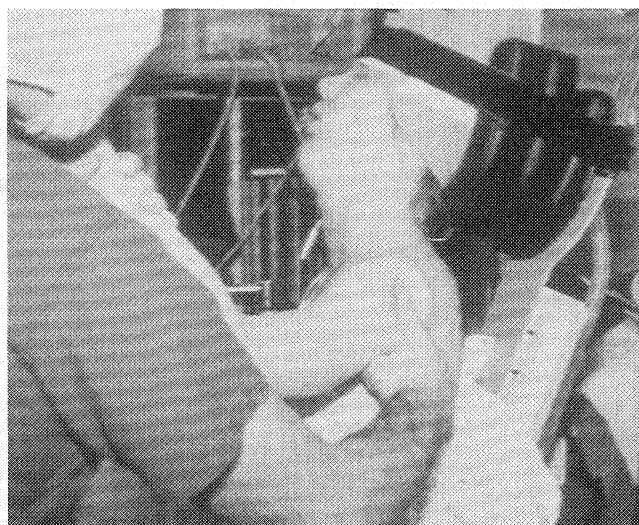


Figure 4-75. Examination under anesthesia performed to determine the primary direction of instability.

surgical treatment. Generalized ligamentous laxity or a significant inferior component indicates the need to also address capsular laxity and, possibly, the rotator interval. The degree of laxity, however, does not necessarily correlate with the presence of a Bankart lesion.

- b. **Diagnostic Arthroscopy.** Additional information regarding the underlying pathology is appreciated at the time of arthroscopy. As already discussed, a systematic evaluation of the GH joint is performed to define all associated pathology. The labrum is evaluated for signs of detachment or medial healing along the scapular neck. The quality and integrity of capsuloligamentous structures is observed in different positions of arm rotation. The dampening of anterior translation with shoulder abduction and external rotation (modified arthroscopic drawer test) and the presence of a drive-through sign is noted. This information is critical to determine the need for capsular plication in addition to anatomic labral repair.
- c. **Arthroscopic Treatment.** Patient selection is critical. Indications include patients with symptomatic recurrent instability despite attempts at nonoperative treatment and patients who experience instability at rest or during their sleep. The best results are in skeletally mature patients with post-traumatic anterior instability with a Bankart lesion and an intact capsuloligamentous complex. Midsubstance or insertional capsular rupture, significant bony insufficiency, and inability to obtain stability with arthroscopic techniques are contraindications to arthroscopic stabilization. The

goals are secure reattachment of the anteroinferior labrum and establishing proper tension in the IGHLC. Capsular laxity (such as that seen in MDI) is addressed with suture plication with or without labral repair or by thermal techniques following labral repair.

Several techniques exist (Table 4-7) to repair the labrum, including transglenoid suture repair (popularized by Caspari), single-point fixation devices (e.g., the Suretac device, Acuflex Microsurgical, Mansfield, Mass.), suture anchors (metal, plastic, bioabsorbable, bone, or plastic), or suture anchors with knotless fixation (Knotless Suture Anchor, MITEK Products, Inc., Westwood, Mass.). Advantages and disadvantages exist for all of these devices, but in principle they achieve anatomic labral repair with variable ability to simultaneously plicate the capsule. The most common techniques require anchor placement, suture passage, and arthroscopic knot-tying techniques.

- d. **Suture Anchor and Suture Plication Technique**
- (1) **Instrumentation**
- Cannulas.** Must fit available instrumentation. Clear screw-in cannulas allow visualization and minimize motion.
 - Anchors.** Must be cortical anchors. Insertion is anchor-specific and may require predrilling or tapping.
 - Sutures.** Most common is No. 1 or No. 2 braided nonabsorbable or prolonged absorbable sutures.
 - Suture Passers.** Used for retrieving sutures by piercing the labrum first and grasping the su-

Table 4-7.

Arthroscopic Stabilization Techniques

Technique	Advantages	Disadvantages
Staple capsulorrhaphy		High failure (30%) Staple migration/breakage Does not address capsular laxity
Transglenoid sutures	Multiple fixation points address capsular laxity	High failure rate Suture loosening with time Sutures cannot be tied arthroscopically Suprascapular nerve injury
Cannulated bioabsorbable implants	Avoids transscapular drilling Short learning curve	Does not address capsular laxity Possible synovial reaction to polyglyconate
Suture anchors	Low failure rate (10%) Arthroscopic knot tying	Technical difficulty Suture breakage Screw migration

Adapted from Cole BJ, Warner JJP: Arthroscopic versus open Bankart repair for traumatic anterior shoulder instability. *Clin Sports Med* 19:19-48, 2000.

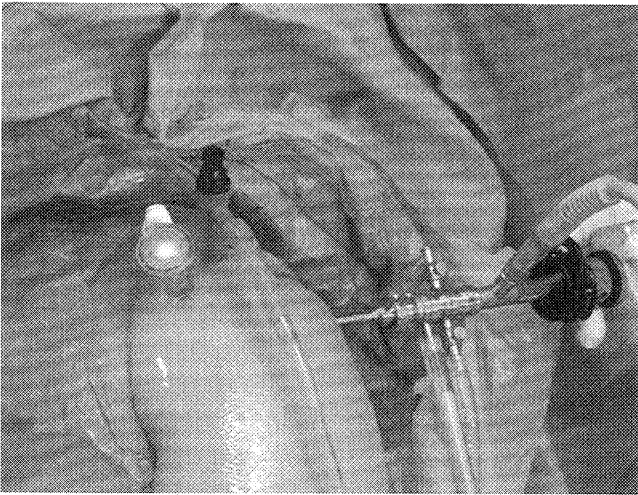


Figure 4-76. Portal placement in preparation for arthroscopic stabilization using suture anchors. Generally, two anterior working portals and one posterior viewing portal is sufficient to perform all required steps of the procedure.

ture or by piercing the labrum and passing a shuttle that is secured to the suture to retrieve it retrograde through the tissue.

- (e) Crochet Hook. Used to manage and retrieve sutures.

- (f) Knot Pusher. Typically, a straight device with a hole on the end that allows a sliding knot or a half-hitch (“suture loop”) to be slid down the suture “post.”

- (g) Arthroscopic Knots. Sliding knots (e.g., Duncan loop) and serial half-hitches in the form of suture loops create tight, secure, and locked knots that will not loosen. Alternating the posts and the direction of each half-hitch a minimum of three times maximizes knot security.

- (2) Portal Placement (Fig. 4-76). Typically, three standard portals are established: the posterior, anterosuperior, and anteroinferior. Wide separation between the two anterior portals avoids crowding.

- (3) Glenoid Preparation and Anchor Placement. The labrum is mobilized off the glenoid to the 6 o'clock position using electrocautery, an elevator, and arthroscopic bur to a point 1 to 2 cm medial to create a bleeding bed (Fig. 4-77). Anchors are positioned on the articular rim beginning at the 5 o'clock position.

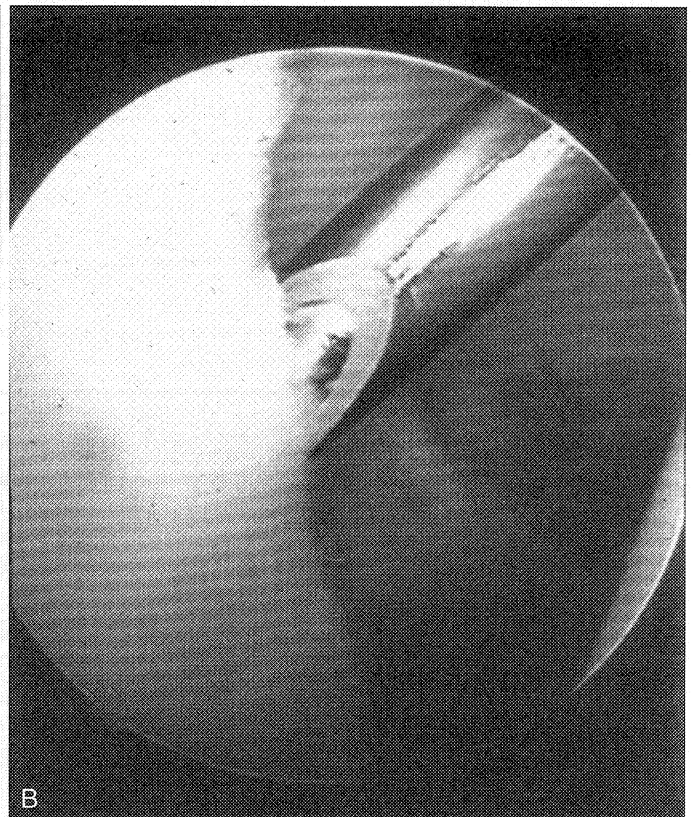
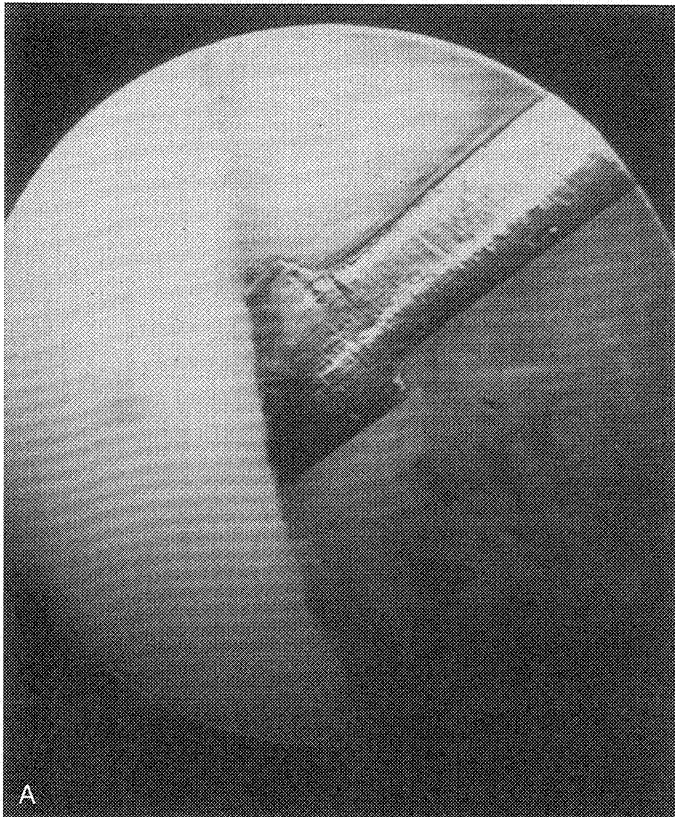


Figure 4-77. Arthroscopic preparation of the Bankart lesion using (A) a small rasp through the anterosuperior portal and (B) an arthroscopic bur to create a bleeding cancellous surface.

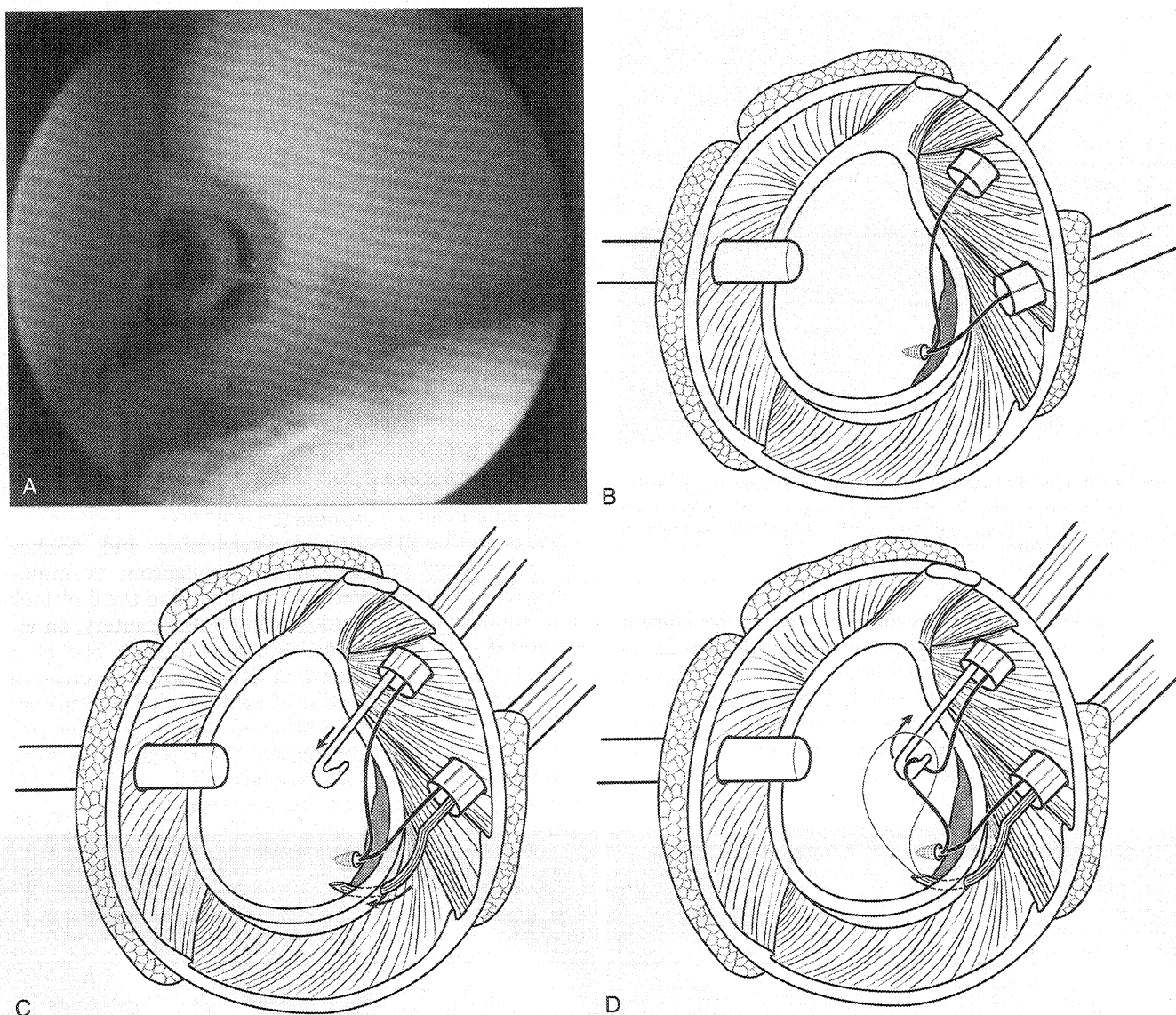


Figure 4-78. Anterior glenohumeral reconstruction sequence. *A*, Proper placement of the anchor on the articular surface of the glenoid rim. *B*, Suture management begins with separation of the two limbs through separate cannulas. *C*, Suture re-retrieval device (or a suture-passing device) is passed through the capsule and labrum inferior to the anchor approximately 1.0 to 1.5 cm medial to the lateral edge. *D*, A crochet hook is used to pull the limb of the suture through the wire loop to capture the suture.

Sutures are passed through the soft tissue and the knot is tied and cut before the next anchor is placed.

- (4) Anterior GH Reconstruction (Fig. 4-78). The first anchor is critical to establishing proper capsular tension. A suture hook (Spectrum, or Caspari Punch, Linvatec, Key Largo, Fla.) or other suture-passing device is placed through the capsule medial and inferior to the lowest anchor to shift the capsule superiorly and laterally. It is helpful to first separate the suture limbs so that one limb is present within each anterior cannula in preparation for shuttling the post limb from within the superior can-

nula through the soft tissue and out the inferior cannula in preparation for arthroscopic knot tying. Additional anchors are placed as needed. If a biodegradable tack is used, a guidewire pierces the detached labrum and IGHL and is advanced into the anterior scapula. A tack is then placed over the wire and impacted (Fig. 4-79).

- (5) The Rotator Interval. In patients with MDI or persistent inferior or infero-posterior translation, rotator interval closure can be accomplished using a suture passer and spinal needle to plicate the interval by tying the suture ends outside the capsule (Fig. 4-80).

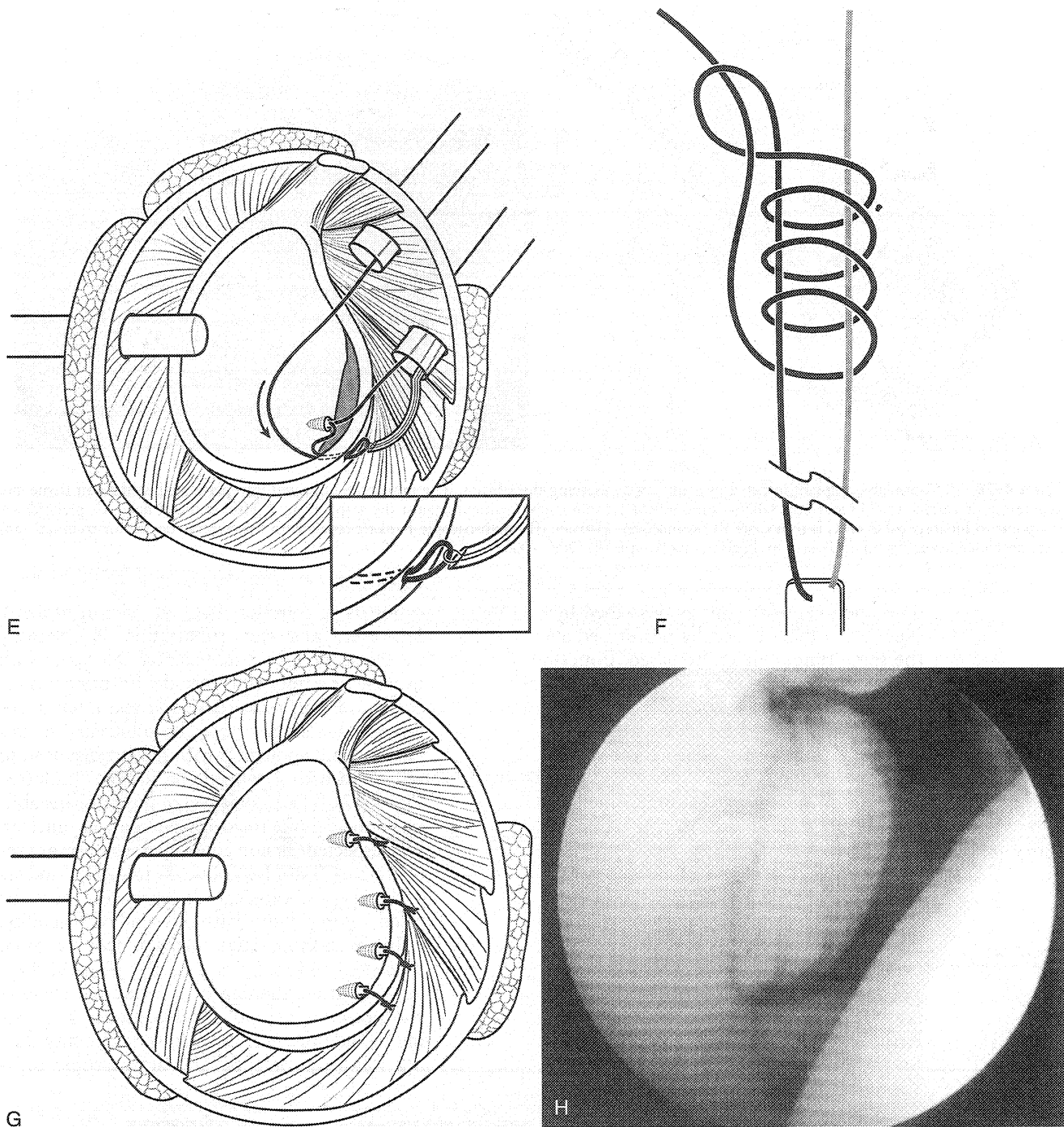


Figure 4-78. (Continued) *E*, Suture retrieved through the capsulolabral complex. This limb will become the “post” limb for the sliding knot. *F*, Duncan loop with switched-post, reversed-direction half-hitches. *G*, Schematic of completed repair. *H*, Arthroscopic view of repair. (From Romeo AA, Cohen B, Carreira: Traumatic anterior shoulder instability. *Op Tech Sports Med* 8:188–196, 2000.)

(6) **Capsular Laxity.** Persistent capsular laxity following capsulolabral repair or in patients with MDI is managed either with suture plication similar to rotator interval closure or with a suture hook passing a PDS suture through both the capsule and the labrum followed by arthroscopic in-

tra-articular knot tying. Alternatively, thermal techniques may be utilized (see next section).

e. **Open Bankart Repair and Capsular Shift** (Fig. 4-81). The anterior deltopectoral approach is utilized. The principles and steps of medial capsulolabral repair are similar to the arthroscopic technique.

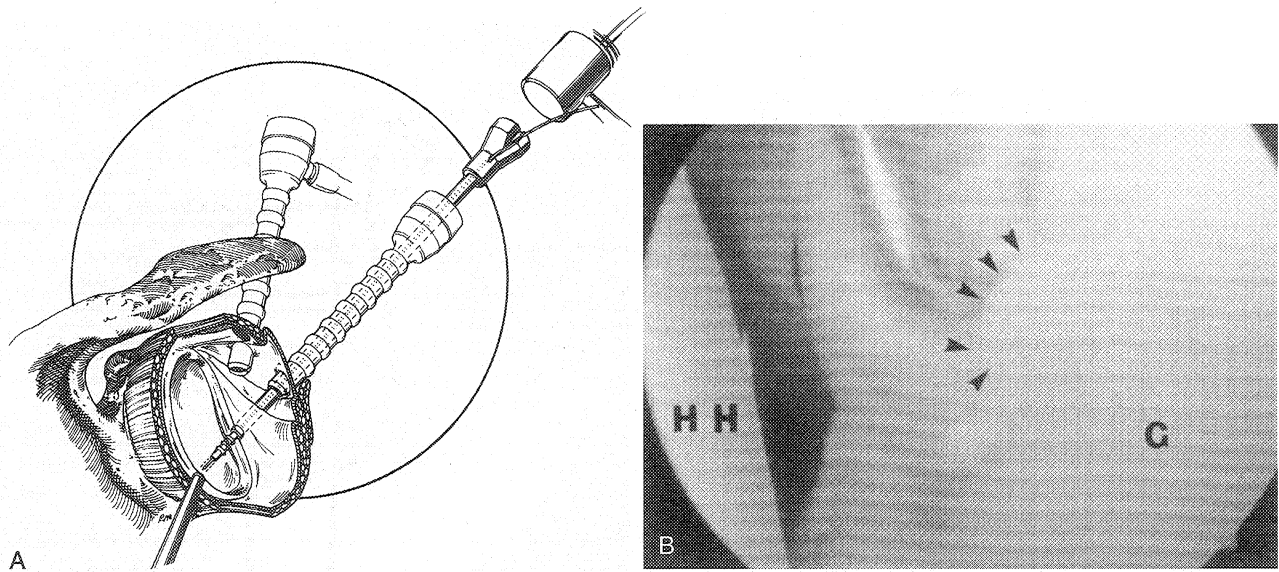


Figure 4-79. *A*, Cannulated implant inserted over guidewire piercing the labrum. The implant is impacted into place against the soft tissue and prepared bony surface to (*B*) secure the labrum and inferior glenohumeral ligament against the scapular neck. HH, humeral head; G, glenoid; *arrows* point to bioabsorbable tack. (From Cole BJ, Romeo AA, Warner JJP: Arthroscopic Bankart repair with the Suretac device for traumatic anterior shoulder instability in athletes. *Op Tech Sports Med* 8:197-205, 2000.)

The open capsular shift as described by Neer and others is usually performed at the same time. A laterally based T-incision is made in the capsule and after inspection of the joint and repair of the labrum the inferior leaf of the capsule is imbricated superiorly beneath the superior limb of the capsule.

- f. Rehabilitation. Rehabilitation is identical for open and arthroscopic repairs. Sling immobilization lasts 4 to 6 weeks. Active hand, wrist, and elbow motions, as well as gentle pendulum exercises, begin immediately. Active forward elevation to 120° and external rotation to 30° begins at 2 to 3 weeks and is advanced at 4 to 6 weeks. At 8 to 10 weeks progressive resistance exercises are begun. Return to sport occurs at 16 to 32 weeks.

E. Posterior Instability. Posterior shoulder dislo-

cation is uncommon but not rare in athletes. However, posterior subluxation is relatively common. Posterior subluxation can occur with overuse or a traumatic episode. Examination reveals pain with forward flexion and internal rotation. The shoulder may be subluxated in this position and abduction with flexion may lead to reduction with a palpable or audible clunk (see Fig. 4-32). The association of posterior instability with glenoid retroversion remains unclear, but suspected version abnormalities warrant preoperative CT study. Voluntary instability and associated psychological disturbances must be ruled out in patients with this kind of instability.

Initial nonoperative management is often successful and includes extensive physical therapy and strengthening of the external rotators and posterior deltoid. Modifications to throwing include the use of the lower extremity during followthrough. Several arthroscopic tech-

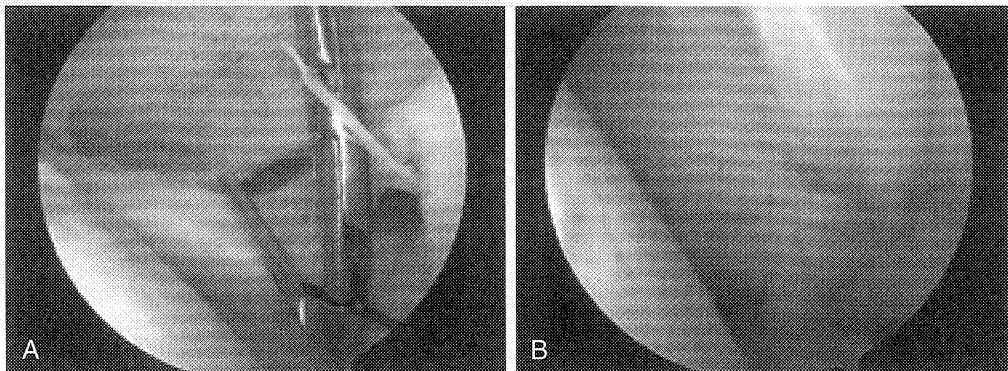


Figure 4-80. Rotator interval closure performed by (*A*) placing a No. 1 PDS suture through a spinal needle at the level of the middle glenohumeral ligament and a suture-grasping device through the anterosuperior portal and capsule to retrieve the suture. Both suture ends are retrieved through the anterosuperior portal and subsequently tied arthroscopically using a sliding knot to (*B*) vertically close the rotator interval.

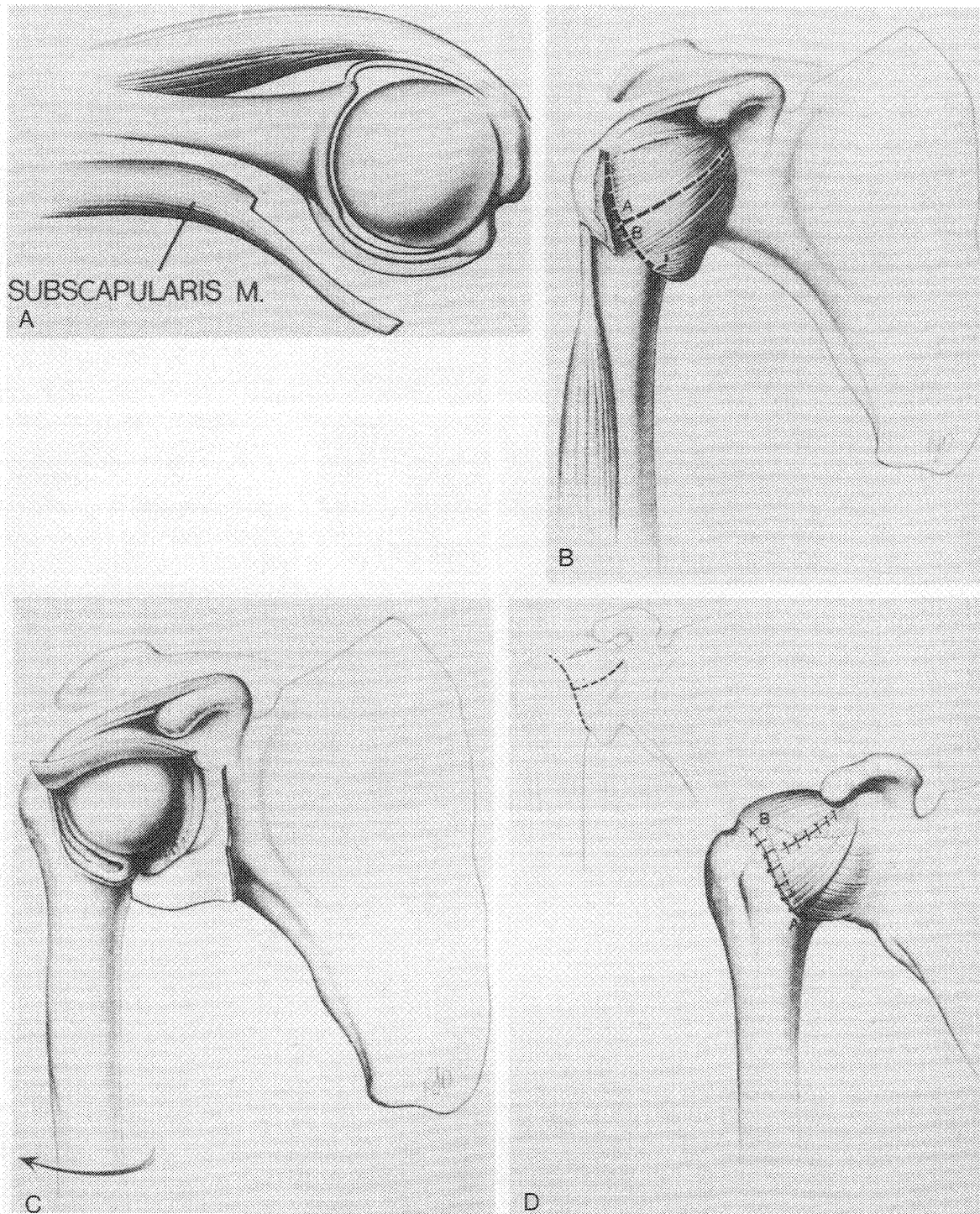


Figure 4-81. Anteroinferior capsular shift. *A*, Note that the subscapularis is dissected off the capsule, leaving some fibers on the capsule to make it more amenable to repair. *B*, T-incision used in the capsule can be based on the humerus, as shown here, or on the glenoid. *C*, Exposure of the joint is facilitated by external rotation. A Fukuda retractor is placed into the joint to inspect (and repair if necessary) the labrum. *D*, Location of flaps following shift. (From Neer CS II, Foster CR: Inferior capsular shift for involuntary inferior and multidirectional instability of the shoulder. A preliminary report. *J Bone Joint Surg Am* 62:897-908, 1980.)

niques are described, but not widely utilized (Fig. 4-82). More commonly, surgical repair is approached through a vertically oriented incision and a deltoid split with deep dissection in the interval between the infraspinatus and teres minor as described previously. The principles of repair are similar to open anterior repair (Fig.

4-83). Postoperatively, patients are immobilized for up to 6 weeks in a handshake or gunslinger orthosis to maintain proper tension on the posterior structures. A return to throwing and contact sports can take upward of 9 months. The results are good, but less favorable than with the treatment of anterior instability.

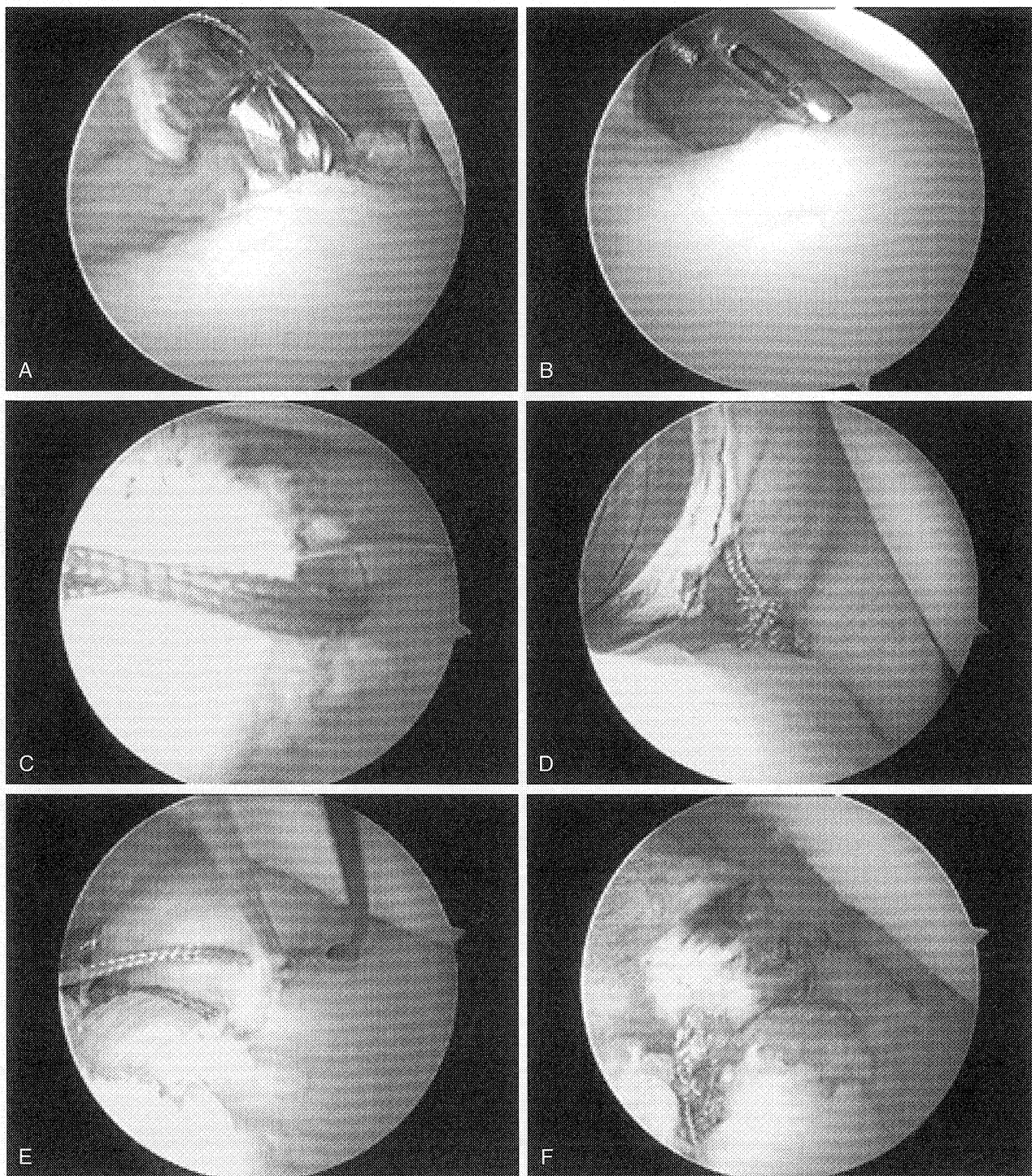


Figure 4-82. Arthroscopic sequence for posterior instability repair. Patient is placed in the lateral decubitus position. The arthroscope is placed through the standard anterosuperior portal. Two posterior working portals are established. *A*, Arthroscopic preparation with an arthroscopic bur to create a bleeding bed. *B*, Anchor placement on the edge of the glenoid. *C*, Suture retrieval device to pierce and grasp the first suture to bring out the posteroinferior portal (Arthrex Penetrator, Naples, Fla.). *D*, First knot tied. *E*, Use of shuttle system using a suture hook to pass a No. 1 PDS to “shuttle” one limb of the suture through the labrum prior to tying the sliding knot (Linvatec Spectrum, Key Largo, Fla.). *F*, Final repair with three anchors.

IX. Thermal Capsulorrhaphy

A. Introduction. Thermal capsulorrhaphy is a relatively new technique with some controversy due to conflicting results, but appears to be useful as an adjunct to arthroscopic treatment for GH instability. It is used to reduce

capsular laxity by denaturing the collagen within the capsule and is technically easier than arthroscopic suture repair. The most common indications are for anterior microinstability and as an adjunct to arthroscopic Bankart repair. Other common indications are for MDI that is

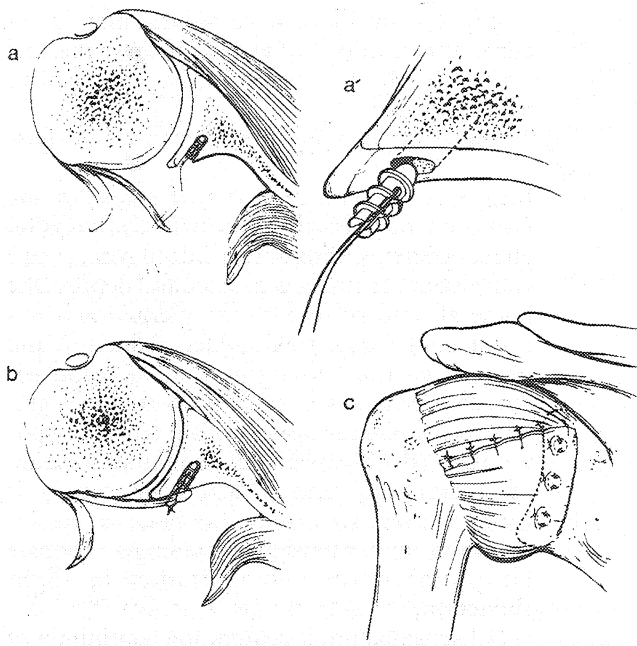


Figure 4-83. Open posterior capsular repair sequence to the glenoid surface using suture anchors. (From Bowen MK, Warren RF: Surgical approaches to posterior instability of the shoulder. *Op Tech Sports Med* 1:301-310, 1993.)

otherwise unresponsive to nonoperative management. Failure rates following the treatment of MDI, however, range from 10% to 50% in some series.

- B. Basic Science.** The application of thermal energy to capsular structures causes a disruption of the heat-sensitive intramolecular bonds in collagen, leading to a transition from the extended helical crystalline-like state to a shortened random configuration. The result is a shortening of the collagen molecule by 20% to 30% of its length. Immediately following treatment, there is significant thermal damage, seen microscopically as a hyalinized zone with pyknotic nuclei. Fibroblasts become hyperactive and, using the contracted collagen as a scaffold, migrate to areas of treatment where they form type I collagen within 72 hours. New collagen production continues for 12 to 14 weeks. By 12 weeks, tissue returns to near normal histologic appearance. Tissue strength is lowest at 2 weeks. At 6 weeks tissue strength is 85% of pretreatment control, and is nearly normal by 12 weeks.
- C. Technique.** The optimal temperature for tissue shrinkage is 65°C to 75°C. The ideal depth of penetration for capsular shrinkage is not currently known. The pattern of shrinkage follows a grid technique leaving 3 to 5 mm of tissue untreated between each pass, enhancing fibroblast migration and vascular ingrowth. Areas with higher collagen densities (e.g., the IGHL) will have a more dramatic "shrinkage" response. Areas with lower collagen densities (e.g., the rotator interval) have a lower response and are more amenable to suture plication.

D. Thermal Devices. There are primarily two types of electro-surgical devices that may be used to transfer heat to promote shrinkage of capsular tissue.

1. **Laser.** Laser produces heat by direct photostimulation of cellular ions, thereby heating the first millimeter of capsular tissue. Its high cost, imprecise temperature control, and need for specialized training limit its widespread use.
2. **Radiofrequency (RF) Probes.** Bipolar RF energy heats tissue by creating a conduction pathway through the arthroscopic medium rather than the tissue. Monopolar RF energy generates heat through molecular excitation of electrolytes in the tissues with a conduction pathway through the tissue to a grounding pad. The majority of basic science and clinical experience is with monopolar RF (Fig. 4-84).

E. Applications. Patients must be able to comply with immobilization and rehabilitation protocols. Contraindications include underlying medical conditions that alter the biomechanical properties of normal collagen such as inflammatory arthritis. Relative contraindications include severe global laxity, capsular rupture, revision stabilization procedures, and isolated application of thermal energy without repair of detachment pathology (e.g., Bankart

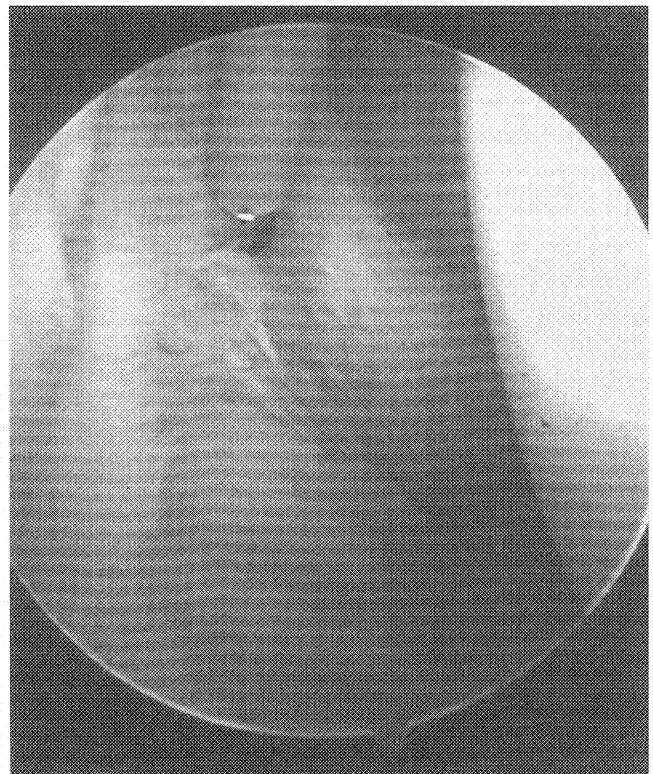


Figure 4-84. Arthroscopic view of monopolar radiofrequency (Oratec Interventions, Menlo Park, Calif.) treatment of the anterior band of the inferior glenohumeral ligament.

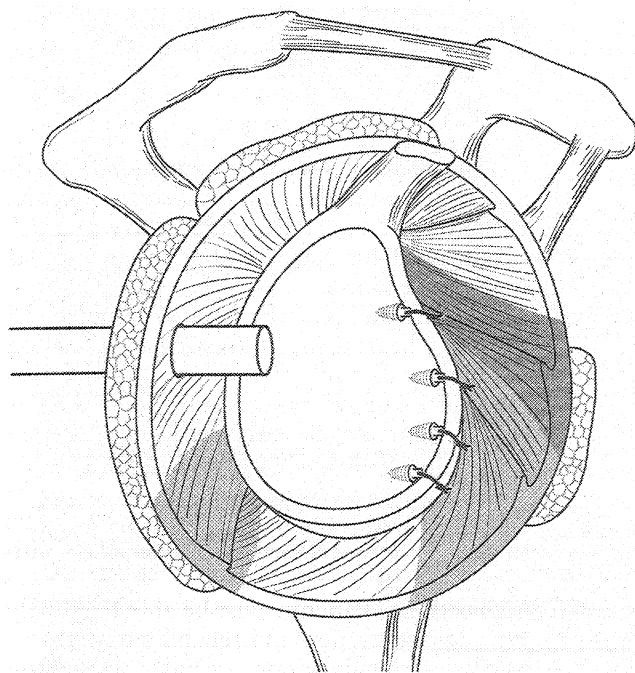


Figure 4-85. Arthroscopic Bankart repair with thermal capsulorrhaphy of the anterior band of the inferior glenohumeral ligament (IGHL), middle glenohumeral ligament, and anterior capsule. The posterior band of the IGHL complex can also be treated if pathologic inferior laxity persists following labral repair (*shaded area*). (From Cohen B, Cole BJ, Romeo AA: Thermal capsulorrhaphy of the shoulder. *Op Tech Orthop* 11:38-45, 2001.)

tion following thermal capsulorrhaphy is recurrent instability. Other risks include thermal necrosis, capsular insufficiency, and axillary neuropathy.

lesion) or unresponsive tissue that may otherwise respond to suture plication (e.g., rotator interval).

1. Anterior Instability. Persistent laxity following Bankart repair (drive-through sign, redundant axillary pouch) may be augmented with thermal treatment of the IGHL complex (Fig. 4-85).
 2. Posterior Instability. A "reverse" Bankart lesion must be repaired. Thermal capsulorrhaphy may address laxity of the capsule and the posterior band of the IGHL. The anterior band of the IGHL is also addressed if laxity persists.
 3. Microinstability. This may be associated with anterior capsular laxity and posterior tightness due to repetitive microtrauma in overhead athletes. Following arthroscopic debridement of the posterosuperior labrum, thermal treatment of the anterior capsuloligamentous structures may offer an effective alternative to suture plication (Fig. 4-86).
 4. Multidirectional Instability. Thermal capsulorrhaphy may be an alternative or adjunct to suture plication of the anterior and posterior capsuloligamentous structures.
- F. Rehabilitation. Sling immobilization is 2 to 3 weeks for anterior instability, 4 weeks for posterior instability, and 4 to 6 weeks for MDI.
- G. Complications. The most common complica-