

Shoulder: Patient Positioning, Portal Placement, and Normal Arthroscopic Anatomy

AUGUSTUS D. MAZZOCCA, BRIAN J. COLE,
AND ANTHONY A. ROMEO

The concept of shoulder arthroscopy was introduced in 1931 by Burman⁴ when he reported on the direct visualization of cadaver joints. Our understanding of and experience with this valuable tool have increased significantly since that time. The anatomy of the shoulder can be examined in detail, allowing analysis of its structure and form. This ability can confirm diagnoses, provide information about particular shoulder pathologies, and improve patient care. In addition, because less soft tissue dissection is required, arthroscopic procedures can result in decreased postoperative pain and generally better early rehabilitation. Patient positioning, portal placement, and fluid management are critical elements in performing effective, reproducible shoulder arthroscopy. This chapter reviews these elements to provide a basic understanding of the performance of other procedures presented in this book.

Preoperative Considerations

A combination of interscalene block and general anesthesia is preferred, leading to a reduced need for inhalation agents and the achievement of postoperative pain relief. Maintenance of a mean arterial pressure of 70 to 90 mmHg or a systolic blood pressure of 100 mmHg maximizes visualization.¹⁸

Obesity is a factor that should be considered before shoulder arthroscopy. A patient with a large abdomen who is positioned in a beach chair position runs the risk of superior vena cava compression, causing decreased venous return and resulting in uncontrollable hypotension. The physician must be willing to lower the back of the table to facilitate the proper return of blood flow to

the heart and restore adequate cardiac output if this problem arises. Another consideration for obese patients is that most operating room beds are rated for 400 pounds. Patients weighing more than 400 pounds require two operating room beds placed together, with the patient in the lateral position with a distraction device.

Examination under Anesthesia

An examination under anesthesia (EUA) is performed with the patient in a supine position. Particular attention is paid to the range of motion (ROM) and stability of the affected shoulder. Comparison between the affected and unaffected limbs should be carried out before the patient is positioned. The EUA is used to support the diagnosis based on the preoperative history, physical examination, and radiographic studies.

Range of Motion

Internal and external rotation with the arm abducted to 90 degrees and at the side should be recorded. An increase in external rotation with the arm at the side may indicate a subscapularis tear, and an increase of internal rotation of the arm abducted to 90 degrees may indicate a posterior rotator cuff tear (infraspinatus or teres minor). Limited external rotation with the arm at the side is seen in osteoarthritis or adhesive capsulitis. Limited internal rotation with the arm abducted is evidence of a tight posterior capsule.

Stability

Labral pathology can be detected during the EUA. A click or grind with loading of the glenohumeral joint can often be elicited in an anesthetized patient who may have been too apprehensive to allow this physical finding to occur while conscious. Increased pathologic translation can also be detected with the EUA. Posterior instability testing can be carried out with the shoulder flexed to 140 degrees (allowing the greater tuberosity to clear the acromion) and adducted to 15 degrees as a posterior-directed axial force is applied. The scapula must be stabilized with the opposite hand when performing this test (Fig. 8-1). Anterior instability can be demonstrated by abducting the arm to 90 degrees and applying an axial and anterior force while stabilizing the scapula. Some other forms of instability may not be apparent with these

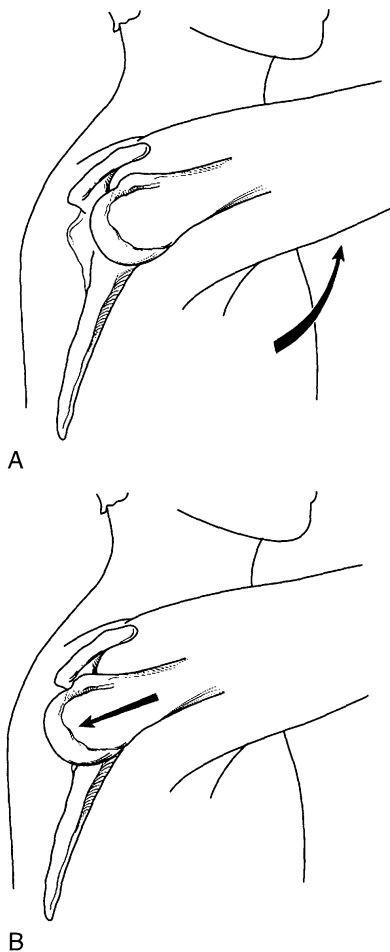


Figure 8-1 A, With the arm flexed to 140 degrees and adducted 15 degrees, the greater tuberosity clears the acromion. B, Posterior-directed axial force with stabilization of the scapula allows the testing of posterior restraints.

maneuvers because such extremes of motion tend to tighten the shoulder capsule. In this case, the arm should be held in neutral with the capsule relaxed, and the humeral head should be grabbed by the examiner's fingers and translated anteriorly and posteriorly. Translation to the glenoid rim is classified as grade I instability, translation over the glenoid rim with spontaneous reduction is grade II, and translation over the rim that is locked and irreducible is classified as grade III.¹ Once the EUA is completed, the patient is positioned.

Patient Positioning

Beach Chair

In the beach chair position (Fig. 8-2), the patient is aligned on the edge of the table so that the affected shoulder is not supported by it (i.e., the medial scapula is parallel and adjacent to the table's edge). Some operating room tables are equipped with headrests with removable backs so that the entire posterosuperior quadrant of the patient is easily accessible. The operating room table is flexed approximately 45 to 60 degrees, and the patient's legs are lowered so that they are parallel to the floor. Lowering the legs beyond the horizontal would allow operative equipment placed on the patient's thighs to slide down to the floor. This is easily remedied by having a Mayo stand positioned over the patient's thighs to hold any operative equipment. The back of the table is completely elevated, which positions the acromion at an approximately 90-degree angle to the floor and places the glenohumeral joint in an anatomic position. The table back is lowered to 30 degrees if conversion to an open procedure is required.

Lateral Decubitus

In the lateral position, the patient must be placed on a beanbag or other stabilizing device, with all bony prominences padded. The patient's torso is rolled posterior 25 to 30 degrees to position the glenoid parallel to the floor (Fig. 8-3). This also opens up the joint and facilitates access into the shoulder joint with the arthroscope. An axillary roll is placed under the thorax distal to the axilla to protect the brachial plexus, and the patient's torso is secured. Once positioned, the arm is suspended so that it can be prepared and draped in a sterile surgical fashion. With the lateral decubitus position, the arm is placed in a foam traction sleeve and connected to the traction device (Fig. 8-4). It is positioned in 45 degrees of abduction and 15 degrees of forward flexion. This arm position is adequate for visualization of both the glenohumeral joint and the subacromial space, obviating the need for repositioning during the procedure. Some surgeons prefer to increase the angle of the arm to 70 degrees, allowing the greater tuberosity to be in a more abducted position and taking tension off the deltoid muscle. Traction is then applied with the arm in neutral. If the arm is rotated, traction should not be placed. Ten pounds is placed for arm distraction, and 10 pounds is

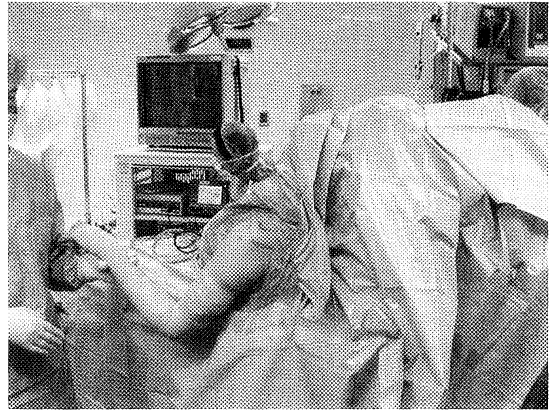
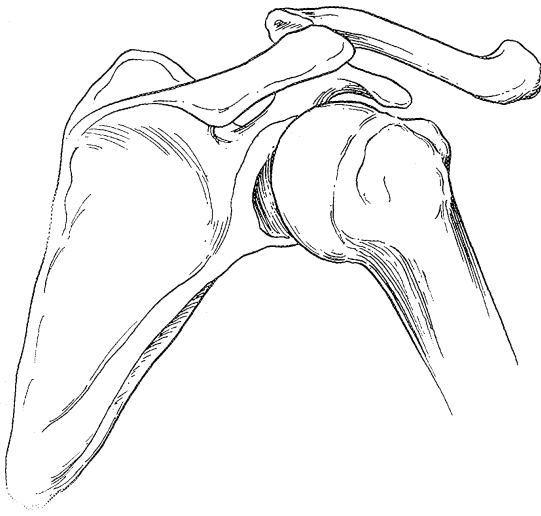


Figure 8-2 A, Scapular-humeral articulation in the beach chair position. B, Patient in the beach chair position supported by a McConnell headrest and side plate.

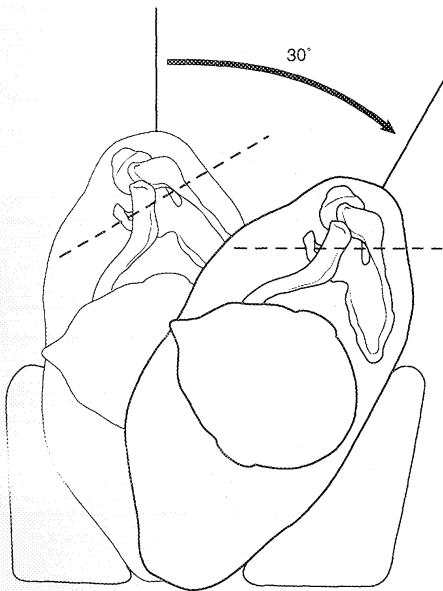


Figure 8-3 Lateral decubitus position with the patient angled 30 degrees posteriorly to place the glenoid parallel to the floor.

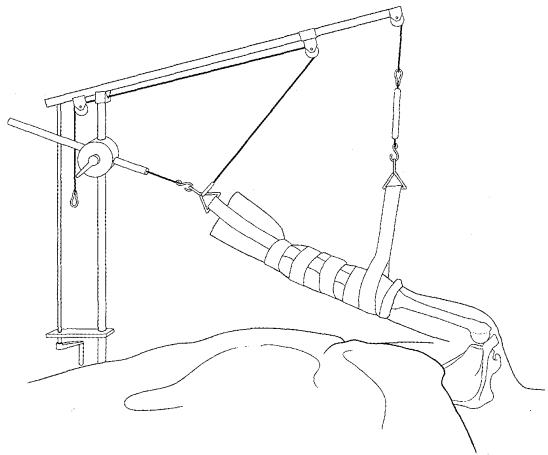


Figure 8-4 Lateral decubitus position with the arm in a foam sleeve. For glenohumeral surgery, the arm is abducted to 45 degrees. For subacromial surgery, the arm is abducted only 20 to 30 degrees. (Courtesy of Arthrex, Naples, FL.)

placed for abduction traction. The humerus is allowed to float away from the glenoid. Optimal traction is achieved when the arm is in a neutral position so that the shoulder capsule ligaments are relaxed. More than 20 pounds of weight is not recommended because a neuroparaxia may develop as traction weight increases.^{8,14}

■ Skin Preparation and Draping

There are numerous commercially available bacteriostatic solutions for use in operating rooms and surgery centers. There is no consensus about the necessity of shaving the axilla at the time of surgery. Having the least amount of skin accessible to the surgical wound is desirable.

Draping for shoulder arthroscopy follows the same principles as for other operative procedures. The basic

difference is the potential for a tremendous amount of fluid to be distributed about the surgical field. Plastic U drapes with water bags or receptacles placed proximally and distally to the axilla may limit this phenomenon. Inadvertently draping out the surgical field during preparation must be avoided.


Equipment Setup

After the completion of patient positioning, equipment setup is considered. A tower containing a video monitor, control box, light source, shaver power source, videotape recorder, and irrigation pump is placed opposite the surgeon at the level of the shoulder on the opposite side of the patient (Fig. 8-5A). This positioning provides for visualization of the video monitor and allows the equipment to be serviced without interfering with the arthroscopist. A Mayo stand is placed distal to the first assistant and should contain the basic or more frequently used equipment necessary to complete the case (Fig. 8-5B). A back table is then positioned within easy reach behind

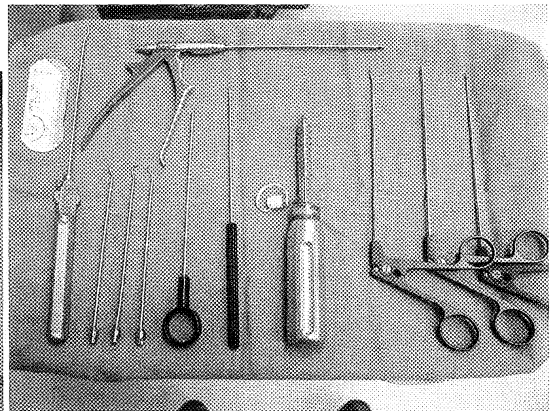
the first assistant; this should contain procedure-specific equipment (Fig. 8-5C).

With the patient in the beach chair position, the surgeon stands slightly behind the shoulder, and the operating table is moved slightly away from the anesthesiologist to give the surgeon more room. The arthroscopy monitor is positioned on the opposite side of the patient at the level of the shoulders for easy viewing by the surgeon. The arthroscopy pump and electrocautery unit are positioned just distal (toward the patient's feet) from the arthroscopy tower. The assistant surgeon stands next to the operating surgeon in front of the patient's shoulder. The assistant's role is to position the arm as required by the specific surgical procedure. Surgical scrub technicians stand behind the surgeon and the assistant.

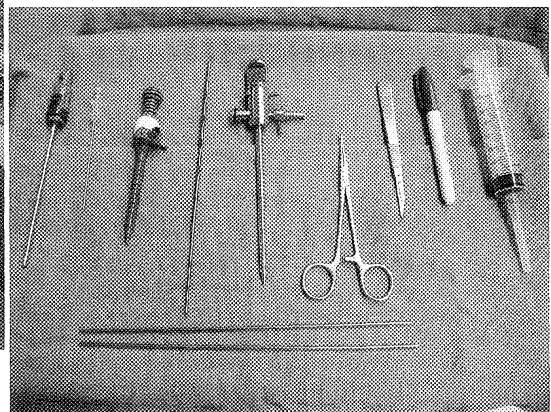
With the patient in the lateral position, the head of the table is turned away from the anesthesiologist. The surgeon stands above the patient's shoulder, and the assistant is below the surgeon. The surgical scrub technician is positioned behind the surgeon. The table can be rotated 180 degrees so that the anesthesiologist is situated at the patient's feet, but the anesthesiologist has



A



B



C

Figure 8-5 A, Arthroscopy tower. B and C, Basic arthroscopic instrumentation.

to be comfortable with this technique. The benefit of this position is that it allows the surgeon complete access to the anterior and posterior aspect of the shoulder by walking around the head of the table.

For diagnostic arthroscopy, a 30-degree arthroscope, cannula, tubing, and probe are the only items needed. For any debridement work, a motorized shaver, bur, and electrocautery or ablation device are used. For reconstructive procedures, the necessary cannulas and fixation devices must be available.

Pumps and Fluid System

Fluid management is critical to shoulder arthroscopy, and understanding fluid dynamics is vital for the performance of advanced arthroscopic procedures. Despite the success of laparoscopy, the fear of pneumomediastinum made isotonic fluid the preferred choice over carbon dioxide.^{3,6,7,11-13} Glycine is another fluid that allows excellent visualization, but it is more expensive than sterile saline. In general, the fluid pressure within the glenohumeral joint is kept close to 30 mmHg; it increases to between 40 and 70 mmHg in the subacromial space, allowing adequate visualization of the anatomy. Maintenance of a mean arterial pressure around 70 to 90 mmHg or a systolic blood pressure of 100 mmHg improves visualization of the shoulder, especially in the subacromial space.¹⁸ Increasing the pressure or flow may cause extravasation of fluid into the soft tissues, distortion of the anatomy, and a gradually decreasing field due to the swollen tissues. Therefore, achieving a balance between fluid pressure or flow and the patient's vital signs is valuable during shoulder arthroscopy.

Fluid management during shoulder arthroscopy is critical for visualization and to minimize postoperative morbidity. There are four basic parameters in fluid management: flow, flow rate, resistance, and pressure. Flow is determined by Poiseuille's law ($\text{flow} = \text{pressure}/\text{resistance}$), leading to fluid inflow during arthroscopy.¹⁶ Flow rate is the amount of fluid that moves past a specific point over a specified period; it is measured in liters per minute and is dependent on inflow (flow of fluid into the joint space) and outflow (flow of fluid out of the joint space). Resistance is based on the diameter of the tube and the diameter of the cannula. Pressure is a measure of force over a certain area; it is measured in millimeters of mercury, and when the inflow equals the outflow, the pressure is stable or in equilibrium. Flow in shoulder arthroscopy is important for keeping the field of view clear, because it flushes blood and debris from the field. It also increases blade-cutting efficiency. Pressure in shoulder arthroscopy distends the joint and helps control bleeding. The two main goals of fluid management systems are to maintain the desired pressure to provide for adequate distention and to control bleeding by means of flow rates to keep the surgical field clear.

Outflow is another critical element in the shoulder arthroscopy system, and it aids in preventing extravasation of fluid into the tissues. Fluid in any system takes the path of least resistance. The subacromial region is a

potential space, and a higher pressure forces fluid out through the point of least resistance. Outflow to gravity allows fluid to exit in this path, decreasing the amount exiting into the tissue. Over time, extravasation into the tissue also has to do with tissue compliance. Younger, more compliant tissues have a tendency to hold more fluid than do older, less compliant tissues.

Two main fluid management systems can be used: a mechanical (motor-driven) pump system in which fluid is "driven" into the joint, and a gravity (passive) system. Peristaltic and centrifugal are the two basic types of mechanical pump systems.

The gravity system works on hydrostatic pressure (1 foot = 22 mmHg). Increasing the height of the bags or decreasing the height of the joint being worked on increases the pressure in the system. The advantages of a gravity system are that it is simple and relatively inexpensive. A potential disadvantage is that when there is a large flow demand, gravity cannot keep up, and the system can "drain the joint."

The peristaltic pump system works by "pinching" inflow tubing as the pump head turns, allowing the introduction of a discrete fluid quantity (individual packets of fluid). This allows for positive fluid displacement by controlling the revolutions per minute of the pump head, thus controlling the amount of pressure and flow. The motor drives rollers that compress the inflow tubing against a race (a metal guard that allows the tubing to be compressed in a uniform fashion). The pump then forces fluid (flow) into the joint, creating a pressure. The inflow tube is a closed system, so the pressure in the tube is the pressure in the joint. However, owing to the momentum of the rollers, there are short peaks and valleys of pressure in a dynamic situation. Flow rate determines how fast the desired pressure is achieved and is measured as a percentage of maximum flow rate. One of the problems with this type of system is that it leads to a pulsing type of action, potentially causing a pressure spike at high flow rates.

The centrifugal pump works on the basis of a rotating impeller in which a continuous volume of fluid is sent. This continuous flow of fluid allows for smoother control of pressure, without any spiking. The problem, however, is that there is a constant fluid flow, so that an uncontrolled or potential space (the subacromial space) may lead to distention of the surrounding soft tissue.

The control of fluid into and out of the joint is critical for shoulder arthroscopy. In basic glenohumeral shoulder arthroscopy, inflow is connected to the camera, and outflow is generally established through the anterior portal. The relationship between inflow and outflow is especially important in the subacromial space, because the area is less confined than the glenohumeral joint, and fluid dynamics greatly affect the surgical field.

Portal Placement and Anatomy

The importance of accurate portal placement cannot be overstated. Because the operative field is limited to the view of a 30- or 70-degree lens, the angle at which this

lens is inserted is critical. This is true for all portals but is especially true for the posterior portal, which is usually the main visualization portal for most procedures.

Accurate tracing of the patient's bony anatomic landmarks is necessary. The anterior and posterior borders of the acromion can be palpated. Marks are then placed at each of these landmarks, and, with the use of an index finger, a line is drawn between them to delineate the lateral border of the acromion. Next, an index finger is placed in the soft spot between the posterior aspect of the distal clavicle and the anterior aspect of the scapular spine. The outline of the clavicle can be drawn from this point, as well as the scapular spine. The acromioclavicular joint is also palpated and drawn, along with the coracoid process, which generally lies 2 to 3 cm inferior to the acromioclavicular joint; these two points mark the level of the glenohumeral articulation. A line marking the path of the coracoacromial ligament is then placed. After all these anatomic areas are palpated and drawn, portal placement can commence.

Posterior Portal

Shoulder arthroscopy begins with the creation of the posterior portal, through which the arthroscope is inserted into the shoulder joint and subacromial space. Depending on the findings observed through this portal, certain accessory portals may be added during the case.

In the beach chair position, the posterior portal is typically placed approximately 2 cm inferior and 1 cm medial to the posterolateral acromion.¹² Although relatively specific coordinates have been reported in the literature, it is important to use all anatomic landmarks as well as various coordinate systems to maintain the ideal position of this portal. The posterior portal is extremely important, as it is the initial viewing portal. This portal "sets the tone" for the rest of the procedure. It is also important to realize that coordinate systems are given for the "normal" shoulder. In extremely small or large shoulders, these coordinates must be modified.

Coordinate systems, bony landmarks, and palpation should all be used to obtain appropriate placement. One method of ensuring correct placement of this portal involves palpation of the bony landmarks with the same hand as the shoulder being operated on. The middle finger is placed on the coracoid process, the index finger is placed into the notch directly posterior to the acromioclavicular joint and anterior to the scapular spine, and the thumb feels for the "soft spot," which is the muscular interval between the infraspinatus and teres minor muscle groups (Fig. 8-6). Another useful method is to grasp the proximal humerus with one hand while stabilizing the scapula with the other and to feel the motion interface at the glenohumeral joint. Once the correct placement has been determined, a mark is made where the posterior portal should go.

The skin is injected with a local anesthetic, and a 1-cm incision is made through the dermis with a number 11 or 15 blade. Depending on the surgeon's preference, a sharp or dull trocar within the cannula for the arthroscopy is used next. If a sharp trocar is used, it is advanced

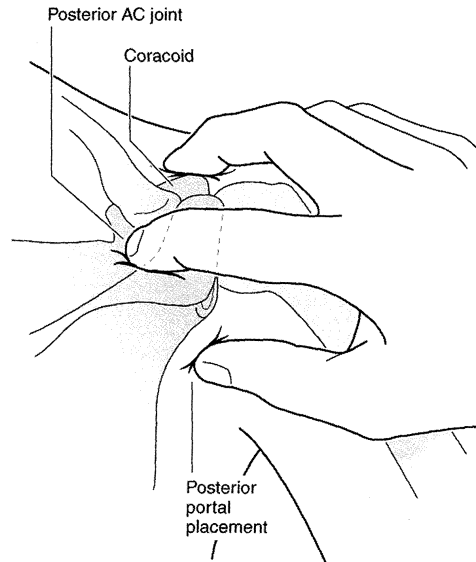


Figure 8-6 Romeo three-finger shuck. This is one method of ensuring the correct placement of the posterior portal. It involves palpation of the bony landmarks with the same hand as the shoulder being operated on. The middle finger is placed on the coracoid process, the index finger is placed into the notch directly posterior to the acromioclavicular (AC) joint and anterior to the scapular spine, and the thumb feels for the "soft spot," which is the muscular interval between the infraspinatus and teres minor muscle groups.

only past the deltoid musculature before being exchanged for a dull trocar. A constant, steady pressure is used to advance the trocar from the posterior skin puncture in line with the tip of the coracoid process, which is being palpated. The amount of resistance encountered at this point varies from shoulder to shoulder. There may be quite a bit of resistance in patients who have adhesive capsulitis or thick posterior capsules, whereas little resistance may be encountered in those with multidirectional instability or thin posterior capsules. If the trocar does not "pop in," it should not be forced, as this may cause injury. To help with insertion, an assistant rotates the arm to localize the joint space by means of the surgeon's palpation of the moving humeral head contrasted with the stationary glenoid. Another method involves having the assistant grab the arm just distal to the axilla, creating an abduction distraction force. This, in essence, creates slightly more glenohumeral space, allowing the trocar to be easily slipped into the joint. Ideally, the cannula is introduced into the shoulder joint at the midequator of the glenoid to provide ideal visualization of the intra-articular structures at the top and bottom of the joint. An upward motion should be used at this time to avoid iatrogenic injury to the articular cartilage of the posterior humeral head. Any bony resistance encountered during insertion should be considered either the posterior aspect of the humeral head or the posterior glenoid. If bony resistance

is experienced, it is safer to take a moment to reassess the anatomic landmarks and then reapply steady pressure at a slightly different angle rather than to attempt forceful insertion and risk possible iatrogenic cartilage injury.

Creation of the posterior portal in the lateral decubitus position is slightly different. There is a natural tendency to enter the joint medially, but this would force the arthroscopist to come over and around the glenoid to view the joint, which could be problematic with some procedures. In general, the portal should be placed slightly more lateral and proximal than the beach chair posterior portal. It is recommended that the portal be placed 3 cm inferior and in line with the posterolateral corner of the acromion (Fig. 8-7).

Distention of the glenohumeral joint with fluid before entering it may have some advantages. The humeral head and glenoid are separated by the fluid, leaving a wider glenohumeral space and allowing the medial trocar to be inserted with less risk of iatrogenic injury. Filling the joint with fluid also puts the posterior capsule in tension and makes entering the joint easier. A theoretic limitation of this technique is the potential for injury to the humeral head during spinal needle placement.

For diagnostic glenohumeral arthroscopy, the entrance for the posterior portal is the same skin incision that can be used for posterior entry into the subacromial space. There are many ways to enter the subacromial space; however, the primary factor is visualization. The technique described here is based on establishing a "room with a view."

After complete glenohumeral arthroscopy, the posterior portal cannula and trocar are withdrawn through

the interval between the infraspinatus and teres minor muscles. The trocar is withdrawn in such a way that no rotator cuff musculature is brought in when entering the subacromial space. The trocar and cannula are angled more superiorly than with glenohumeral arthroscopy, and the posterior border of the acromion is palpated with the trocar. The trocar is then placed underneath the acromion and inserted in an anterior direction. Palpation of the anterior joint with the opposite hand aids in understanding how large the acromion is in relation to the length of the cannula. Both these factors give the surgeon feedback about how far the trocar has been advanced into the space. The subacromial bursa is an anterior structure (Fig. 8-8). After initially aiming anteromedially, the trocar is placed as lateral as possible (Fig. 8-9A). The trocar is removed, and the arthroscope is inserted. When fluid is allowed to distend this potential space, a "room with a view" should be seen (Fig. 8-9B). If soft tissue obscures the view, the surgeon must withdraw and reposition the arthroscope. There is a tendency to be either too medial or too anterior. If this is the case, the anatomic references should be reassessed, and the procedure should be repeated. The posterior portal must be low enough to allow a smooth transition into and out of the subacromial space. If the posterior portal is too close to the scapular spine, a shaver placed through this portal will have to be aimed inferiorly to get under the acromion before it can be aimed superiorly to perform the anterior acromioplasty. Also, if an arthroscopic distal clavicle excision is part of the planned procedure, the posterior portal can be made slightly medial so that the angle of attack is more in line with the acromioclavicular joint.

Alternatively, the anterior portal can be used by passing the arthroscope and trocar through the posterior portal and out the anterior aspect of the shoulder. A plastic outflow cannula is placed over and withdrawn to the center of the subacromial space. Following reinsertion of the camera into its sheath, a spinal needle can be used for triangulation to establish the standard lateral working portal (described later).

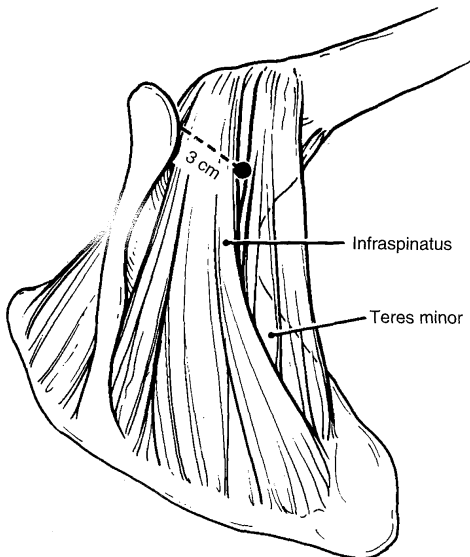


Figure 8-7 Posterior portal placement through the infraspinatus and teres minor interval in the lateral decubitus position.

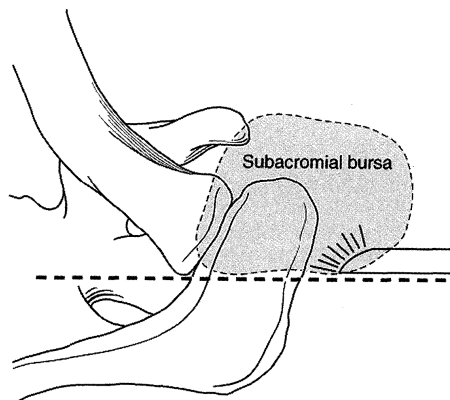


Figure 8-8 Subacromial bursa.

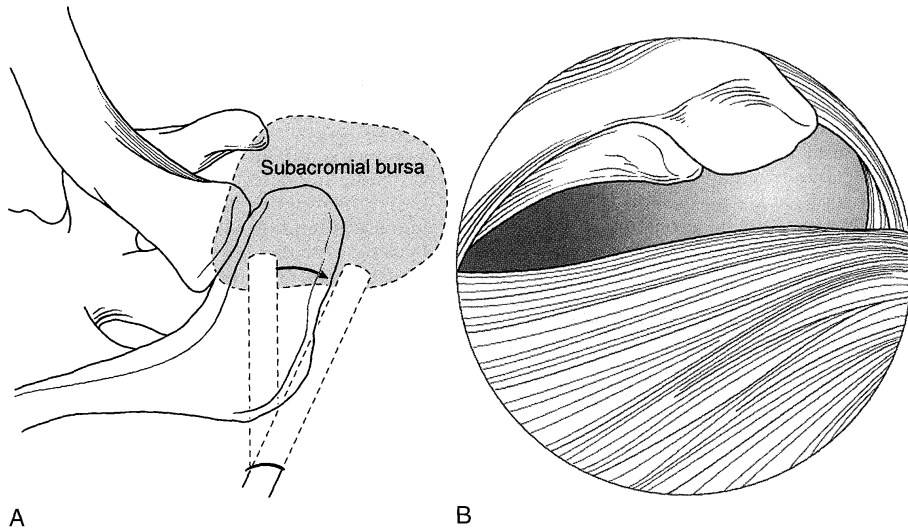


Figure 8-9 A, Initial angulation of the trocar medially to enter the subacromial bursa, followed by manipulation of the trocar laterally. B, “Room with a view”—the arthroscopic view inside the subacromial bursa.

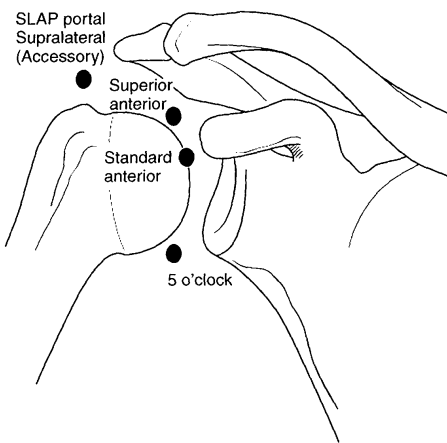


Figure 8-10 Anterior portals. SLAP, superior labral anterior to posterior.

Anterior Portal

The standard anterior portal (Fig. 8-10) is generally placed in the rotator interval or triangle created by the subscapularis tendon, the humeral head, and the biceps tendon superiorly. It is important to assess the competence of the superior glenohumeral and coracohumeral ligaments and the stability of the long head of the biceps tendon before creating this portal. The coracohumeral ligament, along with the superior glenohumeral ligament, forms the medial sling of the biceps, thereby creating medial stability for the long head of the biceps tendon. The supraspinatus creates a bumper, or sling, for

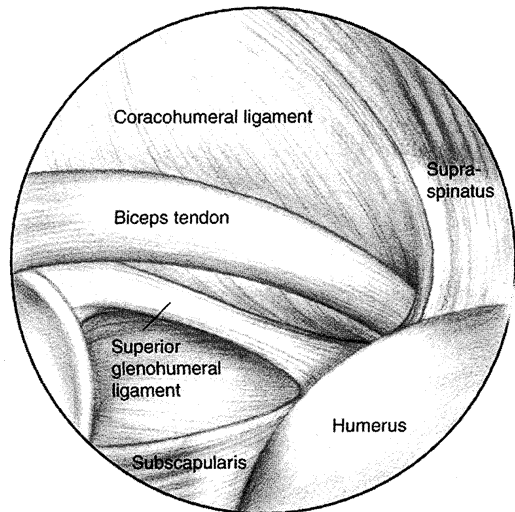


Figure 8-11 Arthroscopic view of the biceps sling anatomy of a right shoulder with the arthroscope in the posterior portal.

the biceps on its lateral side (Fig. 8-11). Creation of the anterior portal can be done with an inside-out or outside-in technique. The inside-out technique involves “driving” the arthroscope into the anterior triangle and placing it with some force into that area so that it does not move. The arthroscope is then removed, and a stout Wissinger rod is placed through the cannula. The rod is then forcefully pushed through the interval tissue, tensing the skin anteriorly. This tented skin should be directly lateral to

the tip of the coracoid process. If it is medial, the rod should immediately be withdrawn and the anatomic structures reassessed. The musculocutaneous nerve exits 1 cm medial and 3 cm distal to the coracoid process. A scalpel (number 11 blade) is used to create a 1-cm incision, and the Wissinger rod is pushed through this incision. A plastic cannula can then be placed over the rod. The arthroscope is advanced into the space, and the position is checked visually (Fig. 8-12).

The outside-in technique uses direct visualization. A spinal needle is placed from the lateral aspect of the coracoid process through the rotator interval (Fig. 8-13). The spinal needle is then removed, and a number 11 blade is used to make the 1-cm skin incision. Under direct visualization, the plastic cannula and plastic trocar

are advanced through this tissue bounded by the long head of the biceps tendon superiorly, humeral head laterally, and subscapularis inferiorly. Care should be taken not to place the portal through the subscapularis tendon. Depending on the pump system being used and the fluid dynamics, the outflow can be changed from the posterior portal to this anterior portal to improve visualization of the shoulder joint.

When creating the anterior portal with the patient in the lateral decubitus position, the tendency is to make the anterior portal too medial, so an effort must be made to ensure that the portal is lateral enough. When establishing the portal, if it is difficult to determine the correct site for needle insertion, the anterior aspect of the shoulder can be palpated while viewing through the arthroscope to observe capsular indentation due to the palpating finger.

In a diagnostic arthroscopic procedure, the anterior portal can be placed anywhere in the rotator cuff interval. If, according to the preoperative plan, various procedures are going to be performed, special attention should be paid to where the initial anterior portal goes. For arthroscopic distal clavicle excision, placing the anterior portal slightly medial is useful to gain access to the acromioclavicular joint. For arthroscopic labral stabilization, the anterior portal may be put slightly higher than usual because a second anterior portal will be needed. It is important to realize that with two anterior portals, crowding can occur. Increasing the distance between these portals helps with triangulation and decreases congestion.

If the selected procedure requires two anterior portals, both can be placed into the rotator interval. The anterosuperior portal is close to the acromion, even with the acromioclavicular joint, and the standard antero-inferior portal is adjacent to the coracoid (Fig. 8-14).

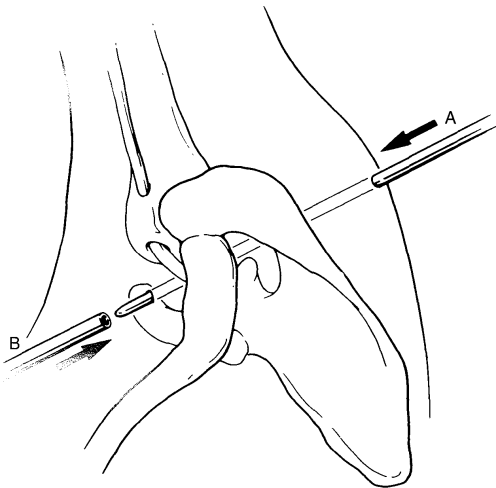


Figure 8-12 Rod being directed anteriorly through the skin (A). Retrograde placement of an arthroscopic cannula into the joint over a Wissinger rod (B).

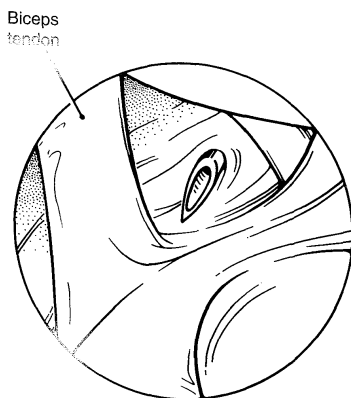


Figure 8-13 Intra-articular view of a spinal needle entering the anterior capsule at the proper site for the anterior portal.

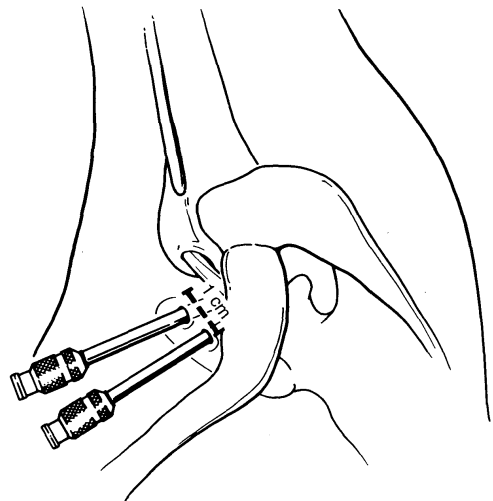


Figure 8-14 Placement of two anterior portals with a 1-cm skin bridge between them.

Standard Lateral Portal

The standard lateral portal (Fig. 8–15) is strictly a subacromial space portal. This exclusive role is due to the fact that the supraspinatus and infraspinatus tendons, depending on internal and external rotation, protect the glenohumeral joint from access by this portal. The axillary nerve anatomy is an important consideration when establishing the direct lateral portal. Many descriptions of the axillary nerve in relation to the lateral edge of the acromion have been provided. Hollinsehead⁹ determined that the position of the axillary nerve was 1.5 to 2 inches (3.8 to 5.1 cm) below the acromion. Hoppenfeld and deBoer¹⁰ reported that the axillary nerve was 7 cm from the acromion. Beals et al.² found that the mean distances from all points of the acromion to the axillary nerve averaged approximately 5 cm.

To localize this portal, an index finger is placed in the notch between the posterior aspect of the clavicle and the spine of the scapula, and a line is drawn from this notch laterally past the lateral edge of the acromion for approximately 2 cm. This places the line in the midportion of the acromion. A spinal needle is used to localize this portal under direct visualization. The needle is placed in position, and once it is manipulated so that all areas of the subacromial space can be accessed with it, a 1-cm incision is made either vertically or horizontally, depending on the surgeon's preference. A dull trocar is used to enter the subacromial space first, and the position is checked again. If this portal is placed too close to the acromion, as the shoulder swells, introducing instruments will become more difficult as they are forced in a caudad direction. This misplacement also raises the relative position of the portal, making contact with the medial acromion difficult. These factors should always be considered when making this portal.

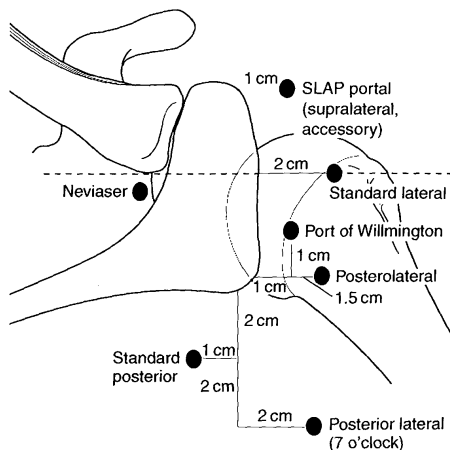


Figure 8–15 Posterior and lateral portals.

Accessory Anterior Portals

To aid in performing the multitude of arthroscopic shoulder procedures, various portals have been described (see Fig. 8–10). As already stated, correct placement of portals is critical to the success of the procedure. A spinal needle can be used in the glenohumeral joint to localize and ascertain the correct angle and position of the proposed portal site. One can then create a portal site that is specific to both the patient's anatomy and the proposed procedure. When creating accessory portals, knowledge of the neurovascular anatomy is important. The musculocutaneous nerve exits 2 cm inferior and 1 cm medial to the coracoid process (Fig. 8–16). The cephalic vein is found in the deltopectoral interval, and the anterior humeral circumflex vessel travels along the inferior border of the subscapularis tendon to send branches into the biceps sheath and humeral head. Beals et al.² reported that the axillary nerve is, on average, 5 cm from the acromion. This can be thought of as a "safe zone" for the application of accessory portals.

Superolateral Portal

The superolateral portal (see Fig. 8–10) has been defined by Laurencin et al.¹⁵ It is placed at a position just lateral to the acromion on a line drawn from the acromion to the coracoid. A spinal needle is placed to enter the subacromial space or joint obliquely. This portal is useful for anterior shoulder procedures, but it is especially important in arthroscopic rotator cuff repair for anchor placement and suture shuttling (Fig. 8–17).

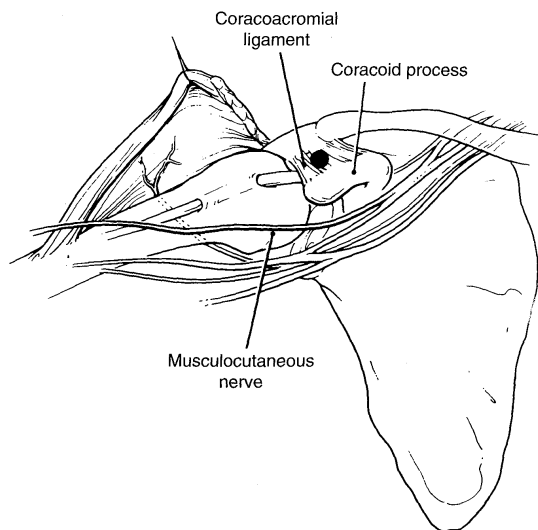


Figure 8–16 Anterior portal placement in relation to the coracoid process and musculocutaneous nerve.

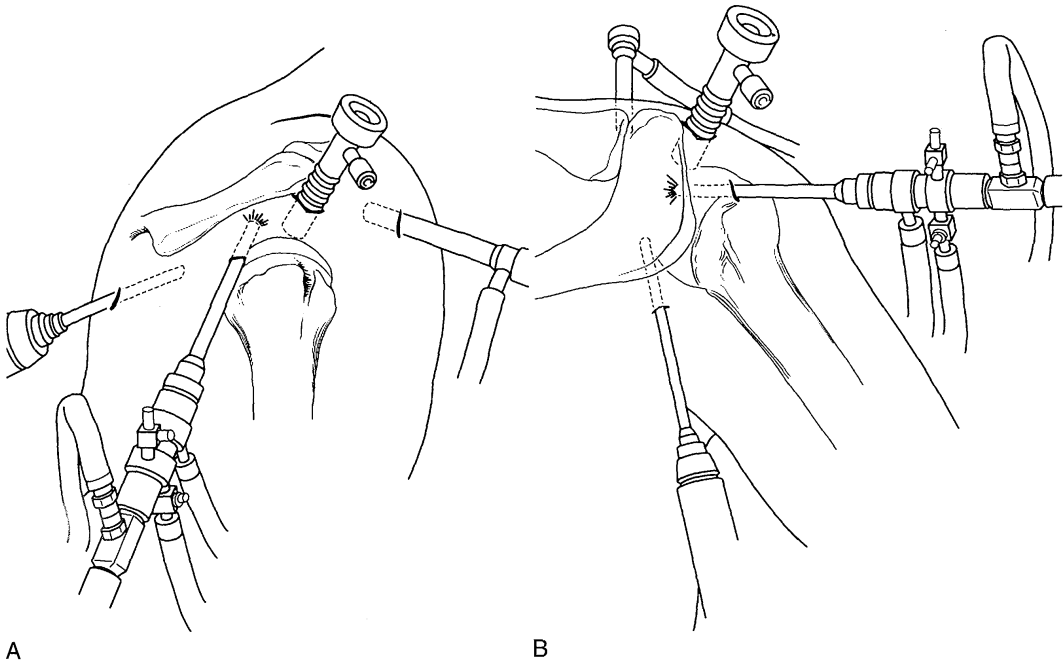


Figure 8-17 Lateral (A) and posterior (B) views of an accessory superolateral portal.

Neviaser Portal

This portal (see Fig. 8-15) is placed in the notch between the posterior acromioclavicular joint and the spine of the scapula. It is useful for the repair of anterior supraspinatus rotator cuff injuries, as well as for arthroscopic distal clavicle resection (Fig. 8-18). The suprascapular nerve and artery traverse the floor of the supraspinatus fossa, approximately 3 cm medial to the portal.

Anteroinferior, or 5 O'clock, Portal

This portal is especially useful for glenohumeral reconstructive procedures such as arthroscopic labral stabilization. Davidson and Tibone⁵ described the anteroinferior 5 o'clock portal for shoulder arthroscopy (see Fig. 8-10). This provides direct linear access to the glenoid rim at the critical anteroinferior site of Bankart capsulolabral detachment. This portal passes lateral to the musculocutaneous nerve and superolateral to the axillary nerve. The mean portal-to-nerve distance for the musculocutaneous nerve is 22.9 mm, and for the axillary nerve it is 24.4 mm.⁹ This portal passes within 10 mm of the deltopectoral groove, slightly lateral to the conjoint tendon in the lower third of the subscapularis muscle. The portal can be placed from the inside out or outside in. With an inside-out technique, the humerus is maximally adducted, the upper third of the subscapularis is pierced, and a Wissinger rod is passed through the capsule with the exiting tip directed as far laterally as possible. A plastic cannula is then placed over the rod anteriorly to provide access to the 5 o'clock position.

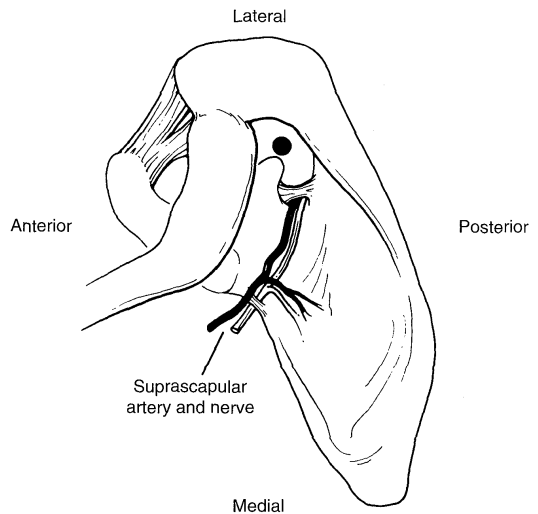


Figure 8-18 Neviaser portal in relation to the suprascapular nerve and artery, acromion, clavicle, and spine of the scapula.

Anterolateral Portal

This is a useful portal for placing anchors to repair anteriorly located superior labral tears. It is placed 1 cm lateral to the anterior acromion. Accessing the glenohumeral joint from this position violates the supraspinatus tendon. Recent advances in anchor placement have

allowed smaller incisions to be made. Anchor cannulas are smaller than the standard arthroscopic cannulas. Small incisions in the supraspinatus tendon have not been reported to cause difficulties; however, damage to the rotator cuff tendon should be minimized (see Fig. 8–15).

Accessory Posterior Portals

The anterior portals do not provide a satisfactory angle of approach for the placement of suture anchors in the posterior aspect of the superior or inferior labrum.

Portal of Wilmington

This portal is used for labral repair in the posterosuperior quadrant of the glenoid.¹⁷ The skin incision is made 1 cm lateral and 1 cm anterior to the posterolateral corner of the acromion, and the portal is made with a 45-degree angle of attack. No cannula is placed in this portal site, to avoid iatrogenic injury to the infraspinatus tendon. For this reason, once the spinal needle is localized to the correct trajectory, the labral fixation device is placed percutaneously under direct visualization (see Fig. 8–15).

Posterolateral, or 7 O'clock, Portal

Placement of plication sutures or anchors into the posteroinferior glenoid is difficult through standard portals. This necessitates the use of an accessory posterior portal. Morrison et al.¹⁸ described a portal that is placed 2 cm inferior to the standard posterior portal at approximately the 7 o'clock position (Fig. 8–19). This facilitates easy access to the axillary pouch by entering the joint below the equator of the glenoid. The average distance

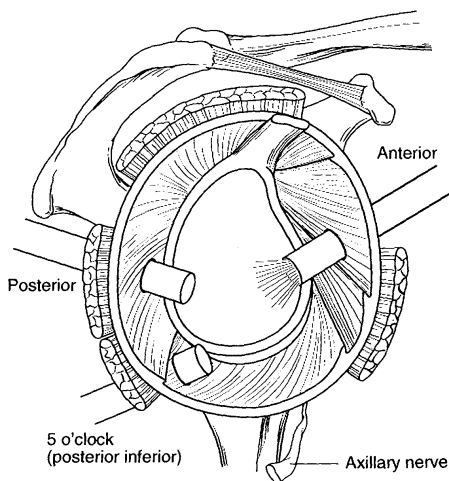


Figure 8–19 Posterolateral (7 o'clock) portal.

between the accessory posterior portal and the axillary nerve is 3.7 cm. The distance to the suprascapular nerve is 2.88 cm. Another accessory posterolateral portal has been described. The incision for this posterolateral portal is placed 1.5 cm lateral to the acromion at its posterior third. The reported average distance between the posterolateral portal and the axillary nerve is 14.4 to 24.1 mm. Although these coordinates are helpful, a spinal needle for localization of the portal is essential (see Fig. 8–15).

Once multiple portals have been established, care must be taken not to widen the portal openings excessively. Cannulas can help keep portals a standard size. If portal distention occurs, this can lead to extravasation of fluid into the soft tissues. Switching sticks or rods can be used to move the arthroscope from one portal to another while maintaining the same portal configuration (Figs. 8–20 and 8–21).

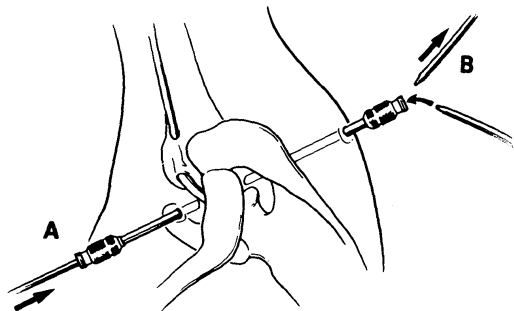


Figure 8–20 Use of switching sticks (A and B) to interchange working portals.

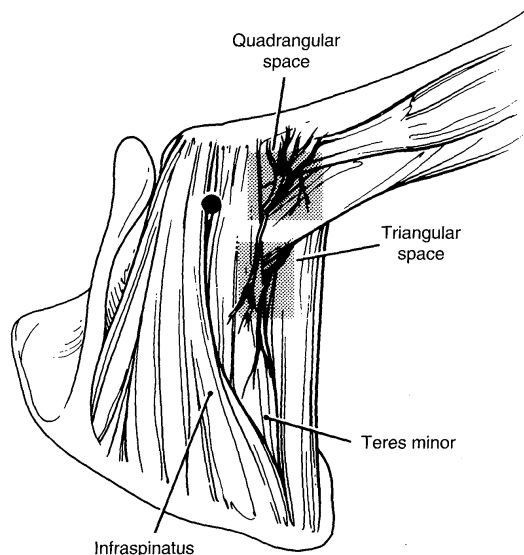


Figure 8–21 View of the posterior portal in relation to the infraspinatus, teres minor, quadrangular space, and triangular space.

Conclusion

Shoulder arthroscopy is an excellent method for treating various pathologies. Attention to detail during patient positioning, portal placement, and fluid management will enhance the success of all arthroscopic procedures of the shoulder.

References

1. Altchek DW, Warren RE, Skyhar MJ, Ortiz G: T-plasty modification of the Bankart procedure for multi-directional instability anterior and inferior types. *J Bone Joint Surg Am* 73:105-112, 1991.
2. Beals TC, Harryman DT, Lazarus MD: Useful boundary of the subacromial bursa. *Arthroscopy* 14:465-470, 1998.
3. Bert JM, Posalaky Z, Snyder S, et al: Effect of various irrigating fluids on the ultrastructure of articular cartilage. *Arthroscopy* 6:104-111, 1990.
4. Burstein MS: Arthroscopy or direct visualization of joints: Experimental cadaver study. *J Bone Joint Surg* 13:669-695, 1931.
5. Davidson PA, Tibone JE: Anterior inferior (5 o'clock) portal for shoulder arthroscopy. *Arthroscopy* 11:519-525, 1995.
6. Gradinger R, Träger J, Klausner RJ: Influence of various irrigation fluids on articular cartilage. *Arthroscopy* 11:263-269, 1995.
7. Hamada S, Hamada M, Nishiue S, Doi T: Osteochondritis dissecans of the humeral head [case report]. *Arthroscopy* 8:132-137, 1992.
8. Hennrikus WL, Mapes RC, Bratton MW, et al: Lateral traction during shoulder arthroscopy: Its effect on tissue perfusion measured by pulse oximetry. *Am J Sports Med* 23:444-446, 1995.
9. Hollinshead WH: *Anatomy for Surgeons*, vol 3, 2nd ed. Philadelphia, Harper & Row, 1969, p 316.
10. Hoppenfeld S, deBoer P: *Surgical exposures*. In *Orthopaedics*, 2nd ed. Philadelphia, JB Lippincott, 1994, pp 25-29.
11. Jobe FW, Giangarra CE, Kvitne RS, Glousman RE: Anterior capsulolabral reconstruction of the shoulder in athletes in overhand sports. *Am J Sports Med* 19:428-434, 1991.
12. Johnson LL: *Arthroscopic Surgery: Principles and Practice*, 3rd ed. St Louis, CV Mosby, 1986.
13. Johnson LL, Schneider DA, Austin MD, et al: Two-percent glutaraldehyde: A disinfectant in arthroscopy and arthroscopic surgery. *J Bone Joint Surg Am* 64:237-239, 1982.
14. Klein AH, France JC, Mutschler TA, et al: Measurement of brachial plexus strain in arthroscopy of the shoulder. *Arthroscopy* 3:45-52, 1987.
15. Laurencin CT, Detsch A, O'Brien SJ, Altchek DW: The superior lateral portal for arthroscopy of the shoulder. *Arthroscopy* 10:255-258, 1994.
16. Morgan C: Fluid delivery systems for arthroscopy. *Arthroscopy* 3:288-291, 1987.
17. Morgan CD, Burkhart SS, Palmeri M, Gillespie M: Type II SLAP lesions: Three subtypes and their relationships to superior instability and rotator cuff tear. *Arthroscopy* 14:553-555, 1998.
18. Morrison DS, Schaefer RK, Friedman RL: The relationship between subacromial space pressure, blood pressure, and visual clarity during arthroscopic subacromial decompression. *Arthroscopy* 11:557-560, 1995.