

# Arthroscopic Treatment of Anterior Glenohumeral Instability: Indications and Techniques

Brian J. Cole, MD, MBA  
 Peter J. Millett, MD, MSc  
 Anthony A. Romeo, MD  
 Stephen S. Burkhart, MD  
 James R. Andrews, MD  
 Jeffrey R. Dugas, MD  
 Jon J.P. Warner, MD

## Abstract

*The arthroscopic treatment of anteriorglenohumeral instability is becoming increasingly accepted as a viable treatment option because reported success rates parallel those of open stabilization techniques. This improved success rate is largely the result of advances in surgical techniques and technology. An improved understanding of the pathoanatomy associated with shoulder instability and continuing education initiatives have also been instrumental in expanding the indications for arthroscopic stabilization of the unstable shoulder. Important considerations during arthroscopy include identifying all pathology, mobilizing soft tissue, enhancing the local biology to promote soft-tissue healing to bone or to itself, securing anatomic fixation, and respecting the healing period during postoperative rehabilitation efforts. Principal contra indications include significant bone deficits and the inability to repair capsular avulsions or rupture. Adherence to these basic principles should lead to excellent results with arthroscopic stabilization of the unstable shoulder.*

Arthroscopy is becoming increasingly accepted as a viable treatment option for anterior glenohumeral instability. Despite early reports of vari-

able recurrence rates, arthroscopic techniques have now evolved significantly largely as a result of improved understanding of the associated pathoanatomy, improved patient selection, simplified techniques, and advanced technology. The major advantages of arthroscopic repair over traditional open repair include the ability to identify and treat concomitant pathology, lower morbidity and

decreased pain, shorter surgical time, and improved cosmesis. Some surgeons believe that patients who undergo arthroscopic repair of anterior glenohumeral instability have an easier functional recovery with greater returns in motion compared with patients undergoing traditional open repair. Finally, some of the inherent risks of open repair procedures, such as postoperative subscapularis rupture, are virtually eliminated.

## Anatomy of Shoulder Stability

Although the diverse stabilizing structures of the glenohumeral joint have been previously described in detail elsewhere,<sup>1</sup> a brief review here will provide a foundation for the discussion to follow. Because the large spherical head of the humerus articulates with the relatively small and shallow glenoid, the glenohumeral joint requires several mechanisms that maintain stability and allow for a large range of motion. Static and dynamic stability are provided by the

*One or more of the authors or the departments with which they are affiliated have received something of value from a commercial or other party related directly or indirectly to the subject of this chapter.*

combined effects of the capsuloligamentous structures, the rotator cuff, the scapular stabilizers, and the biceps muscle. In the midrange of motion, the principal stabilizers are the rotator cuff and biceps tendons, which dynamically stabilize the humeral head through concavity-compression within the glenoid socket. The ligamentous structures function at the extremes of rotation, preventing excessive rotation and translation.

The labrum increases the depth and surface area of the bony glenoid. Its principal function is to increase the depth of the glenoid socket and to act as a "chock block" to prevent the head from rolling over the anterior edge of the glenoid. It consists of a fibrocartilaginous ring that attaches to the glenoid articular cartilage.<sup>2</sup> Above the glenoid equator, the labrum is relatively mobile; below the glenoid equator, the labrum is more tightly attached to the glenoid articular cartilage. The labrum also provides an attachment site for the glenohumeral ligaments and the tendon of the long head of the biceps. Virtually all labral lesions, especially those below the glenoid equator, are thought to be associated with glenohumeral instability.

The role of the capsule and ligaments in shoulder stability is complex and depends on the position of the joint and the direction of the applied force. The inferior glenohumeral ligament complex is the primary static check against anterior, posterior, and inferior translation between 45° and 90° of glenohumeral elevation. The superior and middle glenohumeral ligaments limit anteroposterior and inferior translation in the middle and lower ranges of elevation as the arm approaches the adducted position.

The rotator interval region be

tween the supraspinatus and subscapularis tendons provides stability against inferior and posterior translations, particularly when the arm is adducted and externally rotated. Evidence suggests that this may be a normal variant present at birth and is only a relative contributor to instability in the symptomatic patient with excessive inferior or posterior translation that is not eliminated despite correction of other existing pathology.

The rotator cuff and long head of the biceps brachii enhance stability by increasing compression across the glenohumeral joint, thereby increasing the loads required to translate the humeral head. This is particularly apparent in the midranges of motion where the capsuloligamentous structures are more lax. The scapulothoracic stabilizers help to position the glenoid beneath the humeral head. Dysfunction in any of these stabilizers can lead to symptoms of instability. Proprioceptive mechanisms help to coordinate and time this system and are restored after instability surgery.

The articular surfaces also play a key role in stability. Articular version, negative intra-articular pressure, and adhesion-cohesion all enhance shoulder stability. In general, each of these factors plays a relatively small role in the pathogenesis of shoulder instability, although bone loss, particularly on the glenoid, can be significant enough to warrant surgical correction and remains the principal contraindication to arthroscopic shoulder stabilization.

### Pathoanatomy

#### *Labrum*

Disruption between the anterior labrum and the glenoid below the equator is termed a Bankart lesion. Because the inferior glenohumeral

ligament complex is the major static stabilizer when the shoulder is positioned in abduction and external rotation, a capsulolabral separation in this area effectively destabilizes the glenohumeral joint. Furthermore, the normal stabilizing effect of the rotator cuff compressing the humeral head into the glenoid socket is diminished when the labrum is separated from the glenoid rim. The Bankart lesion, which is considered the essential pathoanatomic lesion, is present in about 90% of all traumatic anterior shoulder dislocations. Because of its essential stabilizing functions, the labrum must be anatomically restored in patients with instability.

In some patients, the labrum heals in a medialized position (anterior labrum periosteal sleeve avulsion lesion).<sup>1</sup> When this occurs, the labroligamentous complex must be mobilized surgically and released from the glenoid and underlying subscapularis so that it can be reattached at its correct anatomic insertion. When the labrum is repaired to the glenoid, the suture anchors should be placed 1 to 2 mm onto the "face" of the glenoid to restore the concavity and to ensure that the labrum can perform its essential biomechanical functions.<sup>6</sup> Currently, the use of multiple anchors (ie, three to four) with multiple sutures providing multiple fixation points is preferred. It is also important that the anchors are placed at least down to the 5 o'clock position. This sometimes necessitates a "5 o'clock portal" to give a proper angle of approach for insertion of the anchors.<sup>1</sup> At the conclusion of the repair, the glenoid concavity should be visibly extended and a buttress or "bumper" effect should be achieved, as is present in the uninjured shoulder.

Above the glenoid equator, labral

anatomy may be quite variable, and a loose attachment below the biceps tendon may be a normal variant (ie, a sublabral foramen). Injuries to the superior labrum with associated destabilization of the biceps insertion may occur with shoulder instability. Both experimental and clinical studies have provided a rationale for arthroscopic repair of these superior labral injuries when treating instability."<sup>1</sup> The variations in superior labral anatomy may pose challenges in determining whether a patient's anatomy is a variant of normal or an abnormal labral detachment. In general, a loosely attached superior labrum with a smooth cartilage transition is a variant of normal and not a labral separation. True labral injury is associated with failure of the origin fibers of the superior labrum, cartilage injury at the margin of the labral attachment, synovitis, and/or extension of the tear into the biceps tendon itself. In the setting of shoulder instability, such tears of the superior labrum should always be repaired.

### **Ligaments**

In addition to the Bankart lesion, recurrent dislocations can also cause stretching of the glenohumeral capsule and ligaments. This plastic deformation occurs from repetitive loading. Although identification of this stretch injury or laxity of the ligaments may be difficult, failure to address this component of the instability when performing an arthroscopic repair may contribute to failure of the procedure. Indeed, in some series, higher failure rates have been attributed to this error. If the middle or inferior glenohumeral ligament complex is stretched, then the joint volume will be increased, and the joint will be susceptible to instability on that basis even with an intact labrum."<sup>10</sup>

Actual macroscopic midsubstance failure of the capsule or failure at the humeral insertion (humeral avulsion of glenohumeral ligament) is uncommon but appears to constitute a relative contraindication to arthroscopic repair because of the technical difficulty associated with repairing such an injury. Although it is technically possible to repair this condition arthroscopically, direct repair with capsule repair and reinsertion appears to be more reliable through an open approach.

Insufficiency of the rotator interval may be responsible for failures in some series. This interval is usually involved if there is a large inferior component to the instability, particularly when the arm is in adduction and external rotation." Rowe and Sakellarides<sup>2</sup> originally pointed out that the capsule may be absent or deficient in this area, and these authors and others recommended closure at the time of open instability repairs." The defect may represent either an injury or, more likely, a relative dysplasia of the ligaments of this region. When the defect is recognized arthroscopically, repair by overlapping the capsular region between the anterior edge of the supraspinatus and proximal edge of the subscapularis is the preferred method.

### **Rotator Cuff**

When the rotator cuff is injured, its concavity-compression effect is diminished. Rotator cuff injury in younger patients usually occurs in the setting of repetitive overload. In such patients, the tear results from eccentric overload of the tendon and represents a secondary injury to the tendon from the recurrent instability. Full-thickness tears of the rotator cuff after a traumatic dislocation are uncommon in patients younger than 40 years but should be suspected in

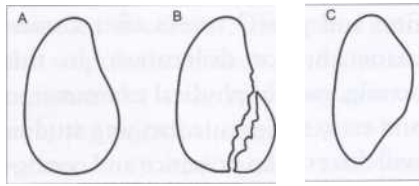
those who continue to have weakness and pain 3 weeks after a traumatic anterior dislocation. In this setting, careful physical examination and early soft-tissue imaging studies will discern the presence and configuration of the rotator cuff tear. Generally, tears of the superior cuff can be repaired arthroscopically at the same time as the instability. Significant tears of the subscapularis can also be repaired arthroscopically, although this does require considerable technical skill, and a traditional open repair is certainly an acceptable option.

### **Bone**

Bone deficiency is a significant cause for the failure of arthroscopic Bankart repairs. Burkhart and De Beer<sup>3</sup> reported on a group of 194 patients who had undergone arthroscopic Bankart repair of the shoulder. One hundred one of these patients were contact athletes. These authors found that when the patients had no significant bone defects (173 patients), the recurrence rate was 4%. However, when patients had significant bone defects (21 patients), the recurrence rate was 67%. Contact athletes with significant bone defects had an 87% recurrence rate, whereas contact athletes without bone defects had a 6.5% recurrence rate.

Three types of bone lesions are found in patients with anterior instability: (1) glenoid erosion (also known as inverted pear glenoid morphology) (Figure 1); (2) the engaging Hill-Sachs lesion (Figure 2); and (3) the nonengaging Hill-Sachs lesion" (Figure 3).

**Glenoid Erosion** The normal glenoid is broader inferiorly than superiorly (pear-shaped). Because the glenoid resists both axial and off-axis loads, significant bone loss results in a shorter arc through which the gle



**Figure 1** The normal glenoid and the inverted-pear glenoid morphology. A, The normal shape of the glenoid is that of a pear, larger inferiorly than superior. B, An acute bony Bankart fracture can create an "inverted pear" configuration. C, Erosion of the anterior glenoid can also create this configuration.

noid can resist these loads. Furthermore, the glenoid resists shear by rim loading. If part of the rim is lost (as the result of a labral tear, fracture, or erosion, for example), then it cannot effectively resist shear. When a large bony Bankart lesion is present or when glenoid erosion occurs from multiple dislocations, the glenoid loses its normal anatomic configuration and assumes the shape of an inverted pear (Figure 1). Anatomic studies have shown that the inverted pear morphology always involves more than a 25% loss in diameter.<sup>13,14</sup>

Burkhart and associates<sup>14</sup> have also shown that the glenoid bare spot is the center of a circle defined by the margins of the anterior, posterior, and inferior glenoids, and therefore it is useful as a reference to gauge how much bone has been lost, particularly in a patient with erosive bone loss from chronic recurrent anterior dislocations. The bare spot is visible in virtually all patients and is best viewed through an anterosuperior viewing portal. Significant bone loss, with greater than a 25% loss of the inferior diameter of the glenoid, is a contraindication for arthroscopic repair because of an unacceptably high recurrence rate among such patients, particularly active individuals and contact athletes. In such cases, an open ap-

proach with bone grafting of the anteroinferior glenoid is preferred. Alternatively, coracoid transfer procedures offer acceptable treatment options.

**Hill-Sachs Lesion** When the glenohumeral joint dislocates, the Hill-Sachs defect can occur at a variety of angles as determined by the position of the humerus at the time of dislocation. Some Hill-Sachs lesions will "engage" the anterior glenoid rim when the glenohumeral joint is in a position of abduction and external rotation. Burkhart and De Beer<sup>13</sup> have described these as engaging Hill-Sachs lesions, in which the long axis of the humeral bone defects aligns parallel to the anterior glenoid rim when the shoulder is in a position of abduction and external rotation. Such fracture configurations have been found to be particularly prone to recurrent dislocation and subluxation after arthroscopic repair (Figure 2).

With the nonengaging Hill-Sachs lesion, the long axis of the Hill-Sachs defect diagonally crosses glenoid rim with the arm in abduction and external rotation so that it never "engages" the glenoid rim (Figure 3). In these types of defects, there is a continuous smooth articular contact throughout the range of motion. Such shoulders with nonengaging Hill-Sachs lesions are not at significant risk for recurrence when repaired arthroscopically, and therefore patients with these types of humeral lesions are good candidates for arthroscopic repair.

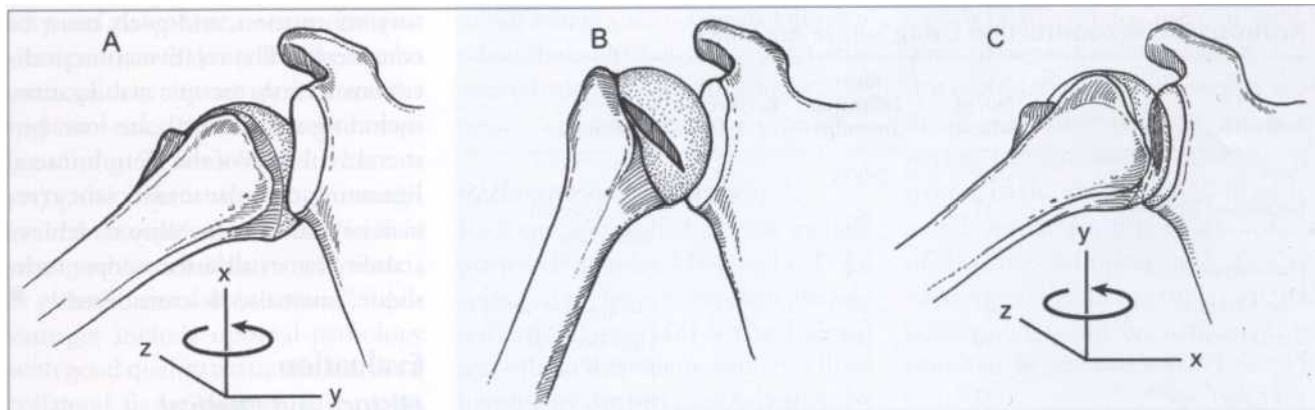
### Evolution of Arthroscopic Repairs

The failure rate after open repair is generally less than 10%; this is benchmark against which arthroscopic repairs must be compared.<sup>15-17</sup> Historically, the literature has classified failures of instability repair as those

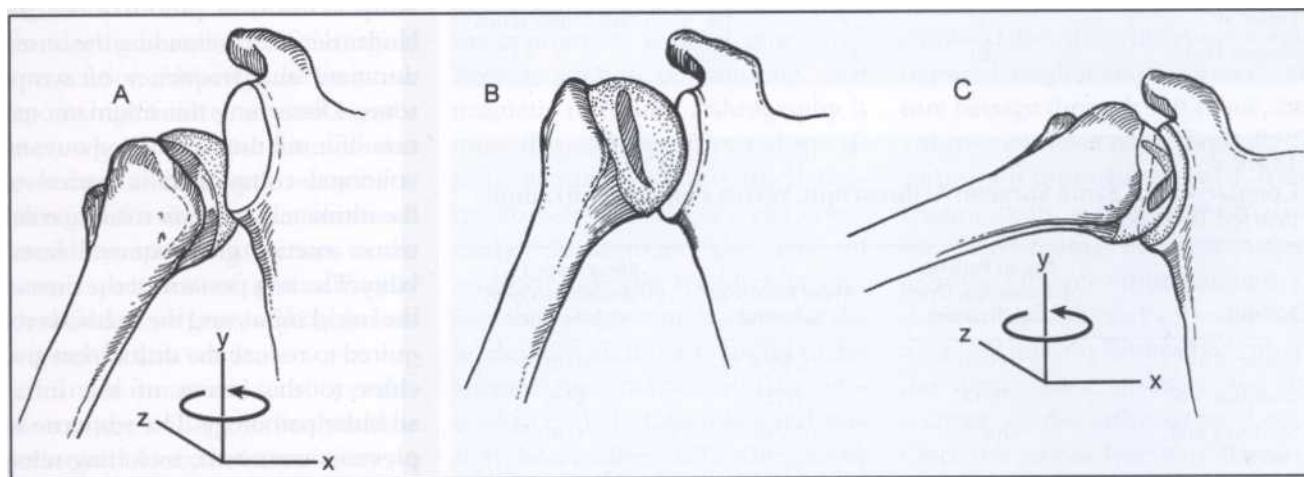
that develop recurrent instability (ie, the shoulders of patients become too loose). However, there is scant mention in the literature of failures of instability repair that are too tight, resulting in stiffness, loss of motion, and late degenerative changes. It is important to remember that stiffness does not equal stability, and that there is significant danger in soft-tissue overconstraint. In addition, the early literature describing the results of open stabilization consists of largely retrospective series with relatively poor results in terms of returning athletes back to their original level of play. In addition, early reports fail to describe patients who have persistent apprehension or recurrent subluxation despite open stabilization procedure.

Variations in surgical indications, surgical techniques, and definitions of success and failure make comparisons across series difficult. Recent prospective studies of arthroscopic stabilization techniques have reported failure rates as low as those reported in the best open repair series, with a high rate of return to sporting activities<sup>18,19</sup> (Table 1).

Johnson<sup>31</sup> first introduced arthroscopic repair with metal staples in 1982; subsequent reports, however, demonstrated unacceptable recurrence rates as high as 33%. This technique has largely been abandoned because of the relatively high complication rates (between 5% and 10%) related principally to the hardware. Transglenoid sutures were introduced by Morgan and Bodinstab<sup>31</sup> and popularized by Caspari and Savoie.<sup>1</sup> Success rates of 90% have been reported,<sup>32,33</sup> but other authors do not report comparable success rates.<sup>34-31</sup> The major advantage of this technique was the multiple points of fixation for the labrum. It also allowed the surgeon to address capsular laxity by shifting the capsule



**Figure 2** The engaging Hill-Sachs lesion. A, This impaction fracture is created when a glenohumeral dislocation occurs with the humerus in abduction and external rotation. B, Schematic showing the orientation of the osseous defect, which is more horizontal. C, Schematic showing the "engagement" of the defect on the anterior glenoid in a functional position of abduction and external rotation.



**Figure 3** The nonengaging Hill-Sachs lesion. A, This impaction fracture is created when a glenohumeral dislocation occurs with the humerus in adduction. B, Schematic showing the orientation of the osseous defect on the humerus, which is more vertical. C, Schematic showing that the defect does not engage the anterior glenoid in a functional position of abduction and external rotation.

superiorly and medially on the glenoid rim. The major disadvantages were the technical difficulty and the transscapular drilling that placed the suprascapular nerve in jeopardy.

To obviate some of these concerns, Speer and associates<sup>37</sup> introduced a bioabsorbable (polyglycolic acid) single-point transfixing implant for intra-articular labral repair (Suretac, Acuflex Microsurgical, Norwood, MA). Initial enthusiasm was

tempered when recurrence rates up to 21% were reported. Recent experience has suggested that recurrence rates can be decreased to less than 10% if the procedure is limited to those with isolated Bankart lesions and no capsular injury.<sup>38,41</sup> Disadvantages of this technique include the inability to address concomitant capsular laxity and the potential for a synovial reaction to the polyglyconate of the implant, which may occur

in up to 6% of patients.<sup>42,43</sup>

**Modern Suture Anchor Repairs**

Repair techniques that use suture anchors have become the most commonly used arthroscopic repair method. This is also the authors' preferred method of repair. The method was first described by Wolf,<sup>11</sup> who reported using a metal anchor and tying knots with absorbable sutures. In 1994, Snyder<sup>44</sup> mod-

**Table 1**  
**Arthroscopic Reconstruction Using Suture Anchors**

Author(s)	No. of Patients	Mean Follow-up (months)	Recurrence (%)	Comments
Wolf <sup>10</sup>	50	"short"	0	
Belzer and Snyder <sup>11</sup>	37	22	11	13% reported "apprehension"
Hoffman and Reif <sup>20</sup>	30	24	11	
Guanche et al <sup>21</sup>	25	27	33	Comparative series
Bacilla et al <sup>22</sup>	40	30	7	High-demand patients
Sisto and Cook <sup>23</sup>	27	47	13	Refined indications
Field et al <sup>4</sup>	50	33	8	Comparative series
Gartsman et al <sup>25</sup>	53	33	8	"Rx all pathology"
Cole and Romeo <sup>26</sup>	32	26	0	3 to 4 anchors per shoulder
Mishra and Fanton <sup>27</sup>	42	28	7	Radiofrequency augmentation
Kim et al <sup>28</sup>	58	39	10	Comparative series
Abrams et al <sup>29</sup>	61	35	6.6	

**Table 2**  
**Comparison of Same Surgeon Arthroscopic Versus Open Stabilization (Varied Techniques)**

Authors	No. of Patients (Arthroscopy/Open Stabilization)	Mean Follow-up (Months)	Recurrence (%) (Arthroscopy/Open Stabilization)
Geiger et al <sup>45</sup>	16/8	23/24	43/8
Guanche et al <sup>21</sup>	25/12	27/25	33/8
Steinbeck and Ierosch <sup>46</sup>	30/32	36/40	17/6
Field et al <sup>24</sup>	50/50	33/30	8/0
Cole and Warner <sup>47</sup>	37/22	52/55	24/18
Karlsson et al <sup>48</sup>	66/53	32	15/10
Sperber et al <sup>49</sup>	30/26	13/10	23/12
Kim et al <sup>28</sup>	30/58	39	10/10

ified the technique with the use of permanent sutures. Although in the past 10 years several series have reported failure rates ranging between 0 and 33%<sup>10,11,29</sup> (Table 1), recent comparative studies of arthroscopic suture anchor technique and open stabilization report recurrence rates of less than 10%<sup>22,24,28,45-49</sup> (Table 2). Compared with transglenoid repair techniques, suture anchor repair

techniques allow for knots to be tied in the joint arthroscopically, thus avoiding the risk of and need for a posterior incision. Newer implant designs allow for suture repair using anchors without knots, thus eliminating knot tying altogether.

### Patient Selection

When considering arthroscopic shoulder stabilization, patient selec-

tion is critical, and the patient's history, motivation, and goals must be considered. The relative contraindications to arthroscopic stabilization, including significant bone loss, humeral avulsions of the glenohumeral ligaments, capsular insufficiency (revisions), and the inability to achieve stability by an all-arthroscopic technique, must also be considered.

## Evaluation

### History and Physical

#### Examination

A thoughtful and detailed history and physical examination are the most important tools in the evaluation of anterior glenohumeral instability. Historical information includes details surrounding the onset, duration, and frequency of symptoms. Discerning the traumatic nature of instability and ruling out any volitional component is critical to the ultimate success in treating traumatic anterior glenohumeral instability. The arm position at the time of the initial injury and the methods required to reduce the dislocation give clues to the extent of the intra-articular pathology. The response to previous treatment, including rehabilitation and activity modification, should be determined. The patient should also be asked comprehensive questions regarding the nature and location of the pain and disability. Catching or audible "clicks" or "pops" may suggest a displaced labral tear. For example, patients who sustain sudden severe trauma with the arm positioned in abduction and external rotation are likely to have a Bankart lesion, whereas patients with recurrent subluxations from repetitive overhead activities such as pitching are likely to have a significant component of capsular laxity contributing to their instability.

Patient age and activity level are

critical to predicting the natural history and risk of recurrence. Patients younger than 20 years and those who participate in contact sports are at the highest risk for recurrence (approaching 90% to 95%). There is particular interest in using immediate arthroscopic stabilization to treat young athletes with an initial anterior or glenohumeral dislocation.<sup>31,39</sup> Advantages include optimal pathology with good quality tissue and minimal collateral tissue damage in patients with a high likelihood of recurrence without surgery despite immobilization. Patients with recurrent anterior glenohumeral instability despite attempts at physical therapy or a willingness to modify their activities are also deemed candidates for surgical intervention. Although the literature reports high failure rates among athletes who participate in collision sports and undergo arthroscopic stabilization for anterior glenohumeral instability, specific attention to the entire spectrum of pathoanatomy identified at surgery is likely to lead to a satisfactory result.

Careful motor and sensory evaluation of the axillary nerve should be performed to exclude an injury. In older patients, weakness may indicate a rotator cuff tear. The presence of muscle atrophy and ligamentous laxity should be noted. Although it may be difficult to clinically assess laxity of the joint because of muscle guarding, side-to-side comparisons should be made for both the degree and direction of glenohumeral translation. In the appropriate setting, provocative testing, particularly testing for apprehension with a relocation maneuver, can be virtually diagnostic for anterior glenohumeral instability.<sup>40</sup> Inferior laxity should be assessed with a sulcus sign. Although the degree of a normal sulcus sign is quite variable, a painful sulcus sign suggests inferior instability. Further-

more, a large sulcus sign that persists when the adducted arm is externally rotated suggests insufficiency of the rotator interval capsular region.

### **Radiographic Evaluation**

Radiographic evaluation may include plain radiographs, MRI, and CT. An appreciation for concomitant glenoid fractures, large Hill-Sachs lesions, and other bony abnormalities will be helpful in determining whether arthroscopic or open stabilization is the appropriate surgical approach. Determining coexisting pathology (ie, rotator cuff tears), the degree of capsular laxity, and the extent of labral pathology is also helpful in selecting the appropriate surgical procedure. Recent studies demonstrate that magnetic resonance arthrography is more than 90% sensitive and specific in detecting inferior labral ligamentous lesions.<sup>51,52</sup> CT can effectively demonstrate the size of associated glenoid fractures or erosions and impression fractures of the humeral head. It is also useful to determine the orientation of the glenoid to exclude hypoplasia and version abnormalities. CT arthrography can also be used to demonstrate soft-tissue pathology such as capsular or labral detachment and excessive capsular redundancy.<sup>53,54</sup>

## **Arthroscopic Repair**

### **General Principles**

Surgical tenets include the reattachment of the anteroinferior labrum along with the reestablishment of proper tension in the inferior glenohumeral ligament complex. Capsular laxity is addressed by superior and medial shift of the capsule. If the capsulolabral suture repair does not seem to decrease all of the capsular laxity, capsular plication or thermal capsulorrhaphy can be used as adjuncts. If there appears to be insuffi-

ciency of the rotator interval region with persistent inferior laxity, then this region should be plicated as well. Finally, an associated tear of the superior labrum should also be repaired. In the rare instances in which a midcapsular rupture or an avulsion of the humeral insertion of the glenohumeral ligament is encountered, conversion to an open reconstruction may be required. **(DVD 49.1)**

### **Instrumentation**

Various commercial instruments are available, and choices are typically based on surgeon experience and familiarity. Appropriately sized disposable cannulas are necessary to accommodate the instrumentation required for glenoid preparation, suture passage through soft tissue, and arthroscopic knot tying. Typically, 5- and 8-mm cannulas are used. Most commercially available cortical anchors have pullout strengths that exceed the ultimate failure strength of the suture, knot, and soft-tissue interface. Thus, the limiting factors are the suture-tissue interface and the security of the arthroscopic knots. Once the anchor has been placed in the tissue, several different types of devices can be used to retrieve the suture and place it through the capsule and ligaments. Some of these devices pierce the ligaments and labrum and then retrieve the suture, and others use a suture loop that is placed through the tissue. This suture loop then serves as a shuttle for the actual suture from the anchor. Surgeon preference again determines which device is used, although it is the authors' opinion that shuttling devices seem to be more flexible and gentler on delicate tissues.

After the sutures are passed through the tissues, arthroscopic knots are tied. This requires an arthroscopic

knot pusher. Although some knot pushers allow the individual suture limbs to be pushed away from each other, thus tensioning the knot, others are simply straight pushers that allow a sliding knot or a half-hitch knot to be slid down a post. If a transfixing device is used, then all of the required instrumentation is part of the insertion of this device.

### **Anesthesia and Positioning**

Interscalene regional anesthesia, general anesthesia, or a combination of both may be used. Regional nerve blocks decrease narcotic requirements and aid in early postoperative pain relief. Either the beach chair or lateral decubitus position may be used. The beach chair position is efficient and conversion to an open approach is easier with the patient in this position compared with the lateral decubitus position. Access to the capsule may be limited compared with the lateral decubitus position, which uses traction on the arm to improve access to the axillary pouch and posterior recess.

### **Examination Under Anesthesia**

Examination under anesthesia should be performed with side-to-side comparisons, and range of motion and the degree and direction of humeral head translation should be documented. Typically, anterior translation over the glenoid rim with (2+ instability) or without (3+ instability) spontaneous reduction is considered abnormal. The sulcus between the inferolateral border of the acromion and the greater tuberosity is measured in centimeters using an inferior displacement force with the arm in different positions of rotation to evaluate capsular laxity and the rotator interval."

In general, the examination under anesthesia confirms the diagnosis established through careful history tak

ing and physical examination. Stability testing with the arm in different positions of abduction will help identify regions of labral or capsular pathology. For example, increased inferior translation when the arm is adducted and externally rotated indicates laxity of the inferior capsule and the rotator interval. Even if translation does not appear to be significantly increased, a Bankart lesion may still be discovered. Thus, correlation with history and preoperative examination is important.

### **Diagnostic Arthroscopy**

The shoulder is prepared for surgery and draped in a sterile manner, and the bony landmarks are carefully marked. A standard posterior portal is established. A systematic evaluation of the glenohumeral joint will demonstrate concomitant pathology including anterior labral detachments, capsular injuries, articular cartilage damage (glenoid and/or Hill-Sachs lesion), superior labrum from anterior to posterior lesions, and rotator cuff tears.

The quality and integrity of the anterior capsuloligamentous structures is determined by observing these structures in different positions of arm rotation while probing and grasping. In general, when the shoulder is placed in a position of abduction and external rotation, the inferior glenohumeral ligament should tighten while the humeral head remains in the glenoid. If an anterior force is applied to the humerus, the humeral head will move anteriorly on the glenoid (arthroscopic drawer). Although the humeral head may move to the anterior edge of the glenoid when the arm is in adduction, there should be no appreciable anterior translation when the shoulder is in abduction and external rotation.

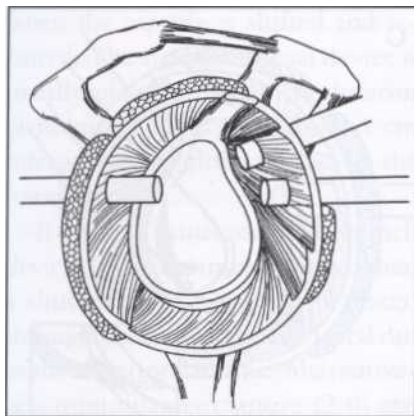
The drive-through sign is the

ability to pass the arthroscope easily from posterior to anterior and then into the axillary pouch. This is indicative of capsular laxity and further delineates the extent of this laxity. A complete diagnostic arthroscopy is performed with the arthroscope placed in both the anterior and posterior portals. Special attention is paid to the rotator interval, superior labrum, rotator cuff, articular cartilage, and reciprocal tightening of the glenohumeral ligaments, especially with the arm abducted and externally rotated. The labrum is evaluated circumferentially for signs of frank detachment or medial healing along the scapular neck. Detachment of the labrum with healing medially on the scapula (anterior labrum periosteal sleeve avulsion lesion) may be difficult to recognize, but it usually appears as a bare glenoid rim with the capsular attachment based medially. It results from repetitive dislocations that strip the capsulolabral attachments from their anatomic origin and push them medially along the scapular neck. This is a condition that must be recognized as the entire capsulolabral sleeve must be mobilized surgically and repaired to the anatomic insertion at the margin of the glenoid rim.

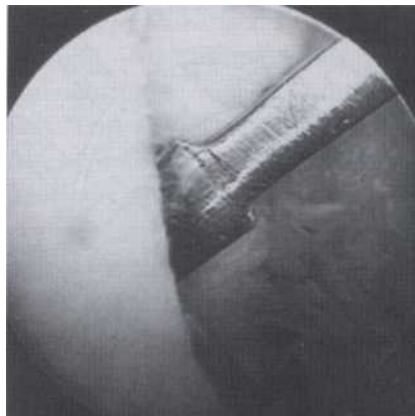
### **Portals**

Two anterior portals (superior and inferior) are established using an outside-in technique with a spinal needle (Figure 4). These portals function as utility portals for instrument passage, glenoid preparation, suture management, and knot tying. It is important to separate these anterior canulas widely so that access in the joint is not a problem. Therefore, a 5- or 6-mm cannula is initially placed in a vertical orientation so that it enters the joint just underneath the biceps ten

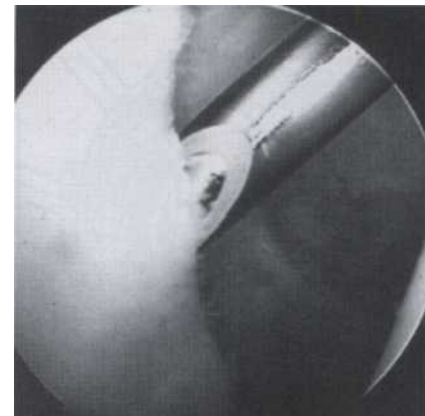




**Figure 4** Schematic of the portals used for arthroscopic instability repairs. Note the relationship of the two anterior portals to the biceps and subscapularis tendons. (Reproduced with permission from Cohen B, Cole B, Romeo A: Thermal capsulorrhaphy of the shoulder. *Oper Tech Orthop* 2001;11:38-45).



**Figure 5** Intra-articular view showing a knife rasp used to mobilize the capsulolabral sleeve. It is important to elevate the tissues until the underlying subscapularis muscle is seen. (Reproduced with permission from Cole BJ, Romeo AA: Arthroscopic shoulder stabilization with suture anchors: Technique, technology, and pitfalls. *Clin Orthop* 2001;390:17-30.)



**Figure 6** An arthroscopic shaver or burr should be used to decorticate the anterior and inferior glenoid surface to achieve an optimal surface for healing. (Reproduced with permission from Cole BJ, Romeo AA: Arthroscopic shoulder stabilization with suture anchors: Technique, technology, and pitfalls. *Clin Orthop* 2001;390:17-30.)

don. This anterosuperior cannula is usually at a 90° angle to the arthroscope. The second cannula is 8 mm in diameter and is placed in the orientation as low as possible in the rotator interval, typically entering just superior to the subscapularis tendon. The proper angle for each portal should be assessed using an outside-in technique with a spinal needle to confirm orientation. The lower, larger cannula is usually placed 1 cm inferior and lateral to the palpable coracoid process so that it enters the joint just over the subscapularis tendon, aiming slightly lateral to medial. This allows the first anchor to be placed at the 5 o'clock position on the clock face of the glenoid (for a right shoulder) with the proper medial orientation. Alternatively, a trans-subscapularis approach can be used to improve inferior access.

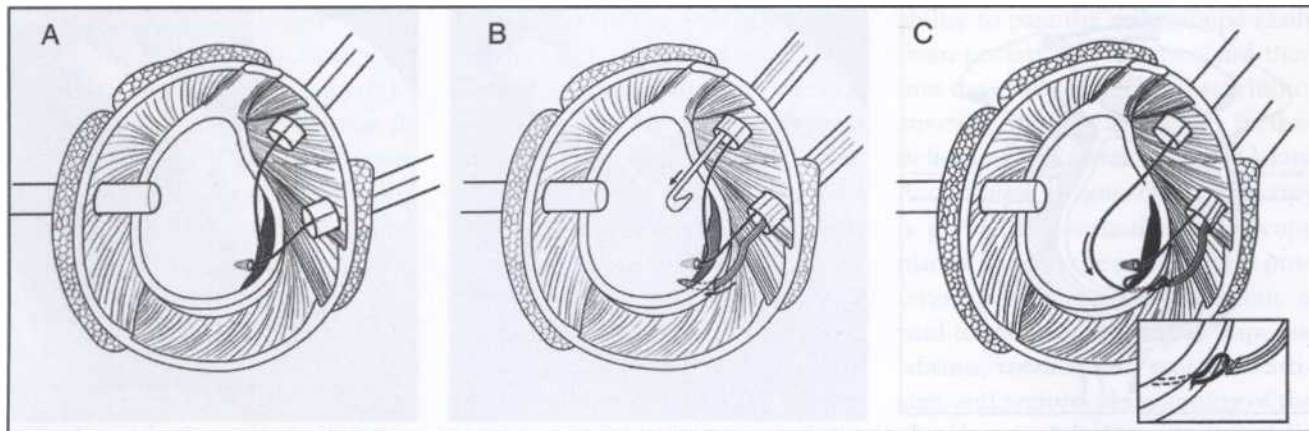
#### **Glenoid Preparation and Anchor Placement**

The 30° arthroscope can be placed in the posterior viewing portal as well

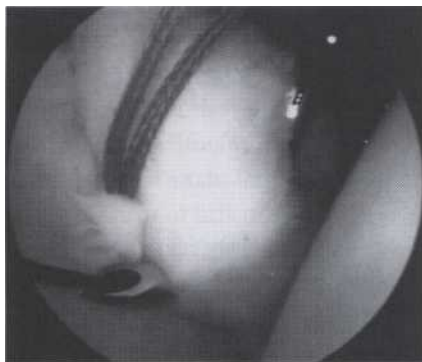as in the anterosuperior portal while working instruments are placed in the anteroinferior portal. In some instances, it is helpful to use a 70° arthroscope to see over the glenoid rim while mobilizing the capsulolabral sleeve. The capsulolabral complex is mobilized off the glenoid neck inferiorly to the 6 o'clock position using electrocautery or a radiofrequency device. A periosteal elevator or knife rasp may also be useful (Figure 5). It is especially important to mobilize the capsulolabral sleeve so that it is freely mobile and can be shifted superiorly and laterally to the glenoid rim. This often requires it to be released from the glenoid neck until the muscle fibers of the underlying subscapularis are seen. Either a motorized hooded burr or shaver may be used to decorticate the anterior and inferior glenoid neck (Figure 6). The abrasion of the juxta-articular scapula should continue approximately 1 to 1.5 cm medial to the articular cartilage and extend all the

way to the inferior glenoid (6 o'clock).

anchors are placed on the articular rim through the anteroinferior cannula at an angle of approximately 45° to the frontal plane to avoid articular penetration and to minimize the risk of inadvertent medial placement along the scapular neck. Anchor placement is from inferior to superior, with the first anchor placed at approximately the 5 o'clock position. Suture passage and knot tying are done after each anchor is placed and before subsequent anchor insertion. Anchor placement may be facilitated by a toothed or serrated cannulated drill guide that maintains the juxta-articular anchor position and by pre-drilling if necessary. Anchors are generally either metal or bioabsorbable polymers. More recently, anchor technology that allows for suture repair without knots has been developed. This design permits the suture to be captured in the end of the anchor once the suture has been passed



**Figure 7** Schematic showing the placement of the first anchor and passage of the sutures. A, Using the anteroinferior portal, the first anchor is placed low (5 o'clock) on the glenoid and at the articular margin. A crochet hook is used to separate the two sutures between the two cannulae. B, A penetrating shuttling device is placed through the anteroinferior cannula and is passed through the capsulolabral tissues. The arrows indicate the direction of insertion. The capsulolabral tissue is penetrated laterally and inferiorly to the anchor so that the capsule will be shifted medially and superiorly. C, The suture in the anterosuperior cannula is retrieved with the shuttling device and is passed through the capsulolabral complex (inset). For knot tying, this limb will then become the post suture so that the knot will rest on the capsulolabral side of the repair. The arrow indicates the direction in which the suture is pulled. (Reproduced with permission from Romeo A, Cohen B, Carreira D: Traumatic anterior shoulder instability. *Oper Tech Orthop* 2000;8:188-196.)



**Figure 8** A suture hook (Linvatec) is passed through the capsulolabral tissues. A shuttle relay (Linvatec) device is then passed into the joint so that the suture from the anchor can be shuttled through the tissue. (Reproduced with permission from Cole BJ, Romeo AA: Arthroscopic shoulder stabilization with suture anchors: Technique, technology, and pitfalls. *Clin Orthop* 2001;390:17-30.)

through the tissue. It is then placed into a predrilled hole and impacted until the capsulolabral tissue is pulled securely against the glenoid rim, thus avoiding all of the steps of knot tying.

Following anchor placement, assessment of anchor security, suture slippage, and knot security is performed. Most surgeons use No. 1 or No. 2 braided, nonabsorbable material or prolonged absorbable, braided suture because of its strength and handling properties, which allows for secure knots that do not slip.

#### **Anterior Glenohumeral Reconstruction**

The first anchor is critical in establishing proper capsular tension (Figure 7). After mobilization of the capsulolabral periosteal sleeve as described above, the first anchor is placed at the articular margin at least as low as the 5 o'clock position. One limb of the suture from this anchor is retrieved through the superior cannula as this will be transported through the capsule with a device placed through the inferior cannula. A crochet hook or other retrieving

device can be used for this step. If possible, it is important to transport the suture that comes out of the anchor on the inferior or medial surface. This will prevent the suture from twisting on itself and will thereby permit easier knot tying with a sliding knot. A hooked device or punch device (eg, the Arthex Suture Lasso, Arthex, Naples, FL or the Spectrum Soft-Tissue Repair System, Linvatec, Largo, FL) is placed through the capsule medial and inferior to the lowest anchor so that the entire inferior glenohumeral ligament is shifted superiorly and laterally (Figure 8). The hook can be pulled when it is in the tissue to confirm the quality of the bite and the tension in the inferior glenohumeral ligament. Tension can also be assessed with a soft-tissue grasper placed through the superior portal while pulling on the hook in the inferior glenohumeral ligament. The labrum should be included in this

suture loop so that it will be repaired when the capsule is shifted and repaired. The suture retrieval device is usually placed through the inferior glenohumeral ligament about 1 cm inferior and slightly medial to the lowest anchor.

If a suture shuttle device or punch device (Caspari punch) is used, then a shuttle relay (Linvatec) is placed through the device and retrieved out of the superior cannula. Alternatively, a monofilament suture (2-0) can be placed, either as a loop or as a single strand to shuttle the suture. If it is retrieved as a loop, it is used to shuttle the suture limb from the anchor back through the capsulolabral tissue. If it is a single limb, it is simply tied to the suture limb from the anchor, which is then shuttled through the tissue. The shuttle relay device is used in the same manner. When transferring suture, it is important to watch carefully to prevent inadvertently unloading the suture from the anchor. Placing a hemostat on the suture limb remaining within the anterosuperior cannula and visualizing the limb during transfer is the most effective way to prevent this from occurring. Alternatively, the eyelet on the anchor can be observed as the suture is pulled; if the sutures are moving at the eyelet, the wrong end of the suture is being pulled.

The suture limb that exits the anterosuperior cannula is the suture that will ultimately pass through the soft tissue. This is called the post suture because the sliding arthroscopic knot will move down this limb. It is important to choose this limb as the post because the knot will then sit on top of the tissue and not underneath it. It is preferable to have the knot on the capsulolabral side.

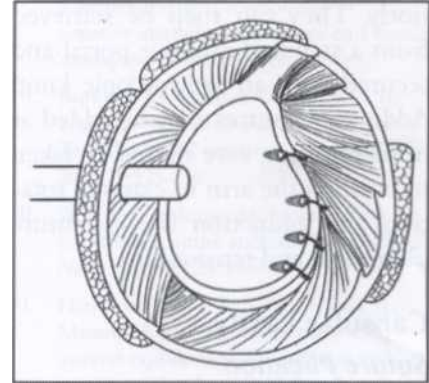
The sequence of steps involved with knot tying begins by placing the knot pusher on each individual limb

and passing it down into the joint to make sure there is no tangling or twisting of the suture limbs. Most surgeons prefer to tie a sliding knot first. This allows the knot to be securely placed, tensioning the tissue. This may be a sliding knot that does not lock (ie, Duncan loop) or a self-locking knot (eg, Bunt line half-hitch, Roeder, or Weston). The knot is "set" by placing a hemostat between the two limbs just distal to the knot and eliminating the slack within the suture loops against the post.

Placing a knot pusher on the post limb and pushing the knot down the post while simultaneously pulling the knot into the joint minimizes suture trauma and reduces the risk for suture failure. Subsequently, several alternating half-hitch, nonsliding knots are advanced down the post guided by the knot pusher. While the first sliding knot is placed by pulling on the post and pushing on the knot, the subsequent half-hitch knots are pulled into the joint by placing the knot pusher just past the half hitch so it pulls on the suture bringing the knot down into the joint. The knot is then tightened by using a past pointing technique with the knot pusher. Alternating the posts and the direction of each half hitch maximizes knot security. The ends are cut, leaving a 3-mm tail. These steps are repeated for each subsequent anchor (Figure 9).

### **Rotator Interval**

If the shoulder demonstrates persistent inferior or inferoposterior translation after repair of the labrum and inferior and middle glenohumeral ligaments, rotator interval closure should be considered. The arm should be placed in slight external rotation to avoid restriction of this motion postoperatively. A curved suture hook or spinal needle is placed through the an-



**Figure 9** Schematic showing the completed anterior capsulolabral repair with three to four anchors placed sequentially from inferior to superior. (Reproduced with permission from Romeo A, Cohen B, Carreira D: Traumatic anterior shoulder instability. *Oper Tech Orthop* 2000;8:188-196.)

terosuperior cannula or percutaneously through the portal without the cannula and advanced through the healthy tissue capsular immediately adjacent to the supraspinatus tendon. The suture hook is advanced inferiorly through the capsular tissue adjacent to the subscapularis tendon and a No. 1 monofilament is advanced through these two tissue regions.

If it is difficult to grasp sufficient tissue with a single pass of the suture hook, an alternative method involves the percutaneous placement of a suture grasper (Penetrator, Arthrex) through the inferior tissue. The suture is then advanced through the superior tissue, either with the Spectrum suture hook (Linvatec) or a spinal needle, and retrieved with the grasping instrument. In either case, the suture ends are retrieved through the anterior portal, after backing tip the cannula, and secured using an arthroscopic sliding knot. This knot is tied blindly, extra-articularly over the anterior soft tissues. Alternatively, the sutures can be retrieved from within the subacromial space by

viewing from within the space posteriorly. They can then be retrieved from a standard anterior portal and secured with an arthroscopic knot. Additional sutures may be added as needed. Again, care should be taken to position the arm in external rotation and adduction during suture placement and tensioning.

## **Capsular Laxity**

### **Suture Plication**

Excessive capsular laxity can be addressed by suture plication. Currently, this is the authors' method of choice for addressing pathologic glenohumeral capsular laxity with or without an associated Bankart lesion. The plication can be performed with either nonabsorbable or absorbable sutures. The technique involves either lateral to medial or inferior to superior shift of the capsule. This can be accomplished either using the pinch-tuck method, suturing capsule to capsule, or as a shift, plicating the capsule to the labrum.

The capsule is initially prepared by abrading it with a full-radius shaver. If the suction is turned off, unintentional capsular damage by the shaver will be minimized. Next, a suture passing device, such as a Spectrum suture hook, Suture Lasso (Arthrex), or similar device, is used to grasp the capsule. The capsule is then shifted the desired amount by penetrating another region of the capsule with the suture passing device. Sutures are then passed and tied arthroscopically, using standard techniques as described previously in this chapter. This effectively decreases capsular volume and decreases glenohumeral joint laxity.

**Thermal Capsulorrhaphy** Thermal capsulorrhaphy has been used as an adjunct to tighten the capsule if persistent capsular laxity remains after the capsulolabral repair.

Unfortunately, few published peer-reviewed studies advocating its routine use appear in the literature. Initial enthusiasm for this technique has been tempered because several series have documented unacceptably high failure rates<sup>61</sup>'s' (DF D'Alessandro, JP Bradley, Orlando, FL, unpublished data, 2000; TJ Noonan, KK Briggs, RJ Hawkins, Miami Beach, FL, unpublished data, 2000; DF D'Alessandro, JP Bradley, PM Connor, personal communication, 2001). If thermal energy is used for a lax capsule, it should be applied after all anchors have been placed and all knots have been tied. Shrinking before suture placement increases the level of difficulty in assessing, approximating, and repairing the soft tissue to the glenoid rim. After suture repair, care should be taken to avoid thermal treatment near the suture line because of the risk of soft tissue weakening and failure. Either a monopolar radiofrequency device or a bipolar radiofrequency device can be used. To date, no prospective, randomized comparisons of these devices with control groups have been conducted. Thus, the technique of thermal treatment of the capsule remains empiric. A grid-like or "cornrow" pattern is preferred because this theoretically maintains normal areas of the capsule between thermally treated areas, allowing viable cells to repopulate thermally modified areas. Results with this technique have been variable, with recurrence rates from 0 to 59%; in general, the results have been less favorable than those achieved with traditional open repair techniques. In light of this and the development of better techniques for suture plication, there is currently a trend away from thermal capsulorrhaphy and toward arthroscopic suture plication for excessive capsular laxity.

The notable exception is throwing athletes with internal impingement.

Levitz and associates's found thermal

capsular shrinkage useful as an adjunct to the standard surgical treatment of pathology in the overhead athlete's shoulder. They reported that it significantly improved the rate of return to competition. In treating the underlying capsular pathology that leads to rotational instability, data from this series support the adjunctive use of thermal capsulorrhaphy in this specific patient population. The authors stress that the postoperative rehabilitation of these athletes must be carefully monitored by both therapist and physician and that the rehabilitation is as important as the surgical treatment.

### **Postoperative Rehabilitation**

Postoperative rehabilitation after arthroscopic repair is identical to that following open reconstruction. Sling immobilization is generally required for 4 to 6 weeks depending on the methods used and the instability pattern treated. Active and unrestricted range of motion of the hand, wrist, and elbow begins immediately following surgery. Similarly, deltoid isometrics and gentle pendulum exercises begin immediately. Some surgeons allow active, forward elevation restricted to 120° after the first 2 to 3 weeks, as experimental studies have shown that this places little load on the capsulolabral region. At this point, external rotation may be permitted to 30° to 40° as well, depending on the extent of repair. At 4 to 6 weeks, rotation limits are gradually extended; at 8 to 10 weeks, progressive resistive exercises begin. Return to sport occurs at 18 to 36 weeks.

### **Summary**

Arthroscopic stabilization for anterior glenohumeral instability has developed rapidly over the past 20 years. Better understanding of the pathoanatomy associated with gleno

numeral instability and advances in surgical technology and technique now make it possible to duplicate and perhaps even exceed the results of open stabilization techniques. The pathoanatomy of instability is quite complex and can involve both soft tissue and bony elements. Failure to recognize and address the pathoanatomy can result in poor results with high recurrence rates. Each element of the instability must be addressed surgically, whether through arthroscopic or open techniques.

A variety of arthroscopic techniques are now available to restore anterior glenohumeral stability. The principal goal is to repair the capsulolabral sleeve carefully with appropriate tension. The techniques described in this chapter allow a thorough evaluation of the patient with instability and present a variety of arthroscopic methods for treating the pathology. Direct repair of the capsule and labrum, plication of the capsule, and closure of the rotator interval can all be accomplished with the arthroscopic techniques described in this chapter. At this point, the use of thermal capsulorrhaphy as an adjunct remains unclear. In certain settings, it may prove useful to shrink the capsule and address residual capsular laxity that would otherwise lead to failure. Perhaps more predictably, variable degrees of capsular tightening can be performed using suture plication techniques. Fortunately, peer-reviewed studies on many of these techniques is forthcoming.

Unfortunately, there are no well-designed, randomized, prospective studies comparing arthroscopic stabilizations to control groups, although several recent uncontrolled, prospective studies confirm the efficacy of these techniques. The arthroscopic suture anchor techniques described in this chapter are preferable because

they best restore the anatomy and most closely duplicate the traditional open Bankart repair. Patient selection is still critical to the ultimate success, as is appropriately addressing all the pathology at the time of surgery. Post-operative rehabilitation is not significantly different from that following traditional open techniques, and appropriate intervals for healing arc needed. Obviously, premature return to activities that place stress on the reconstruction will result in early failure. Surgeons are encouraged to practice these techniques in a forum of continuing education before performing them in an operating room setting.

## References

1. Cole B, Warner J: Anatomy, biomechanics, and pathophysiology of glenohumeral instability, in Iannotti J, Williams J, GR (eds): *Disorders of the Shoulder: Diagnosis and Management*. Philadelphia, PA, Lippincott Williams & Wilkins, 1999, pp 207-232.
2. Cooper D, Arnoczky S, O'Brien S, Warren RF, DiCarlo E, Allen AA: Anatomy, histology, and vascularity of the glenoid labrum: An anatomical study. *J Bone Joint Surg Am* 1992;74:46-52.
3. Cole BJ, Rodeo SA, O'Brien SJ, et al: The anatomy and histology of the rotator interval capsule of the shoulder. *Clin Orthop* 2001;390:129-137.
4. Neviasser TJ: The anterior labroligamentous periosteal sleeve avulsion lesion: A cause of anterior instability of the shoulder. *Arthroscopy* 1992;9:17-21.
5. Bigliani LU, Kurzweil PR, Schwartzbach CC, Wolfe IN, Flatow EL: Inferior capsular shift procedure for anterior-inferior shoulder instability in athletes. *Am J Sports Med* 1994;22:578-584.
6. Bigliani L, Pollock R, Soslowky L, Flatow E, Pawluk R, Mow V: Tensile properties of the inferior glenohumeral ligament. *J Orthop Res* 1992;10:187-197.
7. Caspari R, Savoie F: Arthroscopic reconstruction of the shoulder: The Bankart repair, in McGinty J (ed): *Operative Arthroscopy*. New York, NY, Raven Press, 1991, pp 507-516.
8. Morgan CD, Burkhart SS, Palmeri M, Gillespie M: Type II SLAP lesions: Three subtypes and their relationship to superior instability and rotator cuff tears. *Arthroscopy* 1998;14:553-565.
9. Burkhart SS, Morgan CD, Kibler WB: Shoulder injuries in overhead athletes: The "dead arm" revisited. *Clin Sports Med* 2000;19:125-158.
10. Wolf EM: Arthroscopic capsulolabral repair using suture anchors. *Orthop Clin North Am* 1993;24:59-69.
11. Larryman DT II, Sidles JA, I Harris SL, Matsen FA III: The role of the rotator interval capsule in passive motion and stability of the shoulder. *J Bone Joint Surg Am* 1992;74:53-66.
12. Rowe C, Sakellarides H: Factors related to recurrences of anterior dislocations of the shoulder. *Clin Orthop* 1961;20:40-48.
13. Burkhart SS, De Beer JF: Traumatic glenohumeral bone defects and their relationship to failure of arthroscopic Bankart repairs: Significance of the inverted-pear glenoid and the humeral engaging Hill-Sachs lesion. *Arthroscopy* 2000;16:677-694.
14. Burkhart SS, De Beer JF, Tehrany AM, Parten PM: Quantifying glenoid bone loss arthroscopically in shoulder instability. *Arthroscopy* 2002;18:488-491.
15. Rowe C, Patel J, Southmayd W: The Bankart procedure: A long-term end-result study. *J Bone Joint Surg Am* 1978;60:1-16.
16. Pagnani M, Dome D: Surgical treatment of traumatic anterior shoulder instability in American football players. *J Bone Joint Surg Am* 2002;84:711-715.
17. Magnusson L, Kartus J, Ejerhed L, Iulienheim I, Sernert N, Karlsson J: Revisiting the open Bankart experience: A four- to nine-year follow-up. *Am J Sports Med* 2002;30:778-782.
18. Matsen FA, Thomas SC, Rockwood CAJ: Glenohumeral instability, in Rockwood C, Matsen F (eds): *The Shoulder*. Philadelphia, PA, WB Saunders, 1990, pp 526-622.
19. Belzer J, Snyder J: Abstract: Arthroscopic capsulorrhaphy for traumatic anterior shoulder instability using suture anchors and nonabsorbable suture. *Proceedings from the Annual Meeting of the Arthroscopy Association of North America*. Rosemont, IL, Arthroscopy Association of North America, 1995, p 359.
20. Hoffman F, Reif G: Arthroscopic shoulder stabilization using Mitek anchors. *Knee Surg Sports Traumatol Arthrosc* 1995;3:50-54.

## Shoulder Instability and Labrum Injuries

21. Guanche CA, Quick DC, Sodergren KM, Buss DD: Arthroscopic versus open reconstruction of the shoulder with isolated Bankart lesions. *AmJ Sports Med* 1996;24:144-148.
22. Bacilla P, Field LD, Savoie FH III: Arthroscopic Bankart repair in a high demand patient population. *Arthroscopy* 1997; 13:51-60.
23. Sisto DJ, Cook DL: Intraoperative decision making in the treatment of shoulder instability. *Arthroscopy* 1998; 14:389-394.
24. Field L, Savoie F, Griffith P: A comparison of open and arthroscopic Bankart repair. *J Shoulder Elbow Surg* 1999;8:195.
25. Gartsman GM, Roddey TS, Hammerman SM: Arthroscopic treatment of anterior-inferior glenohumeral instability: Two to five-year follow-up. *J Bone Joint Surg Am* 2000;82:991-1003.
26. Cole BJ, Romeo AA: Arthroscopic shoulder stabilization with suture anchors: Technique, technology, and pitfalls. *Clin Orthop* 2001;390:17-30.
27. Mishra D, Fanton G: Two-year outcome of arthroscopic Bankart repair and electrothermal-assisted capsulorrhaphy for recurrent traumatic anterior shoulder instability. *Arthroscopy* 2001; 17:844-849.
28. Kim SH, Ha KI, Kim SH: Bankart repair in traumatic anterior shoulder instability: open versus arthroscopic technique. *Arthroscopy* 2002;18:755-763.
29. Abrams J, Savoie F, Tauro J, Bradley J: Recent advances in the evaluation and treatment of shoulder instability: Anterior, posterior, multidirectional. *Arthroscopy* 2002;18:1-13.
30. Johnson L: Techniques of anterior glenohumeral ligament repair, in Johnson L (ed): *Arthroscopic Surgery: Principles and Practice*. St Louis, MO, CV Mosby, 1986, pp 1405-1420.
31. Morgan C, Bodenstab A: Arthroscopic Bankart suture repair: Technique and early results. *Arthroscopy* 1987;3:111-122.
32. Savoie FH III, Miller CD, Field LD: Arthroscopic reconstruction of traumatic anterior instability of the shoulder: The Caspari technique. *Arthroscopy* 1997; 13:201-209.
33. Torchia ME, Caspari RB, Asselmeier MA, Beach WR, Gayari M: Arthroscopic transglenoid suture repair: 2 to 8 year results in 150 shoulders. *Arthroscopy* 1997; 13:609-619.
34. Walch G, Boileau P, Levigne C, Mandrino A, Neyret P, Donell S: Arthroscopic stabilization for recurrent anterior shoulder dislocation: Result of 59 cases. *Arthroscopy* 1995;11:173-179.
35. Mologne T, Lapointe J, Morin W, Zilberfarb J, O'Brien J: Arthroscopic anterior labral reconstruction using a transglenoid suture technique. *AmJ Sports Med* 1996;24:268-274.
36. Marcacci M, Zaffagnini S, Petitto A, Pia Neri M, Iacono F, Visani A: Arthroscopic management of recurrent anterior dislocation of the shoulder: Analysis of technical modifications on the Caspari procedure. *Arthroscopy* 1996; 12:144-149.
37. Speer KP, Warren RF, Pagnani M, Warner JJ: An arthroscopic technique for anterior stabilization of the shoulder with a bioabsorbable tack. *J Bone Joint Surg Am* 1996;78:1801-1807.
38. Arciero RA, St Pierre P: Acute shoulder dislocation: Indications and techniques for operative management. *Clin Sports Med* 1995;14:937-953.
39. Arciero R, Taylor D, Snyder R, Uhorchak J: Arthroscopic bioabsorbable tack stabilization of initial anterior shoulder dislocations: A preliminary report. *Arthroscopy* 1995;11:410-417.
40. Resch H, Povacz P, Wambacher M, Sperner G, Golsch K: Arthroscopic extra-articular Bankart repair for the treatment of recurrent anterior shoulder dislocation. *Arthroscopy* 1997; 13:188-200.
41. Laurencin C, Stephens S, Warren R, Altchek D: Arthroscopic Bankart repair using a degradable tack: A followup study using optimized indications. *Clin Orthop* 1996;332:132-137.
42. Warner JJ, Miller MD, Marks P, Fu FH: Arthroscopic Bankart repair with the Suretac device: Part I. Clinical observations. *Arthroscopy* 1995; 11:2-13.
43. Warner J, Pagnani M, Warren R, Cavanaugh J, Montgomery W: Arthroscopic Bankart repair utilizing a cannulated absorbable fixation device. *Orthop Trans* 1991;15:761-762.
44. Snyder R: *Shoulder Arthroscopy*. New York, NY, McGraw Hill, 1994, pp 179-214.
45. Geiger D, Hurley J, Tovey J, Rao J: Results of arthroscopic versus open Bankart suture repair. *Orthop Trans* 1993; 17:973.
46. Steinbeck J, Jerosch J: Arthroscopic transglenoid stabilization versus open anchor suturing in traumatic anterior instability of the shoulder. *AmJ Sports Med* 1998;26:373-378.
47. Cole BJ, Warner JJ: Arthroscopic versus open Bankart repair for traumatic anterior shoulder instability. *Clin Sports Med* 2000;1:19-48.
48. Karlsson J, Magnusson L, Ejerhed L, Hultenheim I, Lundin O, Kartus J: Comparison of open and arthroscopic stabilization for recurrent shoulder dislocation in patients with a Bankart lesion. *AmJ Sports Med* 2001;29:538-542.
49. Sperber A, Hamburg P, Karlsson J, Sward L, Wredmark T: Comparison of an arthroscopic and an open procedure for posttraumatic instability of the shoulder: A prospective, randomized multicenter study. *J Shoulder Elbow Surg* 2001;10:105-108.
50. Speer K, Hannafin J, Altchek D, Warren R: An evaluation of the shoulder relocation test. *AmJ Sports Med* 1994;22:177-183.
51. Green M, Christensen K: Magnetic resonance imaging of the glenoid labrum in anterior shoulder instability. *Am J Sports Med* 1994;22:493-498.
52. Iannotti JP, Zlatkin MB, Esterhai J, Kressel HY, Dalinka MK, Spindler KP: Magnetic resonance imaging of the shoulder: Sensitivity, specificity, and predictive value. *J Bone Joint Surg Am* 1991;73:17-29.
53. Kinnard P, Tricoire J, Levesque R, Bergeron D: Assessment of the unstable shoulder by computed arthrography: A preliminary report. *Ant J Sports Med* 1983;11:157-159.
54. Singson RD, Feldman F, Bigliani L: CT arthrographic patterns in recurrent glenohumeral instability. *AJR AmJ Roentgenol* 1987;149:749-753.
55. Altchek DW, Warren RF, Skyhar MJ, Ortiz G: T-plasty modification of the Bankart procedure for multidirectional instability of the anterior and inferior types. *J Bone Joint Surg Am* 1991;73:105-112.
56. Fitzgerald B, Watson B, Lapointe J: The use of thermal capsulorrhaphy in the treatment of multidirectional instability. *J Shoulder Elbow Surg* 2002;11:108-113.
57. Anderson K, Warren RF, Altchek DW, Craig EV, O'Brien SJ: Risk factors for early failure after thermal capsulorrhaphy. *AmJ Sports Med* 2002;30:103-107.
58. Levitz CL, Dugas J, Andrews J R: The use of arthroscopic thermal capsulorrhaphy to treat internal impingement in baseball players. *Arthroscopy* 2001; 17:573-577.