



# Novel Techniques in Articular Cartilage Restoration

Adam B. Yanke, MD and Brian J. Cole, MD, MBA

## PART ONE: DENOVO NT

### INTRODUCTION

DeNovo NT (Zimmer) is minced (1-mm cubes) juvenile allograft cartilage delivered with fibrin glue indicated for the treatment of chondral defects with minimal to no bone loss. One benefit of DeNovo NT is the use of juvenile tissue, which has been shown to have a considerably greater ability to produce proteoglycans and stimulate matrix production compared to adult sources of chondrocytes.<sup>1,2</sup> An additional feature is that juvenile cells are less immunogenic than their adult counterparts.<sup>1</sup> Because DeNovo NT supplies viable cells, it has a shelf-life of 44 days from the date it was harvested and typically needs to be ordered prior to surgery, similar to an osteochondral allograft. The technique can be applied in an open or arthroscopic fashion; however, the arthroscopic method is significantly more demanding.

Outcomes for DeNovo NT have only recently been reported. Tompkins et al<sup>3</sup> reported on patellar defects ( $2.4 \pm 1.2 \text{ cm}^2$ ) at 28 months using a density of 1 unit per  $1.3 \text{ cm}^2$ . This is twice the density recommended by the manufacturer. In this setting, there was an 89% mean defect fill on magnetic resonance imaging (MRI), and 2 of 15 patients required a debridement for hypertrophy. Farr et al<sup>4</sup> reported on a similar patient population and reported no reoperations at 2 years in 25 patients; the study also demonstrated statistically significant improvements over baseline levels for multiple measures of pain, symptoms, activities of daily living, and sports and recreation.

### INDICATIONS

- ▶ In general, the indications for DeNovo NT mirror that of autologous chondrocyte implantation (ACI).

- ▶ International Cartilage Repair Society grade III cartilage lesion (cartilage defect > 50% cartilage depth but with minimal bone loss, possibly extending down to but not through the subchondral bone)
- ▶ Lesion size > 2 cm<sup>2</sup> after debridement
- ▶ Minimal to no bone loss
  - ▷ Can possibly be performed in conjunction with bone grafting as described in ACI, although there are no data to support this technique
- ▶ Preferentially used in the patellofemoral joint
- ▶ Body mass index less than 30 to 34 kg/m<sup>2</sup>

## Relative Contraindications

- ▶ Bipolar lesion
- ▶ Significant subchondral bone edema
- ▶ > 5 mm of untreated bone loss (osteochondritis dissecans)
- ▶ Unaddressed meniscectomy or malalignment
- ▶ Potentially decreased outcomes in the setting of prior microfracture based on ACI data<sup>5,6</sup>

## PERTINENT PHYSICAL FINDINGS

- ▶ Effusions are probably the most important examination finding demonstrating significant intra-articular pathology
- ▶ Patellofemoral defects
  - ▷ One-finger sign in which a patient points to the front of the patella and describes the pain being deep to this location
  - ▷ Patellar grind test, placing downward force on the patella during flexion and extension
- ▶ Associated pathology
  - ▷ Varus/valgus alignment
  - ▷ Patellar instability/apprehension

## PERTINENT IMAGING

- ▶ X-rays
  - ▷ Anteroposterior standing: Anterior tibiofemoral arthritis
  - ▷ Posteroanterior flexion weightbearing: Posterior tibiofemoral arthritis
  - ▷ Lateral: Patellar alta/baja
  - ▷ Merchant: Patellofemoral joint space narrowing, tilt, and tracking
- ▶ MRI (necessary for all patients to evaluate the following)
  - ▷ Cartilage integrity
  - ▷ Cartilage quality (delayed gadolinium-enhanced MRI of cartilage, fast-spin echo, or other cartilage-specific sequences)
  - ▷ Subchondral bone edema

- ▶ Associated pathology
  - Meniscus status
  - Ligament status
  - Tibial tubercle to trochlear groove (TT-TG) distance
- ▶ Computed tomography (CT)
  - ▶ Considered for patients with significant bone loss, cystic change, or as an alternative to measure the TT-TG distance in the setting of concomitant planned tibial tubercle osteotomy

## EQUIPMENT

- ▶ DeNovo NT needs to be requested prior to surgery because it is viable tissue that is not generally made available as an on-the-shelf option.
- ▶ The manufacturer recommends 1 package per 2.5-cm<sup>2</sup> defect.
- ▶ Arthroscopy setup is based on surgeon preference.
- ▶ Small curettes and ring curette if available

## POSITIONING AND PORTALS

- ▶ Supine with the leg of the bed extended
- ▶ Lateral post
- ▶ Tourniquet

## STEP-BY-STEP DESCRIPTION OF THE PROCEDURE

### *Diagnostic Arthroscopy*

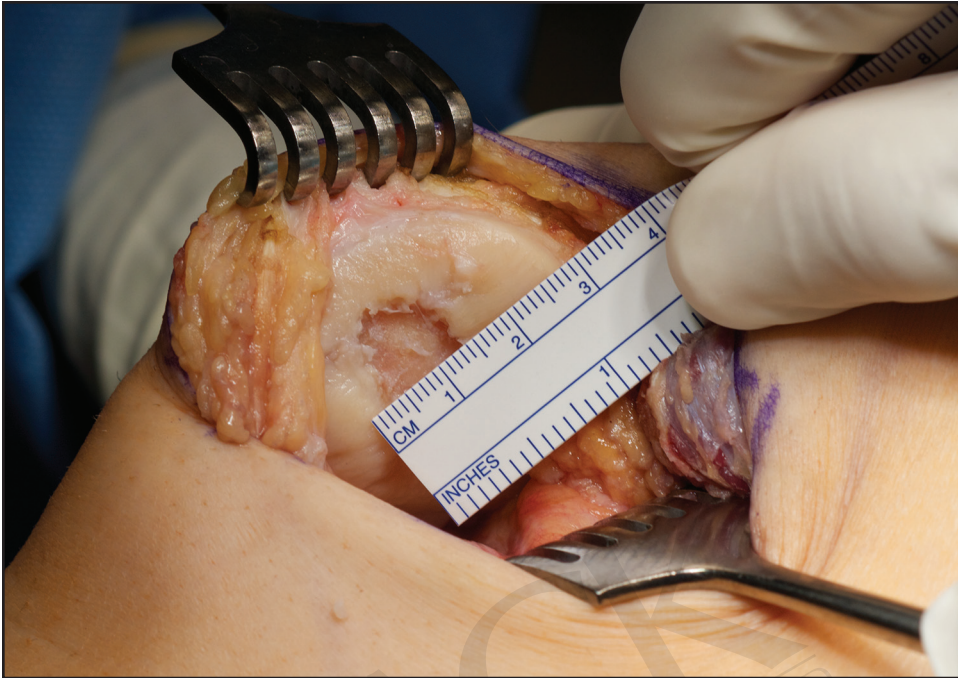- ▶ The procedure should begin with standard diagnostic arthroscopy (inferolateral viewing portal and inferomedial working portal with optional outflow).
- ▶ Evaluate the entire knee and the lesion to determine the lack of unexpected contraindications or concomitant pathology, even in the setting of a relatively recent index arthroscopy indicating a patient for DeNovo NT.

### *Arthrotomy*

- ▶ The authors prefer performing an arthrotomy to access the cartilage defect. The location of the incision depends on the location of the defect, with a lateral arthrotomy preferred for a patellofemoral or lateral femoral condyle defect and a medial vastus-sparing approach for other defects.

### *Defect Preparation*

- ▶ Similar to any cartilage procedure, the defect should be debrided to stable healthy walls that are vertical in nature.



**Figure 21-1.** Sizing of a patellar defect through an arthrotomy after debridement.

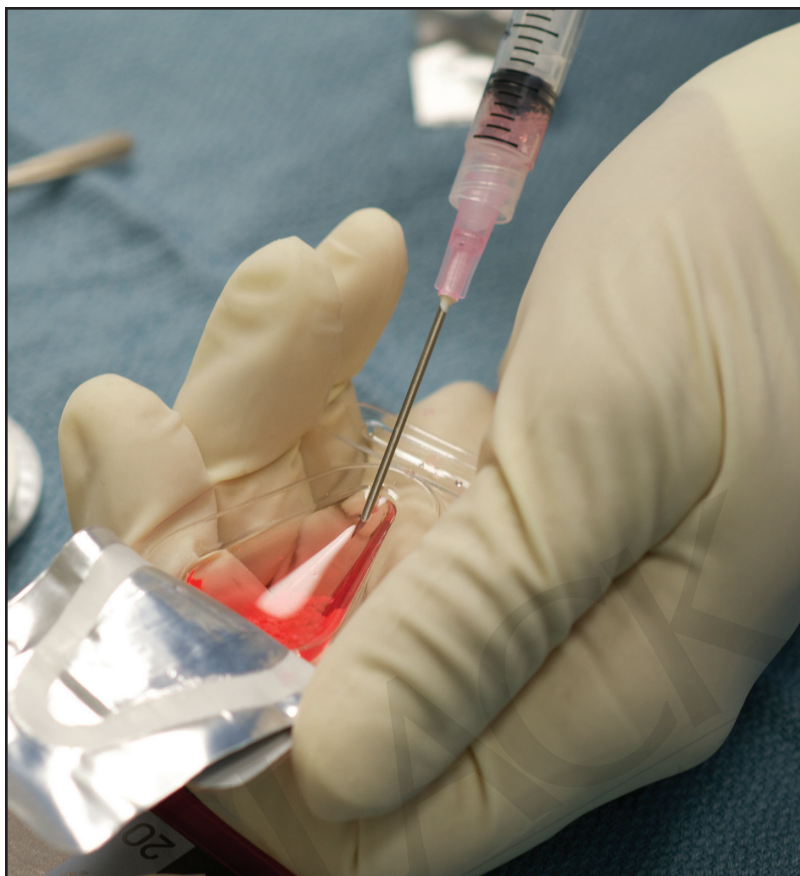
- ▶ The bed of the defect should be free of any diseased tissue, and care should be taken to attempt removal of the calcified cartilage layer without gaining access to the subchondral bone elements.
- ▶ Measure the defect to ensure the size is as expected (Figure 21-1).

### ***DeNovo NT Application Directly Into the Defect***

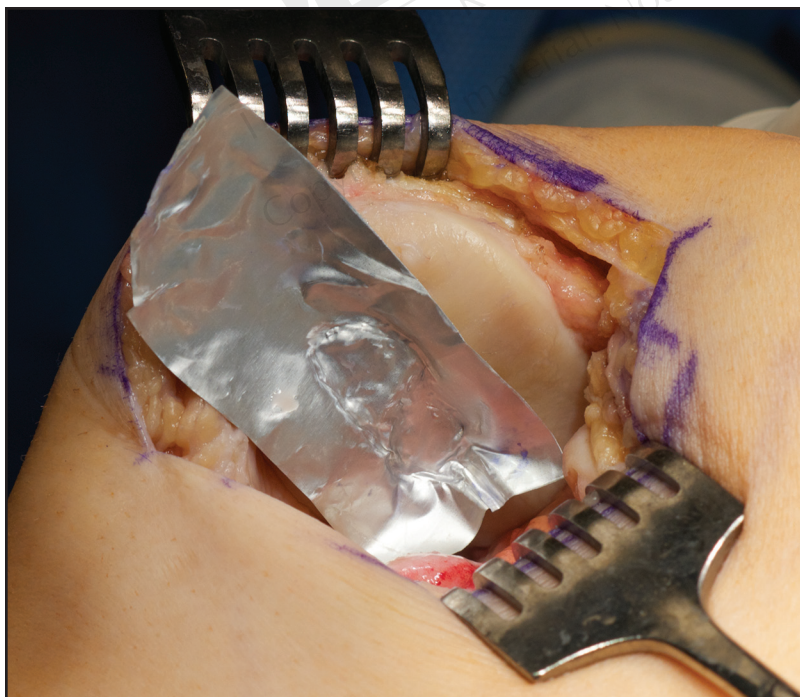
- ▶ Although there are several methods to apply DeNovo NT, the authors' preferred method is preparing the implant directly into the defect.
- ▶ To begin, the remaining media from the DeNovo NT package should be aspirated (Figure 21-2).
- ▶ The minced cartilage can then be placed directly into the defect site, which is immediately covered with fibrin glue.
- ▶ Care should be taken to avoid the fibrin being proud to the bordering healthy chondral surface to avoid displacement.
- ▶ After the fibrin has set, gently range the knee to ensure construct stability.

### ***Extra-Articular DeNovo NT Preparation and Placement***

- ▶ Alternatively, the DeNovo NT implant can be prepared on the back table.
- ▶ A piece of sterile foil can be pressed into the defect to form a negative mold (Figure 21-3).
- ▶ This is then filled with the DeNovo NT and fibrin glue (Figure 21-4).
- ▶ As this sets, place fibrin glue in the base of the defect and press in digitally to decrease bleeding from the defect bed (Figure 21-5).



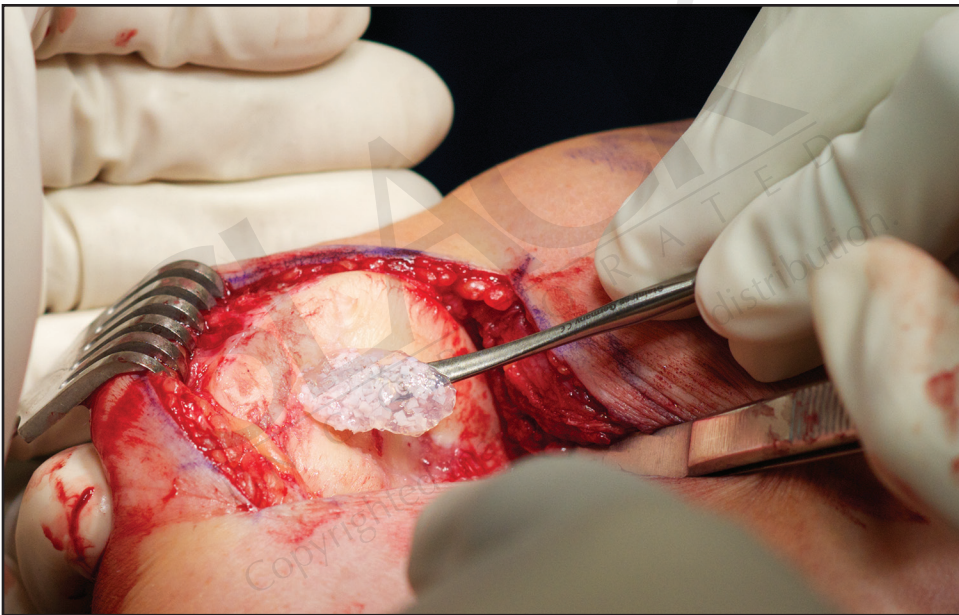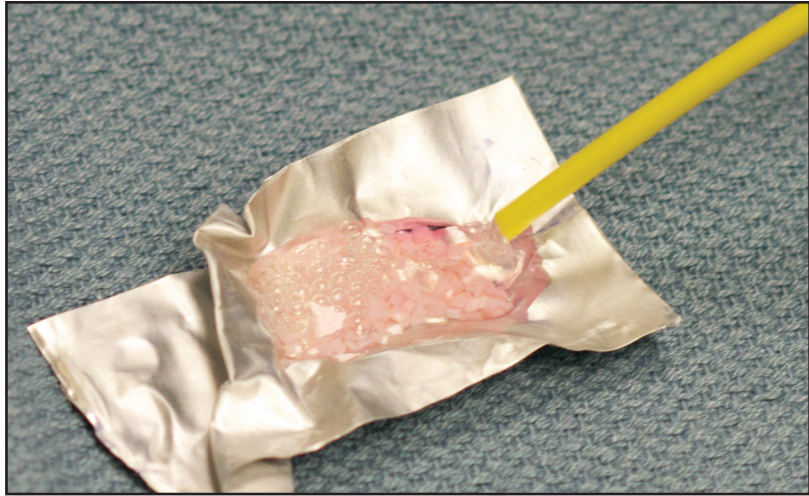**Figure 21-2.** Removing the media from the DeNovo NT implant on the back table.



**Figure 21-3.** Foil placed in a patellar defect to create a negative mold for DeNovo NT placement.



**Figure 21-4.** Fibrin being added to the DeNovo NT placed in the negative mold.

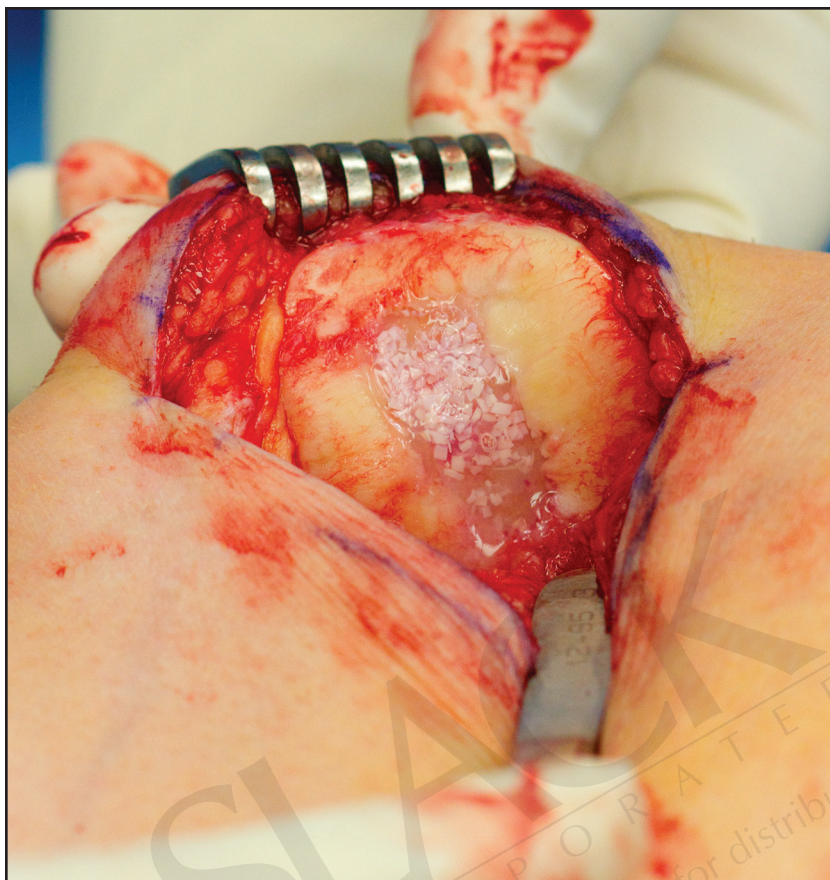


**Figure 21-5.** The implant is lifted from the foil using an elevator and is placed into the defect after fibrin has been placed in the base of the defect.

- ▶ Finally, set the pre-prepared DeNovo implant into the defect bed and ensure stability with knee range of motion (ROM) (Figure 21-6).

## POSTOPERATIVE PROTOCOL (PATELLOFEMORAL)

- ▶ **Weightbearing:** Perform weightbearing as tolerated with the brace locked in extension if no osteotomy was performed. Limit weightbearing to nonweightbearing from 0 to 2 weeks and partial weightbearing at 2 to 4 weeks if osteotomy was performed.
- ▶ **Brace:** Lock in extension for weightbearing for at least 2 weeks, increase by 20 degrees each week until full, and then discontinue.



**Figure 21-6.** The final DeNovo NT implant placed in the patellar defect with fibrin placed over the implant after placement.

- ▶ ROM: Continuous passive motion (CPM) is performed out of the brace for 6 hours per day from 0 to 45 degrees for 3 weeks and is then increased by 5 to 10 degrees per day until it reaches 90 degrees by 6 weeks. Discontinue it thereafter.
- ▶ Exercises: At weeks 1 to 4, perform quadriceps sets and straight leg raises with hamstring isometrics. At weeks 4 to 10, perform isometric closed chain exercises with balance and bike at 8 weeks. At 6 to 8 months, perform fast walking on a treadmill and light plyometric activity. High-impact activities thereafter are limited and advanced as tolerated as long as symptoms do not recur.

## POTENTIAL COMPLICATIONS

- ▶ Lack of integration/graft displacement
- ▶ Graft hypertrophy
- ▶ Risk of infection/allograft transmission
- ▶ Chondrocytes have not been shown to stimulate proliferation of allogeneic or xenogeneic lymphocytes or promote graft rejection immune responses

## TOP TECHNICAL PEARLS FOR THE PROCEDURE

1. Ensure adequate defect sizing if performing a staged procedure in order to place the appropriate amount of DeNovo NT.
2. Do not perform arthroscopically unless you feel you can get the same result as when performing an arthrotomy.
3. Correct associated pathology to optimize the results (eg, osteotomy, meniscal allograft transplantation, medial patellofemoral ligament reconstruction, etc).
4. Ensure that the fibrin glue is not proud relative to the surrounding cartilage.
5. Do not take shortcuts on the rehabilitation; there is no quick fix for cartilage damage and the time required to promote integration and tissue stability.

## PART TWO: BIOCARTILAGE

### INTRODUCTION

Although microfracture is not considered an emerging technology, the augmentation of microfracture continues to evolve. BioCartilage (Arthrex) is one such product that acts as a clot stabilizer that also involves autogenous growth factor delivery. Using micronized hypothermic dehydrated allograft articular cartilage that is 100 to 300  $\mu$  in size, this is mixed in equal parts of an autologous blood solution, such as platelet-rich plasma (PRP). This mixture can be delivered arthroscopically or through an open technique. After placement, fibrin glue is used to maintain the graft in the defect site. BioCartilage does not contain a viable cell source and has a shelf-life of 5 years. Although comparing it to microfracture is favorable in clinical use and basic science in vivo large animal models, no clinical outcomes regarding BioCartilage have been reported.

### INDICATIONS<sup>7,8</sup>

- ▶ In general, the indications for BioCartilage mirror that of microfracture alone.
- ▶ Grade III/IV cartilage lesion
- ▶ Lesion size < 2 to 4 cm<sup>2</sup> after debridement
- ▶ No bone loss
- ▶ Preferentially used on the femoral condyle, trochlea, tibia, and hard-to-reach locations
- ▶ Body mass index < 30 to 34 kg/m<sup>2</sup>
- ▶ No prior cartilage repair surgery
- ▶ Better outcomes if Tegner score is > 4 and symptoms last for < 12 months

### *Relative Contraindications*

- ▶ Bipolar lesion
- ▶ Significant subchondral bone edema



- ▶ Unaddressed meniscectomy or malalignment
- ▶ Larger (> 4 cm<sup>2</sup>) shallow defect with primary microfracture may decrease the potential outcomes of future interventions, such as ACI

## PERTINENT PHYSICAL FINDINGS

- ▶ Effusions are probably the most important examination finding demonstrating significant intra-articular pathology.
- ▶ Femoral defects
  - ▷ Tenderness directly over the femoral condyle. (If it is a distal femoral lesion, it is easiest to palpate directly with the knee in flexion.)
- ▶ Associated pathology
  - ▷ Varus/valgus alignment
  - ▷ Joint line tenderness and prior meniscectomy

## PERTINENT IMAGING

### X-rays

- ▶ Anteroposterior standing: Anterior tibiofemoral arthritis
- ▶ Posteroanterior flexion weightbearing: Posterior tibiofemoral arthritis
- ▶ Lateral: Patellar alta/baja
- ▶ Merchant: Patellofemoral joint space narrowing, tilt, and tracking

### MRI (necessary for all patients to evaluate the following)

- ▶ Cartilage integrity
- ▶ Cartilage quality (delayed gadolinium-enhanced MRI of cartilage, fast-spin echo, or other cartilage-specific sequences)
- ▶ Subchondral bone edema
- ▶ Associated pathology
  - ▷ Meniscus status
  - ▷ Ligament status
  - ▷ TT-TG distance
- ▶ CT
- ▶ A consideration for patients with significant bone loss, cystic change, or as an alternative to measure the TT-TG distance in the setting of concomitant planned tibial tubercle osteotomy

## EQUIPMENT

- ▶ Arthroscopy setup based on surgeon preference
- ▶ Small curettes and ring curette if available
- ▶ Microfracture awls and/or powered device to create subchondral access

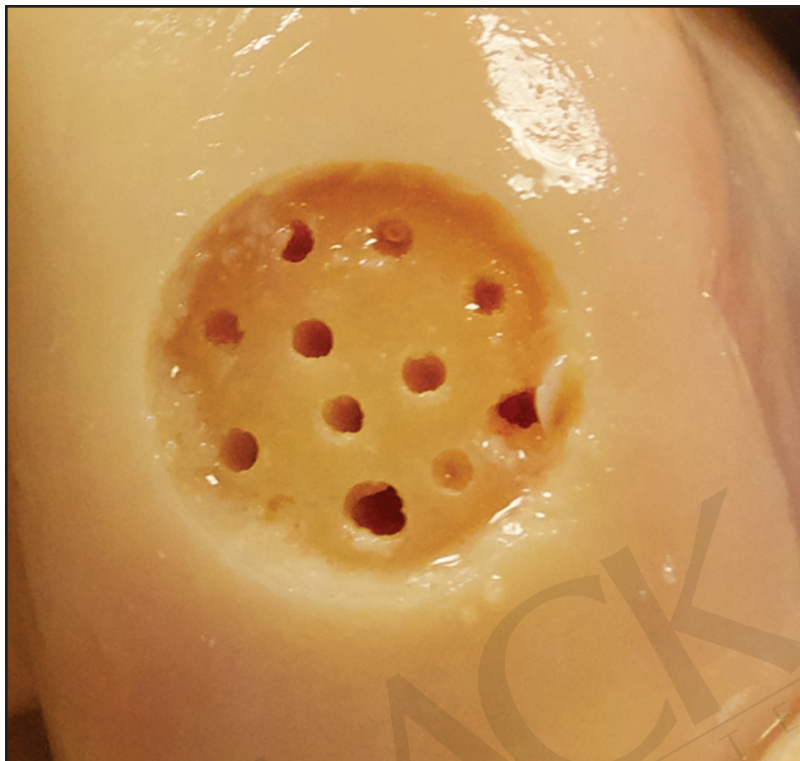- ▶ BioCartilage comes in 1-cc packages that are to be mixed with 1 cc of PRP or less; this typically is enough volume to cover any indicated lesion.
- ▶ BioCartilage Mixing and Delivery System
- ▶ PRP system of choice

## POSITIONING AND PORTALS

- ▶ Supine with the leg of the bed extended
- ▶ Lateral post
- ▶ Tourniquet

## STEP-BY-STEP DESCRIPTION OF THE PROCEDURE

- ▶ Diagnostic arthroscopy: Standard diagnostic arthroscopy (inferolateral viewing portal and inferomedial working portal with optional outflow)
- ▶ Evaluate the entire knee and the lesion to determine the lack of unexpected contraindications or concomitant pathology, even in the setting of a relatively recent index arthroscopy indicating a patient for BioCartilage arthrotomy.
  - ▷ The authors prefer performing an arthrotomy to access the cartilage defect. The location of the incision depends on the location of the defect, with a lateral arthrotomy preferred for a patellofemoral or lateral femoral condyle defect and a medial vastus-sparing approach for other defects.
- ▶ Defect preparation
  - ▷ Similar to any cartilage procedure, the defect should be debrided to stable healthy walls that are vertical in nature.
  - ▷ The bed of the defect should be free of any diseased tissue, and care should be taken to attempt removal of the calcified cartilage layer without gaining access to the subchondral bone elements.
- ▶ Perform microfracture
  - ▷ The bed of the defect should then be microfractured, which is described elsewhere (Figure 21-7).
- ▶ BioCartilage preparation
  - ▷ Open the BioCartilage vial and prepare equal parts of PRP (Figure 21-8).
  - ▷ The mixture should be workable and viscous. Start by adding part of the PRP until you can mold the mixture. This may not require the entire PRP volume (Figure 21-9).
- ▶ BioCartilage application
  - ▷ After BioCartilage preparation, the defect can be approached by arthrotomy or arthroscopy.
  - ▷ If applying via arthroscopy, Touhy needles can be used.
  - ▷ Applying through an arthrotomy can be performed with a freer elevator and digital pressure.
  - ▷ This is then covered with a layer of fibrin glue, making sure that this is not overly proud compared to the surrounding cartilage (Figure 21-10).
  - ▷ The final construct should be stable after putting the knee through a ROM (Figure 21-11).

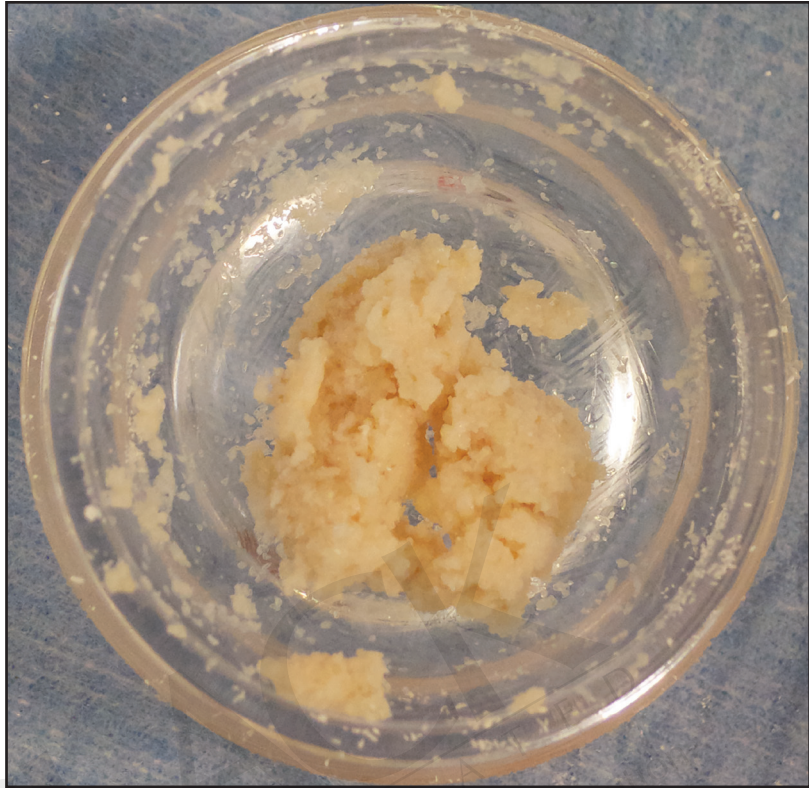


**Figure 21-7.** Cadaveric example of a prepared cartilage defect with microfracture performed.

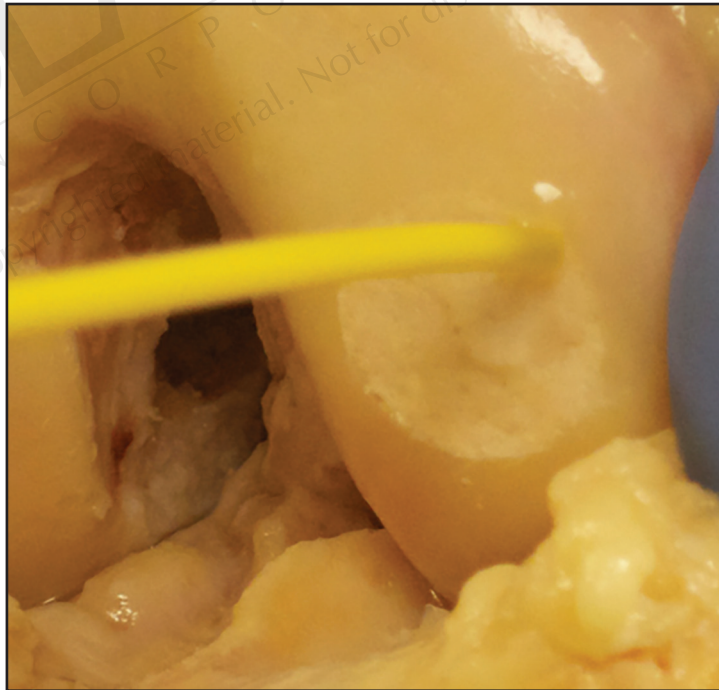


**Figure 21-8.** BioCartilage added to equal parts of PRP.

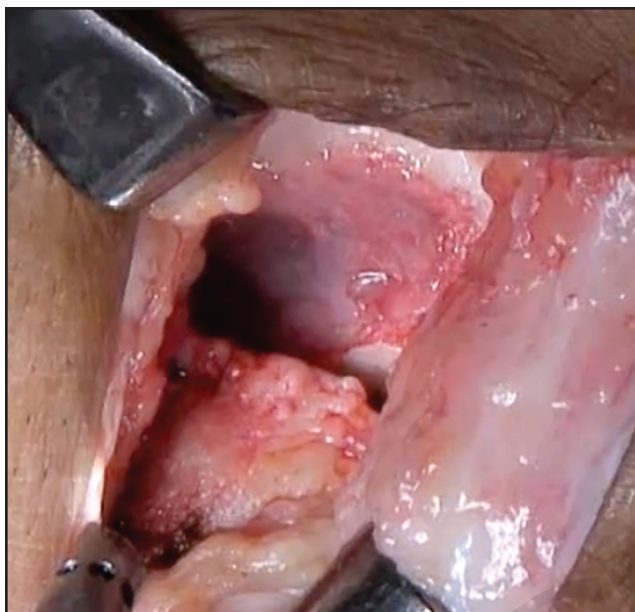**Figure 21-9.** The BioCartilage and PRP mixture prepared for placement into the defect. Note the viscosity and workable texture.



**Figure 21-10.** The BioCartilage implant has been placed into the femoral condyle defect, and fibrin glue is placed over this to improve stability.







**Figure 21-11.** A clinical example of the BioCartilage implant after placement in a femoral condyle defect.

## POSTOPERATIVE PROTOCOL (FEMORAL CONDYLE)

- ▶ **Weightbearing:** Weeks 0 to 2: Nonweightbearing. Weeks 2 to 6: Foot flat weightbearing (30 to 40 lb with use of 1 crutch). Weeks 6 to 12: Progress to full weightbearing and normal gait.
- ▶ **Brace:** Weeks 0 to 2: Locked in full extension (removed for CPM or manually cycle leg and exercise). Weeks 2 to 4: Gradual brace unlocking as lower-extremity control returns.
- ▶ **ROM:** Weeks 0 to 4: CPM for 6 to 8 hours/day (may be broken up into 2-hour increments) at 1 cycle/minute or manually cycle the leg. Begin at 0 to 30 degrees and increase 5 to 10 degrees daily per patient comfort. The patient should gain at least 90 degrees by week 4 and 120 to 130 degrees by week 6 or manually cycle the leg. Full active ROM is allowed thereafter.
- ▶ **Exercises:** Weeks 0 to 2: Quadriceps sets, straight leg raises, hamstring isometrics (complete exercises in the brace if quadriceps control is inadequate). Weeks 2 to 6: Begin progressive closed chain exercises. Open chain exercises with emphasis on quadriceps and core muscles (customized to the site of the lesion). Weeks 10 to 12: Progress closed chain exercises using resistance less than patient's body weight, progress to unilateral closed chain exercises, begin balance activities, and perform biking with progressive load 30 minutes per day as possible. Months 3 to 6: Advance bilateral and unilateral closed chain exercises, with emphasis on concentric/eccentric control; continue with biking, StairMaster, and treadmill; and progress balance activities.
  - ▷ Respect the chondrocyte graft with closed chain activities (if anterior, avoid loading in full extension; if posterior, avoid loading in flexion greater than 45 degrees).
  - ▷ All phases are to include an emphasis on terminal extension and patellar mobility.
  - ▷ If pain or swelling occurs with any activities, they must be modified to decrease symptoms.

## POTENTIAL COMPLICATIONS

- ▶ Microfracture site pain
- ▶ Osseous overgrowth at the site of microfracture
- ▶ Subchondral cyst formation

## ACKNOWLEDGMENTS

We would like to sincerely thank David Merkow and Annemarie K. Tilton for their work on this chapter.

### TOP TECHNICAL PEARLS FOR THE PROCEDURE

1. Do not short-change the microfracture part of the procedure; ensure proper technique with calcified cartilage layer removal and adequate marrow access confirmed visually.
2. Do not perform the procedure arthroscopically unless you feel you can get the same result as achieved with an arthrotomy.
3. Do not add excessive PRP to the BioCartilage; keep it viscous for placement.
4. Ensure that the fibrin glue is not proud relative to the surrounding cartilage.
5. Check knee ROM after finishing to ensure the BioCartilage is retained within the defect.

### REFERENCES

1. Adkisson HD, Gillis MP, Davis EC, Maloney W, Hruska KA. In vitro generation of scaffold independent neocartilage. *Clin Orthop Relat Res*. 2001;(391 suppl):S280-S294.
2. Bonasia DE, Martin JA, Marmotti A, et al. Cocultures of adult and juvenile chondrocytes compared with adult and juvenile chondral fragments: in vitro matrix production. *Am J Sports Med*. 2011;39(11):2355-2361.
3. Tompkins M, Hamann JC, Diduch DR, et al. Preliminary results of a novel single-stage cartilage restoration technique: particulated juvenile articular cartilage allograft for chondral defects of the patella. *Arthroscopy*. 2013;29(10):1661-1670.
4. Farr J, Tabet SK, Margerrison E, Cole BJ. Clinical, radiographic, and histological outcomes after cartilage repair with particulated juvenile articular cartilage: a 2-year prospective study. *Am J Sports Med*. 2014;42(6):1417-1425.
5. Minas T, Gomoll AH, Rosenberger R, Royce RO, Bryant T. Increased failure rate of autologous chondrocyte implantation after previous treatment with marrow stimulation techniques. *Am J Sports Med*. 2009;37(5):902-908.
6. Pestka JM, Bode G, Salzmann G, Südkamp NP, Niemeyer P. Clinical outcome of autologous chondrocyte implantation for failed microfracture treatment of full-thickness cartilage defects of the knee joint. *Am J Sports Med*. 2012;40(2):325-331.
7. Mithoefer K, McAdams T, Williams RJ, Kreuz PC, Mandelbaum BR. Clinical efficacy of the microfracture technique for articular cartilage repair in the knee: an evidence-based systematic analysis. *Am J Sports Med*. 2009;37(10):2053-2063.
8. Kreuz PC, Steinwachs MR, Erggelet C, et al. Results after microfracture of full-thickness chondral defects in different compartments in the knee. *Osteoarthritis Cartilage*. 2006;14(11):1119-1125.

Please see videos on the accompanying website at

[www.healio.com/books/TO COME](http://www.healio.com/books/TO COME)